

Multifocal motor neuropathy

Jan-Thies H Van Asseldonk, Hessel Franssen, Renske M Van den Berg-Vos, John H J Wokke, Leonard H Van den Berg

Lancet Neurol 2005; 4: 309–19

Multifocal motor neuropathy (MMN) is an immune-mediated disorder characterised by slowly progressive, asymmetrical weakness of limbs without sensory loss. The clinical presentation of MMN mimics that of lower-motor-neuron disease, but in nerve-conduction studies of patients with MMN motor-conduction block has been found. By contrast with chronic inflammatory demyelinating polyneuropathy, treatment with prednisolone and plasma exchange is generally ineffective in MMN and even associated with clinical worsening in some patients. Of the immunosuppressants, cyclophosphamide has been reported as effective but only anecdotally. Various open trials and four placebo-controlled trials have shown that treatment with high-dose intravenous immunoglobulin leads to improvement of muscle strength in patients with MMN. Although clinical, pathological, imaging, immunological, and electrophysiological studies have improved our understanding of MMN over the past 15 years, further research is needed to elucidate pathogenetic disease mechanisms in the disorder.

Department of Clinical Neurophysiology (J-T H Van Asseldonk MD, H Franssen PhD) and Department of Neurology (R M Van den Berg-Vos PhD, J H J Wokke PhD, L H Van den Berg PhD), Neuromuscular Research Group, Rudolf Magnus Institute of Neuroscience, University Medical Centre Utrecht, Netherlands

Correspondence to: Dr Leonard H Van den Berg, Department of Neurology, University Medical Centre Utrecht, PO Box 85500, Heidelberglaan 100, 3584 CX Utrecht, Netherlands
l.h.vandenber@neuro.azu.nl

In 1985, Parry and Clarke¹ studied nerve conduction in two patients with a lower-motor-neuron syndrome characterised by progressive, asymmetric, predominantly distal weakness without sensory loss and found conduction block. Soon afterwards, others reported patients with similar characteristics.^{2,3} Weakness in patients with a lower-motor-neuron syndrome with conduction block was shown to be reversible with immunomodulating therapy and associated with high titres of IgM antibodies to GM1 ganglioside.⁴ Hence, a separate disorder emerged: multifocal motor neuropathy (MMN).^{4–11} The disorder was thought to be immune mediated, possibly through IgM antibodies that bind gangliosides on human peripheral nerves.¹² The differential diagnosis of MMN includes motor-neuron disease^{13,14} and demyelinating neuropathies.^{15–17} Diagnosis of MMN is supported by the finding of motor but not of sensory abnormalities on nerve-conduction studies.^{18–23} Whether conduction block must be present for the diagnosis of MMN is debatable. Various open and placebo-controlled studies have shown that treatment with high-dose intravenous immunoglobulin leads to improvement of muscle strength. Intravenous immunoglobulin is now the treatment of first choice in MMN.^{24–27} Many clinical and electrophysiological studies have improved our understanding of MMN in the past 15 years, but the disease mechanisms underlying weakness in MMN are poorly understood.

Clinical features

MMN is characterised by slowly progressive weakness and muscle atrophy that develops gradually over several years.^{8,11,22,23,28–31} More men than women are affected, at a ratio of 2–6. The mean age at onset is 40 years, with a range of 20–70 years.^{9,22,32} In almost 80% of patients, the first symptoms occur between age 20 years and 50 years. The most common initial symptoms are wrist drop, grip weakness, and foot drop. Weakness develops asymmetrically and is more prominent in the arms than in the legs.^{22,23} In most patients with onset in the legs, the abnormalities also eventually affect the arms and

become the most prominent.³³ Symptoms and signs in the distal muscles prevail for a long time, but eventually weakness in proximal muscle groups of the arms, but not of the legs, may develop.^{32,33} Weakness is typically more pronounced than the degree of atrophy suggests.^{11,22} Nevertheless, atrophy of affected muscles can be substantial in patients with a long disease duration. Other motor symptoms include muscle cramps and fasciculations in about two-thirds of patients.^{3,19,21} Myokymia has been reported occasionally.^{3,19,21} Tendon reflexes are commonly reduced in affected regions, although these are rarely brisk in the arms.^{4,21,22,28,30} Single cases of cranial-nerve involvement have been reported.^{21,34–36} Respiratory failure due to unilateral or bilateral phrenic-nerve palsy can occur, even at the beginning of the disorder.^{35,37,38} Some patients report feelings of paraesthesia or numbness but sensory loss on objective neurological or neurophysiological assessment should not be found.

Differential diagnosis

The differential diagnosis of MMN includes two different categories of disorders: motor-neuron disease^{2,13,14,28,39–43} and demyelinating neuropathies.^{15–17} The first signs and symptoms in MMN can be similar to those in motor-neuron disease, and some patients are initially diagnosed as having amyotrophic lateral sclerosis or lower-motor-neuron disease.^{13,14} The slowly progressive disease course, the absence of upper-motor-neuron signs or bulbar signs and the presence of demyelinating features on electrodiagnostic assessment will eventually differentiate MMN from amyotrophic lateral sclerosis; differentiation of MMN from lower-motor-neuron disease is more difficult. We¹⁴ categorised lower-motor-neuron disease into four types of spinal muscular atrophy: slowly progressive general; distal; segmental distal; and segmental proximal. Clinically, MMN is difficult to differentiate from slowly progressive generalised spinal muscular atrophy or segmental distal spinal muscular atrophy.^{14,44} The finding of persistent motor-nerve conduction block on nerve-conduction studies outside nerve compression sites, a positive titre

of anti-GM1, or high signal intensity on T2-weighted MRI of the brachial plexus can help to differentiate MMN from lower-motor-neuron disease.⁴⁵

Within the demyelinating neuropathies, the disorders from which MMN must be differentiated are: chronic inflammatory demyelinating polyneuropathy (CIDP), particularly the pure motor form, and the Lewis-Sumner syndrome.^{16,17,46–53} In patients with CIDP, proximal symmetrical weakness and general areflexia are common, whereas weakness in MMN is asymmetrical and distal, and reflexes are only poor or absent in affected limbs. A remitting and relapsing course or a progression of symptoms in weeks is common in CIDP but not in MMN. The CSF protein concentration in MMN is normal or slightly increased but rarely higher than 1 g/L, unlike in CIDP, and can therefore help to differentiate between the two.^{11,23,45} Sensory signs and symptoms also differ for MMN and CIDP. On nerve-conduction studies, motor conduction block is found in both disorders, but other features of demyelination are more prominent in CIDP, such as slowed conduction velocities and prolonged distal latencies.^{23,46} Another disease entity that has similarities with MMN (and CIDP) is the Lewis-Sumner syndrome (table 1).^{48–53} Patients with this syndrome have an asymmetrical sensory or sensorimotor demyelinating neuropathy that can be localised to one arm or leg for several years, sometimes associated with neuropathic pain or focal nerve tenderness. Nerve-conduction studies are necessary to diagnose the syndrome and can help to differentiate it from MMN because low action-potential amplitudes in distal sensory nerves are found in many patients with the Lewis-Sumner syndrome, but not in patients with MMN. Patients with the Lewis-Sumner syndrome can benefit from treatment with corticosteroids, whereas those with MMN do not, and can even deteriorate.^{21,34,54–57}

Diagnosis

Electrophysiological characteristics

Conduction block, the failure of a nerve impulse to propagate through a structurally intact axon, is the electrophysiological hallmark of MMN in motor conduction studies (figure 1).^{1,4,18–23,28,58} Conduction block in a sufficient number of axons can be detected as a lower amplitude or area of the compound muscle action potential (CMAP) on proximal stimulation of a nerve segment than on distal stimulation of that segment (proximal/distal decrement in CMAP; figure 1). As well as conduction block, two other mechanisms can lead to CMAP decrement.^{59,60} When axons within a nerve have different conduction times (known as temporal dispersion), the positive phase of fast-motor-unit action potentials coincides with the negative phase of slow-motor-unit action potentials, yielding increased duration of the proximal compared with the distal CMAP, phase cancellation, and CMAP decrement. Furthermore, polyphasia of the motor-unit action potentials that contribute to the CMAP (due to collateral sprouting) has been assumed to yield increased phase cancellation and, consequently, a greater CMAP decrement. Because the occurrence of temporal dispersion and polyphasic motor-unit action potentials can yield CMAP decrement and mimic conduction block in peripheral polyneuropathies and lower-motor-neuron disease,^{61,62} criteria to separate conduction block from the other mechanisms that can cause CMAP decrement are needed. A simulation study in rats, in which compound muscle-unit action potentials were reconstructed from motor-unit action potentials, showed that maximum temporal dispersion could result in a decrement of the CMAP area of up to 50%.⁵⁹ No simulation studies with human polyphasic motor-unit action potentials and realistic temporal dispersion have been done. Consequently, a decrease in the CMAP area of more than 50% is currently the best indication that conduction is blocked in one or more axons of a nerve. Evidence is lacking for various other criteria for conduction block, which are based on expert opinions that have been established by consensus.^{45,60,63–66}

Whether conduction block is always part of MMN is an important issue and depends on the criteria for conduction block and the number of nerves investigated. We reviewed studies in which patients with lower-motor-neuron syndromes were treated with intravenous immunoglobulin, to assess whether or not conduction block was present (table 2). In nerves with limited temporal dispersion (<30%), a criterion consisting of a CMAP (area or amplitude) decrement of at least 50% was fulfilled in none,⁶⁷ or in few patients who responded positively to intravenous immunoglobulin.²⁰ This number increased when conduction block criteria allowed more temporal dispersion, required less CMAP decrement, or a combination of both.^{20,45} The American Academy of Electrodiagnostic Medicine proposed research criteria

	MMN	Lower-motor-neuron disease	CIDP	Lewis-Sumner syndrome
Distribution	Asymmetrical	Asymmetrical	Symmetrical	Asymmetrical
Arms > legs	Yes	Yes	No	Yes
Prominent sensory symptoms	No	No	Yes	Yes
Reflex pattern	Decreased in affected regions	Decreased in affected regions	General areflexia	Decreased in affected regions
Disease course	Slowly progressive	Slowly progressive	Progressive or relapsing	Progressive or relapsing
Laboratory features				
CSF protein >1 g/L	No	No	Yes	Rare
Anti-GM1 antibodies	30–50% of patients	10% of patients	Rare	No
Abnormal MRI of brachial plexus	Asymmetrical*	No	Symmetrical	Asymmetrical*
Response to treatment				
Intravenous immunoglobulin	Yes	No	Yes	Yes
Corticosteroids	No†	No	Yes	Yes†

*Corresponding with neurological deficit; †deterioration can occur.⁵²

Table 1: Comparison of typical features of MMN, lower-motor-neuron disease, CIDP, and the Lewis-Sumner syndrome

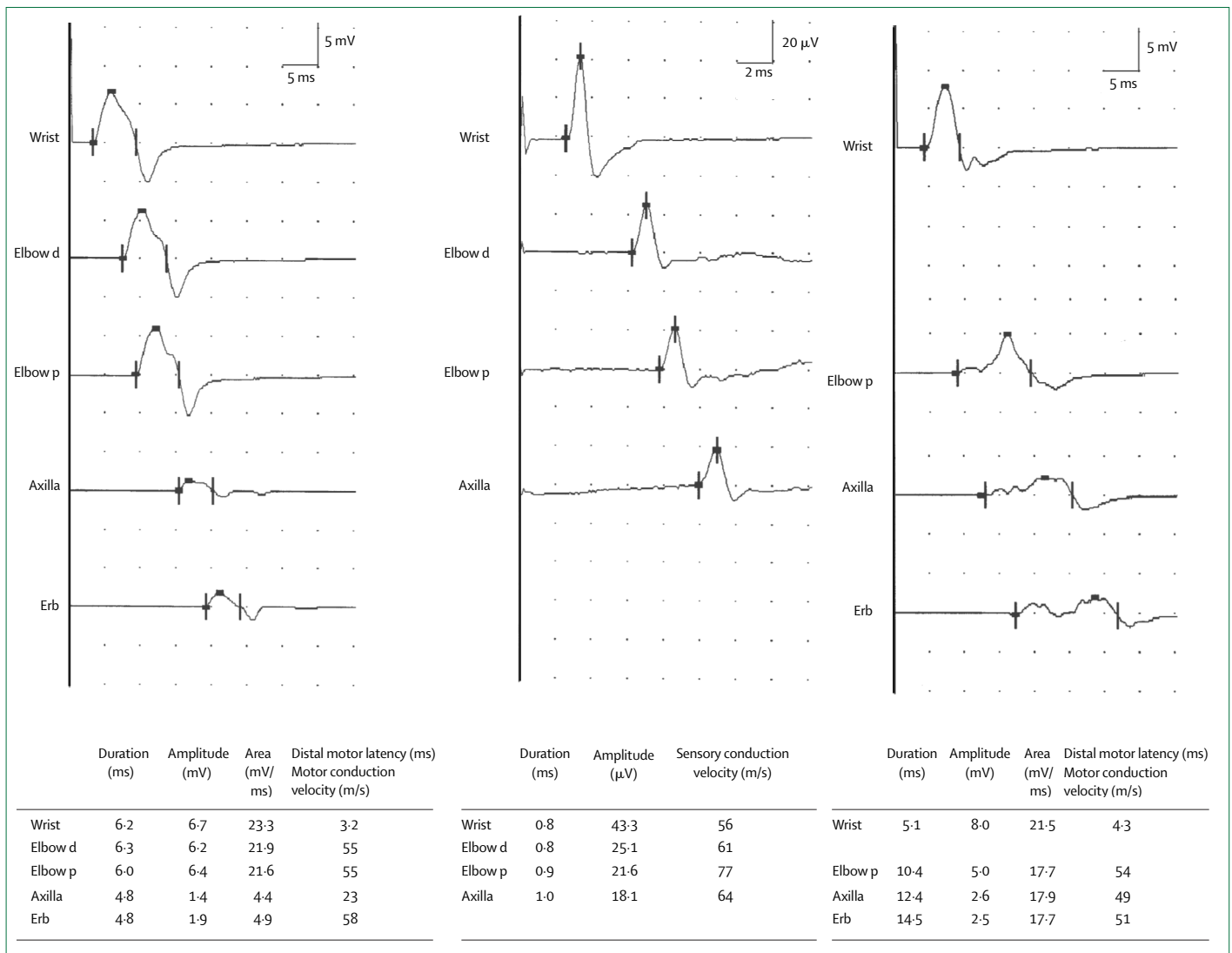


Figure 1: Conduction studies in patients with MMN

Motor conduction (left) and sensory conduction (middle) in the ulnar nerve, recorded from the fifth abductor digiti muscle. Definite conduction block (a decrease of more than 50% in the CMAP area) and motor conduction velocity compatible with demyelination were found in the upper arm segment. No abnormalities in sensory conduction were found. Motor conduction in the median nerve of a different patient (right) recorded from the left and middle abductor pollicis brevis muscle. Increased temporal dispersion (a prolongation of more than 30% in the CMAP duration) and probable conduction block (a decrease of more than 30% in the CMAP amplitude) were found in the lower arm segment and probable conduction block was found in the upper arm segment. Elbow d=stimulation 5 cm distally from elbow; elbow p=stimulation 5 cm proximally from elbow.²³

that specified the degree of temporal dispersion for nerves and for segments within nerves, and they found conduction block in 60–70% of patients with a favourable response to intravenous immunoglobulin.^{45,68} Criteria less stringent than those proposed by the American Academy of Electrodiagnostic Medicine, requiring a compound-muscle-action-potential area decrement of at least 50% in arm or leg nerves, or a compound-muscle-action-potential amplitude decrement of at least 30% in arm nerves, were fulfilled in all patients with a favourable response to intravenous immunoglobulin when a large number of arm and leg nerves, including those innervating non-weakened muscles, were studied bilaterally.^{23,45} For this

reason we prefer criteria for conduction block that require a CMAP area decrement of at least 50% or a CMAP amplitude decrement of at least 30%. These criteria were not fulfilled in all patients with a favourable response to intravenous immunoglobulin when a small number of arm and leg nerves were studied unilaterally.⁶⁹ In MMN, conduction block according to these criteria is most likely to be found in long arm nerves that innervate weakened muscles. If conduction block cannot be found in these nerves in patients with a lower-motor-neuron syndrome, electrophysiological assessment should be extended to other nerves, including long, intermediate, or short arm nerves innervating weakened or non-weakened muscles

Reference	Number of patients	Standard protocol		Conduction block criteria		Number of patients with conduction block	Positive response to treatment with intravenous immunoglobulin/total treated	
		Nerves investigated	Bilateral	CMAP decrement	Duration of prolongation		With conduction block	Without conduction block
20	16	Med, Uln, Per, Tib	Unknown	Amplitude and area >50%	<30% >30%	5 6	2/3 4/4	0/2
23	39*	Med, Uln, Rad, Mef, Mus, Per, Tib	Yes	Area >50%	..	30	30/30	..
42	10	Med, Uln, Per, Tib	No	Amplitude >30%	<30%	9	9/9	..
45	37	Med, Uln, Rad, Mef, Mus, Per, Tib	Yes	Amplitude and area >50%	<30%	0	..	4/10
67	5	Unknown	Unknown	Area >50%	..	21	17/21	0/4
68	23†	Med, Uln, Per, Tib	No	amplitude >30%	..	12	6/12	..
69	9‡	Med, Uln, Rad, Mus, Per, Tib	No	Amplitude >50%	<15%	0	..	3/4
				AAEM	AAEM	14	12/14	1/3
				AAEM -10%	AAEM	6	4/6	..
				Amplitude or area >30%	..	0	..	3/6

Med=median nerve recorded from abductor pollicis brevis; Uln=ulnar nerve recorded from fifth abductor digiti; Rad=radial nerve recorded from extensor carpi ulnaris; Mef=median nerve recorded from flexor carpi radialis; Mus=musculocutaneous nerve recorded from biceps brachii; Per=deep peroneal nerve recorded from extensor digitorum brevis; Tib=tibial nerve recorded from abductor hallucis. AAEM=criteria proposed by the American Academy of Electrodiagnostic Medicine; AAEM -10%=criteria that require 10% less decrement in amplitude on proximal versus distal stimulation or area for conduction block than those proposed by the AAEM. *Patients with a positive response to intravenous immunoglobulin were selected, 33 patients were previously reported in a study by Van den Berg-Vos 2001.⁴⁵ †Patients with conduction block or other features of demyelination on nerve conduction studies were selected; ‡patients were selected on the absence of conduction block.

Table 2: Presence of conduction block in patients with lower-motor-neuron syndromes who were treated with intravenous immunoglobulin

on both sides, until conduction block is found.²³ Because no favourable response to immune-modulating treatment has ever been reported for a patient with a lower-motor-neuron syndrome without conduction block, on extensive nerve-conduction studies we restrict treatment to patients with conduction block.

The detection of conduction block can be further improved by fatigability testing⁷⁰ or root stimulation,^{70,71} both of which show conduction block in nerves in which it is not found on conventional nerve-conduction studies in a restricted number of nerves. Motor conduction is typically slow in MMN, as it is in CIDP and sporadically in motor-neuron disease.^{23,46,72} Sensory-nerve-conduction studies are needed to exclude sensory abnormalities (at the site of conduction block) in MMN and can help to differentiate MMN from CIDP. Low distal CMAP amplitudes on nerve conduction studies, suggestive of axonal degeneration, as well as signs of denervation and re-innervation on needle electromyography, occur in MMN, lower-motor-neuron disease, and CIDP.^{46,73-75} Because of axonal degeneration in MMN, needle electromyography cannot differentiate between MMN and lower-motor-neuron disease. Nerve-conduction studies in patients with a lower-motor-neuron syndrome are therefore important.

Laboratory characteristics

Results of routine analysis of blood and urine are unremarkable in patients with MMN, despite slightly to moderately high serum creatine-kinase activity, consistent with slowly progressive axonal degeneration, in up to two-thirds of patients.^{45,76} In MMN, oligoclonal bands are not found in the CSF and the IgG index is normal.¹⁹ Immunofixation electrophoresis is typically normal in MMN; if a monoclonal spike is seen, the disease should be differentiated from polyneuropathy

associated with monoclonal gammopathy of unknown significance. Serum immunoglobulin concentrations are high in some patients, but they are polyclonal.^{4,12,21,28,40,45,77}

Initial reports of increased antibodies to GM1 ganglioside in patients with a lower-motor-neuron syndrome and conduction block in nerve-conduction studies raised hopes for a diagnostic marker for MMN.^{4,22,30,39,77-79} Positive findings for polyclonal anti-GM1 in about half of the patients with MMN (range 22–85%), as well as in patients with lower-motor-neuron disease, amyotrophic lateral sclerosis, and CIDP, and even in healthy people, suggested that the sensitivity and specificity of antibody testing are limited.^{24,77,80-85} However, in healthy people and patients with disorders other than MMN, the titres of anti-GM1 are typically much lower than in MMN. Several studies have shown that high titres of IgM anti-GM1 are found in patients with Guillain-Barré syndrome, MMN, or lower-motor-neuron disease.^{81,86-88} Furthermore, a positive IgM anti-GM1 test was associated with MMN within a group of patients with lower-motor-neuron syndrome.⁴⁵ Moreover, a meta-analysis on the diagnostic value of IgM anti-GM1 in MMN showed that probabilities before the test between 20% and 60% for having MMN on the basis of clinical characteristics changed to probabilities between 50% and 85% when IgM anti-GM1 was found.⁸⁹ Overall, these studies show that a positive test in a patient with a lower-motor-neuron syndrome is supportive but not conclusive of a diagnosis of MMN and should prompt extensive electrophysiological assessment, whereas a negative test has no diagnostic value.

Neuroimaging

In patients with MMN, signal intensity on T2-weighted images of the brachial plexus was asymmetrical and high, corresponding with the distribution of

symptoms.^{23,45,90} Asymmetrically high signal intensity was also shown on T1-weighted images after gadolinium enhancement, which colocalised with conduction block in the brachial plexus⁹¹ and in the forearm segment of the median nerve.⁹² The findings in MMN resemble the symmetrical high signal intensity seen in CIDP and might be due to demyelination.^{90,93} MRI might help to differentiate MMN from lower-motor-neuron disease; although MRI is normal in the latter, signal intensity is high in about 40–50% of patients with MMN.⁹⁰

Diagnostic criteria

Most diagnostic studies of MMN have focused on the diagnostic yield of criteria for conduction block, whereas there are few data on the additional diagnostic value of clinical and laboratory characteristics. We found that not only the presence of conduction block, but also the age at onset, number of affected limb regions, high signal intensity on T2-weighted images of the brachial plexus, and high titres of anti-GM1 predicted a positive response to intravenous immunoglobulin treatment in patients with lower-motor-neuron syndromes.⁴⁵ From these findings, we proposed a set of criteria, consisting of combined clinical, laboratory, and electrophysiological characteristics, for definite, probable, and possible MMN (panel).⁴⁵ In a group of patients with lower-motor-neuron syndromes and conduction block or conduction slowing compatible with demyelination on nerve-conduction studies, the likelihood of responding to intravenous immunoglobulin treatment was 81% for definite MMN, 71% for probable MMN, and 11% for possible MMN.⁴⁵ Because our criteria improved the identification of patients who might respond favourably to intravenous immunoglobulin, they were proposed for clinical practice but should be validated further.⁴⁵

Pathophysiology

Pathological, immunological, and electrophysiological studies have improved understanding of the typical pattern of weakness (asymmetrical, predominantly distal, more in arm than in leg muscles), the presence of weakness in atrophic and in non-atrophic muscles, the absence of sensory involvement, the partial reversibility of weakness after intravenous immunoglobulin treatment, the poor effect of treatment as the disease progresses, the slowly progressive course despite long-term treatment, and the presence of IgM anti-GM1 in some patients.

Biopsy

Reluctance to take biopsy samples from motor nerves has resulted in few pathological studies in MMN. In an ulnar-nerve biopsy at the site of previously documented conduction block, Auer and colleagues⁹⁴ reported onion-bulb formation, which is characteristic of several episodes of demyelination and remyelination, and axons that were thinly myelinated in relation to axon diameter. Furthermore, Kaji and colleagues⁹⁵ showed large-diameter

Panel: Proposed diagnostic criteria for MMN

Clinical criteria

1. Slow or stepwise progressive limb weakness
2. Asymmetrical limb weakness
3. Fewer than seven affected limb regions (upper arm, lower arm, upper leg, or lower leg on both sides of body; maximum eight)
4. Tendon reflexes in affected limbs are decreased or absent
5. Signs and symptoms are more pronounced in arms than in legs
6. Age 20–65 years at onset of disease
7. No objective sensory abnormalities except for vibration sense
8. No bulbar signs or symptoms
9. No upper-motor-neuron features
10. No other neuropathies (eg, diabetic, lead, porphyric, or vasculitic neuropathy, CIDP, Lyme neuroborreliosis, post-radiation neuropathy, hereditary neuropathy with liability to pressure palsies, Charcot-Marie-Tooth neuropathies, meningeal carcinomatosis)
11. No myopathy (eg, facioscapulohumeral muscular dystrophy, inclusion-body myositis)

Laboratory criteria

1. CSF protein <1 g/L
2. High anti-GM1 titre
3. High signal intensity on T2-weighted MRI of the brachial plexus

Electrodiagnostic criteria

1. Definite motor conduction block: CMAP area reduction on proximal versus distal stimulation of at least 50% over a long segment (between Erb and axilla, upper arm, lower arm, lower leg), or a CMAP amplitude reduction on proximal versus distal stimulation of at least 30% over a short distance (2.5 cm) detected by inching. CMAP amplitude on stimulation of the distal part of the segment with motor conduction block of at least 1 mV
2. Probable motor conduction block: CMAP amplitude reduction on proximal versus distal stimulation of at least 30% over a long segment of an arm nerve. CMAP amplitude on stimulation of the distal part of the segment with motor conduction block of at least 1 mV
3. Slowing of conduction compatible with demyelination: MCV <75% of the lower limit of normal; DML or shortest F wave latency >130% of the upper limit of normal or absence of F waves all after 16–20 stimuli. CMAP amplitude on distal stimulation of at least 0.5 mV
4. Normal sensory-nerve conduction in arm segments with motor conduction block. Normal SNAP amplitudes on distal stimulation.

Definite MMN

1–11 on clinical criteria, 1 on laboratory criteria, and 1 and 4 on electrodiagnostic criteria

Probable MMN

1–3 and 6–11 on clinical criteria, 1 on laboratory criteria, and 2 and 4 on electrodiagnostic criteria

Possible MMN

1 and 7–11 on clinical criteria, 2 or 3 on laboratory criteria, and 3 and 4 on electrodiagnostic criteria

CMAP=compound muscle action potential; MCV=motor conduction velocity; DML=distal motor latency; SNAP=sensory nerve action potential.⁴⁵

axons almost devoid of myelin in the median pectoral nerve with CMAP decrement on intraoperative recording. By contrast, Taylor and colleagues⁹⁵ showed that multifocal loss and degeneration of axons, as well as prominent clusters of regenerating axons, dominated over myelin pathology in biopsy samples of motor fascicular nerve with evidence of conduction block on intraoperative

recording in seven patients with MMN. Except for intermediate-sized fibres with thin myelin—which could have represented previous remyelination—paranodal demyelination, internodal demyelination, and onion-bulb formation were not found.⁹⁵ Although these findings suggest that axonal pathology is more prominent than demyelinating pathology in MMN, they do not explain the finding of conduction block on nerve-conduction studies and the rapid response to intravenous immunoglobulin in patients with MMN. The finding that, unlike CIDP, inflammatory cellular infiltrates are sporadic in MMN implies that the two disorders are unlikely to share underlying disease mechanisms.^{92,94–96} The findings in biopsied sural nerves from patients with MMN were either normal or showed mild axonal degeneration, mild demyelination, or both, which is consistent with the infrequent sensory impairment in patients with MMN.^{11,97}

Immunopathology

The positive response to immunomodulating treatment, the finding of anti-GM1 in 20–80% of patients with MMN,^{4,12,21,28,40,45,77} and the expression of GM1 on axon and myelin membranes^{77,98–101} suggest that anti-GM1 are pathogenetic in MMN. In this context, differences in the fatty-acid and long-chain-base composition of peripheral-nerve ganglioside GM1 between sensory and motor nerves, resulting in different affinities of anti-GM1, could contribute to selective involvement of motor fibres.^{102–104} Antibody-mediated demyelination or blocking of the voltage-gated sodium channels at the node of Ranvier was supported by the results of some *in vivo* and *in vitro* animal experiments^{105–108} but not in others.^{109–112} Furthermore, anti-GM1 binding sites and voltage gated sodium channels were not colocalised.¹¹³ Moreover, human IgM anti-GM1 modulate intracellular calcium homeostasis in neuroblastoma cells, probably owing to activation of L-type voltage-gated calcium channels that are also present in motor neurons.¹¹⁴ Overall, these experiments have not confirmed or excluded the pathogenicity of IgM GM1 antibodies in MMN. The finding that distal motor-nerve conduction in mice was blocked by serum samples from patients with or without high GM1 antibody titres suggests that factors other than GM1 antibodies may be pathogenetic in MMN.¹¹⁵

Electrophysiology

Conduction block, the electrophysiological hallmark of MMN, was thought to underlie weakness in MMN. Most nerve-conduction studies of patients with MMN found improvement in conduction block after initial and long-term treatment with intravenous immunoglobulin.^{18,19,25,27,34,55,75,116–118} The inability of nerve-conduction studies to assess proximal nerve segments might explain the lack of improvement in conduction block in some patients. Conduction block might cause weakness that could, at least partly, be reversed by intravenous immunoglobulin. In 39 patients with

MMN, long nerves had more segments with conduction block owing to a random distribution of block in arm nerves.²³ Furthermore, distal CMAPs were commonly low in long nerves. Together, these findings suggest length-dependent axonal degeneration due to the high occurrence of conduction block in these nerves.²³

Electrophysiological studies in patients with MMN who were treated with intravenous immunoglobulin raised important questions about the causes of weakness in MMN. Although muscle strength in patients with MMN improves after intravenous immunoglobulin treatment, it rarely recovers to normal.^{24–27,33,47,55,75,76,119,120} Irreversible weakness may be caused by irreversible conduction block or axonal degeneration. Many observations suggest that axonal degeneration contributes to weakness in patients with MMN. Atrophic muscles, low distal CMAP amplitudes on nerve-conduction studies, and findings of denervation and re-innervation on needle electromyography are all found in patients with MMN, even in those with a short disease duration.^{11,22,23,33,75} In a study of patients with MMN who had never received intravenous immunoglobulin treatment, a longer disease duration was not only associated with more segments with conduction block, but also with more nerves with low distal CMAP amplitudes, the latter being consistent with progressive axonal degeneration.³² Weakness due to progressive axonal degeneration was suggested to underlie the less pronounced response to initial (or long-term) intravenous immunoglobulin treatment for patients with a long disease duration.⁶⁸ Three long-term follow-up studies of patients on intravenous immunoglobulin maintenance treatment showed a mild decrease in muscle strength as well as continuing axonal degeneration, measured by distal CMAP amplitude.^{33,121,122} However, in a study that used a high monthly maintenance dose of intravenous immunoglobulin the results were contrasting: weakness was not progressive, and distal CMAP amplitude did not suggest continuing axonal degeneration.⁷⁵

To assess the independent contributions of conduction block and axon loss to chronic progressive weakness, we⁷³ did a multivariate analysis of 20 patients with MMN who were receiving long-term intravenous immunoglobulin treatment. Axon loss, and not conduction block, had the strongest relation to weakness, whereas conduction block alone had the strongest relation to axon loss.⁷³ These findings suggest that intravenous immunoglobulin treatment affects reversible conduction block but when conduction block is irreversible the affected axons eventually degenerate despite continuous intravenous immunoglobulin treatment.

Generally, conduction block occurs when the action current at one node does not induce a sufficiently large depolarisation at the next node to generate an action potential, either because the current available is low or because high current is needed.¹²³ The finding that

conduction block and demyelination were independently related to each other in the arm nerves of patients with MMN, and the finding of demyelination at the site of conduction block on most biopsy studies, suggests that conduction block results from a primary demyelinating process.⁷³ In animal experiments, paranodal demyelination impaired saltatory conduction; the current available for depolarisation was low because the outward capacitive sodium current, which leads to depolarisation of the node to be activated, was dissipated over the node and the adjacent damaged paranodal region.^{124,125} The period to depolarise the node to threshold for an action potential will be longer when moderate amounts of current are lost, yielding conduction slowing. With severe loss of current, there will be insufficient current to attain the threshold for an action potential, yielding conduction block.¹²³ The loss of current may be aggravated when demyelination exposes paranodal or internodal potassium channels. Motor axons in arm nerves have a more prominent slow potassium conductance than motor axons in leg nerves.¹²⁶ These differences in conductances could contribute to the greater tendency of motor axons in arm nerves to develop conduction block.^{23,126,127}

The mechanism that underlies axon loss in MMN is poorly understood. A common disease mechanism that leads to conduction block in some axons and degeneration of other axons could explain the independent relation between axon loss and conduction block. A common disease mechanism is supported by pathological studies showing that the antibodies to the ganglioside GM1 bind to epitopes of the nodal axolemma and paranodal myelin, possibly leading to conduction block and axon loss, and to epitopes of spinal-cord motor neurons, possibly leading to axon loss.^{45,105,113,123} Alternatively, the association between axon loss and conduction block might suggest that an axon will eventually degenerate if a process resulting in conduction block affects it. This mechanism is supported by excitability measurements that showed axonal hyperpolarisation adjacent to sites with conduction block. Hyperpolarisation was thought to be secondary to intra-axonal sodium accumulation at the site with conduction block, caused by low activity of the sodium/potassium pump.^{128,129} An animal study of inflammatory demyelination showed that sodium accumulation leads to intra-axonal calcium accumulation due to passive reversal of the sodium/calcium exchanger.¹³⁰ An animal study of inflammatory demyelination supported this mechanism, showing that blockade of sodium channels or sodium/calcium exchanger prevented axonal degeneration.¹³¹

Treatment

The hypothesis that MMN is an immune-mediated neuropathy has led to trials of several immunological treatments. By contrast with CIDP, prednisolone and

plasma exchange were ineffective in most patients and were even associated with clinical worsening in some patients with MMN.^{4,21,28,30,34,36,39,54–58,76,116,120,132–137} Of the immunosuppressants, only high-dose cyclophosphamide seems to be effective.^{4,30,54,76} Unfortunately, the substantial side-effects of cyclophosphamide, especially the risk of neoplasia, restrict its use in patients with MMN.

Many open studies have shown that intravenous immunoglobulin has a beneficial effect.^{19–21,31,34,44,55,56,58,67,75,76,90,116,117,138–140} The efficacy of this treatment in MMN was confirmed in four double-blind placebo-controlled trials.^{24–27} The treatment was effective within a week, but because the effect lasted only a few weeks, maintenance treatment was needed to maintain the effect on muscle strength in most patients.^{19,33,117,120,122} Side-effects were minor; the most disabling were skin changes (eczema) on the hands and trunk.^{141,142}

Maintenance of intravenous immunoglobulin treatment is expensive, and many patients find the frequent infusions onerous, but no alternative treatment is available. Therefore, long-term studies are important. We assessed the effects over 4–8 years in 11 patients with MMN.³³ Muscle strength improved substantially within 3 weeks of the start of treatment, and at the last follow-up assessment muscle strength was better than before treatment, even though it decreased slightly during the follow-up period (figure 2). The treatment did not induce remission in any of our patients; when it was stopped, weakness progressed substantially. A study of ten patients on maintenance treatment with intravenous immunoglobulin over 5–12 years showed that the effectiveness tended to decrease when treatment was continued over a long period, even when the dose was increased.¹²² During the first few years of maintenance treatment, the response could be restored by increasing the dose, whereas later an increase in dose was only partially effective. However, in another study, a high monthly maintenance dose of immunoglobulin was shown to improve muscle strength and functional disability during long-term follow-up.⁷⁵ Study of the efficacy of various long-term doses with a double-blind design is needed.

Natural course

Because most patients with MMN respond to intravenous immunoglobulin treatment, a prospective study on the natural course of MMN without any treatment is not feasible. Two retrospective studies on the natural course of MMN have been published; both reported a slowly progressive course.^{22,32} Step-wise^{31,55} and spontaneously remitting^{2,19} disease courses have also been described but are less common than the slow progressive course. In a study of 38 patients with MMN, we³² showed that disease duration and disease severity are related. Patients who responded to initial intravenous immunoglobulin treatment had a disease duration of up to 24 years and could have severe weakness. Lack of

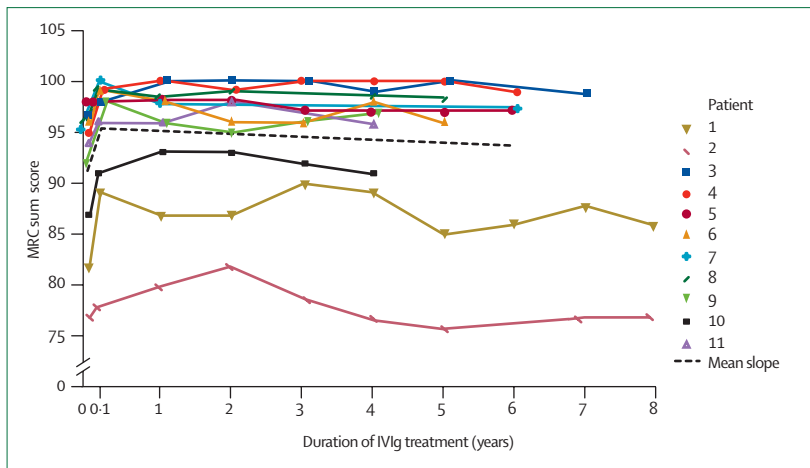


Figure 2: Muscle strength of 11 patients with MMN during maintenance with intravenous immunoglobulin treatment

Sum score of muscle strength was measured according to the Medical Research Council (MRC) criteria in five muscle groups in both arms and in five muscle groups in both legs, yielding a maximum score of 100. 0=before the start of intravenous immunoglobulin treatment; 0-1=after the first full course of intravenous immunoglobulin; 1-8=during and after follow-up.³³

response to intravenous immunoglobulin was not associated with arm or leg involvement, muscle strength, disability, or electrophysiological variables. Nobile-Orazio and colleagues⁶⁸ showed that the response to initial intravenous immunoglobulin treatment was less pronounced for patients with a longer disease duration. A continuing immunological process might cause progression of weakness in MMN, and early treatment could prevent future progression of weakness and disability in patients with MMN. Although the overall prognosis of patients with MMN seems to be better than that of patients with lower-motor-neuron disease, most patients with MMN have poor dexterity in manual tasks that are a part of daily life.^{22,32} Some patients are disabled

Search strategy and selection criteria

References for this review were identified from searches of MEDLINE between 1985 and October 2004 and from references in relevant articles; many articles were also identified through searches of the extensive files of the authors. The search terms "MMN", "multifocal motor neuropathy", "conduction block", "anti GM1 antibodies", "MRI brachial plexus", "lower motor neuron syndrome", "motor neuron disease", "chronic inflammatory demyelinating polyneuropathy", "Lewis Sumner syndrome", "demyelination", "axonal degeneration", "nerve conduction studies", "needle electromyography", "threshold tracking", "intravenous immunoglobulin", "immune modulating treatment", "diagnosis", "prognosis", "etiology", and "therapy" were used. Only papers and abstracts published in English were reviewed, and papers that were original and relevant to the review topic were selected.

by fatigue;⁷⁰ in our opinion this symptom has been underestimated in patients with MMN and needs further study. Death after several years with the disease has been reported in only two patients,^{35,143} whereas in others, death was related to concomitant diseases.^{38,40}

Conclusion

In the two decades since MMN was first reported, clinical and electrophysiological studies have led to advances in its diagnosis and treatment. The clinical presentation of MMN mimics that of lower-motor-neuron disease, whereas conduction block on motor-conduction studies differentiates between the two. The finding that conduction block presents in patients with MMN suggests that nerve conduction should be extensively studied in every patient with a lower-motor-neuron syndrome until conduction block is found to identify patients who might respond favourably to immunomodulating treatment. In MMN, but not in lower-motor-neuron disease, high doses of intravenous immunoglobulin produce rapid but unsustainable improvement in most patients. Although expensive, repeated intravenous immunoglobulin treatment is effective in maintaining remission and slowing progression of weakness, according to the results of most studies. Despite pathological and immunological studies, the pathogenesis of MMN and the mechanism by which immunoglobulin is effective are poorly understood. Most evidence suggests that conduction block results from a primary demyelinating process and that axonal degeneration in MMN is related to it. Most likely, intravenous immunoglobulin treatment affects reversible conduction block whereas axonal degeneration continues despite intravenous immunoglobulin treatment. Future research on pathogenetic mechanisms is needed so that novel treatment strategies for MMN can be developed.

Authors' contributions

J-THVA, JHJW, and LVdB planned the review. J-THVA, RMVdB-V, and LVdB researched relevant research papers. All authors contributed to the writing of the review.

Conflicts of interest

LVdB has received research grants and honoraria for lecturing from companies that produce intravenous gammaglobulins, including Baxter, Laboratoire Francais du fractionnement et des biotechnologies, ZLB Bioplasma Belgium, and Sanguin.

Role of the funding source

A grant from the Prinses Beatrix Fonds supported this review.

References

- 1 Parry GJ, Clarke S. Pure motor neuropathy with multifocal conduction block masquerading as motor neuron disease. *Muscle Nerve* 1985; **8**: 167.
- 2 Chad DA, Hammer K, Sargent J. Slow resolution of multifocal weakness and fasciculation: a reversible motor neuron syndrome. *Neurology* 1986; **36**: 1260-63.
- 3 Roth G, Rohr J, Magistris MR, Ochsner F. Motor neuropathy with proximal multifocal persistent conduction block, fasciculations and myokymia: evolution to tetraplegia. *Eur Neurol* 1986; **25**: 416-23.
- 4 Pestronk A, Cornblath DR, Ilyas AA, et al. A treatable multifocal motor neuropathy with antibodies to GM1 ganglioside. *Ann Neurol* 1988; **24**: 73-78.

- 5 Lange DJ, Trojaborg W, Latov N, et al. Multifocal motor neuropathy with conduction block: is it a distinct clinical entity? *Neurology* 1992; **42**: 497–505.
- 6 Parry GJ, Sumner AJ. Multifocal motor neuropathy. *Neurol Clin* 1992; **10**: 671–84.
- 7 Nobile-Orazio E. Multifocal motor neuropathy. *J Neurol Neurosurg Psychiatry* 1996; **60**: 599–603.
- 8 Biessels GJ, Franssen H, Van den Berg LH, et al. Multifocal motor neuropathy. *J Neurol* 1997; **244**: 143–52.
- 9 Chaudhry V. Multifocal motor neuropathy. *Semin Neurol* 1998; **18**: 73–81.
- 10 Pestronk A. Multifocal motor neuropathy: diagnosis and treatment. *Neurology* 1998; **51**: S22–24.
- 11 Nobile-Orazio E. Multifocal motor neuropathy. *J Neuroimmunol* 2001; **115**: 4–18.
- 12 Freddo L, Yu RK, Latov N, et al. Gangliosides GM1 and GD1b are antigens for IgM M-protein in a patient with motor neuron disease. *Neurology* 1986; **36**: 454–58.
- 13 Traynor BJ, Codd MB, Corr B, Forde C, Frost E, Hardiman O. Amyotrophic lateral sclerosis mimic syndromes: a population-based study. *Arch Neurol* 2000; **57**: 109–13.
- 14 Van den Berg-Vos RM, Van den Berg LH, Visser J, de Visser M, Franssen H, Wokke JH. The spectrum of lower motor neuron syndromes. *J Neurol* 2003; **250**: 1279–92.
- 15 Hughes RA. The spectrum of acquired demyelinating polyradiculoneuropathy. *Acta Neurol Belg* 1994; **94**: 128–32.
- 16 Saperstein DS, Katz JS, Amato AA, Barohn RJ. Clinical spectrum of chronic acquired demyelinating polyneuropathies. *Muscle Nerve* 2001; **24**: 311–24.
- 17 Leger JM. Multifocal motor neuropathy and chronic inflammatory demyelinating polyradiculoneuropathy. *Curr Opin Neurol* 1995; **8**: 359–63.
- 18 Chaudhry V, Corse AM, Cornblath DR, Kuncl RW, Freimer ML, Griffin JW. Multifocal motor neuropathy: electrodiagnostic features. *Muscle Nerve* 1994; **17**: 198–205.
- 19 Bouche P, Moulouguet A, Younes-Chennoufi AB, et al. Multifocal motor neuropathy with conduction block: a study of 24 patients. *J Neurol Neurosurg Psychiatry* 1995; **59**: 38–44.
- 20 Katz JS, Wolfe GI, Bryan WW, Jackson CE, Amato AA, Barohn RJ. Electrophysiologic findings in multifocal motor neuropathy. *Neurology* 1997; **48**: 700–07.
- 21 Le Forestier N, Chassande B, Moulouguet A, et al. Multifocal motor neuropathies with conduction blocks: 39 cases. *Rev Neurol (Paris)* 1997; **153**: 579–86.
- 22 Taylor BV, Wright RA, Harper CM, Dyck PJ. Natural history of 46 patients with multifocal motor neuropathy with conduction block. *Muscle Nerve* 2000; **23**: 900–08.
- 23 Van Asseldonk JTH, Van den Berg LH, Van den Berg-Vos RM, Wieneke GH, Wokke JH, Franssen H. Demyelination and axonal loss in multifocal motor neuropathy: distribution and relation to weakness. *Brain* 2003; **126**: 186–98.
- 24 Azulay JP, Blin O, Pouget J, et al. Intravenous immunoglobulin treatment in patients with motor neuron syndromes associated with anti-GM1 antibodies: a double-blind, placebo-controlled study. *Neurology* 1994; **44**: 429–32.
- 25 Van den Berg LH, Kerkhoff H, Oey PL, et al. Treatment of multifocal motor neuropathy with high dose intravenous immunoglobulins: a double blind, placebo controlled study. *J Neurol Neurosurg Psychiatry* 1995; **59**: 248–52.
- 26 Federico P, Zochodne DW, Hahn AF, Brown WF, Feasby TE. Multifocal motor neuropathy improved by IVIg: randomised, double-blind, placebo-controlled study. *Neurology* 2000; **55**: 1256–62.
- 27 Leger JM, Chassande B, Musset L, Meininger V, Bouche P, Baumann N. Intravenous immunoglobulin therapy in multifocal motor neuropathy: a double-blind, placebo-controlled study. *Brain* 2001; **124**: 145–53.
- 28 Parry GJ, Clarke S. Multifocal acquired demyelinating neuropathy masquerading as motor neuron disease. *Muscle Nerve* 1988; **11**: 103–07.
- 29 Pestronk A, Adams RN, Kuncl RW, Drachman DB, Clawson LL, Cornblath DR. Differential effects of prednisone and cyclophosphamide on autoantibodies in human neuromuscular disorders. *Neurology* 1989; **39**: 628–33.
- 30 Krarup C, Stewart JD, Sumner AJ, Pestronk A, Lipton SA. A syndrome of asymmetric limb weakness with motor conduction block. *Neurology* 1990; **40**: 118–27.
- 31 O'Leary CP, Mann AC, Lough J, Willison HJ. Muscle hypertrophy in multifocal motor neuropathy is associated with continuous motor unit activity. *Muscle Nerve* 1997; **20**: 479–85.
- 32 Van den Berg-Vos RM, Franssen H, Visser J, et al. Disease severity in multifocal motor neuropathy and its association with the response to immunoglobulin treatment. *J Neurol* 2002; **249**: 330–36.
- 33 Van den Berg-Vos RM, Franssen H, Wokke JH, Van den Berg LH. Multifocal motor neuropathy: long-term clinical and electrophysiological assessment of intravenous immunoglobulin maintenance treatment. *Brain* 2002; **125**: 1875–86.
- 34 Kaji R, Shibasaki H, Kimura J. Multifocal demyelinating motor neuropathy: cranial nerve involvement and immunoglobulin therapy. *Neurology* 1992; **42**: 506–09.
- 35 Magistris M, Roth G. Motor neuropathy with multifocal persistent conduction blocks. *Muscle Nerve* 1992; **15**: 1056–57.
- 36 Pringle CE, Belden J, Veitch JE, Brown WF. Multifocal motor neuropathy presenting as ophthalmoplegia. *Muscle Nerve* 1997; **20**: 347–51.
- 37 Cavaletti G, Zincone A, Marzorati L, Frattola L, Molteni F, Navalesi P. Rapidly progressive multifocal motor neuropathy with phrenic nerve paralysis: effect of nocturnal assisted ventilation. *J Neurol* 1998; **245**: 613–16.
- 38 Beydoun SR, Copeland D. Bilateral phrenic neuropathy as a presenting feature of multifocal motor neuropathy with conduction block. *Muscle Nerve* 2000; **23**: 556–59.
- 39 Pestronk A, Chaudhry V, Feldman EL, et al. Lower motor neuron syndromes defined by patterns of weakness, nerve conduction abnormalities, and high titers of antiglycolipid antibodies. *Ann Neurol* 1990; **27**: 316–26.
- 40 Bentes C, de Carvalho M, Evangelista T, Sales-Luis ML. Multifocal motor neuropathy mimicking motor neuron disease: nine cases. *J Neurol Sci* 1999; **169**: 76–79.
- 41 Donaghy M. Classification and clinical features of motor neuron diseases and motor neuropathies in adults. *J Neurol* 1999; **246**: 331–33.
- 42 Ellis CM, Leary S, Payan J, et al. Use of human intravenous immunoglobulin in lower motor neuron syndromes. *J Neurol Neurosurg Psychiatry* 1999; **67**: 15–19.
- 43 Molinuevo JL, Cruz-Martinez A, Graus F, Serra J, Ribalta T, Valls-Sole J. Central motor conduction time in patients with multifocal motor conduction block. *Muscle Nerve* 1999; **22**: 926–32.
- 44 Vucic S, Dawson K, Sun D, Cros D. Pure motor mononeuropathy with distal conduction block: an unusual presentation of multifocal motor neuropathy with conduction blocks. *Clin Neurophysiol* 2004; **115**: 2323–28.
- 45 Van den Berg-Vos RM, Franssen H, Wokke JH, Van Es HW, Van den Berg LH. Multifocal motor neuropathy: diagnostic criteria that predict the response to immunoglobulin treatment. *Ann Neurol* 2000; **48**: 919–26.
- 46 Barohn RJ, Kissel JT, Warmolts JR, Mendell JR. Chronic inflammatory demyelinating polyradiculoneuropathy: clinical characteristics, course, and recommendations for diagnostic criteria. *Arch Neurol* 1989; **46**: 878–84.
- 47 Kornberg AJ, Pestronk A. Chronic motor neuropathies: diagnosis, therapy, and pathogenesis. *Ann Neurol* 1995; **37** (suppl 1): S43–50.
- 48 Oh SJ, Claussen GC, Kim DS. Motor and sensory demyelinating mononeuropathy multiplex (multifocal motor and sensory demyelinating neuropathy): a separate entity or a variant of chronic inflammatory demyelinating polyneuropathy? *J Peripher Nerv Syst* 1997; **2**: 362–69.
- 49 Lewis RA. Multifocal motor neuropathy and Lewis Sumner syndrome: two distinct entities. *Muscle Nerve* 1999; **22**: 1738–39.
- 50 Mezaki T, Kaji R, Kimura J. Multifocal motor neuropathy and Lewis Sumner syndrome: a clinical spectrum. *Muscle Nerve* 1999; **22**: 1739–40.
- 51 Saperstein DS, Amato AA, Wolfe GI, et al. Multifocal acquired demyelinating sensory and motor neuropathy: the Lewis-Sumner syndrome. *Muscle Nerve* 1999; **22**: 560–66.
- 52 Van den Berg-Vos RM, Van den Berg LH, Franssen H, et al. Multifocal inflammatory demyelinating neuropathy: a distinct clinical entity? *Neurology* 2000; **54**: 26–32.

- 53 Katz JS, Saperstein DS. Asymmetric acquired demyelinating polyneuropathies: MMN and MADSAM. *Curr Treat Options Neurol* 2001; 3: 119–125.
- 54 Feldman EL, Bromberg MB, Albers JW, Pestronk A. Immunosuppressive treatment in multifocal motor neuropathy. *Ann Neurol* 1991; 30: 397–401.
- 55 Nobile-Orazio E, Meucci N, Barbieri S, Carpo M, Scarlato G. High-dose intravenous immunoglobulin therapy in multifocal motor neuropathy. *Neurology* 1993; 43: 537–44.
- 56 Donaghy M, Mills KR, Boniface SJ et al. Pure motor demyelinating neuropathy: deterioration after steroid treatment and improvement with intravenous immunoglobulin. *J Neurol Neurosurg Psychiatry* 1994; 57: 778–83.
- 57 Van den Berg LH, Lokhorst H, Wokke JH. Pulsed high-dose dexamethasone is not effective in patients with multifocal motor neuropathy. *Neurology* 1997; 48: 1135.
- 58 Jaspert A, Claus D, Grehl H, Neundorfer B. Multifocal motor neuropathy: clinical and electrophysiological findings. *J Neurol* 1996; 243: 684–92.
- 59 Rhee EK, England JD, Sumner AJ. A computer simulation of conduction block: effects produced by actual block versus interphase cancellation. *Ann Neurol* 1990; 28: 146–56.
- 60 Oh SJ, Kim DE, Kuruoglu HR. What is the best diagnostic index of conduction block and temporal dispersion? *Muscle Nerve* 1994; 17: 489–93.
- 61 Sumner AJ. Separating motor neuron diseases from pure motor neuropathies. Multifocal motor neuropathy with persistent conduction block. *Adv Neurol* 1991; 56: 399–403.
- 62 Lange DJ, Trojaborg W, McDonald TD, Blake DM. Persistent and transient “conduction block” in motor neuron diseases. *Muscle Nerve* 1993; 16: 896–903.
- 63 Albers JW, Donofrio PD, McGonagle TK. Sequential electrodiagnostic abnormalities in acute inflammatory demyelinating polyradiculoneuropathy. *Muscle Nerve* 1985; 8: 528–39.
- 64 Feasby TE, Brown WF, Gilbert JJ, Hahn AF. The pathological basis of conduction block in human neuropathies. *J Neurol Neurosurg Psychiatry* 1985; 48: 239–44.
- 65 Cappellari A, Nobile-Orazio E, Meucci N, Levi MG, Scarlato G, Barbieri S. Criteria for early detection of conduction block in multifocal motor neuropathy (MMN): a study based on control populations and follow-up of MMN patients. *J Neurol* 1997; 244: 625–30.
- 66 Olney RK, Lewis RA, Putnam TD, Campellone JV, Jr. Consensus criteria for the diagnosis of multifocal motor neuropathy. *Muscle Nerve* 2003; 27: 117–21.
- 67 Pakiam AS, Parry GJ. Multifocal motor neuropathy without overt conduction block. *Muscle Nerve* 1998; 21: 243–45.
- 68 Nobile-Orazio E, Cappellari A, Meucci N, et al. Multifocal motor neuropathy: clinical and immunological features and response to IVIg in relation to the presence and degree of motor conduction block. *J Neurol Neurosurg Psychiatry* 2002; 72: 761–66.
- 69 Katz JS, Barohn RJ, Kojan S, et al. Axonal multifocal motor neuropathy without conduction block or other features of demyelination. *Neurology* 2002; 58: 615–20.
- 70 Kaji R, Bostock H, Kohara N, Murase N, Kimura J, Shibusaki H. Activity-dependent conduction block in multifocal motor neuropathy. *Brain* 2000; 123: 1602–11.
- 71 Menkes DL, Hood DC, Ballesteros RA, Williams DA. Root stimulation improves the detection of acquired demyelinating polyneuropathies. *Muscle Nerve* 1998; 21: 298–308.
- 72 Cornblath DR, Kuncl RW, Mellits ED, et al. Nerve conduction studies in amyotrophic lateral sclerosis. *Muscle Nerve* 1992; 15: 1111–15.
- 73 Van Asseldonk JTH, Van den Berg LH, Kalmijn S, Wokke JHJ, Franssen H. Axon loss is a prominent determinant of weakness in multifocal motor neuropathy. *Muscle Nerve* 2003; 12: S150–51.
- 74 Van den Berg-Vos RM, Visser J, Franssen H, et al. Sporadic lower motor neuron disease with adult onset: classification of subtypes. *Brain* 2003; 126: 1036–47.
- 75 Vucic S, Black KR, Chong PS, Cros D. Multifocal motor neuropathy: decrease in conduction blocks and reinnervation with long-term IVIg. *Neurology* 2004; 63: 1264–69.
- 76 Chaudhry V, Corse AM, Cornblath DR, et al. Multifocal motor neuropathy: response to human immune globulin. *Ann Neurol* 1993; 33: 237–42.
- 77 Latov N, Hays AP, Donofrio PD, et al. Monoclonal IgM with unique specificity to gangliosides GM1 and GD1b and to lacto-N-tetraose associated with human motor neuron disease. *Neurology* 1988; 38: 763–68.
- 78 Pestronk A. Invited review: motor neuropathies, motor neuron disorders, and antiglycolipid antibodies. *Muscle Nerve* 1991; 14: 927–36.
- 79 Willison HJ, Paterson G, Kennedy PG, Veitch J. Cloning of human anti-GM1 antibodies from motor neuropathy patients. *Ann Neurol* 1994; 35: 471–78.
- 80 Nobile-Orazio E, Legname G, Daverio R, et al. Motor neuron disease in a patient with a monoclonal IgM directed against GM1, GD1b, and high-molecular-weight neural-specific glycoproteins. *Ann Neurol* 1990; 28: 190–94.
- 81 Sadiq SA, Thomas FP, Kilidireas K, et al. The spectrum of neurologic disease associated with anti-GM1 antibodies. *Neurology* 1990; 40: 1067–72.
- 82 Shy ME, Heiman-Patterson T, Parry GJ, Tahmouh A, Evans VA, Schick PK. Lower motor neuron disease in a patient with autoantibodies against Gal(beta 1-3)GalNAc in gangliosides GM1 and GD1b: improvement following immunotherapy. *Neurology* 1990; 40: 842–44.
- 83 Lamb NL, Patten BM. Clinical correlations of anti-GM1 antibodies in amyotrophic lateral sclerosis and neuropathies. *Muscle Nerve* 1991; 14: 1021–27.
- 84 Kinsella LJ, Lange DJ, Trojaborg W, Sadiq SA, Younger DS, Latov N. Clinical and electrophysiologic correlates of elevated anti-GM1 antibody titers. *Neurology* 1994; 44: 1278–82.
- 85 Kornberg AJ, Pestronk A. The clinical and diagnostic role of anti-GM1 antibody testing. *Muscle Nerve* 1994; 17: 100–04.
- 86 Taylor BV, Gross L, Windebank AJ. The sensitivity and specificity of anti-GM1 antibody testing. *Neurology* 1996; 47: 951–55.
- 87 Van den Berg LH, Marrink J, de Jager AE, et al. Anti-GM1 antibodies in patients with Guillain-Barre syndrome. *J Neurol Neurosurg Psychiatry* 1992; 55: 8–11.
- 88 Van den Berg LH, Franssen H, Van Doorn PA, Wokke JH. Intravenous immunoglobulin treatment in lower motor neuron disease associated with highly raised anti-GM1 antibodies. *J Neurol Neurosurg Psychiatry* 1997; 63: 674–77.
- 89 Van Schaik IN, Bossuyt PM, Brand A, Vermeulen M. Diagnostic value of GM1 antibodies in motor neuron disorders and neuropathies: a meta-analysis. *Neurology* 1995; 45: 1570–77.
- 90 Van Es HW, Van den Berg LH, Franssen H, et al. Magnetic resonance imaging of the brachial plexus in patients with multifocal motor neuropathy. *Neurology* 1997; 48: 1218–24.
- 91 Parry GJ. AAEM case report 30: multifocal motor neuropathy. *Muscle Nerve* 1996; 19: 269–76.
- 92 Kaji R, Oka N, Tsuji T, et al. Pathological findings at the site of conduction block in multifocal motor neuropathy [see comments]. *Ann Neurol* 1993; 33: 152–58.
- 93 Duggins AJ, McLeod JG, Pollard JD, et al. Spinal root and plexus hypertrophy in chronic inflammatory demyelinating polyneuropathy. *Brain* 1999; 122: 1383–90.
- 94 Auer RN, Bell RB, Lee MA. Neuropathy with onion bulb formations and pure motor manifestations. *Can J Neurol Sci* 1989; 16: 194–97.
- 95 Taylor BV, Dyck PJ, Engelstad J, Gruener G, Grant I, Dyck PJ. Multifocal motor neuropathy: pathologic alterations at the site of conduction block. *J Neuropathol Exp Neurol* 2004; 63: 129–37.
- 96 Prineas JW, McLeod JG. Chronic relapsing polyneuritis. *J Neurol Sci* 1976; 27: 427–58.
- 97 Corse AM, Chaudhry V, Crawford TO, Cornblath DR, Kuncl RW, Griffin JW. Sensory nerve pathology in multifocal motor neuropathy. *Ann Neurol* 1996; 39: 319–25.
- 98 Schlupe M, Steck AJ. Immunostaining of motor nerve terminals by IgM M protein with activity against gangliosides GM1 and GD1b from a patient with motor neuron disease. *Neurology* 1988; 38: 1890–92.
- 99 Thomas FP, Adapon PH, Goldberg GP, Latov N, Hays AP. Localization of neural epitopes that bind to IgM monoclonal autoantibodies (M-proteins) from two patients with motor neuron disease. *J Neuroimmunol* 1989; 21: 31–39.
- 100 O’Hanlon GM, Paterson GJ, Wilson G, Doyle D, McHardie P, Willison HJ. Anti-GM1 ganglioside antibodies cloned from

- autoimmune neuropathy patients show diverse binding patterns in the rodent nervous system. *J Neuropathol Exp Neurol* 1996; 55: 184–95.
- 101 O'Hanlon GM, Paterson GJ, Veitch J, Wilson G, Willison HJ. Mapping immunoreactive epitopes in the human peripheral nervous system using human monoclonal anti-GM1 ganglioside antibodies. *Acta Neuropathol (Berl)* 1998; 95: 605–16.
 - 102 Corbo M, Quattrini A, Lugaresi A, Santoro M, Latov N, Hays AP. Patterns of reactivity of human anti-GM1 antibodies with spinal cord and motor neurons. *Ann Neurol* 1992; 32: 487–93.
 - 103 Thomas FP, Thomas JE, Sadiq SA, et al. Human monoclonal IgM anti-Gal(beta 1-3)GalNAc autoantibodies bind to the surface of bovine spinal motoneurons. *J Neuropathol Exp Neurol* 1990; 49: 89–95.
 - 104 Ogawa-Goto K, Funamoto N, Ohta Y, Abe T, Nagashima K. Myelin gangliosides of human peripheral nervous system: an enrichment of GM1 in the motor nerve myelin isolated from cauda equina. *J Neurochem* 1992; 59: 1844–49.
 - 105 Santoro M, Uncini A, Corbo M, et al. Experimental conduction block induced by serum from a patient with anti-GM1 antibodies. *Ann Neurol* 1992; 31: 385–90.
 - 106 Arasaki K, Kusunoki S, Kudo N, Kanazawa I. Acute conduction block in vitro following exposure to antiganglioside sera. *Muscle Nerve* 1993; 16: 587–93.
 - 107 Uncini A, Santoro M, Corbo M, Lugaresi A, Latov N. Conduction abnormalities induced by sera of patients with multifocal motor neuropathy and anti-GM1 antibodies. *Muscle Nerve* 1993; 16: 610–15.
 - 108 Takigawa T, Yasuda H, Kikkawa R, Shigeta Y, Saida T, Kitasato H. Antibodies against GM1 ganglioside affect K⁺ and Na⁺ currents in isolated rat myelinated nerve fibers. *Ann Neurol* 1995; 37: 436–42.
 - 109 Harvey GK, Toyka KV, Zielasek J, Kiefer R, Simonis C, Hartung HP. Failure of anti-GM1 IgG or IgM to induce conduction block following intraneural transfer. *Muscle Nerve* 1995; 18: 388–94.
 - 110 Hirota N, Kaji R, Bostock H, et al. The physiological effect of anti-GM1 antibodies on saltatory conduction and transmembrane currents in single motor axons. *Brain* 1997; 120: 2159–69.
 - 111 Benatar M, Willison HJ, Vincent A. Immune-mediated peripheral neuropathies and voltage-gated sodium channels. *Muscle Nerve* 1999; 22: 108–10.
 - 112 Paparounas K, O'Hanlon GM, O'Leary CP, Rowan EG, Willison HJ. Anti-ganglioside antibodies can bind peripheral nerve nodes of Ranvier and activate the complement cascade without inducing acute conduction block in vitro. *Brain* 1999; 122: 807–16.
 - 113 Sheikh KA, Deerinck TJ, Ellisman MH, Griffin JW. The distribution of ganglioside-like moieties in peripheral nerves. *Brain* 1999; 122: 449–60.
 - 114 Quattrini A, Lorenzetti I, Sciorati C, et al. Human IgM anti-GM1 autoantibodies modulate intracellular calcium homeostasis in neuroblastoma cells. *J Neuroimmunol* 2001; 114: 213–19.
 - 115 Roberts M, Willison HJ, Vincent A, Newsom-Davis J. Multifocal motor neuropathy human sera block distal motor nerve conduction in mice. *Ann Neurol* 1995; 38: 111–18.
 - 116 Comi G, Amadio S, Galardi G, Fazio R, Nemni R. Clinical and neurophysiological assessment of immunoglobulin therapy in five patients with multifocal motor neuropathy. *J Neurol Neurosurg Psychiatry* 1994; 57 (Suppl): 35–37.
 - 117 Van den Berg LH, Franssen H, Wokke JH. Improvement of multifocal motor neuropathy during long-term weekly treatment with human immunoglobulin. *Neurology* 1995; 45: 987–88.
 - 118 Cappellari A, Nobile-Orazio E, Meucci N, Scarlato G, Barbieri S. Multifocal motor neuropathy: a source of error in the serial evaluation of conduction block. *Muscle Nerve* 1996; 19: 666–69.
 - 119 Leger JM, Younes-Chennoufi AB, Chassande B, et al. Human immunoglobulin treatment of multifocal motor neuropathy and polyneuropathy associated with monoclonal gammopathy. *J Neurol Neurosurg Psychiatry* 1994; 57 (Suppl): 46–49.
 - 120 Azulay JP, Rihet P, Pouget J, et al. Long term follow up of multifocal motor neuropathy with conduction block under treatment. *J Neurol Neurosurg Psychiatry* 1997; 62: 391–94.
 - 121 Van den Berg LH, Franssen H, Wokke JH. The long-term effect of intravenous immunoglobulin treatment in multifocal motor neuropathy. *Brain* 1998; 121: 421–28.
 - 122 Terenghi F, Cappellari A, Bersano A, Carpo M, Barbieri S, Nobile-Orazio E. How long is IVIg effective in multifocal motor neuropathy? *Neurology* 2004; 62: 666–68.
 - 123 Kaji R. Physiology of conduction block in multifocal motor neuropathy and other demyelinating neuropathies. *Muscle Nerve* 2003; 27: 285–96.
 - 124 Rasminsky M, Sears TA. Internodal conduction in undissected demyelinated nerve fibres. *J Physiol* 1972; 227: 323–50.
 - 125 Sumner AJ, Saida K, Saida T, Silberberg DH, Asbury AK. Acute conduction block associated with experimental antiserum-mediated demyelination of peripheral nerve. *Ann Neurol* 1982; 11: 469–77.
 - 126 Kuwabara S, Cappelen-Smith C, Lin CS, Mogyoros I, Bostock H, Burke D. Excitability properties of median and peroneal motor axons. *Muscle Nerve* 2000; 23: 1365–73.
 - 127 Burke D, Kiernan MC, Bostock H. Excitability of human axons. *Clin Neurophysiol* 2001; 112: 1575–85.
 - 128 Bostock H, Sharief MK, Reid G, Murray NM. Axonal ion channel dysfunction in amyotrophic lateral sclerosis. *Brain* 1995; 118: 217–25.
 - 129 Kiernan MC, Guglielmi JM, Kaji R, Murray NM, Bostock H. Evidence for axonal membrane hyperpolarization in multifocal motor neuropathy with conduction block. *Brain* 2002; 125: 664–75.
 - 130 Stys PK, Waxman SG, Ransom BR. Na⁽⁺⁾-Ca²⁺ exchanger mediates Ca²⁺ influx during anoxia in mammalian central nervous system white matter. *Ann Neurol* 1991; 30: 375–80.
 - 131 Kapoor R, Davies M, Blaker PA, Hall SM, Smith KJ. Blockers of sodium and calcium entry protect axons from nitric oxide-mediated degeneration. *Ann Neurol* 2003; 53: 174–180.
 - 132 Dyck PJ, O'Brien PC, Oviatt KF, et al. Prednisone improves chronic inflammatory demyelinating polyradiculoneuropathy more than no treatment. *Ann Neurol* 1982; 11: 136–41.
 - 133 Dyck PJ, Daube J, O'Brien P, et al. Plasma exchange in chronic inflammatory demyelinating polyradiculoneuropathy. *N Engl J Med* 1986; 314: 461–65.
 - 134 Carpo M, Cappellari A, Mora G, et al. Deterioration of multifocal motor neuropathy after plasma exchange. *Neurology* 1998; 50: 1480–82.
 - 135 Abbruzzese M, Reni L, Schenone A, Mancardi GL, Primavera A. Multifocal motor neuropathy with conduction block after *Campylobacter jejuni* enteritis. *Neurology* 1997; 48: 544.
 - 136 de Carvalho M, Luis ML. Relapsing chronic low-dose corticosteroid-responsive multifocal motor neuropathy with conduction block. *Electromyogr Clin Neurophysiol* 1997; 37: 95–97.
 - 137 Claus D, Specht S, Zieschang M. Plasmapheresis in multifocal motor neuropathy: a case report. *J Neurol Neurosurg Psychiatry* 2000; 68: 533–35.
 - 138 Charles N, Benoit P, Vial C, Bierme T, Moreau T, Bady B. Intravenous immunoglobulin treatment in multifocal motor neuropathy. *Lancet* 1992; 340: 182.
 - 139 Kermodé AG, Laing BA, Carroll WM, Mastaglia FL. Intravenous immunoglobulin for multifocal motor neuropathy. *Lancet* 1992; 340: 920–21.
 - 140 Yuki N, Yamazaki M, Kondo H, Suzuki K, Tsuji S. Treatment of multifocal motor neuropathy with a high dosage of intravenous immunoglobulin. *Muscle Nerve* 1993; 16: 220–21.
 - 141 Brannagan TH, III, Nagle KJ, Lange DJ, Rowland LP. Complications of intravenous immune globulin treatment in neurologic disease. *Neurology* 1996; 47: 674–77.
 - 142 Wittstock M, Benecke R, Zettl UK. Therapy with intravenous immunoglobulins: complications and side-effects. *Eur Neurol* 2003; 50: 172–75.
 - 143 Parker GJ. Motor neuropathy with multifocal persistent conduction block. *Muscle Nerve* 1992; 15: 1057.