

# Serum Biomarkers of Vascular Involvement in Childhood Uveitis

Carlyn V. Kouwenberg<sup>1</sup>, Jonas J. W. Kuiper<sup>1,2</sup>, Joke H. de Boer<sup>1</sup>, and Viera Kalinina Ayuso<sup>1</sup>

<sup>1</sup> Department of Ophthalmology, University Medical Center Utrecht, Utrecht, The Netherlands

<sup>2</sup> Center for Translational Immunology, University Medical Center Utrecht, University of Utrecht, Utrecht, The Netherlands

**Correspondence:** Carlyn V. Kouwenberg, Department of Ophthalmology, University Medical Center Utrecht, P.O. Box 85500, Utrecht 3508 GA, The Netherlands. e-mail:

[c.v.kouwenberg-3@umcutrecht.nl](mailto:c.v.kouwenberg-3@umcutrecht.nl)

**Received:** September 5, 2023

**Accepted:** February 27, 2024

**Published:** April 4, 2024

**Keywords:** pediatric; uveitis; biomarkers; retinal vasculature; proteomics

**Citation:** Kouwenberg CV, Kuiper JJW, de Boer JH, Kalinina Ayuso V. Serum biomarkers of vascular involvement in childhood uveitis. *Transl Vis Sci Technol.* 2024;13(4):9. <https://doi.org/10.1167/tvst.13.4.9>

**Purpose:** Nonanterior uveitis frequently involves the retinal vasculature; however, no molecular markers associated with the retinal vascular disease are currently known. In this study, we aimed to identify serum biomarker signatures associated with retinal vascular involvement in noninfectious pediatric uveitis.

**Methods:** We performed a 384-plex targeted proteomic analysis of serum samples of 154 noninfectious pediatric uveitis patients diagnosed with nonanterior uveitis ( $n = 74$ ), idiopathic chronic anterior uveitis (iCAU,  $n = 36$ ), or juvenile idiopathic arthritis-associated uveitis (JIA-U,  $n = 44$ ), as well as 22 noninflammatory pediatric controls. Data on retinal vascular involvement (i.e., papillitis, cystoid macular edema, retinal vasculitis, or retinal capillary leakage on optical coherence tomography and/or fluorescein angiography) were used to stratify cases in the nonanterior uveitis group.

**Results:** In the analysis of nonanterior uveitis, we identified nine proteins significantly associated with retinal vascular involvement, including F13B, MYOM3, and PTPN9. These proteins were enriched through pathway enrichment analysis for the coagulation cascade. Comparing cases and controls, we identified 63 differentially expressed proteins, notably proteins involved in platelet biology and complement cascades, which could be primarily attributed to differences in serum proteomes between anterior uveitis and nonanterior uveitis groups.

**Conclusions:** Serum proteins related to the coagulation and complement cascade are associated with retinal vascular involvement in pediatric uveitis patients. Our results indicate involvement of mediators that could interact with the microcirculation in pediatric uveitis and might serve as potential biomarkers in personalized medicine in the future.

**Translational Relevance:** Our targeted proteomics analysis in serum of pediatric uveitis patients indicates involvement of mediators that could interact with the microcirculation in pediatric uveitis and might serve as potential biomarkers in personalized medicine in the future.

## Introduction

Noninfectious pediatric uveitis is a complex inflammatory ocular condition, accounting for 5% to 10% of all uveitis cases.<sup>1</sup> Pediatric uveitis can occur in relation to autoimmune diseases such as juvenile idiopathic arthritis (JIA); however, most uveitis in children is idiopathic.<sup>2</sup> Children frequently have a severe chronic disease course with a high potential risk of develop-

ing vision-threatening complications. There is a higher risk of vision loss among pediatric uveitis patients with retinal vascular involvement, which accounts for 40% of all pediatric uveitis cases.<sup>2</sup> Retinal vascular involvement includes cystoid macular edema (CME), retinal vasculitis, and retinal capillary leakage, which require lengthy treatment or result in treatment failure and poor visual outcome.<sup>3,4</sup> Early identification of patients at risk of posterior involvement may enable early treatment to prevent vision-threatening complications.

Retinal vascular involvement is monitored by clinical assessment through imaging. Molecular mechanisms that predispose cases to posterior involvement remain poorly understood, and currently no biomarkers are known.

The rapid development of blood proteomic technologies provides new insights into the pathophysiological mechanisms, leading to the discovery of biomarkers and putative targets for treatment. The simultaneous quantification of hundreds of proteins using multiplexed immunoassays has aided our understanding of inflammatory conditions, including uveitis.<sup>5-7</sup> The application of targeted proteomics may help to identify the pathways associated with retinal vascular involvement in pediatric uveitis. In this study, we aimed to identify molecular signatures associated with the involvement of the retinal microcirculation through targeted proteomics of serum of patients with noninfectious pediatric uveitis.

## Methods

### Patients and Sample Collection

This study adhered to the tenets of the Declaration of Helsinki and was conducted in compliance with the Medical Ethics Research Committee of the University Medical Center Utrecht (protocol number: 22-1036). Written informed consent was obtained from all participants and/or representatives after they received an explanation of the nature and possible consequences of the study. Serum blood samples were collected from 154 children with noninfectious pediatric uveitis and 22 pediatric controls without a history of inflammatory disease during surgery indicated for strabismus. Patients with pediatric uveitis consisted of cases with nonanterior uveitis (the main anatomical localization of uveitis other than anterior—intermediate and panuveitis combined;  $n = 74$ ), idiopathic chronic anterior uveitis (iCAU,  $n = 36$ ), and juvenile idiopathic arthritis-associated uveitis (JIA-U,  $n = 44$ ). Serum was collected at the outpatient department of the University Medical Center Utrecht (uveitis biobank,  $n = 158$ ) or at the diagnostic laboratory at the University Medical Center Utrecht (the remainder of samples obtained for diagnostic purposes,  $n = 18$ ) between January 2013 and January 2023. The children were <18 years of age at the time of sampling. The initial diagnosis of uveitis was established by a trained uveitis specialist in accordance with the Standardization of Uveitis Nomenclature (SUN) criteria.<sup>8</sup> All patients were referred to a pediatric rheumatologist for the presence of underlying systemic disease. The diagno-

sis of systemic diseases was in concordance with the current diagnostic criteria.<sup>9,10</sup> For each sample, we collected age, sex, anatomic subtype of uveitis, presence of an associated systemic condition, uveitis activity, and laboratory results for antinuclear antibody (ANA) testing, as well as the use of systemic treatment with corticosteroids, immunomodulatory therapy (IMT), and/or biological agents. Uveitis activity at the time of sampling was determined in accordance with the SUN criteria.<sup>8</sup>

### Assessment of Retinal Vascular Involvement

The presence of retinal vascular involvement was determined for patients with nonanterior uveitis based on the presence of any of the following features in one or both eyes:

1. Retinal vasculitis on fluorescence angiography (FA)<sup>11</sup>
2. Diffuse capillary leakage on FA<sup>11</sup>
3. Papillitis defined as the presence of hyperfluorescence and/or leakage of the optic disc on FA<sup>4</sup> and/or average retinal nerve fiber layer thickness > 130  $\mu\text{m}$  on optical coherence tomography (OCT) with the exclusion of all other noninflammatory causes of optic disc swelling<sup>12</sup>
4. CME, defined as the presence of macular thickening with cyst formation visible on macular OCT and/or FA<sup>13-15</sup>

FA was performed within 6 months before or after sampling and OCT within 3 months before or after sampling.

### Serum Proteomic Olink Analysis

Serum tubes were kept for 30 minutes at room temperature, centrifuged at 2000g for 10 minutes at room temperature, and stored directly at  $-80^{\circ}\text{C}$  until assayed. Targeted proteomics of the serum samples was performed in close collaboration with Olink Proteomics (Uppsala, Sweden) using their proximity extension immunoassay (PEA) with the Explore 384 inflammation II panel measured by next-generation sequencing.<sup>16,17</sup> The obtained protein concentrations are expressed as normalized protein expression (NPX) values, an arbitrary unit or procedure defined on a  $\log_2$  scale of the serum concentration of each protein. Five proteins did not meet the Olink batch release quality control criteria and therefore are not included in the analysis (Supplementary Fig. S1). Based on protein detection information returned by Olink, 323 out of the 365 proteins (88%) were detected in >55% of the

samples. The full list of protein targets ( $n = 365$ ) is provided in Supplementary Table S1.

## Statistical Analysis

All statistical analysis were performed in R 4.2.2 (R Foundation for Statistical Computing, Vienna, Austria). Preprocessing of the Olink data output was conducted using the OlinkAnalyze R package<sup>18</sup> with the Olink\_qc\_plot and Olink\_dist\_plot functions. Principal component analysis was conducted using the factoextra package.<sup>19</sup> Differential expression analysis was conducted using a likelihood ratio function adjusting for age and sex. The qvalue R package was used for false discovery rate (FDR) estimation and  $q < 0.05$  was considered statistically significant. We made the following group comparisons: (1) pediatric controls versus nonanterior uveitis, iCAU, and JIA-U patients; (2) anterior versus nonanterior uveitis; and (3) nonanterior uveitis patients with and without retinal vascular involvement. Pathway enrichment analysis was conducted using the clusterProfiler R package<sup>20</sup> with Reactome as a reference database.<sup>21</sup>

## Results

In total, 176 participants were included in the study: nonanterior uveitis ( $n = 74$ ), iCAU ( $n = 36$ ), JIA-U ( $n = 44$ ), and controls ( $n = 22$ ). The nonanterior uveitis patients consisted of 21 patients diagnosed with intermediate uveitis and 53 patients with panuveitis. Demographic characteristics of the participants are shown in the Table. Among the patients with anterior uveitis, imaging was conducted in 78% ( $n = 62$ ), of whom FA was performed in 13% ( $n = 8$ ). None of these anterior uveitis patients showed evidence for vascular involvement.

## Group Comparisons

We conducted serum proteomic analysis of 154 patients and 22 controls adjusted for age and sex. The serum proteome of patients and controls showed 63 differentially expressed proteins ( $q < 0.05$ ), of which pigment epithelium-derived factor (PEDF; SERPINF1, serpin family F member 1;  $q = 5.4E-5$ ),

**Table 1.** Demographic Characteristics

Characteristic	Pediatric Control	Nonanterior Uveitis	iCAU	JIA-U	<i>P</i> Value
<i>N</i>	22	74	36	44	
Male, <i>n</i> (%)	8 (36)	32 (43)	11 (31)	15 (34)	0.578
Age at sampling in years, median (IQR)	8 (5–11)	13 (10–14)	11 (8–13)	10 (7–12)	<b>&lt;0.001</b>
Active uveitis at sampling, <i>n</i> (%)	NA	53 (72)	11 (31)	24 (55)	<b>&lt;0.001</b>
Duration of uveitis prior to sampling in years, median (IQR)	NA	1 (0.2–3)	1 (0.3–2)	3 (1–6)	<b>0.004</b>
Systemic disease <sup>a</sup> , <i>n</i> (%)					
None	22 (100)	57 (77)	31 (86)	40 (91)	
TINU	NA	12 (16)	3 (8)	1 (2)	
Blau syndrome/sarcoidosis	NA	4 (5)	0	0	
Other	NA	1 <sup>b</sup> (1)	2 <sup>c</sup> (6)	3 <sup>d</sup> (7)	
ANA seropositivity, <i>n</i> (%)	NA	17/69 (25)	21/36 (58)	34/41 (82)	<b>&lt;0.001</b>
Systemic therapy					
None	22 (100)	31 (42)	14 (39)	13 (30)	
Corticosteroids	0	13 (18)	2 (6)	2 (5)	
csDMARD	0	38 (81)	21 (58)	30 (68)	
Biological agent	0	10 (14)	4 (11)	0	

ANA, antinuclear antibodies, csDMARD, synthetic disease-modifying antirheumatic drug, iCAU, idiopathic chronic anterior uveitis, IQR, interquartile range, JIA-U, juvenile idiopathic arthritis associated uveitis, NA, not applicable, TINU, tubulointerstitial nephritis and uveitis syndrome.

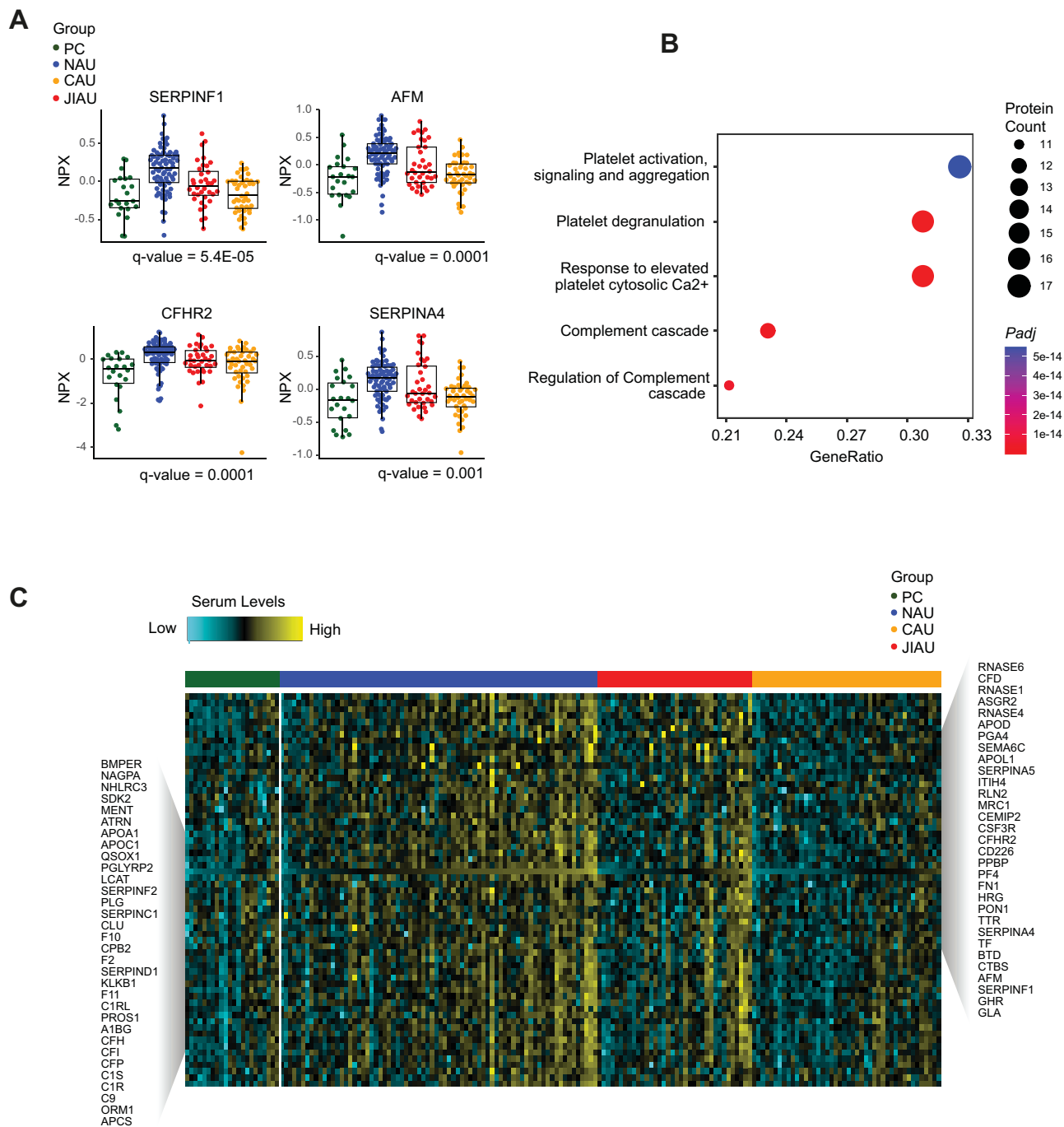
Bold text indicates a statistically significant difference with a *P*-value less than 0.05.

<sup>a</sup>Other than JIA

<sup>b</sup>Vogt-Koyanagi-Harada Disease

<sup>c</sup>Diabetes Mellitus Type I

<sup>d</sup>Alopecia Areata, Colitis Ulcerosa, Rosacea



**Figure 1.** Serum proteome changes comparing pediatric controls (PCs,  $n = 22$ ), nonanterior uveitis (NAU) patients ( $n = 74$ ), idiopathic chronic anterior uveitis (ICAU) patients ( $n = 36$ ), and juvenile idiopathic arthritis-associated uveitis (JIA-U) patients ( $n = 44$ ). **(A)** Scatterplots for the top four differentially serum proteins ( $q < 0.05$ ). NPX indicates normalized protein expression data from Olink. **(B)** Pathway enrichment analysis of the 63 differentially expressed proteins showing the top five using Reactome, with coloring based on the adjusted  $P$  values. **(C)** Heatmap of the 63 differentially expressed proteins between the controls and uveitis subtypes. The levels for each protein analyte are shown for each of the samples in the study and are color coded from low (cyan) to high (yellow).

a potent inhibitor of angiogenesis; afamin (AFM;  $q = 1.0E-4$ ), which is involved in vitamin E binding; complement factor H-related 2 (CFHR2;  $q = 1.4E-4$ ); and kallistatin (SERPINA4;  $q = 0.001$ ) were the most

differentially expressed (Fig. 1A). Pathway enrichment analysis of the 63 significantly altered serum proteins revealed that “platelet degranulation” and “response to elevated platelet cytosolic Ca<sup>2+</sup>” were the



top two significant identified pathways in the group comparison (Fig. 1B). Generally, cases with nonanterior uveitis showed the highest levels of significantly altered proteins ( $q < 0.05$ ), whereas controls showed the lowest levels (Fig. 1C). As a means of investigating whether systemic disease may have influenced our results, we compared iCAU (by definition without systemic involvement) with anterior uveitis associated with JIA-U. This comparison did not reveal any significant differences in serum protein levels between JIA-U and iCAU ( $q > 0.05$ ), indicating that the identified protein signatures are predominantly involved in uveitis (Supplementary Fig. S2A).

### Anterior and Nonanterior Uveitis

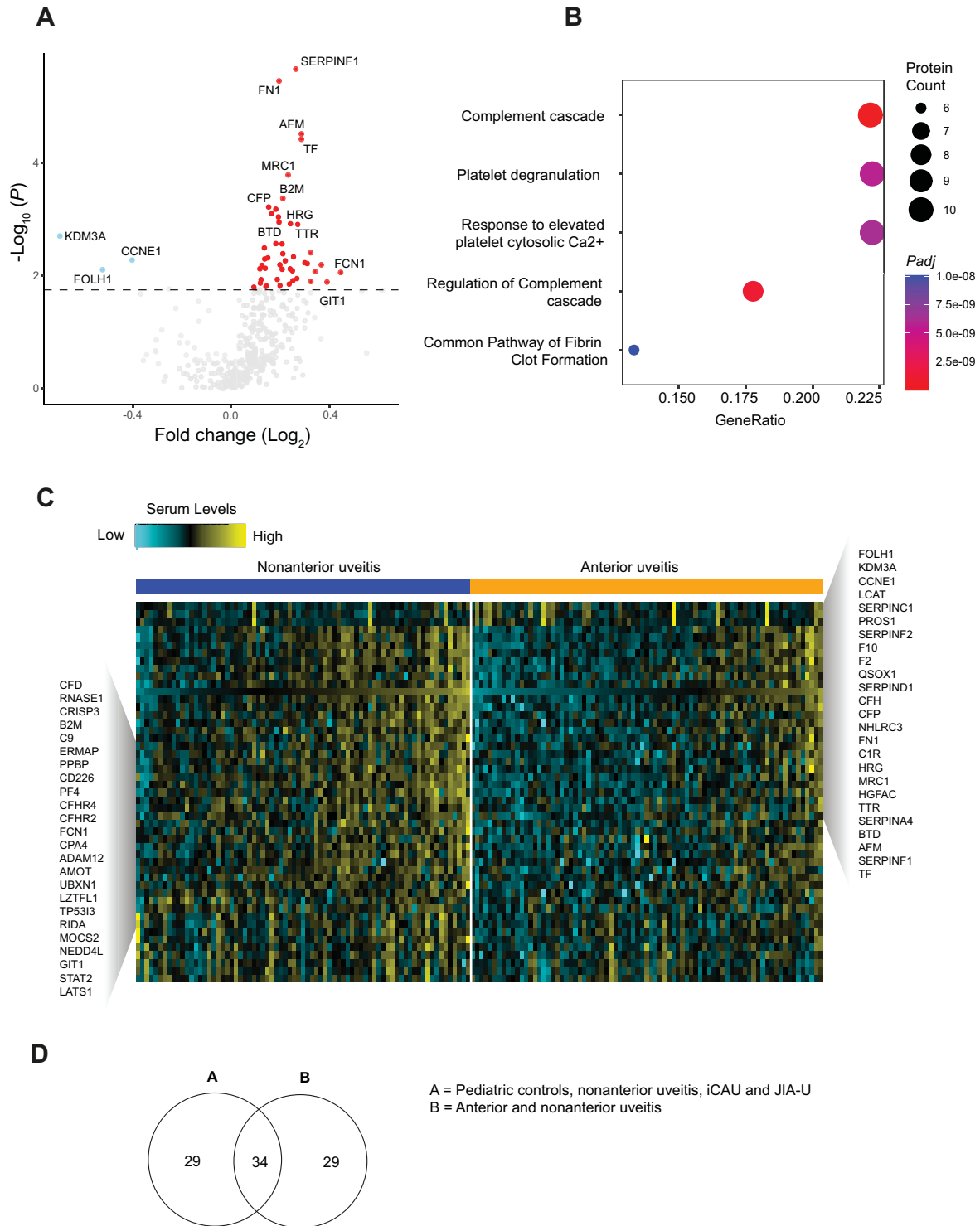
A common and clinically relevant bifurcation of pediatric uveitis phenotypes is based upon the anatomical location of disease. Because the nonanterior uveitis group has more retinal vascular involvement, we also compared the serum proteome between patients with anterior uveitis (iCAU and JIA-U,  $n = 80$ ) and cases with nonanterior uveitis ( $n = 74$ ) while adjusting for sex and age. This analysis revealed 63 significantly different serum proteins, of which SERPINF1 ( $q = 6.1E-4$ ) was most significantly differentially expressed in serum, followed by fibronectin 1 (FN1;  $q = 2.6E-4$ ), AFM ( $q = 0.001$ ), and the iron-binding transport protein transferrin ( $q = 0.001$ ) (Fig. 2A, Supplemental Table S1). In agreement with the analysis of the four disease groups, the differentially expressed proteins were generally most elevated in nonanterior uveitis (Fig. 2C). In total, 34 proteins were identical to those detected by group comparison. These proteins were also enriched for the pathways “platelet degranulation” ( $q = 6.18E-13$ ) and “response to elevated platelet cytosolic  $Ca^{2+}$ ” ( $q = 6.18E-13$ ). The 29 proteins uniquely identified by this analysis were enriched for “signaling by Hippo” and “downregulation of TGF-beta receptor signaling” as the most significant pathways; however, both  $q$  values were 0.09. A Venn diagram shows the overlapping proteins in the two analyses (Fig. 2C). Pathway enrichment analysis of the 63 differently expressed serum proteins ( $q < 0.05$ ) showed a strong enrichment for the “platelet degranulation” pathways ( $q = 2.1E-9$ ) and the “complement cascade” pathways ( $q = 2.6E-11$ ) (Fig. 2B).

### Retinal Vascular Involvement in Nonanterior Uveitis

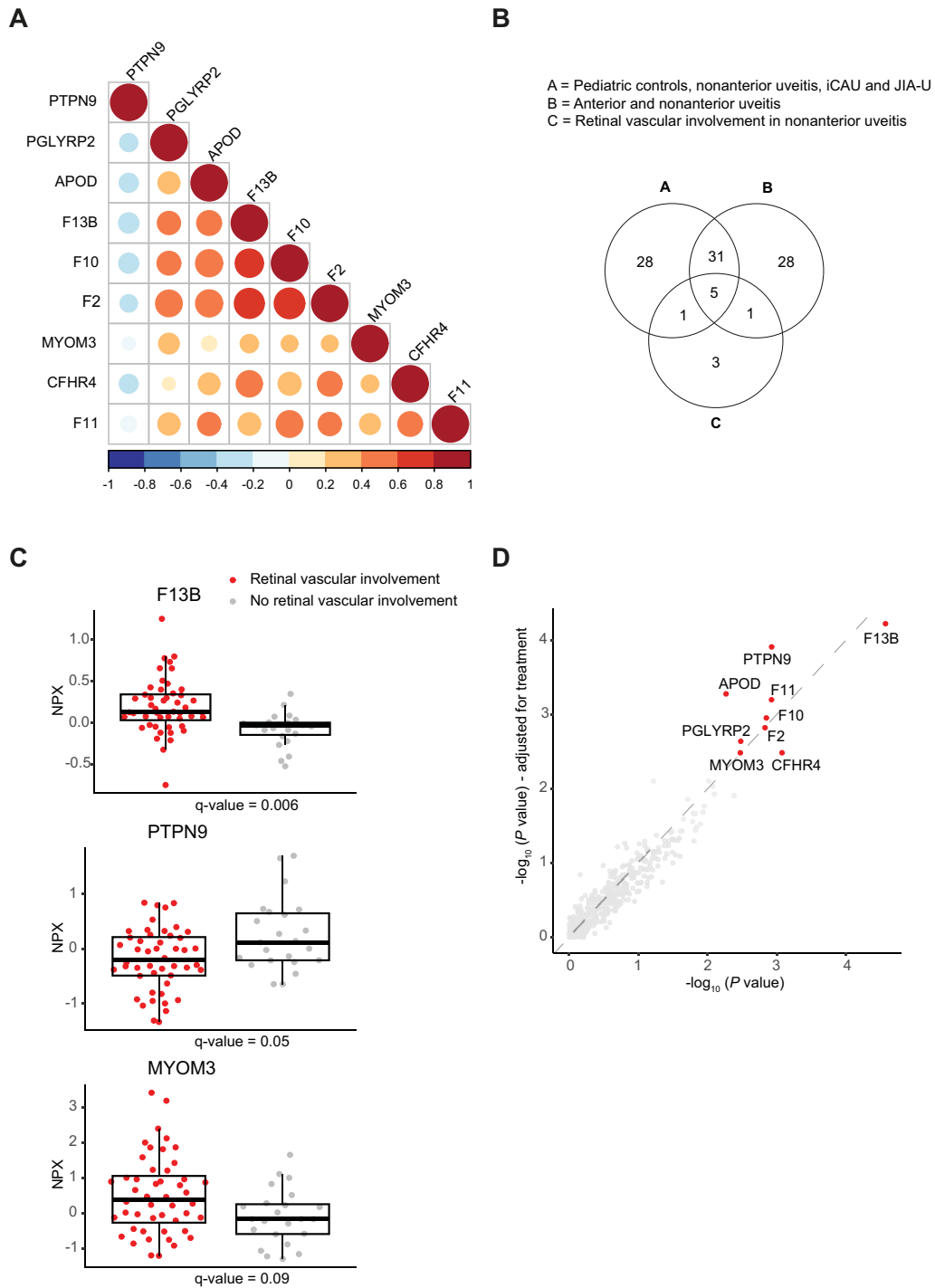
Finally, we aimed to correlate clinical evidence for retinal vascular involvement (supported by FA and/or

OCT) with serum protein markers. To this end, the nonanterior uveitis group was subdivided into active retinal vascular involvement ( $n = 48$ ) and non-active retinal vascular involvement ( $n = 23$ ). The likelihood ratio test at a FDR of 5% resulted in only one significantly different protein when adjusting for age and sex: F13B (coagulation factor XIII B chain;  $q = 0.006$ ). Using a less stringent  $q$  value of 0.1, we found nine differentially expressed proteins. We found the same nine differentially expressed proteins that showed a moderate correlation (Fig. 3A, Supplementary Table S1). However, in this new analysis apolipoprotein D was differentially expressed instead of serpin family A member 6 (SERPINA6). The proteins are predominantly involved in the clotting cascade as supported by pathway enrichment analysis (“formation of fibrin clot,”  $q = 1.05E-6$ ), such as myomesin 3 (MYOM3) and protein tyrosine phosphatase non-receptor type 9 (PTPN9) (Fig. 3B). Three of these proteins were unique for retinal vascular involvement (F13B, MYOM3, and PTPN9) (Fig. 3C).

Next, we investigated the influence of systemic treatment, uveitis activity, and the presence of presumed tubulointerstitial nephritis and uveitis (TINU) syndrome on our results. To further investigate the influence of systemic treatment on the results, we performed an additional analysis in which we corrected for the use of systemic treatment. This is shown in Figure 3D, where we plotted the protein expressions with and without correction (i.e., addition as covariate in the model) for the use of systemic treatment. This analysis revealed that systemic treatment had little influence on the signal structure of the statistical associations detected and, thus, that biological differences between the groups explained the bulk of the signal. Forty-eight percent ( $n = 23$ ) of the patients with active retinal vascular involvement used systemic treatment compared to 73% ( $n = 17$ ) of the patients with non-active retinal vascular involvement. The same analysis was performed for uveitis activity, where we compared the models with and without adjustment for uveitis activity (shown in Supplementary Fig. S2B), which also revealed a minimal impact of uveitis activity on the association signal found between the groups. The last variable we investigated is the presence of systemic disease. In the nonanterior uveitis group, 16 patients were diagnosed with presumed TINU syndrome. The  $P$  values from analyses with and without adjustment for the presence of presumed TINU syndrome were comparable, as is shown in Supplementary Figure S2C. We concluded that systemic treatment, uveitis activity, and TINU syndrome were not related to the serum proteome differences found between groups.



**Figure 2.** Serum proteome changes comparing anterior pediatric uveitis ( $n = 80$ ) versus nonanterior pediatric uveitis ( $n = 74$ ) patients. **(A)** Differential expression of serum proteins obtained from proximity extension assay (PEA) results. Differentially upregulated proteins are depicted in *red*, and downregulated proteins are depicted in *blue*. Proteins were analyzed using the likelihood ratio test adjusted for age and sex and followed by FDR multiple testing correction. The *dotted line* represents  $q = 0.05$ . NPX indicates normalized protein expression data from Olink. **(B)** Pathway enrichment analysis of the 63 differentially expressed proteins showing the top five using Reactome, with coloring based on the adjusted  $P$  values. **(C)** Heatmap of the 63 differentially expressed proteins between the anterior and nonanterior uveitis cases. The levels for each protein analyte are shown for each of the samples in the study and are color coded from low (*cyan*) to high (*yellow*). **(D)** Venn diagram showing overlapping and unique proteins in the four disease group comparisons **(A)** and the nonanterior versus nonanterior comparison.



**Figure 3.** Serum proteome changes comparing pediatric nonanterior uveitis patients with active retinal vascular involvement ( $n = 48$ ) and non-active retinal vascular involvement ( $n = 23$ ). **(A)** Correlation plot showing the correlation between nine differentially expressed serum proteins obtained from PEA results using the likelihood ratio test adjusted for age, sex, and immunomodulatory treatment and followed by a relaxed FDR multiple testing correction ( $q < 0.1$ ). **(B)** The overlapping serum proteins shown in a Venn diagram of three different group comparisons: A, pediatric controls compared to nonanterior uveitis, iCAU, and JIA-U; B, anterior compared to nonanterior uveitis; and C, retinal vascular involvement in nonanterior uveitis patients. **(C)** Scatterplots for the three unique serum proteins regarding retinal vascular involvement in children with nonanterior uveitis with  $q < 0.1$ , except for F13B, for which is  $q < 0.05$ . **(D)** Protein expressions with and without correction for the use of immunomodulatory treatment. NPX indicates normalized protein expression data from Olink.

## Discussion

In this study, we used extensive PEA proteomics analysis to identify serum biomarkers to discriminate between active and non-active retinal vascular involvement in children with nonanterior uveitis. These results reveal increased serum levels of proteins related to the clotting cascade. This indicates that mediators that affect microcirculation may play a role in noninfectious pediatric uveitis. Furthermore, our study demonstrates that dysregulation of the coagulation and complement cascade contributes to the disease pathophysiology of noninfectious nonanterior uveitis in children. The question is whether the dysregulation in the coagulation and complement cascade contributes to developing retinal vascular involvement or whether it might be a secondary effect of retinal vascular involvement in pediatric uveitis. However, the current study cannot discriminate between cause and effect and mainly shows associations among groups of patients.

Proteomics is a powerful screening tool for serum biomarkers in various diseases which may aid in our understanding of the pathogenesis and pathophysiology of a disease through identification of disease-associated protein profiles.<sup>22–24</sup> Disease biomarkers may serve as agents for diagnostics or directly serve as targets for therapeutic treatment. Previous proteomic studies have successfully identified protein signatures in the serum of noninfectious uveitis that can predict the relative need for IMT.<sup>5,7</sup>

In our study of pediatric uveitis, we identified that disturbances of the coagulation and complement pathways are specifically related to retinal vascular involvement. Previous studies of animal models of experimental autoimmune uveitis have also shown it to be characterized by upregulation of complement and coagulation cascades.<sup>25</sup> Similarly, in adult patients with intermediate uveitis, elevated levels of complement cascade effectors and the coagulation system have been reported.<sup>26</sup> A recent study by de Groot et al.<sup>27</sup> identified a key role of the complement and coagulation cascades in the underlying disease mechanisms of idiopathic multifocal choroiditis. Platelets are well known for their essential role in thrombus formation in response to vessel injuries.<sup>28</sup> However, platelets are increasingly being recognized for their immune modulatory properties and role in inflammatory processes.<sup>29,30</sup> The storage granules of platelets contain receptors, soluble proteins, and bioactive molecules that all have important pro- and anti-inflammatory functions. For example, activated platelets can trigger activation of the complement system through these molecules. Vice versa, complement activation can induce platelet

activation and aggregation, leading to enhancement of procoagulant activity.<sup>30</sup> Platelets may become excessively activated if this interaction between platelet and complement is not sufficiently controlled, leading to inflammatory disease. There is no evidence that the activated complement and coagulation cascade have clinical significance in pediatric uveitis patients or that their effects can be reversed, but they provide an important avenue for future studies.

In the analysis comparing anterior with nonanterior uveitis, the protein levels exhibited significant variation among cases, irrespective of the uveitis subtype. This indicates molecular heterogeneity associated with factors that could be extending beyond those linked solely to vascular involvement. Previous studies have reported several biomarkers detected in aqueous humor and serum of uveitis patients that differed based on uveitis location. These studies mainly focused on anterior uveitis, especially JIA-associated uveitis. Transthyretin (TTR) was found to be a biomarker for active disease in JIA-U and silent chronic anterior uveitis in aqueous humor. TTR had a higher expression in the serum of nonanterior uveitis patients compared to anterior uveitis patients regardless of uveitis activity.<sup>32</sup> TTR is suggested to modulate immune responses and inhibit inflammation. Similarly, it has been suggested that SERPINF1 (PEDF) is a negative acute-phase protein,<sup>33</sup> and it also has higher expression rates in nonanterior uveitis patients in our study. One could speculate that higher expression rates of these negative acute-phase proteins are needed as a response to inhibit the inflammation in nonanterior uveitis. The exact working mechanisms and roles must be further investigated and compared with levels in the aqueous humor. Other biomarkers detected in prior studies, such as IL-29, S100A8, S100A9, and S100A12, are not included in the Olink Inflammation II panel and could be included in future research.

The protein that was mostly upregulated in patients with active vascular involvement was coagulation factor XIII B chain (F13B) involved in stabilizing the fibrin clot. The *F13B* gene is located at a locus on chromosome 1 near the complement factor H (*CFH*) gene. This locus encodes regulators of the complement system. Genetic variants in chromosome 1 lead to an increased risk of developing age-related macular degeneration driven predominantly by dysregulation of the complement system and are also associated with central serous chorioretinopathy and multifocal choroiditis.<sup>27,34,35</sup> *CFH*-rs1065489 polymorphism was associated with anterior uveitis, as well as uveitis recurrence.<sup>36</sup> There are many genetic variants or polymorphisms of the *CFH* gene in the general population; therefore, it would be interesting for future research to



investigate whether these polymorphisms in the *CFH* gene are associated with retinal vascular involvement in idiopathic pediatric uveitis.

Another interesting topic for future research would be to investigate prospectively the predictive value of the differentially expressed proteins of retinal vascular involvement. Several patients have increased levels of the differentially expressed proteins, but they do not show clinical vascular retinal involvement established by imaging (OCT and FA) at the time of sampling or prior to sampling. These patients could develop retinal vascular involvement at a later stage, indicating a predictive value of the found proteins. This difference might possibly be influenced by medication use, as 73% of the patients without retinal vascular involvement used IMT (including corticosteroids) compared to 48% of the patients with retinal vascular involvement. Both groups had relatively higher levels of the differentially expressed proteins than patients whom did not use IMT. Also, analysis with correction for the use of IMT showed that the main findings do not change. Therefore, the immunomodulating therapy may have led to remission in those without retinal vascular involvement. In future studies, the role of medication in relation to vascular involvement and complement activation could be further investigated.

By identifying the characterization of uveitis proteome, the revealed protein biomarkers might be used for early detection of advanced disease. These patients might be at risk for developing a more advanced and severe disease, resulting in the need for a more intensive treatment approach. Based on our findings, one could speculate whether the coagulation and complement cascade might be interesting to further explore with regard to its role in the early detection of advanced disease and for novel treatment strategies. A limitation of this study is the use of serum for the proteomic analysis, as several clotting factors are destroyed or consumed during the clotting process, which can complicate the interpretation. However, the PEA analysis by Olink uses relative changes in proteins between samples, so even for low protein levels the relative change can be detected and analyzed.

In conclusion, we discovered upregulation of circulating proteins with key functions in the coagulation and complement cascade in pediatric uveitis patients with retinal vascular involvement. Our results indicate involvement of mediators that interact with the systemic microcirculation in nonanterior pediatric uveitis that could be interesting key targets for future studies of the immunopathogenesis of vascular involvement in pediatric noninfectious uveitis. Future identification of solid biomarkers associated with different forms of retinal vascular involve-

ment could serve as diagnostic markers or even be potentially associated with innovative therapeutic approaches preventing vision-threatening complications and improving the general prognosis for this vulnerable group of patients.

## Acknowledgments

The authors especially thank Wouter J. Venema and Aafke M. de Lig for assisting in the data preparation.

Supported by the Dutch Ophthalmology Foundation Oogfonds, the F.P. Fischer Stichting, and the ODAS Stichting.

Disclosure: **C.V. Kouwenberg**, None; **J.J.W. Kuiper**, None; **J.H. de Boer**, None; **V. Kalinina Ayuso**, None

## References

1. Cunningham J. Uveitis in children. *Ocul Immunol Inflamm.* 2000;8(4):251–261.
2. Smith JA, Mackensen F, Sen HN, et al. Epidemiology and course of disease in childhood uveitis. *Ophthalmology.* 2009;116(8):1544–1551.e1.
3. Yang P, Zhong Z, Su G, et al. Retinal vasculitis, a common manifestation of idiopathic pediatric uveitis? *Retina.* 2021;41(3):610–619.
4. Maleki A, Cao JH, Silpa-Archa S, Foster CS. Visual outcome and poor prognostic factors in isolated idiopathic retinal vasculitis. *Retina.* 2016;36(10):1979–1985.
5. Kuiper JJW, Verhagen FH, Hiddingh S, et al. A network of serum proteins predict the need for systemic immunomodulatory therapy at diagnosis in noninfectious uveitis. *Ophthalmol Sci.* 2022;2(3):100175.
6. Schrijver B, Koliijn PM, Berge JCEM, et al. Vitreous proteomics, a gateway to improved understanding and stratification of diverse uveitis aetiologies. *Acta Ophthalmol.* 2022;100(4):403–413.
7. Wennink RAW, Kalinina Ayuso V, Tao W, Delemarre EM, de Boer JH, Kuiper JJW. A blood protein signature stratifies clinical response to csDMARD therapy in pediatric uveitis. *Transl Vis Sci Technol.* 2022;11(2):4.
8. Jabs DA, Nussenblatt RB, Rosenbaum JT, et al. Standardization of uveitis nomenclature for reporting clinical data. Results of the first international workshop. *Am J Ophthalmol.* 2005;140(3):509–516.

9. Petty RE, Southwood TR, Manners P, et al. International League of Associations for Rheumatology classification of juvenile idiopathic arthritis: second revision, Edmonton, 2001. *J Rheumatol.* 2004;31:390–392.
10. Wood P. Diagnosis criteria, nomenclature, classification. In: Munthe E, ed. *The Care of Rheumatic Children*. Basel: EULAR Publishers. 1978:42–50.
11. Tugal-Tutkun I, Herborg CP, Khairallah M, et al. Scoring of dual fluorescein and ICG inflammatory angiographic signs for the grading of posterior segment inflammation (dual fluorescein and ICG angiographic scoring system for uveitis). *Int Ophthalmol.* 2010;30(5):539–552.
12. Kouwenberg CV, Blom LA, Vellinga SC, Bozkir I, de Boer JH, Ayuso VKK. The role of the retinal nerve fiber layer thickness on OCT in the evaluation of papillitis in childhood uveitis: evaluating papillitis in pediatric uveitis using OCT-RNFL. *Am J Ophthalmol.* 2023;254:62–68.
13. Agarwal A, Pichi F, Invernizzi A, Gupta V. Disease of the year: differential diagnosis of uveitic macular edema. *Ocul Immunol Inflamm.* 2019;27(1):72–88.
14. Fardeau C, Champion E, Massamba N, Lehoang P. Uveitic macular edema. *Eye (Lond).* 2016;30(10):1277–1292.
15. Kempen JH, Sugar EA, Jaffe GJ, et al. Fluorescein angiography versus optical coherence tomography for diagnosis of uveitic macular edema. *Ophthalmology.* 2013;120(9):1852–1859.
16. Lundberg M, Eriksson A, Tran B, Assarsson E, Fredriksson S. Homogeneous antibody-based proximity extension assays provide sensitive and specific detection of low-abundant proteins in human blood. *Nucleic Acids Res.* 2011;39(15):e102.
17. Assarsson E, Lundberg M, Holmquist G, et al. Homogenous 96-plex PEA immunoassay exhibiting high sensitivity, specificity, and excellent scalability. *PLoS One.* 2014;9(4):e95192.
18. Nevola K, Sandin M, Guess J, et al. Olink-Analyze: facilitate analysis of proteomic data from Olink. Available at: <https://cran.r-project.org/web/packages/OlinkAnalyze/index.html>. Accessed March 20, 2024.
19. Kassambara A, Mundt F. factoextra: extract and visualize the results of multivariate data analyses. Available at: <https://cran.r-project.org/web/packages/factoextra/index.html>. Accessed March 20, 2024.
20. Yu G, Wang LG, Han Y, He QY. clusterProfiler: an R package for comparing biological themes among gene clusters. *OMICS.* 2012;16(5):284–287.
21. Gillespie M, Jassal B, Stephan R, et al. The Reactome pathway knowledgebase 2022. *Nucleic Acids Res.* 2022;50(D1):D687–D692.
22. Kalla R, Adams AT, Bergemalm D, et al. Serum proteomic profiling at diagnosis predicts clinical course, and need for intensification of treatment in inflammatory bowel disease. *J Crohns Colitis.* 2021;15(5):699–708.
23. Jakimovski D, Qureshi F, Ramanathan M, et al. Proteomics and relationship with axonal pathology in multiple sclerosis: 5-year diffusion tensor imaging study. *Brain Commun.* 2023;5(3):fcad183.
24. Hu C, Dai Z, Xu J, et al. Proteome profiling identifies serum biomarkers in rheumatoid arthritis. *Front Immunol.* 2022;13:865425.
25. Guo DD, Hu B, Tang HY, et al. Proteomic profiling analysis reveals a link between experimental autoimmune uveitis and complement activation in rats. *Scand J Immunol.* 2017;85(5):331–342.
26. Sepah YJ, Velez G, Tang PH, et al. Proteomic analysis of intermediate uveitis suggests myeloid cell recruitment and implicates IL-23 as a therapeutic target. *Am J Ophthalmol Case Rep.* 2020;18:100646.
27. de Groot EL, Ossewaarde-van Norel J, de Boer JH, et al. Association of risk variants in the *CFH* gene with elevated levels of coagulation and complement factors in idiopathic multifocal choroiditis. *JAMA Ophthalmol.* 2023;141(8):737–745.
28. Broos K, Feys HB, De Meyer SF, Vanhoorelbeke K, Deckmyn H. Platelets at work in primary hemostasis. *Blood Rev.* 2011;25(4):155–167.
29. Puy C, Pang J, Reitsma SE, et al. Cross-talk between the complement pathway and the contact activation system of coagulation: activated factor XI neutralizes complement factor H. *J Immunol.* 2021;206(8):1784–1792.
30. Eriksson O, Mohlin C, Nilsson B, Ekdahl KN. The human platelet as an innate immune cell: interactions between activated platelets and the complement system. *Front Immunol.* 2019;10:1590.
31. Chen X, Yao X, Chi Y, et al. A cross-sectional observational study of nailfold capillary morphology in uveitis. *Curr Eye Res.* 2018;43(11):1342–1350.
32. Kalinina Ayuso V, de Boer JH, Byers HL, et al. Intraocular biomarker identification in uveitis associated with juvenile idiopathic arthritis. *Invest Ophthalmol Vis Sci.* 2013;54(5):3709–3720.
33. Zipplies JK, Hauck SM, Schoeffmann S, et al. Serum PEDF levels are decreased in a spontaneous

- animal model for human autoimmune uveitis. *J Proteome Res.* 2009;8(2):992–998.
34. Keenan TDL, Toso M, Pappas C, Nichols L, Bishop PN, Hageman GS. Assessment of proteins associated with complement activation and inflammation in maculae of human donors homozygous risk at chromosome 1 CFH-to-F13B. *Invest Ophthalmol Vis Sci.* 2015;56(8):4870–4879.
35. Chen ZJ, Lu SY, Rong SS, et al. Genetic associations of central serous chorioretinopathy: a systematic review and meta-analysis. *Br J Ophthalmol.* 2022;106(11):1542–1548.
36. Yang MM, Lai TYY, Tam POS, et al. Association of CFH and SERPING1 polymorphisms with anterior uveitis. *Br J Ophthalmol.* 2013;97(11):1475–1480.