




# Noninvasive diode laser—an effective and safe treatment of iris cysts in 46 eyes of 35 horses

Emanuël K. L. Stas<sup>1</sup>  | Hanneke Hermans<sup>1</sup>  | Inge J. M. Slenter<sup>2</sup>  |  
Stefanie Veraa<sup>3</sup>  | Jos M. Ensink<sup>1</sup>

<sup>1</sup>Faculty of Veterinary Medicine, Department Clinical Sciences, Equine Sciences, Equine Surgery and Orthopaedics, Utrecht University, CM, Utrecht, The Netherlands

<sup>2</sup>Faculty of Veterinary Medicine, Department Clinical Sciences, Surgery of Companion Animals, Ophthalmology, CM, Utrecht, The Netherlands

<sup>3</sup>Faculty of Veterinary Medicine, Department Clinical Sciences, Diagnostic Imaging, Utrecht University, CM, Utrecht, The Netherlands

## Correspondence

Emanuël K. L. Stas, Faculty of Veterinary Medicine, Department Clinical Sciences, Equine Sciences, Equine Surgery and Orthopaedics, Utrecht University, Yalelaan 112-114, 3584 CM Utrecht, The Netherlands.  
Email: [e.k.l.stas@uu.nl](mailto:e.k.l.stas@uu.nl)

## Funding information

Utrecht University

## Abstract

**Background:** Iris cysts in horses are often asymptomatic and noticed incidentally. However, cysts can cause local corneal oedema and erratic behaviour like shying, decreased performance and head-shaking.

**Objectives:** To describe the use of diode laser as a noninvasive treatment option for iris cysts in the horse and to document factors influencing its efficacy, associated complications, long-term outcome and rate of recurrence.

**Study design:** Retrospective case series.

**Methods:** Case records of horses treated for iris cysts by diode laser at the Utrecht University Equine Clinic were reviewed between 2008 and 2020. Diagnosis was based on ophthalmic and ultrasonographic evaluation. Long-term follow-up was obtained in two phases, a telephone survey with the owner and a photographic re-evaluation of the treated eyes.

**Results:** Thirty-five horses were included, with a total of 46 eyes treated. One day after diode laser treatment (short-term), 35/46 treated eyes had a good decrease in cyst size, 7/46 had a moderate effect, 1/46 had a minimal effect, 1/46 had no effect, and in two cases the effect was unspecified. The decrease in size after diode laser treatment in polycystic eyes (odds ratio [OR] 0.381, 95% CI 0.1530–0.724),  $p = 0.001$ , thick-walled cysts (OR = 0.139; CI = 0.023–0.726,  $p = 0.02$ ) and hyperplastic corpora nigra (OR = 0.081; CI = 0.004–0.528,  $p = 0.03$ ) was significantly less satisfactory, with ORs of 0.381, 0.139 and 0.081, respectively. Minor complications, such as mild reactive uveitis, were reported in 8/46 (17%) eyes. On long-term follow-up (median 19 months; IQR 25.5), clinical signs had diminished or disappeared in most cases (93%) and 83% of the owners would recommend the treatment. Based on long-term photographic re-evaluation (median 32.5 months; IQR 49.75), 2/16 cases of recurrence were seen.

**Main limitations:** Retrospective design, follow-up by telephone questionnaire and photographic re-evaluation. Loss to follow-up in the photographic re-evaluation.

**Conclusions:** Both short- and long-term results indicate diode laser treatment is a useful and safe option for iris cyst size reduction, with a low risk of recurrence.

This is an open access article under the terms of the [Creative Commons Attribution-NonCommercial](https://creativecommons.org/licenses/by-nc/4.0/) License, which permits use, distribution and reproduction in any medium, provided the original work is properly cited and is not used for commercial purposes.

© 2022 The Authors. *Equine Veterinary Journal* published by John Wiley & Sons Ltd on behalf of EVJ Ltd.

Presurgical ultrasonography is recommended to assess the feasibility of treatment and to allow for better surgical planning.

#### KEYWORDS

corpora nigra, head-shaking, horse, long-term follow-up, ophthalmology

## 1 | INTRODUCTION

Multiple types of anterior uveal or iris cysts have been described in the equine eye: cystic enlarged corpora nigra, pupillary margin cysts and cysts of the ciliary body and iris.<sup>1-7</sup> The neuroectoderm of the optic cup creates the anterior and posterior iris epithelium.<sup>8</sup> Corpora nigra, also called granula iridica, are formed by remnants of the optic cup that create vacuolated extensions at the dorsal and to a smaller extent at the ventral pupillary margin of horses.<sup>6-11</sup> It has been hypothesised that cystic enlarged corpora nigra develop as a coalescence of these vacuolated areas; and that pupillary margin cysts arise due to an increased production of viscous fluid by the neuroectodermal cells that line the corpora nigra.<sup>8,9,12</sup> In dogs, histopathology of iridociliary cyst content has been shown to be consistent with hyaluronic acid.<sup>13</sup> The exact etiopathogenesis for development of iris cysts in the equine eye is still unclear as they often occur spontaneously and may fluctuate in size.<sup>6-10</sup> Most iris cysts are unilateral, singular and have a smooth surfaced round appearance at ophthalmic examination. Intraocular melanomas and hyperplasia of the corpora nigra should be on the list of differential diagnoses.<sup>6,9,11,12,14-16</sup> On ultrasonographic examination, the cysts appear as a rounded structure with hyperechoic lining surrounding an anechoic centre most commonly bulging into the anterior eye chamber.<sup>10,17,18</sup> Ultrasonography aids in differentiating between fluid filled cysts and solid masses.<sup>9-11,14,19,20</sup>

Although iris cysts in horses are often asymptomatic and noticed incidentally,<sup>2,9,10</sup> cysts of a certain size could impair vision as they block the pupillary aperture to some extent.<sup>2,9,12,21</sup> This impaired vision will be accentuated in a bright and sunny environment when the pupil is miotic and could cause erratic behaviour like shying, decreased performance (e.g. in showjumping) or head-shaking.<sup>2,9-12,21</sup> In other species like dogs, cats and humans, obstruction of the pupillary aperture can not only impair vision but also decreases aqueous humour outflow, leading to secondary glaucoma. However, this phenomenon has not been described in horses.<sup>2,12,14,19,22</sup> In some horses, very large iris cysts can come in contact with the corneal endothelium causing mechanical disturbance, leading to corneal oedema and possible corneal ulceration.<sup>10,22</sup>

In cases of symptomatic cysts, treatment is advocated.<sup>2,22</sup> Multiple treatment options have been described, like limbal cystotomy with fine needle aspiration, surgical excision and laser deflation.<sup>2,9,10,12,18,21-23</sup> Several lasers can be used, like Nd:YAG laser,<sup>12,18</sup> argon laser<sup>9</sup> and diode laser.<sup>2,21</sup> In general, diode lasers are less expensive and more compact than Nd:YAG lasers.<sup>2</sup> The 810-nm diode laser wavelength is absorbed by melanin-containing tissues, where the thermal energy results in photocoagulation of the cyst wall.<sup>2</sup> However, this thermal energy could cause collateral thermal damage.<sup>2,18</sup> To date, reported

literature and long-term follow-up on diode laser deflation of iris cysts in horses is limited. This study aimed to contribute to the evidence on the efficacy, safety and long-term outcome of diode laser treatment of iris cysts in horses, which may aid veterinarians and owners in making an informed treatment decision.

## 2 | MATERIALS AND METHODS

### 2.1 | Cases

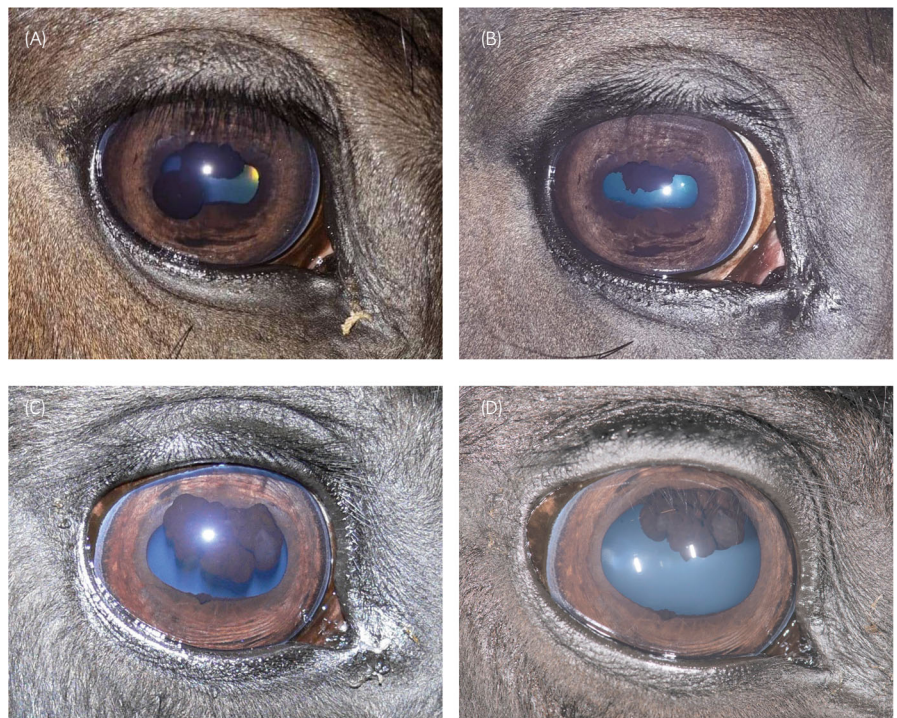Case records at the Utrecht University Equine Clinic from January 2008 to December 2020 were reviewed. Horses were included based on diagnosis of an iris cyst and treatment of the iris cyst by diode laser at the Utrecht University Equine Clinic. Breed, age, sex, clinical history, treatment, complications and outcome until hospital discharge were recorded.

### 2.2 | Diagnostic evaluation

A day before treatment, all horses underwent a routine ophthalmic examination performed by a board-certified veterinary ophthalmologist and/or a resident in veterinary ophthalmology (ECVO) together with a board-certified or resident veterinary surgeon (ECVS), and included neuro-ophthalmic testing, hand-held slit lamp biomicroscopy (SL-15, Kowa) and direct ophthalmoscopy (Pneumatic Otoscope, Welch Allyn), revealing iris cysts (Figure 1A,C). Based on the treating veterinarian's choice, the intraocular pressure (IOP) was measured with a rebound tonometer in the unsedated horse (Icare Tonovet®, Icare).

Ultrasonographic evaluation of both eyes was performed by a board-certified veterinary radiologist (ECVDI). A standard transpalpebral method was performed using a high-frequency linear 12-3 MHz (L12-3), linear 18-5 MHz (L18-5) or microconvex 8-5 MHz (C8-5) transducer (all Philips Healthcare) in combination with an Epiq-5 ultrasound machine (Philips Healthcare). The location of the cysts, number of cysts, cyst architecture, cyst size and cyst wall thickness were recorded. Cyst architecture was categorised into two groups: cysts incorporated in the (hyperplastic) corpora nigra and isolated cysts. The size of the largest cyst per eye was measured on ultrasonography or estimated visually if no ultrasound was performed. Wall thickness was calculated as the average of 5 measurements, taken at the anterior aspect of the cysts which would be reachable by laser. A wall thickness of <0.5 mm was categorised as thin-walled and ≥0.5 mm was categorised as thick-walled.

**FIGURE 1** Iris cysts before and after treatment. (A) a single solitary iris cyst on the ventrotemporal pupillary margin. The iris blocks the temporal miotic pupil. (B) Same eye as in Figure 1A, diode laser treatment led to a complete deflation of the cyst. (C) Polycystic iris cysts incorporated in the corpora nigra. (D) Same eye as in 1C, diode laser treatment led to a moderate decrease in size



### 2.3 | Treatment

Anti-inflammatory treatment was started 1 day prior to surgery, consisting of corticosteroid (dexamethasone [Dexamethasone, Teva] or hydrocortisone [Terra-Cortril, Pfizer]) containing eye drops q6h and meloxicam (Boehringer Ingelheim) (0.6 mg/kg) q24 h orally per os. On the day of surgery, all horses received Meloxicam, Metacam (Boehringer Ingelheim) per os (0.6 mg/kg) or intravenously (i.v.). All horses were placed in stocks and sedated with detomidine (Orion) (0.01–0.02 mg/kg) with or without butorphanol (MSD) (0.01–0.02 mg/kg) i.v. An auriculopalpebral nerve block was performed using lidocaine (Richter Pharma AG) or mepivacaine (Richter Pharma AG) and topical tetracaine hydrochloride (Bausch & Lomb Pharma) was administered in the lower conjunctival sac. Laser deflation was performed with an Iridex DioVet™ 810-nm diode laser (Iridex) applied with an indirect ophthalmoscopy headset delivery system (LIO) and a double aspherical lens. Pulses of 500 msec were used and power was gradually increased based on clinical effectiveness and ranged from 400 to 1250 mW. Laser time was estimated to be between 5 and 10 minutes. Total amount of energy (J) applied per eye was recorded.

### 2.4 | Post-operative management

One day after laser treatment, ophthalmic examination was repeated, the effect of treatment was evaluated and possible complications, for example reactive uveitis were noted. No standardised post-operative (ultrasonographic) measurements were performed. After laser treatment, atropine eye drops were added to the anti-inflammatory treatment of topical dexamethasone eye drops, and oral meloxicam

(Boehringer Ingelheim) (0.6 mg/kg). From 2017 onwards, a standardised post-operative anti-inflammatory protocol, to prevent discomfort and laser-induced uveitis, was instituted: first 5 days of oral meloxicam (Boehringer Ingelheim) q24h (0.6 mg/kg), topical atropine 0.5% eyedrops q24h, topical dexamethasone 0.1% combined with an antibiotic (usually gentamycin [Bausch & Lomb Pharma]) eye-drops q6h. Topical dexamethasone 0.1% (Teva) was continued for another 14 days with a tapering dose.

### 2.5 | Long-term follow-up

Long-term follow-up was organised in two parts: a telephone survey with the owners (Supplementary Item 1) and photographic re-evaluation. The telephone survey was conducted in two phases: 13/35 horse owners were contacted by JE in 2016, and the remaining (22/35) were contacted in 2020 by ES. Owners were asked for the initial clinical signs, resolution of clinical signs, reoccurrence of iris cysts and if owners would recommend the treatment. In 2021, a photographic follow-up was performed by ES. Eyes were re-evaluated for the recurrence of cysts and other long-term complications.

### 2.6 | Data analysis

Data were collected and processed in a Microsoft Excel® spreadsheet (Tables S1–S4). Statistical analysis was performed using R software (version 1.1.1093). Data were assumed to be categorical, and each eye was treated as a single statistical unit. Three variables that could affect a successful decrease in cyst size after diode laser treatment were selected:

the number of cysts per eye, cyst wall thickness and cyst architecture. For each of the variables, a logistic regression model was built. In this model, the outcome variable was the effect of treatment on cyst size, being 1 for positive ('good') outcome and 0 for negative ('moderate', 'slight' or 'no') outcome. Explanatory variables on each separate model were the number of cysts, wall thickness and architecture. The number of cysts per eye, calculates the effect for each increment of a cyst per eye. Cyst wall thickness was categorised in thin-walled and thick-walled cysts (as mentioned above). Architecture was categorised into two groups: solitary cysts and cysts incorporated in (hypertrophic) corpora nigra. Models were built in R-studio (1.1.193) using the function 'glm' for each model using the option 'logit' for logistic regression. P-value, odds ratio (OR) and respective 95% confidence intervals (CIs) were calculated from each model using the R package *oddratio* (version 2.0.1). Significance was set at  $p \leq 0.05$ .

### 3 | RESULTS

#### 3.1 | Cases

Thirty-five horses were included: 26/35 (74%) Warmbloods, 4/35 (11%) Friesians, 3/35 (9%) ponies, 1 (3%) trotter and 1 (3%) Haflinger. Age at presentation ranged between 1 and 18 years (mean 10.4 years, standard deviation [SD] 4.28). The cases included 14 mares and 21 geldings (Table S1).

The horses were presented with a variety of complaints. In 31/35 horses, the cyst was either noticed by the owner or by the referring veterinarian during a routine examination or a prepurchase examination. In 8/35 cases, the iris cyst was an incidental finding; in 27/35, it was suspected to be related to clinical signs. Five owners mentioned the cysts appeared to increase in size over time. Of the 35 horses, 3 presented with concurrent local corneal oedema. In 23/35 horses, shying was a presenting clinical sign. In most cases, this behaviour was more noticeable in bright surroundings. Of the 35 horses, 5 had signs of head-shaking. Some horses presented with multiple clinical signs. The cysts were suspected to cause loss of performance and difficulties in riding and handling of 26/35 horses (Table S4).

#### 3.2 | Diagnostic evaluation

A total of 48 eyes in 35 horses were diagnosed with iris cysts. Findings on ophthalmic examination of cyst laterality, cyst location and number of cysts per eye are displayed in Figure 2 and Table S2. In 3/48 eyes, large iris cysts were in contact with the endothelium leading to localised corneal oedema. Based on the treating veterinarian's assessment, intraocular pressure (IOP) was measured in 10 horses and was within normal limits (16–30 mmHg) in all of them.<sup>24,25</sup>

In 26/35 horses, bilateral ultrasonography was performed, confirming the clinical/ophthalmic diagnosis of fluid filled iris cysts (Figure 3). The mean size of the largest cyst per eye was 5.4 mm with a range of 2–10 mm. Of the 48 cysts, 20 cysts were incorporated in

the (hyperplastic) corpora nigra and 20 were isolated cysts; for 8/48, it was not specified in the medical records. Of the 48 cysts, 29 cysts were categorised as thin walled (<0.5 mm), 9 were thick walled ( $\geq 0.5$  mm) and 9 were not evaluated by ultrasound (Table S2).

#### 3.3 | Treatment

Of the 35 horses, 29 horses were given anti-inflammatory treatment 1 day prior to surgery. Of the 35 horses, 46 eyes were treated by diode laser. The total amount of energy applied per eye varied from 2 to 25.2 J, with an average of 10.5 J. The average joules applied per cyst, based on the eyes with only one cyst, was 6.8 J.

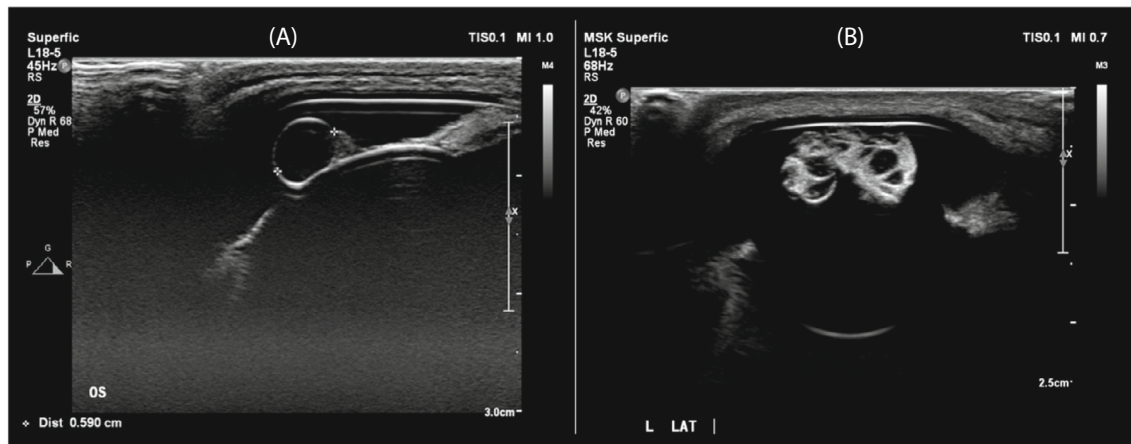
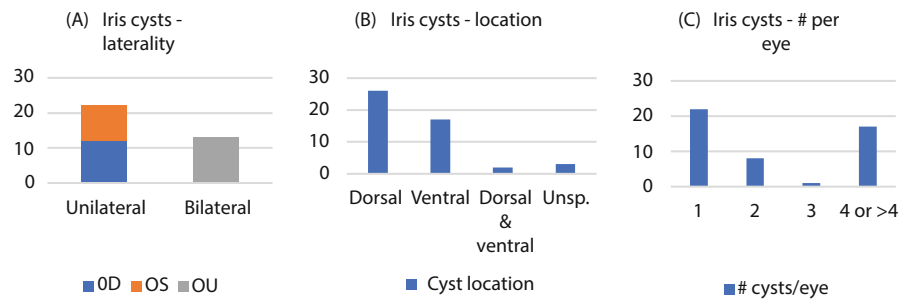
The effect of the laser treatment was evaluated perioperatively and 24–48 h post-operatively by the treating veterinarian (Figure 4). In 12/46 eyes, the procedure led to perforation and deflation of the cyst perioperatively, with minor to moderate dispersion of viscous cyst content containing fine pigment particles in the anterior chamber. The pigmented substance dissolved in the following 24 h. In the others, the effect of laser treatment was only visible at evaluation 24–48 h post-operatively. In total, 36/46 (78%) treated eyes had a satisfactory (good) effect as described by the treating veterinarian, 7/46 (15%) had a moderate decrease in size, 1/46 (2%) minimal effect, 1/46 (2%) no effect, and in two cases, it was not specified in the medical records (Figure 1). All eight moderate to minimal responders had multiple cysts (3 or more) located within hyperplastic corpora nigra. Two horses underwent a second laser treatment with 4- and 6-day intervals between the two treatments, based on an unsatisfactory effect of the first treatment. The second laser session led to cystic collapse in one case, and minimal further improvement in the second case. In one horse, a cremello filly with a translucent cyst of 4.2 mm, laser treatment had no effect (Figure 5 and Table S2).

Statistical analysis confirmed that the effect of laser treatment on cyst size was significantly ( $p = 0.001$ ) less satisfactory in eyes with multiple cysts. The OR for each increment of 1 cyst was 0.381 [95% CI = 0.153–0.724]. Each additional cyst reduced the chance of successful treatment. Chances of successful decrease in size were also significantly ( $p = 0.02$ ) lower if cysts were incorporated in the corpora nigra [OR = 0.081; CI = 0.004–0.528]. There were also significantly ( $p = 0.03$ ) lower success rates for thick-walled cysts [OR = 0.139; CI = 0.023–0.726].

#### 3.4 | After-treatment and complications

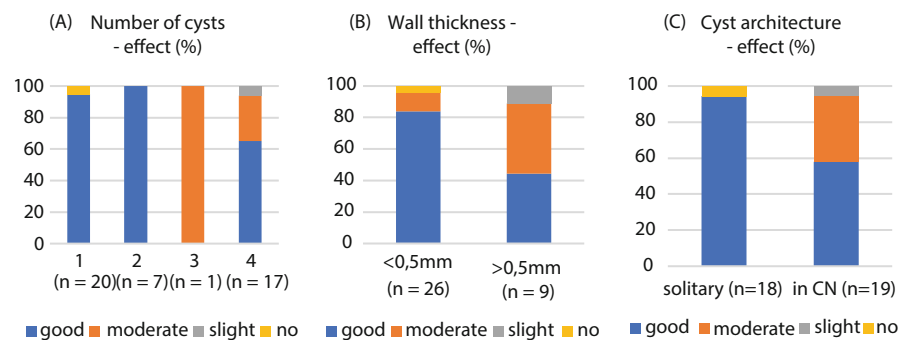
Given the retrospective nature of the study, post-operative treatment was not uniform for all patients and ranged from 3 days to 24 days (mean 17 days). Horses were hospitalised for 0–9 days after surgery (mean 5 days). Complications were reported in 8/46 (17%) eyes. One eye showed some spots of laser damage to the retina after treatment. Three eyes had newly developed postsurgical localised corneal oedema most likely caused by thermal endothelial damage that resulted in subtle corneal fibrosis. One eye with pigment dispersion after perforation of the cyst developed some laser-induced uveitis

**FIGURE 2** Findings on ophthalmic examination of iris cysts (A) laterality, (B) location and (C) number of cysts per eye



**FIGURE 3** Ophthalmic ultrasonography. (A) A fluid filled thin-walled iris cyst bulging into the anterior eye chamber. (B) A polycystic and hyperplastic corpora nigra bulging into the anterior eye chamber and contacting the endothelial side of the cornea

**FIGURE 4** Effect of diode laser treatment of iris cysts in the horse as evaluated by the treating veterinarian in relation to (A) Number of cysts, (B) Cyst wall thickness and (C) Cyst architecture. CN, corpora nigra



with fibrin/inflammatory debris in the anterior chamber that resolved after 24 h with the standard after-treatment protocol. Three eyes developed a fluorescein-positive corneal defect during hospitalisation, most likely caused by inadvertent contact with the cornea during the application of topical eye medication. In these cases, corticosteroid treatment was discontinued until corneas were fluorescein negative on re-evaluation.

### 3.5 | Long-term follow-up

Follow-up was obtained by telephone questionnaire for all 35 horses. The median time to follow-up was 19 months, interquartile range

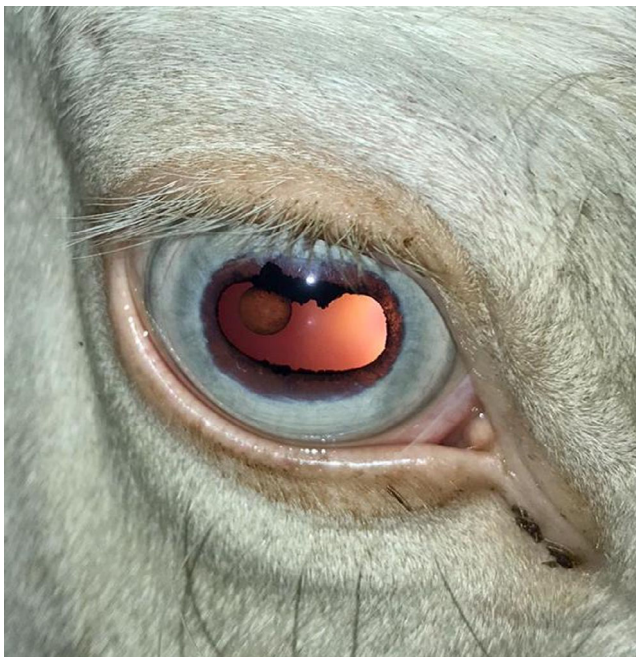
(IQR) 25.5 (range 3–126 months). Of the 35 horses, 8 underwent treatment of asymptomatic cysts. In these cases, resolution of clinical signs could not be evaluated. Of the 27 symptomatic horses, 22 (82%) horse owners described complete resolution of the clinical signs. Three (3/27, 11%) horse owners described partial resolution. In two of these, shying decreased but did not disappear. In the third horse, the shying resolved but the horse continued to display head-shaking and this was later diagnosed as trigeminal-mediated head-shaking. In 2/27 (7%) horses, the treatment did not affect head-shaking (1) or shying (1) (Figure 6). Time to resolution of clinical signs varied from immediate improvement to 6 months. Of the 35 owners, 22 stated that there was no recurrence of enlarged corpora nigra or cysts. Eight of the 35 owners were not able to answer this question

as they were unable to see the cyst before treatment or did not have a reference to compare the corpora nigra. Five of the 35 owners reported that their horse had a recurrence of enlarged corpora nigra. Two of these horses were re-examined at the Utrecht University Equine Clinic as the clinical signs recurred. On ultrasonographic examination, one of these horses had a solid mass of hyperplastic corpora nigra 46 months after the first treatment and the other horse redeveloped polycystic corpora nigra 11 months after treatment. Neither of these horses were treated with diode laser for a second time either because the owner declined or because a second treatment was not deemed beneficial.

Of the 35 owners, 29 (83%) stated that they would recommend the treatment, 3 were moderately satisfied with the treatment,

1 would not recommend treatment and 2 had no opinion on this matter. Owner dissatisfaction was related to a limited effect of the laser on the cyst size and/or lack of improvement of clinical signs.

After the first phase of follow-up had been concluded, all owners were contacted again for a photographic re-evaluation (median 32.5; IQR 49.75; range 9–161 months). Of the 35 horses, 16 horses were re-evaluated for recurrence of iris cysts and other long-term complications, 10 were sold and could not be re-evaluated, 5 were subjected to euthanasia due to reasons unrelated to the eyes and 4 were lost to follow-up for other reasons (Table S4). Of the 16 horses, 14 horses did not show any signs of recurrence of enlarged corpora nigra or other long-term complications. One horse had an empty cyst sac hanging from the iris that did not cause any clinical signs. Photographic re-evaluation confirmed two cases of recurrence of enlarged CN (Table S4).

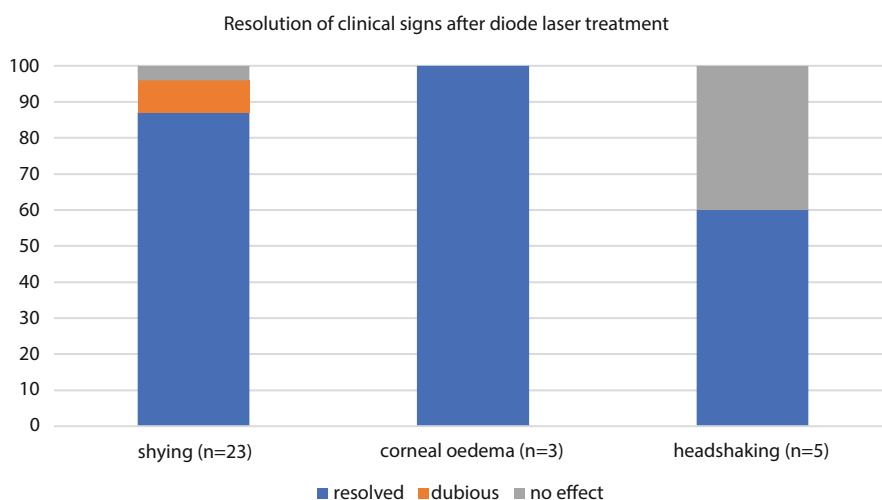


**FIGURE 5** A translucent iris cyst in a cremello filly. The cyst was unresponsive to diode laser treatment.

## 4 | DISCUSSION

Diode laser treatment in pigmented iris cysts is a valid treatment option in horses, with minor complications and a low risk of recurrence at long-term follow-up. Effectiveness of treatment is dependent on the number of cysts present, cyst architecture, wall thickness and the degree of pigmentation. To the authors' knowledge, this is the first large study including long-term follow-up on diode laser treatment of iris cysts in horses. Treatment is indicated for cysts that result in clinical signs.<sup>2,22</sup> However, not all animals that were treated in this study had clinical signs related to the cysts. In a subset of cases, diode laser treatment might be instituted and useful as a preventive measure. For example, in case of an asymptomatic cyst that is increasing in size, or if the iris cyst is a remark on the prepurchase exam (PPE), preventing the sale.

In our group of horses, shying was the clinical sign encountered most often, followed by head-shaking, similar to previous reports.<sup>2,12,18</sup> In a bright environment, the iris cyst can block either the nasal or temporal miotic pupil (Figure 1A). With movement of the head and blinking, cysts often show subtle motions. The combination



**FIGURE 6** Resolution of clinical signs after diode laser treatment reported by owners during a telephone survey

of these two features might explain the complaints of decreased performances, shying and head-shaking.<sup>9</sup> Glaucoma secondary to iris cysts has been reported in humans, dogs and cats, however, not in horses.<sup>2,14,19,22,26</sup> In the current study, none of the horses showed signs of glaucoma (e.g. corneal striae) on ophthalmic examination and all the IOPs measured were within normal limits.

In this study, all horses were treated with an Iridex DioVet™ 810-nm diode laser (Iridex). The 810-nm laser wavelength enables transcorneal photocoagulation of pigmented areas like melanin in iris cysts. This can cause cyst wall rupture and collapse during laser treatment or might have a delayed effect caused by damage to the blood vessels and epithelial cells lining the cyst. The nonresponding cyst encountered in our study was translucent and the lack of pigment likely prevented absorption of the laser energy by the cyst wall. Based on the presentation in the cremello filly, this cyst could be a clinical sign of the heterozygote form of multiple congenital ocular anomaly (MCOA) related to colour dilution as seen in Rocky Mountain and Icelandic horses.<sup>1–5</sup>

Diode laser deflation of iris cysts is a short procedure that can be safely performed in the standing sedated horse, avoiding the risks related to general anaesthesia and recovery in horses.<sup>2,12</sup> This offers an advantage in comparison with more invasive surgical methods that necessitate general anaesthesia.<sup>9,23</sup>

Based on the eyes treated in our study, diode laser treatment proved to be a safe procedure with only minor complications. These included corneal scarring, retinal burns, corneal defects and laser-induced uveitis.<sup>2,12,18</sup> Corneal scarring could be the result of the cyst being in contact with the corneal endothelium or could occur during the diode laser treatment due to collateral thermal damage.<sup>2,21</sup> In our study, 3/46 eyes developed corneal oedema after laser treatment, leading to subtle corneal fibrosis. Similarly, retinal burns can occur due to an incorrect aimed laser beam or an unexpected movement of the horse during laser application.<sup>2,18</sup> User experience is an important factor in avoiding these complications.<sup>2,18</sup> In the post-operative period, fluorescein-positive corneal defects occurred in three horses, most likely related to horse behaviour and handler experience during the application of topical eye medication. Students with different levels of experience had applied the medication at the Utrecht University Equine Clinic. All corneal lesions healed without significant consequences. Although not encountered in our study, Gilger et al.<sup>12</sup> and Toth et al.<sup>18</sup> have described intraoperative haemorrhage after Nd:YAG deflations, without perceived consequences.

Most ophthalmic surgeries in horses can potentially induce reactive uveitis as a complication. In our study, only one horse had mild signs of a reactive uveitis (fibrin in the anterior chamber) after the laser treatment. All horses received a post-operative anti-inflammatory treatment with a tapering dose of topical dexamethasone disodium phosphate 0.1% eyedrops (Teva). In current literature, there are conflicting results regarding the necessity of corticosteroids and the long-term tapering dose to prevent discomfort and laser-induced uveitis in all patients.<sup>9,12,18,21</sup> Gilger et al.<sup>12</sup> used anti-inflammatory therapy in their first four patients for 5–7 days. No signs of discomfort or laser-induced uveitis were observed.<sup>12</sup> Their

subsequent four patients did not receive any anti-inflammatory therapy, without perceived consequences.<sup>12</sup> The equine patients mentioned by Gemensky-Metzler et al.<sup>2</sup> only got perioperative flunixin meglumine IV and topical atropine, 2/9 cases received an extra dose of flunixin on indication of discomfort (blepharospasm).<sup>2</sup> Toth et al.<sup>18</sup> used systemic and topical anti-inflammatory treatment for 5 days in all 13 horses, no signs of discomfort or reactive uveitis were noted.<sup>18</sup> Therefore, the need for pre- and post-treatment with anti-inflammatory drugs seems debatable.<sup>2,12</sup> More research is needed to provide more information on the necessity and intensity of this anti-inflammatory treatment.

Pretreatment ultrasonography was helpful for evaluation of the number of cysts, and cyst wall thickness, size and architecture. This proved to be important information, as success rates were lower for polycystic eyes, thick-walled cysts and hyperplastic corpora nigra. Ultrasonography also aids in the identification of thin-walled areas, reducing the amount of energy needed for cyst wall deflation and in this way avoiding complications related to delivery of undue laser energy.<sup>27</sup> Based on our results, we concluded that ultrasonographic examination is not only an important part of the diagnostic evaluation, but also of added value in expectation management and surgical planning.

In the cases described in our study, diode laser treatment led to a decrease in cyst size in 93% of the cases. In our study, this was further differentiated in a good effect in 78% of cases and a moderate effect in 15% of cases. Previous studies report very good success rates up to 100%, but did not differentiate further.<sup>2,12,18</sup> A moderate response was mainly seen in polycystic eyes, thick-walled cysts and hyperplastic corpora nigra. In these cases, a second ultrasonographic examination and (guided) treatment might have led to a further improvement, increasing the success rate.<sup>9,18,27</sup> However, because of the retrospective nature of this study, this could not be assessed. In our study, only two horses received a second treatment, leading to collapse of the cyst in one case and slight improvement in the second case. The choice of repeat laser treatment was based on the treating veterinarians' assessment, repeat ultrasonography, the presence of clinical signs, and the owners' motivation.

Recurrence of iris cysts or enlarged corpora nigra was reported by five owners during the long-term follow-up telephone survey. The fact that this was based on owner's evaluation and not on repeat ophthalmic examination is an important limitation of this study. Only two of these horses redeveloped clinical signs and were re-examined at the Utrecht University Equine Clinic. In the long-term photographic follow-up of 16 horses, two recurrences were seen. Based on these results of the telephone survey and photographic re-evaluation, a low recurrence rate is expected. Recurrence of iris cysts after laser treatment in horses has not been reported previously.<sup>2,12,18</sup> Newly formed cysts have been described post-treatment, however, in cats and humans.<sup>19,22</sup>

The resolution of clinical signs after laser treatment was evaluated by the owner. Clinical signs diminished or disappeared in most cases (25/27; 93%). In one horse, a moderate effect of treatment was related to a partial resolution of clinical signs. In several horses, it took a couple of months before erratic behaviour faded away. As stated by Berger et al.,<sup>21</sup> behavioural changes can be

normalised after removing the physical causes, thereby restoring performance.<sup>21</sup> This underlines the importance of retraining and desensitisation as a second part of the treatment.<sup>9,21</sup> Three (3/5) horses presented with head-shaking showed a complete resolution of signs. Two (2/5) other horses did not show a resolution of clinical signs despite successful cyst deflation. Of these two, one horse was diagnosed with trigeminal-mediated head-shaking at a later stage. For the second horse, no further diagnostics were performed to rule out other causes of head-shaking. Iris cysts are one of the many differential diagnoses of head-shaking and it is a challenge to definitively identify the cyst as the cause of the complaint before surgery.<sup>18,21</sup> This is why cyst deflation is often used as a diagnostic treatment in cases of head-shaking and abnormal behaviour.<sup>17</sup> In this perspective, nonresponders might be related to retained psychological causes as cyst deflation did not result in resolution of the clinical signs or the cyst was not related to the clinical signs.<sup>18,21</sup>

Our study has some limitations as it is a retrospective case series. Thirty-five horses and 46 eyes were included in this study and a larger number of cases would make statistical analysis more reliable. Diagnostic evaluation was not complete for all patients as not all patients underwent measurement of IOP or underwent ocular ultrasonography and not all horses received anti-inflammatories 1 day prior to laser treatment. As mentioned above, the reduction in cyst size was only evaluated by the treating veterinarian based on an ophthalmic evaluation, no objective measurements were performed. Long-term follow-up was obtained by a telephone questionnaire and photographic re-evaluation, but a full ophthalmic and ultrasonographic examination of all patients would have given more information. All owners participated in the telephone questionnaire; however for the photographic re-evaluation, about half of the cases were lost to follow-up. Clinical signs were only observed and evaluated by the owner. No reliable recordings were performed when clinical signs diminished or resolved after treatment. There was no control group included in this study to compare the resolution of clinical signs without treatment.

In conclusion, this retrospective case series provides a better understanding about the pre-, intra- and post-operative considerations related to diode laser deflation of iris cysts in horses. Diode laser treatment proved to be a safe and effective treatment option for pigmented iris cysts in horses. Our results demonstrate that a low recurrence rate of enlarged corpora nigra or cysts can be expected with only minor recurrence of clinical signs. Presurgical ultrasonography is recommended to assess the feasibility of treatment and allow for better surgical planning.

## CONFLICT OF INTERESTS

No competing interests have been declared.

## AUTHORSHIP

All authors participated in clinical investigations. E. Stas, H. Hermans, J. Ensink and I. Slenter performed ophthalmic examinations; S. Veraa performed ocular ultrasonography; I. Slenter performed diode laser treatments. J. Ensink and E. Stas designed the study. Data were

collected and processed by J. Ensink and E. Stas. The manuscript was drafted by E. Stas and revised by all authors. All authors approved the final manuscript.

## ACKNOWLEDGEMENTS

We thank our colleagues at the university clinic of Utrecht, especially Filipe Serra Braganca, Michael Boevé and Sylvia Djajadiningrat-Laanen, and owners and referring veterinarians for their contributions to our study.

## FUNDING INFORMATION

None.

## PEER REVIEW

The peer review history for this article is available at <https://publons.com/publon/10.1111/evj.13590>.

## DATA AVAILABILITY STATEMENT

The data that support the findings of this study are openly available at Stas, Emanuël, 2022, "Non-invasive diode laser, an effective and safe treatment of iris cysts in 46 eyes of 35 horses", <https://doi.org/10.34894/S9PTKL>, DataverseNL

## ETHICAL ANIMAL RESEARCH

Research ethics committee oversight not required by this journal: retrospective analysis of clinical data.

## INFORMED CONSENT

Completion of the questionnaire was taken as participant consent.

## ORCID

Emanuël K. L. Stas  <https://orcid.org/0000-0002-6915-9402>

Hanneke Hermans  <https://orcid.org/0000-0002-7581-6683>

Inge J. M. Slenter  <https://orcid.org/0000-0002-4061-6542>

Stefanie Veraa  <https://orcid.org/0000-0002-1067-3976>

## REFERENCES

- Andersson LS, Axelsson J, Dubielzig RR, Lindgren G, Ekesten B. Multiple congenital ocular anomalies in Icelandic horses. *BMC Vet Res.* 2011;7:21.
- Gemensky-Metzler AJ, Wilkie DA, Cook CS. The use of semiconductor diode laser for deflation and coagulation of anterior uveal cysts in dogs, cats and horses: a report of 20 cases. *Vet Ophthalmol.* 2004;7:360–8.
- Hurn SD, Turner AG. Ophthalmic examination findings of thoroughbred racehorses in Australia. *Vet Ophthalmol.* 2006;9:95–100.
- Paschalis-Trela K, Cywińska A, Trela J, Czopowicz M, Kita J, Witkowski L. The prevalence of ocular diseases in polish Arabian horses. *BMC Vet Res.* 2017;13:1–8.
- Ramsey DT, Ewart SL, Render JA, Cook CS, Latimer CA. Congenital ocular abnormalities of Rocky Mountain horses. *Vet Ophthalmol.* 1999;2:47–59.
- Barnett KC, Crispin SM, Lavach JD, Matthews AG. *Color atlas and text of equine ophthalmology.* 2nd ed. London, England: Elsevier Inc; 2004. p. 184–91.



7. Gilger BC. Equine ophthalmology. 3rd ed., John Wiley & Sons Inc; 2016;374–5.
8. Crispin SM. Developmental anomalies and abnormalities of the equine iris. *Vet Ophthalmol.* 2000;3:93–8.
9. Brooks DE. Corpora nigra/iris cysts in the horse. *Equine Vet. Educ.* 2007;19:512–4.
10. Byam-Cook KL, Knottenbelt DC. Recurrent corneal ulceration secondary to an iris cyst. *Equine Vet Educ.* 2007;19:508–11.
11. Carastro SM. Equine ocular anatomy and ophthalmic examination. *Vet Clin North Am - Equine Pract.* 2004;20:285–99.
12. Gilger BC, Davidson MG, Nadelstein B, Nasisse M. Neodymium:yttrium-aluminum-garnet laser treatment of cystic granula iridica in horses: eight cases (1988–1996). *J Am Vet Med Assoc.* 1997;211:341–3.
13. Deehr AJ, Dubielzig RR. A histopathological study of iridociliary cysts and glaucoma in Golden retrievers. *Vet Ophthalmol.* 1998;1:153–8.
14. Barnett KC, Platt H. Intraocular melanomata in the horse. *Equine Vet J.* 1990;22(S10):76–82.
15. Myrna K, Sheridan C. Melanocytic ocular and periocular tumours of the horse. *Equine Vet. Educ.* 2019;31:410–2.
16. Scotty NC, Barrie KB, Brooks DE, Taylor D. Surgical management of a progressive iris melanocytoma in a mustang. *Vet Ophthalmol.* 2008;11:75–80.
17. Sidoti PA, Valencia M, Chen N, Baerveldt G, Green RL. Echographic evaluation of primary cysts of the iris pigment epithelium. *Am J Ophthalmol.* 1995;120:161–7.
18. Toth J, Buijs L. Erfahrungen mit der Therapie von Iriszysten mittels Laserzystotomie und Reduktion von vergrößerten Traubenkörnern beim Pferd mit einem Nd:YAG-Laser. *Prakt Tierarzt.* 2018;99:1276–85.
19. Blacklock BT, Grundon RA, Meehan M, Tetas Pont R, Hartley C. Uveal cysts in domestic cats: a retrospective evaluation of thirty-six cases. *Vet Ophthalmol.* 2016;19:56–60.
20. Gialletti R, Marchegiani A, Valeriani T, Nannarone S, Beccati F, Fruganti A, et al. A survey of ocular ultrasound abnormalities in horse: 145 cases. *J Ultrasound.* 2018;21:53–9.
21. Berger JM, Bell SA, Holmberg BJ, Madigan JE. Successful treatment of head shaking by use of infrared diode laser deflation and coagulation of corpora nigra cysts and behavioral modification in a horse. *J Am Vet Med Assoc.* 2008;233:10–2.
22. Georgalas I, Petrou P, Papaconstantinou D, Brouzas D, Koutsandrea C, Kanakis M. Iris cysts: a comprehensive review on diagnosis and treatment. *Surv Ophthalmol.* 2018;63:347–64.
23. Gywat L, Keller M, Gutzwiller A, Daicker B, Brücken R. Operative Entfernung einer Iriszyste beim Pferd. *Schweiz Arch Tierheilk.* 1988;130:673–80.
24. Mustikka MP, Pietilä EM, Mykkänen AK, Grönthal TSC. Comparison of two rebound tonometers in healthy horses. *Vet Ophthalmol.* 2020;23:892–8.
25. Knollinger AM, La Croix NC, Barrett PM, Miller PE. Evaluation of a rebound tonometer for measuring intraocular pressure in dogs and horses. *J Am Vet Med Assoc.* 2005;227:244–8.
26. Pumphrey SA, Pizzirani S, Pirie CG, Needle DB. Glaucoma associated with uveal cysts and goniodysgenesis in American bulldogs: a case series. *Vet Ophthalmol.* 2013;16:377–85.
27. Rao A, Gupta V, Bhadange Y, Sharma R, Shields JA. Iris cysts: a review. *Semin Ophthalmol.* 2011;26:11–22.

### SUPPORTING INFORMATION

Additional supporting information may be found in the online version of the article at the publisher's website.

**How to cite this article:** Stas EKL, Hermans H, Slenter IJM, Veraa S, Ensink JM. Noninvasive diode laser—an effective and safe treatment of iris cysts in 46 eyes of 35 horses. *Equine Vet J.* 2023;55(2):205–13. <https://doi.org/10.1111/evj.13590>