

Long-term ophthalmologic examinations of eyes with equine recurrent uveitis after pars plana vitrectomy

Eva I. A. Baake¹, Myriam von Borstel¹, Karl Rohn², Michael H. Boevé¹ and Bernhard Ohnesorge¹

Clinic for Horses¹ and Institute for Veterinary Biometry and Epidemiology², University of Veterinary Medicine Hannover, Foundation, Hannover, Germany

Summary: Equine recurrent uveitis (ERU) is an ocular disease in horses of different breeds with a prevalence between 2.7 and 7.6% in Europe and vitrectomy is a common method of treatment. The objective of the study was to evaluate the long-term retention of vision and control of uveitis after pars plana vitrectomy performed between 2005 and 2013 on eyes with a history of equine recurrent uveitis (ERU). Vitrectomy in eyes with ERU can influence the recurrent nature of the disease. Previous studies indicated success rates regarding the further absence of uveitis between 73.6 and 97.7%. Owners of the horses were contacted and an ophthalmological reexamination including tonometry, induction of mydriasis, slit lamp biomicroscopy and direct ophthalmology was performed in 116 horses (147 eyes vitrectomized). Visual acuity was examined by the dazzle reaction and the menace response. Aspects such as gender, age and breed of the horses, as well as leptospiral status and preexisting damage of operated eyes are described. A total of 246 eyes were accessible for follow-up information, whereas 147 eyes were available for ophthalmologic reexaminations. If only the reexamined eyes are considered, an improvement of the condition was seen in 133 eyes (91%) and 14 eyes (9%) showed at least one uveitic recurrence after vitrectomy. A positive menace response and a positive dazzle reaction were observed in 128 of the 147 reexamined eyes (87%). The number of episodes prior to vitrectomy, the gender of the horse and the leptospiral status of the eye showed no significant correlation with the prevalence of recurrences. Coat color, breed and age of the horse operated, and preexisting ocular alterations showed a significant influence on the chance of postoperative recurrences of uveitis. Horses with a coat color other than “chestnut” and “black and brown” had significantly more recurrences and odds ratio for these horses developing recurrences was also significantly higher. The present study shows that a large number of reexamined eyes remained visual (87%) and a large proportion of the eyes (91%) showed an improvement of the condition after vitrectomy. Results of this study suggest that genetic factors, age and preexisting ocular alterations influence the long-term prognosis of eyes with ERU after vitrectomy.

Keywords: eye, uveitis, vitrectomy, equine recurrent uveitis, ERU, leptospores, horse, equine

Citation: Baake E. I. A., von Borstel M., Rohn K., Boevé M. H., Ohnesorge B. (2019) Long-term ophthalmologic examinations of eyes with equine recurrent uveitis after pars plana vitrectomy. *Pferdeheilkunde* 35, 220–233; DOI 10.21836/PEM20190303

Correspondence: Dr. Eva I. A. Baake, University of Veterinary Medicine Hanover, Clinic for horses, Buenteweg 9, 30559 Hanover, Germany; eva.ingrid.agnes.baake@gmail.com

Submitted: April 1, 2019 | **Accepted:** April 15, 2019

Introduction

Equine recurrent uveitis (ERU) is an ocular disease in horses of different breeds with a prevalence between 2.7 and 7.6% in Europe (Alexander und Keller 1990, Szemes and Gerhards 2000). Recurrent episodes of intraocular inflammation are painful, can lead to chronic damage to ocular structures and, hence, impair vision sooner or later (Angelos et al. 1988, Gerhards and Wollanke 2001, von Borstel et al. 2005, Wollanke and Gerhards 2009). The impact of ERU on affected horses and their owners regarding the impairment of vision, the loss of use and the financial loss is significant (Gerding and Gilger 2016). The immediate therapeutic target during an acute episode of ocular inflammation is to control the pain and keep the damage to intraocular structures as little as possible by minimizing the ocular inflammation immediately. This can be accomplished by using local mydriatic cycloplegics, topical corticosteroids and systemic nonsteroidal anti-inflammatory drugs. In addition to the acute therapy, only the prevention of future recurrences can effectively prevent further intraocular damage (Curling 2011). In addition to enucleation, vitrectomy, the implantation of a cyclosporine drug delivery device and intravitreal injection of a low-dose gentamicin are currently the only

therapeutic modalities that may prevent recurrences (Werry and Gerhards 1991, Werry and Gerhards 1992, Winterberg and Gerhards 1997, Frühauf et al. 1998, Gilger and Allen 1998, von Borstel et al. 2005, Gilger et al. 2010, Tömördy et al. 2010, Dorrego-Keiter et al. 2017, McMullen 2015, Kleinpeter et al. 2019, Fischer et al. 2019).

Equine recurrent uveitis is categorized into three different clinical subtypes in literature: The “classic ERU,” the “posterior ERU” and the “insidious ERU.” If horses show acute and painful episodes of intraocular inflammation affecting posterior and anterior parts of the eye, with recurrence after non-inflammatory episodes, ERU is considered to be the “classic ERU.” If intraocular inflammation is primarily affecting the vitreous body, choroid and retina, it is considered to be “posterior ERU.” This type of ERU is seen mostly in Warmbloods, draught breed horses and horses imported from Europe to the USA. “Insidious ERU” is characterized as a mild and almost painless intraocular inflammation, regularly seen in the Appaloosa and draft horses in the USA (Gilger 2010).

Vitrectomy (single port, double port) in equine eyes suffering from ERU has been performed in Europe for more than two decades. During vitrectomy, the vitreous and the inflamma-

tory debris it contains is mostly replaced by a buffered salt solution with glutathione, sodium bicarbonate and glucose¹², mixed with gentamicin¹⁴ (Werry and Gerhards 1991, Werry and Gerhards 1992, Frühauf et al. 1998, von Borstel et al. 2005). Initially, vitrectomy was expected to reduce and alleviate recurrences, but not to prevent them entirely (Werry and Gerhards 1991). It was shown subsequently that vitrectomy was able to alter the recurrent nature of the disease in most cases and, therefore, prevent additional ocular pain and damage to intraocular structures (Werry and Gerhards 1992, Winterberg and Gerhards 1997, Frühauf et al. 1998). In addition to preservation of vision, it has been implemented in the literature over the years that the vitrectomy is only deemed successful when no uveitic recurrences occur postoperatively (von Borstel et al. 2005, Tömördy et al. 2010).

Seven studies have been published regarding the long-term prognosis after vitrectomy since 1991 (Werry and Gerhards 1992, Winterberg and Gerhards 1997, Frühauf et al. 1998, von Borstel et al. 2005, Tömördy et al. 2010, Dorrego-Keiter et al. 2017, Schinagl 2017). No recurrences of uveitic symptoms were recognized in these studies in a range between 73.6 (Tömördy et al. 2010) and 97.7% (Winterberg and Gerhards 1997) of the eyes evaluated. These variations may be due to different patient populations, operating methods, periods between the surgery and the follow-up, or variations in study design. The aim of the current study was to provide a differentiated long-term prognosis based mainly upon ophthalmologic reexaminations and depending on gender, age and breed of each horse, the leptospiral status and preexisting alterations in eyes that underwent a double-port pars plana vitrectomy.

Materials and methods

A total of 284 eyes from 235 horses were vitrectomized between 2005 and 2013 at the equine clinic of the University of Veterinary Medicine of Hannover. Signalment and clinical data were collected from medical records.

Study population

All horses had a clinical history of at least two uveitic episodes of unknown etiology according to the referring veterinarian. A complete ophthalmologic examination was performed by a German veterinarian specialist for ophthalmology, including slit lamp biomicroscopy, direct ophthalmoscopy and tonometry in the clinic for horses prior to the vitrectomy to evaluate the extent of ocular changes and the current inflammatory status of the eye to determine the indication for vitrectomy. Mydriasis was performed in every patient for the preoperative examination. Vitrectomy was only performed in eyes without any signs of active intraocular inflammation.

Horses were stabled two days prior to the vitrectomy. Preoperative topical treatment consisted of ophthalmic ointment containing dexamethasone, neomycin and polymyxin B¹ eight times a day and atropine ophthalmic drops² (0.5%, q. 12 h). Horses were held off feed for about 6 h prior to the vitrectomy. Flunixin-meglumine³ was administered intravenously in a dosage of 1.1 mg per kg body weight approximately 1 h prior

to the surgery. In addition, sulfadimethoxine and trimethoprim⁴ was administered orally in a combined dosage of 20 mg per kg body weight about 3 h prior to the surgery.

Surgical procedure

Horses were placed under general anesthesia in lateral recumbency with the affected eye facing up. The eyelashes were cut and the nasolacrimal duct and the conjunctival sac were flushed with a mild antibacterial solution containing sodium chloride, sodium mono- and dihydrogen phosphate and benzalkonium chloride⁵, subsequently, with a 1% povidone-iodine solution and, finally, with saline solution mixed with gentamicin⁶ (4 mg/ml) (Frühauf et al. 1998, von Borstel et al. 2005). The eye was surgically draped and an eye speculum was used to open the eyelids. A conjunctival flap was prepared to expose the sclera 11 to 13 mm from the limbus at the area of the pars plana ciliaris with the base of the flap away from the limbus (Werry and Gerhards 1991, von Borstel et al. 2005). Two intrascleral cruciate sutures⁷ were preplaced at the sclerotomy site at the 11 and 1 o'clock position to allow a fast closure after removal of instruments (Frühauf et al. 1998, von Borstel et al. 2005). A lancet-shaped blade was used to prepare the two transscleral ports to enable a double-port vitrectomy (Werry and Gerhards 1992, von Borstel et al. 2005). The temporal sclerotomy was used as an irrigation port. The vitrectomy handpiece⁸ of an oscillating vitrector was entered into the vitreous cavity through the nasal sclerotomy port. An indirect binocular ophthalmoscope⁹ was used to visualize the vitrectomy tip through the dilated pupil to control the vitrectomy procedure (Frühauf et al. 1998, von Borstel et al. 2005). All accessible vitreal material, especially uveitic effusions, was aspirated and replaced by buffered saline solution¹⁰ mixed with gentamicin⁶ (160 µg/ml). The vitreous cavity was flushed with 250 to 500 ml of the flushing solution, depending on the amount of vitreal material that needed to be removed. Both sclerotomies were closed immediately with the two preplaced intrascleral cruciate sutures after the removal of the vitrectomy handpiece and irrigation port. The conjunctiva was closed with a continuous suture¹¹ and 40 mg of gentamicin⁶ and 4 mg of dexamethasone¹² were injected into the ventral subconjunctiva (von Borstel et al. 2005).

Vitrectomized eyes were reevaluated every day during hospitalization by slit lamp biomicroscopy and direct ophthalmoscopy. In straightforward cases, topical therapy with ophthalmic ointment containing dexamethasone, neomycin and polymyxin B¹ was conducted q. 3 h for five days postoperatively, q. 6 h for another seven days and q. 8 h for another 14 days subsequently at the home stable. Oral flunixin-meglumine¹³ therapy was continued until one day postoperatively at the full dosage (1.1 mg/kg body weight q. 12 h) and the second and third day postoperatively at the half dosage (0.55 mg/kg body weight q. 12 h). Sulfadimethoxine and trimethoprim⁴ were administered for four days (20 mg/kg q. 12 h).

Vitreous samples were obtained during the first few seconds after the start of the vitrectomy via the specimen collection vial of the vitrectomy system. Vitreous material was immediately sent to an external laboratory¹⁴ to perform a microscopic agglutination test (MAT) for intraocular leptospiral antibodies

and a polymerase chain reaction (PCR) detecting leptospiral DNA. A total of 254 vitreous samples were available for MAT and PCR.

Intra- and postoperative complications

Intra- and postoperative complications throughout hospitalization were documented and evaluated.

Contacting for reexamination

Owners were contacted by telephone and interviewed for the current study with the aid of a standardized questionnaire. They were asked about the postoperative clinical course of the vitrectomized eye/eyes, whether any signs of ocular inflamma-

tion or other ocular problems had been noticed and/or may have been diagnosed by a veterinarian. Three different options were used to differentiate between possible outcomes: free of complaints (FOC), recurrences (REC) or non-specific ocular inflammatory symptoms (NOIS), such as conjunctivitis or keratitis (Table 1). After answering the questionnaire, the owners were offered an ophthalmologic checkup of their horse at their home stable.

The ophthalmologic examination was performed by a veterinarian (first author) trained by a German veterinarian specialist of ophthalmology, and by an ECVO-certified ophthalmologist. A complete ophthalmologic examination was executed to evaluate the vitrectomized eyes for the current study and included tonometry, induction of mydriasis using tropicamide¹⁵, slit lamp biomicroscopy and direct ophthalmoscopy. The findings were documented and an ERU score established previ-

Table 1 Possible postoperative outcomes after the vitrectomy | *Mögliche postoperative Ergebnisse nach der Vitrektomie*

postoperative progression of ERU	abbreviation
signs of ocular inflammation, similar to the episodes prior to the vitrectomy	REC (recurrence of uveitis)
mild signs of ocular inflammation, not comparable to the episodes prior to the vitrectomy (e.g. epiphora, chemosis, due to conjunctivitis, keratitis)	NOIS (non-specific ocular inflammatory symptoms)
no signs of ocular inflammation	FOC (free of complaints)

} IMP (improvement)

Table 2 Score for chronic uveitis findings of the most affected ocular compartments (Score by M. von Borstel [18, 19]) | *Score für chronische Uveitis-Befunde der am meisten betroffenen Augenabschnitte*

score	iris	lens	vitreous	fundus oculi	other chronic changes
0	no abnormality detected	no abnormality detected	no abnormality detected	no abnormality detected	no abnormality detected
1	low-grade depigmentation; focal small synechia	focal capsular cataract; focal iris residues	low-grade liquefaction with several floating filamentous strands of cell debris and inflammatory products	single focal chorioretinopathy („bullet hole lesion“)	low-grade reduction in size of the bulb/reduction in size of the anterior chamber
2	low-grade depigmentation; focal large-scale synechia	multifocal capsular/subcapsular cataract; local bullous subcapsular/cortical cataract; multifocal iris residues	low-grade liquefaction; several curtain-like strands of cell debris and inflammatory products	a few focal chorioretinopathies („bullet hole lesion“); small-area peripapillary chorioretinopathy („butterfly lesion“)	moderate reduction in size of the bulb/reduction in size of the anterior chamber; local corneal haze
3	moderate depigmentation; several focal synechia	local reticular capsular/subcapsular cataract; local immature corticale/nuclear cataract	moderate liquefaction; moderate curtain-like strands of cell debris and inflammatory products; low grade diffuse yellow haze	multiple focal chorioretinopathies; large-scale peripapillary chorioretinopathy	low-grade bulb enlargement of the anterior; laminar corneal haze; low-grade increase in intraocular pressure
4	moderate depigmentation; atrophy; circular synechia	diffuse immature capsular/subcapsular/cortical and/or nuclear cataract; lens subluxation	high-grade liquefaction; moderate curtain-like strands of cell debris and inflammatory products; moderate diffuse yellow haze	laminar chorioretinopathies/laminar degeneration of the retina; peripapillary wrinkles of the retina; partial retinal detachment	moderate bulb enlargement/enlargement of the anterior chamber; laminar corneal haze/haab's striae; moderate increase in intraocular pressure
5	high-grade depigmentation; seclusio pupillae	mature/hypermature cataract; lens luxation	high-grade liquefaction; high-grade visible strands of cell debris and inflammatory products; high-grade diffuse yellow haze	complete retinal detachment	high-grade bulb enlargement/enlargement of the anterior chamber; laminar corneal haze/haab's striae; high-grade increase in intraocular pressure; phthisis bulbi

ously was used to estimate the status of each eye. The score was applied for different ocular compartments (iris, lens, vitreous and fundus oculi) and for other chronic changes and resulted in a total score for each eye. Values ranged from zero (no abnormality detected) to five (high-grade abnormalities) (Table 2) (von Borstel et al. 2010, Kulbrock et al. 2013b). This score system was also applied retrospectively to acquire a preoperative score for each eye based on examinations documented before the vitrectomy.

Statistical evaluation

Statistical analysis was performed with the SAS Enterprise Guide 7.1¹⁶. The binomial distribution was used to assess the age distribution among the horses vitrectomized. Fisher’s ex-

act test was used to evaluate the frequency of distribution in the group of horses vitrectomized between 2005 and 2013 and the patient population in the clinic for horses during the same period. Since not all vitrectomized eyes were available for follow-up information, two distinct groups were created to further specify and verify information. One group consisted of all horses with follow up information (A) and one only of the horses with ophthalmologic reexaminations (B). Fisher’s exact test and the chi-squared test were used to evaluate the dependence of various characteristics on the frequency of REC and NOIS. The group NOIS was tested combined with REC against FOC and was tested combined with FOC against REC. The Wilcoxon signed-rank test was performed to evaluate the trends between the height of the pre- and postoperative ERU scores. Odds ratios were used to estimate the influence of leptospiral antibodies and leptospiral DNA detectable on the appearance of REC and NOIS.

Table 3 Gender, breed and coat color distribution of the vitrectomized horses and the patient population of the clinic for horses between 2005 and 2013 | Geschlechts-, Rassen- und Fellfarbenverteilung der vitrektomierten Pferde und der Patientenpopulation der Klinik für Pferde zwischen 2005 und 2013

	vitrectomized horses		patient population, clinic for horses University of Veterinary Medicine Hannover
gender	n	(%)	(n/%)
mares	102	(43)	(6827/53)
geldings	109	(46)	(4341/34)
stallions	24	(10)	(1749/14)
female	102	(43)	(6827/53)
male	133	(56)	(6090/47)
breed	n	(%)	(n/%)
Warmbloods	123	(52.3)	(7941/62.1)
Icelandic horses	32	(13.6)	(584/4.6)
ponies	29	(12.3)	(1492/11.7)
Frisian horses	10	(4.3)	(325/2.5)
Trotters	9	(3.8)	(138/1.1)
Pura Raza Espanola	7	(3)	(154/1.2)
Quarter horse / paint	6	(2.6)	(408/3.2)
Arabic horses	5	(2.1)	(457/3.6)
Knabstruppers	3	(1.3)	(24/0.2)
Thoroughbred	3	(1.3)	(503/3.9)
Pinto	1	(0.4)	(50/0.4)
others	7	(3)	(711/5.5)
coat color	n	(%)	(n/%)
black & brown ⁺	135	(57)	(5513/50)
others ⁺⁺	53	(23)	(3077/28)
chestnut	47	(20)	(2527/22)

*p < 0.05, **p < 0.01, ***p < 0.001 (fisher’s exact test); + brown, black-brown, black; ++gray, dappled, others, undocumented

Results

Patient population

The retrospective patient population was composed of various breeds and comprised 102 mares (124 eyes), 109 geldings (132 eyes) and 24 stallions (28 eyes). The major proportion of the vitrectomized horses were colored “black and brown” (57%) (Table 3). Most horses were between four and seven years old (106/235) at the time of vitrectomy of the first eye (Table 4).

Horses with an age between four and seven years old were significantly overrepresented compared to every other age group (p ≤ 0.0001) (Table 4). Compared to the patient population in the clinic for horses between 2005 and 2013, vitrectomy was significantly more often performed in male than in female horses (males: p = 0.0037; geldings: p = 0.0049; stallions: p = 0.0001) and significantly more often in Icelandic horses (p ≤ 0.0001), Friesian horses (p = 0.0411), Trotters (p = 0.0004), Pura Raza Española (p = 0.0118) and Knabstruppers (p = 0.0061) than in Warmbloods (Table 3). More than half of the horses vitrectomized were Warmbloods (52.3%, 123/235). The most frequent coat color among the horses vitrectomized in this study was “black and brown” and these were vitrectomized significantly more often than horses with the coat color “other” (p = 0.031), when compared to

Table 4 Age distribution of the vitrectomized horses | Altersverteilung der vitrektomierten Pferde

age group	age in years	n	(%)
1	0–3	27	(11,5%)
2	4–7	106	(45,1%)
3	8–11	47	(20%)
4	12–15	33	(14%)
5	16–19	15	(6,4%)
6	20–23	6	(2,6%)
7	24–27	1	(0,4%)
8	≥28	0	(0%)

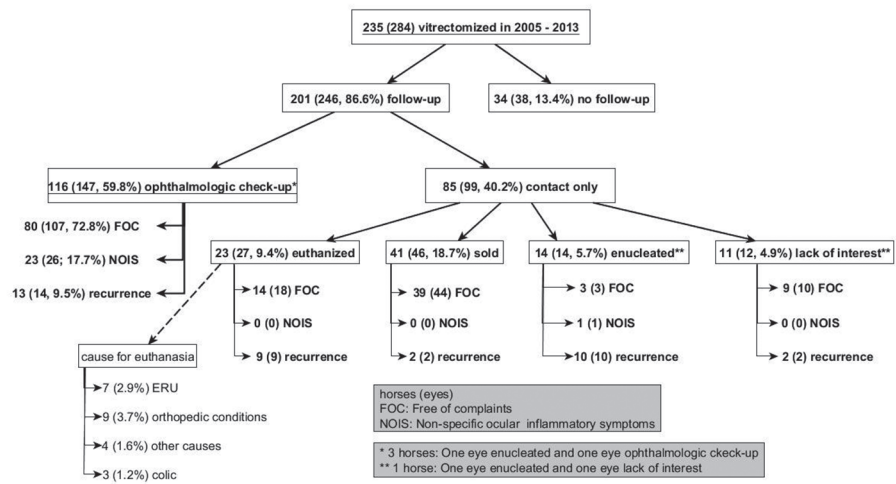


Fig. 1 Overview of the horses and eyes available for follow-up and for ophthalmologic check-up | Übersicht über die Pferde und Augen, die kontaktiert und zur ophthalmologischen Untersuchung zur Verfügung standen

the patient population of the equine clinic in the same time period (Table 3).

Intra- and postoperative complications

The most common intraoperative complication documented was leakage from one of the sclerotomy sites, this complication was documented in 3 of 284 surgeries. A loss of intraocular pressure and a partial detachment of the retina was documented in one each of 284 surgeries. The most frequent postoperative complication documented after the vitrectomy was corneal ulceration/erosion in varying degrees; a total of 21 eyes from 21 horses was affected. A total of 4 eyes showed a progression of cataract a few days after surgery. A postoperative partial detachment of the retina was documented in 2 of 284 vitrectomized eyes and a total retinal detachment was documented after the surgery in 3 of 284 eyes.

Follow-up

Follow-up information of 201 horses (246 eyes vitrectomized) was available either through contacting the owner, through later hospitalizations and/or an ophthalmologic checkup at the home stable performed as described on 116 horses (147 eyes) (Fig. 1).

Active uveitis was seen in 5 of the 14 eyes with REC. The most common manifestations were endothelial/keratic precipitates and aqueous flare. Other clinical signs, such as blepharospasm, epiphora and conjunctival hyperemia, were also observed. However, 9 of the 14 eyes that were categorized as REC did not show any signs of active uveitis at all; in these cases the diagnosis was based upon the owners' reports of REC throughout the last years/months.

The median time between vitrectomy and follow-up was 64 months (minimum 17 months, maximum 123 months, mean time 63.5 months). Looking only at the reexamined eyes, 73% (107/147) of them showed no signs of uveitis or other ocular inflammation or problems at all (FOC). Mild signs of ocular inflammation not comparable to the episodes prior to the vitrectomy, such as keratitis or conjunctivitis (NOIS), were shown by 18% (26/147) of the eyes. An improvement

of the condition was achieved in 91% (133/147) of the eyes (IMP), whereas 9% (14/147) of the eyes showed signs of ocular inflammation similar to the episodes prior to the vitrectomy (REC). Considering all the eyes where information was available, 74% (182/246) were FOC and 11% (27/246) were categorized as NOIS, therefore, 85% (209/246) of the eyes were categorized as IMP, while REC was shown in 15% (37/246) of the eyes. No significant differences between the follow-up group (A) and the ophthalmologic checkup group (B) could be shown (Fig. 2).

Stratification

Because not all the vitrectomized horses were available for follow-up information, the information available was stratified for different factors that could not affect the outcome of the vitrectomized eyes. This was carried out to verify the success rates concerning the absence of uveitic symptoms after the vitrectomy.

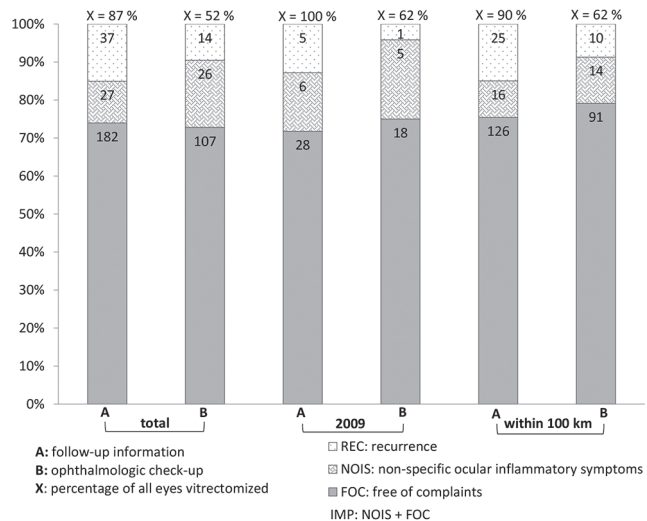


Fig. 2 Number of eyes categorized as "FOC" (free of complaints), "NOIS" (non-specific ocular inflammatory symptoms) and "REC" (recurrence of uveitis), stratified by year and two different radii around the clinic | Anzahl der Augen, klassifiziert als „FOC“ (beschwerdefrei), „NOIS“ (unspezifische okuläre Entzündungssymptome) und „REC“ (Wiederauftreten der Uveitis), nach Jahr und zwei verschiedenen Radien um die Klinik herum geschichtet

This group of eyes was used for stratification because 100% of the horses vitrectomized from the year 2009 (n = 39) were available for follow-up information (Fig. 2).

In addition, the owner’s place of residence was used to further stratify the follow-up information. A radius of 100km (90% follow-up rate) around the clinic was used. No significant differences could be shown between both stratifications (total vs. 2009 and within 100 km) or between the ophthalmologic checkup group (B) and the follow-up and ophthalmologic checkup group (A).

ERU Score

All reexamined eyes were scored with the ERU score (Table 1). This post-vitrectomy score was compared to the pre-vitrectomy score, which was based on the examinations documented prior to the vitrectomy. The Wilcoxon signed-rank test showed no significant differences between the total score from pre- (2.8 ± 1.1) to post-vitrectomy (2.9 ± 1.2) for the re-examined eyes (B). The lens score increased significantly from pre- (1.5 ± 1.1) to post-vitrectomy (2.8 ± 1.3), whereas the vitreous score decreased significantly from pre- (2.5 ± 1.3) to post-vitrectomy (1.7 ± 1.7). All other compartments showed no significant changes from pre- to post-vitrectomy.

Sight

A negative dazzle reaction combined with a negative menace response was observed in 4% (6/147) and a positive dazzle reaction combined with a negative menace response was observed in 9% (13/147) of the eyes reexamined (B). One of the six eyes with a negative dazzle reaction and a negative menace response had a fundus score of 5, which was defined as a complete retinal detachment, and the other five horses had a lens score of 5, which was defined as a mature or hypermature cataract or a lens luxation (Table 1).

The group of eyes with a positive dazzle reaction combined with a negative menace response had four eyes with a lens score of 4 (diffuse immature capsular/subcapsular/cortical and/or nuclear cataract; lens subluxation), eight eyes with a lens score of 5 and one eye with a fundus score of 4 (laminar chorioretinopathies/laminar degeneration of the retina; peripapillary wrinkles of the retina; partial retinal detachment).

Number of uveitis episodes

The number of uveitis episodes pre-vitrectomy did not influence the occurrence of REC significantly.

Gender, breed, coat color, age

The gender did not influence the rate of REC significantly (p > 0.05). Overall, 17% of the female eyes showed REC (18/103) and 83% of the female eyes improved after the vitrectomy (IMP: 85/103; FOC: 68/103, NOIS: 17/103). The

number of REC was 13% (19/143) in vitrectomized eyes of male horses and 87% of the eyes of male horses improved after the vitrectomy (IMP: 124/143; FOC: 114/143; NOIS: 10/143).

All Knabstrappers (3/3) in the present study showed REC and were, therefore, excluded from the further statistics. The breed did not influence the rate of REC significantly (p > 0.05).

Significantly more REC were noticed in the eyes of horses with the coat color “other” (12/55, 22%) compared to the eyes of horses with a “black and brown” coat color (15/141, 11%) (p = 0.0264). The coat color “other” included horses with the coat colors gray, dappled and undocumented colors and the breed, Knabstrappers being excluded from the statistics, did not influence the rate of recurrences significantly.

Older horses tended to have more REC than younger horses. Horses older than 20 years showed a significantly higher number of eyes with REC compared with horses aged four to seven years (p = 0.0477) (Fig. 3).

ERU score and time point of recurrence

The higher the preoperative ERU score, the higher the rate of REC. Eyes with a total score of three and five had significantly more REC than horses with a score of two (p = 0.0112, p = 0.0212, respectively) (Fig. 4).

The mean time between the vitrectomy and the first REC was 12.8 (± 22.8) months. The latest onset of REC was 95 months after the vitrectomy; this was observed in two eyes. A total of 17 REC (6.9%) were noticed during the first two months. Six REC occurred between the third and the sixth month post-vitrectomy. The Kaplan-Meier value showed that the probability of a non-recurrence of intraocular inflammation after vitrec-

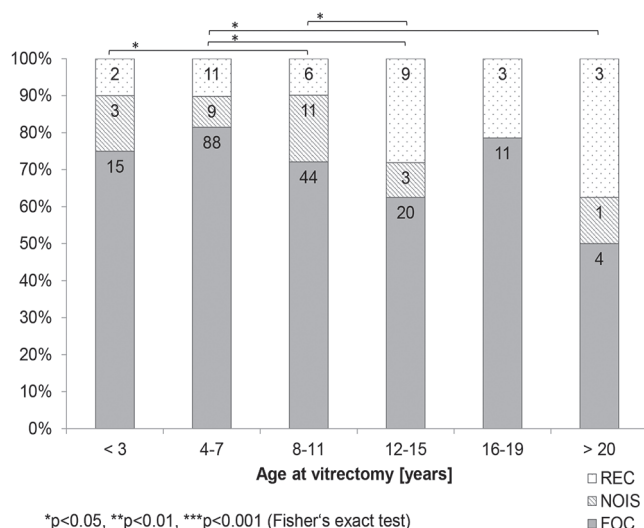


Fig. 3 Number of eyes with “FOC” (free of complaints), “NOIS” (non-specific ocular inflammatory symptoms) and “REC” (recurrence of uveitis) by age at vitrectomy | Anzahl der Augen mit „FOC“ (beschwerdefrei), „NOIS“ (unspezifische okuläre Entzündungssymptome) und „REC“ (Wiederauftreten der Uveitis) nach Alter bei der Vitrektomie

tomy decreased over time. The highest decrease happened during the first two months. After 20 months, the probability seemed to reach a plateau, which dropped down again after about 50 months. After 123 months, the probability of a non-recurrence was 80.79% (Fig. 5).

Leptospiral status

Horses younger than three years were significantly more often leptospiral-positive than horses aged 12 to 15 years ($p=0.0176$) and older than 20 years ($p=0.0014$) (Fig. 6). The color distribution showed no significant differences between the age groups.

Leptospiral-negative eyes (16/98, 16%) did not show significantly more recurrences than leptospiral-positive eyes (13/121, 11%).

The odds ratio of developing REC after a vitrectomy was higher (not significantly) for leptospiral-negative eyes (OR: 1.925, CI: 0.8988, 4.1228). Horses where a serovar other than serovar Grippotyphosa was detected, had a higher odds ratio

of developing REC than horses where serovar Grippotyphosa was detected (OR: 2.1667, CI: 0.6065, 7.7407). The odds ratio of developing REC was also higher for Warmbloods when the eyes were leptospiral-negative (OR: 2.087, CI: 0.6945, 6.2713). Icelandic horses had a higher odds ratio of developing REC than Warmbloods (OR: 1.4637, CI: 0.5289, 4.0504). None of the latter odds ratios were significant. The odds ratio was significantly higher of developing REC for the coat color "other" than for the coat colors "chestnut" or "black and brown" (OR: 2.6321, CI: 1.2596, 5.5003) (Fig. 7).

The outcome of the vitrectomy regarding the absence of recurrent episodes (REC) was tested for Warmbloods and Icelandic horses depending upon the leptospiral status of the vitrectomized eyes.

The rate of IMP (improvement) was 88% (121/137) for all Warmblood horses and 84% (31/37) for all Icelandic horses. When only leptospiral-positive eyes were included, the rate of IMP was lower (79%) for Icelandic horses (15/19) than for Warmblood horses (64/70; 91%). This difference was not significant ($p=0.999$).

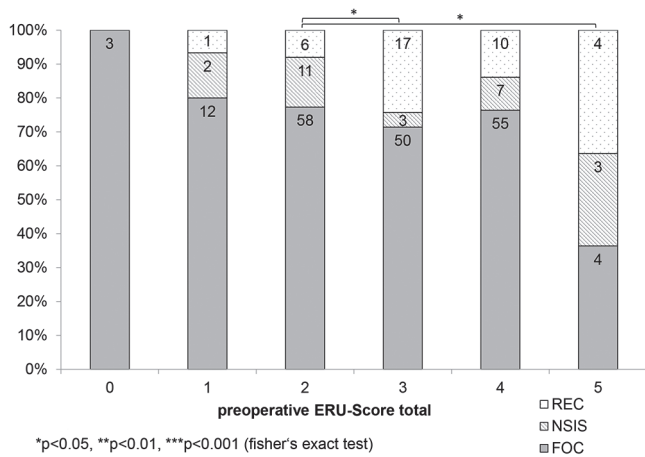


Fig. 4 Number of eyes with FOC" (free of complaints), "NOIS" (non-specific ocular inflammatory symptoms) and "REC" (recurrence of uveitis) by ERU-score at vitrectomy | Anzahl der Augen, klassifiziert als „FOC“ (beschwerdefrei), „NOIS“ (unspezifische okuläre Entzündungssymptome) und „REC“ (Wiederauftreten der Uveitis), nach ERU-Score bei der Vitrektomie

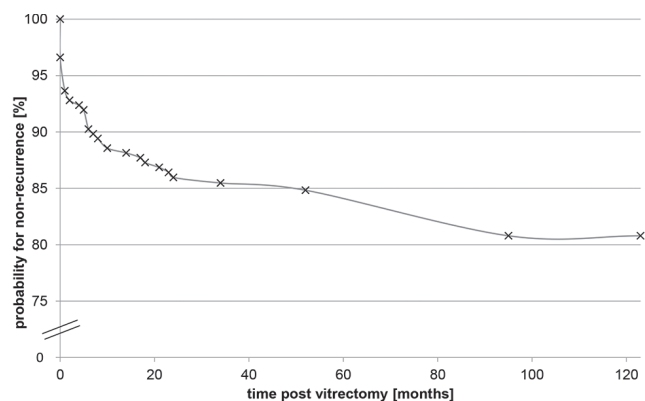


Fig. 5 Kaplan-Meier estimation of the probability for non-recurrence after vitrectomy | Kaplan-Meier-Schätzung der Wahrscheinlichkeit eines Nicht-Wiederauftretens nach Vitrektomie

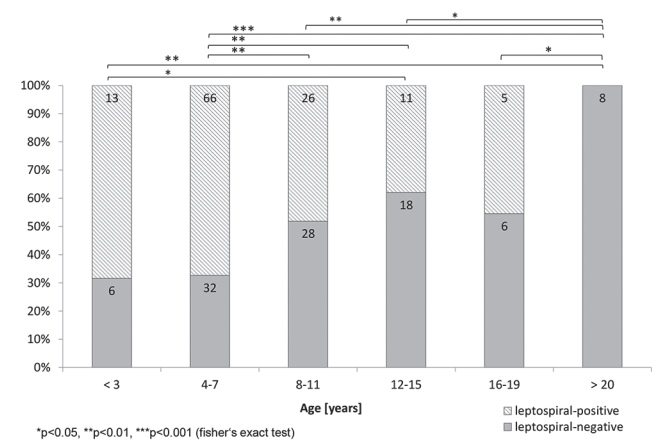


Fig. 6 Distribution of leptospiral-positive and leptospiral-negative eyes between different age groups | Verteilung der leptospiren-positiven und leptospiren-negativen Augen zwischen verschiedenen Altersgruppen

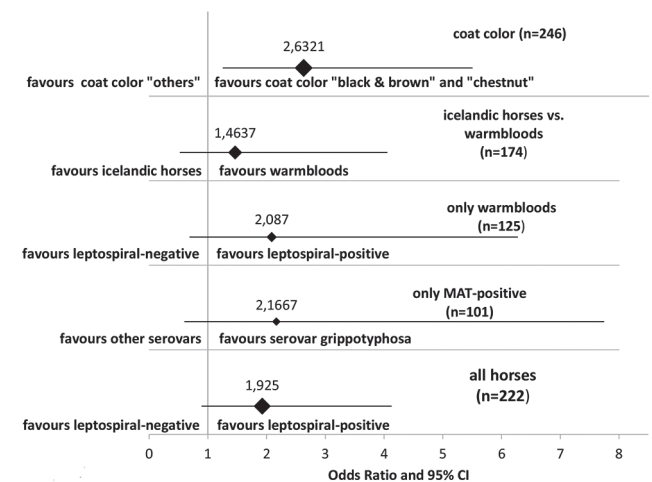


Fig. 7 Forest diagram showing the odds ratios of having a "REC" (recurrence of uveitis) between different stratifications | Forest Diagramm, das die Quotenverhältnisse eines "Rezidivs" (Wiederauftreten der Uveitis) zwischen verschiedenen Schichten zeigt

Discussion

Follow-up surveys are the only way to provide a prognosis for horses with ERU that are going to have a vitrectomy. It is in the nature of follow-up surveys that not all subjects are available for follow-up information, and even fewer are available for follow-up examinations. Therefore, the rates for non-recurrence of uveitic symptoms in literature ranged between 73.6 and 97.7% (Table 5) (Werry and Gerhards 1992, Winterberg and Gerhards 1997, Frühauf et al. 1998, von Borstel et al. 2005, Tömördy et al. 2010, Schinagl 2017). These rates were based on ophthalmologic reexaminations in only four of seven studies, with the other studies not indicating how many horses were reexamined as part of the study design (Winterberg and Gerhards 1997, Frühauf et al. 1998, Dorrego Keiter et al. 2017, Schinagl 2017). Most information in the latter studies was gained through interviewing the owners by telephone (von Borstel et al. 2005, Tömördy et al. 2010). The number of eyes evaluated in these studies was between 10 and 134, and the period between the vitrectomy and the follow-up ranged between 2 and 216 months. Only two studies gave a median time of 29 and 87 months of the evaluation after the vitrectomy (Dorrego Keiter et al., 2017 Schinagl 2017). No recurrences of uveitic symptoms were recognized in these studies in a range between 73.6 (Tömördy et al. 2010) and 97.7% (Winterberg and Gerhards 1997) of the eyes evaluated. These variations may be due to different patient populations, operating methods, periods between the surgery and the follow-up, or variations in study designs.

The aim of the current study was to obtain information of and to perform a reexamination on as many eyes as possible after a period of at least 17 and up to 123 months post-vitrectomy. Follow-up information for 86.6% (246/284) of all eyes vitrectomized between 2005 and 2013 was available. A total of 59.8% (147/246) of these eyes were available for ophthalmologic reexaminations and 40.2% (99/246) were contacted only via telephone (Fig. 1).

Ophthalmologic checkup group (B) vs. follow-up information group (A)

The number of eyes with REC was smaller in the ophthalmological checkup group (B: 9% REC) compared to the follow-up information group (A: 15% REC). This may be partly explained by the numbers of enucleation and euthanasia in the “information only” group (Fig. 2). Since any episode of uveitis may result in globe destruction and loss of vision and since uveitis in equines is generally highly painful, euthanasia may have been a reasonable choice for owners in these cases (Gerding and Gilger 2016).

Since the ophthalmological reexamination for the current study was performed only once, it could not be clarified at what exact time after the vitrectomy the eyes showed recurrences. However, it could be shown that 17 of 35 REC happened during the first two months after vitrectomy (Fig. 5). In the current study the probability of REC increases with time.

Whether NOIS is accounted for in the group of REC or the group of FOC could not be finally clarified. An argument that NOIS needs to be numbered among FOC is that inflammatory ocular signs of eyes with NOIS were certainly distinguished by owners from the episodes prior to the vitrectomy and that veterinarians diagnosed another ocular problem in the eyes of their horses besides uveitis (e.g. keratitis, conjunctivitis). Owners of a vitrectomized horse were presumably very sensitively attuned to recognizing signs of ocular inflammation in their horse. This aspect may provide a bias in the “information only” group. A certain expectation of the owners regarding the success of the vitrectomy should not be underestimated. The FOC and NOIS (IMP) together represented 85% (209/246) of the eyes vitrectomized (Fig. 2). Regarding the studies published about the long-term prognosis after vitrectomy, the rate for non-recurrence as FOC only ranged between 73 and 74% and confirmed the results of Tömördy et al., who found a rate of non-recurrence of 73.6% and of Dorrego-Keiter et al. with a rate

Table 5 Published studies regarding the long-term prognosis of horses with ERU after a vitrectomy | Veröffentlichte Studien zur Langzeitprognose von Pferden mit ERU nach einer Vitrektomie

	evaluated eyes	time post vitrectomy [months]	ophthalmological reexaminations	no uveitic symptoms	conservation of visual acuity (not blind)
Werry et al. 1992	90.9% (10/11)	not specified	not specified	100%	no information
Winterberg et al. 1997	53.1% (43/81)	6 to 67	100%	97.7%	72% (31/43)
Frühauf et al. 1998	89.5% (34/38)	5 to 60	79%	85%	85% (29/34)
Borstel et al. 2005	89.3% (50/56)	2 to 3	not specified	94%	80% (40/50)
Tömördy et al. 2010	89.8% (53/59)	3 to 90	not specified	73.6%	no information
Dorrego-Keiter et al. 2017	100% (134/134)	8 to 54 median 29	not specified	76.3% (FOC + NOIS)	no information
Schinagl 2018	100% (654/654)	6 to 216 median 87,6	16% (105/54)	96,3%	81% (128/147)
Present study, Baake 2017	86.6% (246/289)	17 to 123 median 64	59.8% (147/246)	91% IMP 73% FOC / 18% NOIS	87% (128/147)

of non-recurrence of 77.6% (Tömördy et al. 2010, Dorrego Keiter et al. 2017). Dorrego-Keiter et al. stated clearly that they included eyes with ocular problems other than uveitis (e.g. keratitis, conjunctivitis) as a non-recurrence (Dorrego Keiter et al. 2017). If NOIS is counted among FOC, the rate for non-recurrence ranged between 85 and 91% in the present study, which is almost the same as the findings of Winterberg et al., Frühauf et al., von Borstel et al. and Schinagl (Winterberg and Gerhards 1997, Frühauf et al. 1998, Von Borstel et al. 2005, Schinagl 2017). Nevertheless, some results of previous publications differ from each other significantly. This may not only be explained by different time periods between the vitrectomy and the ophthalmologic follow-up examination for these studies, but also by the method of evaluation (ophthalmologic examination vs. contact only). Tömördy et al. (reexamined and contacted owners and referring veterinarians of the horses between 3 and 90 months post-vitrectomy, whereas Frühauf et al. examined 27 of 38 eyes of the horses vitrectomized between 5 and 60 months post-vitrectomy and von Borstel et al. reexamined or contacted owners after two to three months post-vitrectomy (Frühauf et al. 1998, von Borstel et al. 2005, Tömördy et al. 2010). Frühauf et al. reported that most of the REC were recognized during the first and second month post-vitrectomy (Frühauf et al. 1998). The present study confirmed that most of the REC occurred during the first two months post-vitrectomy (17 out of 35 eyes with REC) (Fig. 5). In addition, we also found that late REC occurred, as a total of 20 eyes with REC were noticed later than the second month post-vitrectomy in the present study. Two eyes even showed REC after 95 months, but these were the only REC that were recognized later than 60 months post-vitrectomy. This is in accordance with another study that showed two late recurrences at 30 and 60 months after the vitrectomy (Schinagl 2017). Assuming that the ocular examinations in the current study would have been performed only three months after each vitrectomy, the success rate (IMP) would have increased up to 93%. Von Borstel et al. (2005) evaluated vitrectomized eyes only two to three months post-vitrectomy and, therefore, probably demonstrated a higher success rate (94%) than in the present study (von Borstel et al. 2005). Since Tömördy et al. evaluated eyes up to 90 months post-vitrectomy, their rate for non-recurrence was less than that presented by von Borstel et al. (Von Borstel et al. 2005, Tömördy et al. 2010). The longer the postsurgical period reviewed and the more reexaminations performed, the lower the rates found for postsurgical non-recurrence are. This is contrary to Schinagl, who evaluated eyes up to 216 months post vitrectomy and showed a rate of non-recurrence of 96.3%. But it has to be pointed out that only 16% of the evaluated eyes were ophthalmologically examined (Schinagl 2017). The Kaplan-Meier values provide the impression of a rapid decrease of REC during the first six months post-vitrectomy and a slower, but steady decrease of the probability of non-recurrence from 89 down to 80% during the time between 7 to 123 months (Fig. 5). Nevertheless, surgeons, surgical methods, patients and owners' compliance may have influenced the rate for non-recurrence as well.

A limitation of the present study was the fact that not all horses were available for an ophthalmological reexamination. Therefore, the actual rate of REC might be higher or lower

than determined. In addition, the memories of the owners may have been insufficient regarding the health issues of each horse. The information available was stratified by different factors (total, year 2009, radius of 100 km around the clinic) to minimize these limitations and to determine these influences. However, regardless of whether eyes were reexamined or information was only based on phone calls, the decision concerning the possible postoperative outcome of an eye was, in the end, always based upon the owner's statements.

No significant difference could be shown between the total number of REC and the two stratifications (100 km and the year 2009) (Fig. 2). Therefore, the assumption regarding the long-term prognosis in the current study was thought to be of high value.

ERU subtypes and scoring

In the literature, ERU is categorized into three different clinical subtypes: "classic ERU," "posterior ERU" and "insidious ERU." The "classic ERU" affects posterior and anterior parts of the eye, the "posterior ERU" affects primarily the vitreous body, choroid and retina, and the "insidious ERU" is characterized as a mild and almost painless intraocular inflammation (Gilger 2010). In the current study, the major proportion of the horses belonged to the subtype "classic ERU" or "posterior ERU." It can be assumed that the three Knabstruppers belonged to the subtype "insidious ERU," and these horses were, therefore, excluded from further statistics.

The total ERU score of all eyes examined from pre- to post-vitrectomy did not change significantly from pre- to post-vitrectomy in the current study, including the eyes with REC and NOIS. Since ophthalmologic changes tend to worsen in eyes with ERU during each inflammatory episode if they are not vitrectomized (Alexander and Keller 1990), this can be interpreted as another indication for the success of this surgery. Ocular inflammation did not seem to have worsened the ERU score further after the vitrectomy. The lens score increased significantly from a mean score of 1.5 to 2.8. Cataracts seemed to have an ongoing maturation and another study could show that 13 vitrectomized eyes had a progressive postsurgical cataract formation, 11 of which already showed incipient cataracts or vitreal inflammatory infiltrates adhered to the posterior capsule of the lens prior to the vitrectomy (Frühauf et al. 1998). The progressive nature of cataract formation in horses can be explained by alterations within the complex anatomy of the lens. If inflammatory debris, for example, was attached to the posterior lens capsule and removed within the vitrectomy, shear forces effected the hyaline membrane of the lens and the usually inactive lens epithelium might have been triggered to start mitosis and the newly formed cells might undergo hyaline degeneration, lipid metamorphosis and calcification (Cogan 1962). In another study, 2 out of 53 horses showed a cataract two months after the vitrectomy (von Borstel et al. 2005). The same authors described in a later study that the higher the preexisting ocular changes, the higher the odds for postsurgical complications, such as retinal detachment and progressive cataract formation (von Borstel et al. 2010). If lenses showed cataract formations prior to the surgery, the chance of postoperative progressive cataract formation was found to be high.

It should be mentioned that none of the three eyes with a total ERU-Score of zero showed REC (Fig. 4), which might raise up the question whether these eyes might not have suffered from ERU. But the authors consider these horses to have ERU since all vitrectomized horses had a clinical history of at least two uveitic episodes of unknown etiology according to the referring veterinarian, who in some cases was one of the co-authors and surgeons. Two of these three eyes belonged to horses that already had a vitrectomy in the other eye and this might explain an early intervention. But regardless of these three eyes that might be questionable, it could be shown that eyes with a total ERU-Score of 3 and 5 had significantly more recurrences than eyes with a total ERU-Score of 2. This highlights that horses benefit from a vitrectomy at an early stage of ERU, as other authors already suggested (von Borstel et al. 2005).

Vitreous opacities due to inflammatory debris were the most common findings in eyes of horses with ERU (Bartel 2004, Wiehen 2012, Kulbrock et al. 2013b). The mean score of all eyes examined for the vitreous was 2.5 prior to the vitrectomy in the current study and decreased significantly to 1.7 after the vitrectomy. This was the principle alteration of the ERU score caused directly by the vitrectomy procedure.

The recurrent episodes of intraocular inflammation usually lead to a destruction of intraocular tissue. Equine recurrent uveitis has been described to be the most common cause of blindness in horses (Angelos et al. 1988, Lavach 1990). A recent study evaluated the prognosis and impact of ERU in the United States and reported a high frequency of blindness as well (Gerding and Gilger 2015). Vision has been reported to be maintained in 72 to 85% of the eyes with ERU that underwent a vitrectomy (Winterberg and Gerhards 1997, Frühauf et al. 1998). A more recent study evaluated the outcome of low-dose gentamicin injection in eyes with different stages of equine recurrent uveitis and showed that 70.5% (43 of 61 eyes) remained visual after this treatment (Kleinpeter et al. 2019). Winterberg et al. differentiated between an increase and decrease of vision after vitrectomy (Winterberg and Gerhards 1997). According to that study, an increase of vision occurred in 39.5% (17/43) of the eyes, whereas vision decreased in 32.6% (14/43) of the eyes and 27.9% of the eyes were blind after the vitrectomy. Von Borstel et al. reported that 20% (10/47) of the vitrectomized eyes showed a complete loss of vision post-vitrectomy (von Borstel et al. 2005). In the present study, a total of 87% (128/147) of the reexamined eyes had a positive dazzle reaction and a positive menace response. Only 3% (5/147) of the reexamined eyes showed a negative dazzle reaction and 10% (14/147) of the eyes showed a negative menace response. It is not possible to state at what time point the eyesight was impaired after the vitrectomy. Further prospective studies need to reexamine vitrectomized eyes at certain time points after the vitrectomy.

Gender

Previous studies suggest that male horses suffer from ERU significantly more often than females (Wollanke 1995, Szemes and Gerhards 2000, Kulbrock et al. 2013, Dorrego-Keiter et al. 2016). Geldings have been reported to be affected significantly more often than mares and stallions (Szemes and Gerhards

2000). The present study verified these findings, because more male than female, and more geldings than mares and stallions were vitrectomized compared to the clinic population during the same time period (Table 3). Wollanke et al. demonstrated previously that the leptospiral antibody titers were similar for male and female horses (Wollanke 1995). Hence, these authors postulated a protective action of female hormones. Other uveitic diseases in human medicine have been described to be gender-predisposed. Morbus Behçet syndrome and Fuch's heterochromic cyclitis are two diseases seen in human patients that involve uveitic symptoms. These diseases were thought to be gender-related (O'Brien et al. 1994), but recent studies have cast doubt whether gender influences exist in these diseases (Bonfioli et al. 2005, Davatchi et al. 2012). A different outcome after the vitrectomy between male and female horses seems to be altogether nonexistent in the present study, since the mean ERU score pre- and post-vitrectomy did not alter significantly between male and female horses.

Breed, coat color and age

In the current study, Icelandic and Friesian horses, Trotters, Pura Raza Española and Knabstrappers were significantly more often vitrectomized than Warmbloods compared to the clinic population (Table 3). This may well be due to a higher prevalence of ERU in these breeds. In a previous retrospective study, over one third of all horses with ERU were Icelandic horses (Wiehen 2012).

Appaloosas are significantly more likely to develop uveitis than Standardbreds and Thoroughbreds (McLaughlin et al. 1992). Dwyer et al. described that Appaloosas have an 8.3 times higher chance of developing uveitis than other equine breeds (Dwyer et al. 1995). A recent study showed that Appaloosas with equine recurrent uveitis had a significant risk of developing recurrences after intravitreal treatment with low-dose gentamicin (Fischer et al. 2019) and another study showed that leopard colored horses had a significantly higher risk to have a REC after vitrectomy (Schinagl 2017). One study evaluated the genetic risk factors for Appaloosas, such as a marker in the TRPM1 gene in the ECA1 region responsible for their spotted coat color and two different markers in the region for the equine major histocompatibility complex (Fritz et al. 2014). These and other authors were able to identify three markers in these regions that were significantly associated with ERU. A leopard complex spotting gene that is associated with a higher risk of ERU and congenital stationary night blindness in the horse was found in Knabstrappers (Bellone et al. 2013, Baumgart and Gerhards 2014, Fritz et al. 2014). In the present study, all Knabstrappers showed a post-surgical REC. This may be due to the different subtype of ERU in this breed and perhaps even due to a solely autoimmune or genetically triggered uveitis. Therefore, a long-term sustained cyclosporine implant may be the better choice of therapy in this breed (Gilger and Allen 1998, Gilger et al. 2000, Gilger et al. 2010, Baumgart 2014, Baumgart and Gerhards 2014). A genetic risk factor for developing ERU was also shown for Warmblood horses (Kulbrock et al. 2013a).

Since "insidious ERU" has been described as mild and painless, owners often do not recognize ocular changes until loss

of vision occurs. "Insidious ERU" has less often been associated with an intraocular leptospiral infection in Appaloosas and Knabstrappers and a larger primarily immunological etiological component than in other breeds has, therefore, been assumed (Gilger et al. 2010, Baumgart 2014).

Horses were divided into the groups "black and brown," "chestnut" and "others" because of their different genetic patterns. The extension of black color in "black and brown" horses is determined by a homo- or heterozygote gene "E" (EE or Ee) and chestnut horses have a homozygous "ee" (Castle 1954). The group with the coat color "other" was affected by REC significantly more frequently in the present study than horses with a "black and brown" coat color. One reason for this may be that all horses with a spotted coat color were assigned to this group and, as outlined above, "spotted" horses appear to have a poorer prognosis concerning their rate of REC than single color horses. Horses with a black, brown and black-brown coat color ("black and brown") were vitrectomized significantly more often in the current study than horses with the coat color "other" (Table 3). This is in accordance with the higher occurrence of ERU among Warmbloods with a "black and brown" coat color (Kulbrock et al. 2013b). Other studies have demonstrated an overrepresentation of horses with ERU of a brown coat color as well (Bartel 2004, Wiehen 2012).

A total of 45.1% (106/235) of all horses vitrectomized were between four and seven years of age. This age group was significantly overrepresented compared to any other age group. Information about the prevalence of ERU among horses of different ages varies in literature. Some authors stated that relatively young horses were affected (Alexander and Keller 1990, Wollanke 1995), while others reported an increase of ERU among older horses, supposedly because of the cumulative contact to leptospiral antigens and antibodies during their lives (Szemes and Gerhards 2000, Bartel 2004). The current study implies that horses of an age between four and seven years are more likely to be vitrectomized. The reason for this may be that younger horses were more prone to develop ERU, that owners were more prone to invest in a vitrectomy in younger horses, or that referring veterinarians could diagnose ERU earlier than in older horses. Referring veterinarians may have recommended vitrectomy at an early stage of the disease, due to a better outcome at an early stage of the disease (von Borstel et al. 2010). In the present study horses older than 20 years showed a significantly higher number of eyes with REC compared with horses aged four to seven years. This is in accordance with a recent study from southern Germany, where older horses showed significantly more often REC than younger horses (Schinagl 2017).

Leptospiral status

One of the propagated etiological (infectious) factors for ERU in North-West Europe is an intraocular leptospiral infection. In previous studies, vitreous and aqueous humor of affected eyes has been analyzed by different methods, such as PCR, MAT and ELISA, to identify a potential intraocular

infection with leptospire (Rimpau 1947, Heusser 1948, Halliwell et al. 1985, Sillerud et al. 1987, Schwink et al. 1989, Alexander and Keller 1990, Brem et al. 1998, Wollanke et al. 1998, Brem et al. 1999, Faber et al. 2000, Wollanke et al. 2000, Wollanke et al. 2001, Wollanke et al. 2004, Niedermaier et al. 2006, Brandes et al. 2007, Pearce et al. 2007, Gilger et al. 2008, Frelstedt 2009, von Borstel et al. 2010, Wiehen 2012, Polle et al. 2014, Gerding and Gilger 2015). In the present study, intraocular leptospiral infection was demonstrable through MAT and/or PCR in a total of 56% of the vitrectomized eyes. This finding is in accordance with a recent study performed in northern Germany in which 221 undiluted vitreal samples were examined by MAT and culturing. The MAT revealed that 57.7% of the samples were positive and 16% of the samples had a positive leptospiral culture (Dorrego-Keiter et al. 2016). It is still under discussion whether the prognosis is better in leptospiral-positive eyes after a vitrectomy. Tömördy et al. and Schinagl reported a higher number of eyes without recurrent episodes of uveitis if leptospiral antibodies were detectable (Tömördy et al. 2010, Schinagl 2017). In contrast to these studies, Dorrego-Keiter et al. demonstrated that there is no significant difference between the outcome of eyes tested negative and tested positive for leptospiral antibodies via MAT (Dorrego Keiter et al. 2017). All odds ratios calculated in the present study for eyes having a REC depending upon being leptospiral-positive or leptospiral-negative showed a 95% confidence interval below one. Hence, none of these odds ratios were significant, although the odds ratio for leptospiral-negative eyes having a REC was found to be higher (OR: 1.925). When Warmbloods are compared to Icelandic horses, independent of their intraocular leptospiral status, Icelandic horses are 1.4 times more likely to develop REC. Therefore, not only the intraocular leptospiral status, but also the breed appeared to have an influence on the prognosis after vitrectomy. Since these odds ratios were only tendencies and 82 of the leptospiral-negative eyes did not show any signs of REC, vitrectomy did not appear to be significantly less effective on leptospiral-negative than on leptospiral-positive eyes. If only leptospiral-positive eyes would have been included, the rate of non-recurrence would be slightly higher for Warmblood horses (64/70, 91%), but lower for Icelandic horses (15/19, 79%). The findings of the present study, therefore, support the concept that the etiology of ERU is multifactorial, and other factors influencing the long-term prognosis after a vitrectomy are most probably autoimmunogenic and genetically determined (Deeg et al. 2001, Deeg 2008, Gilger 2010, von Borstel et al. 2010, Kulbrock et al. 2013a).

Alternative methods of treatment

The currently most promising alternative treatment option of equine recurrent uveitis is the intravitreal injection of low-dose gentamicin. A recent study shows that up to 88,1% of 59 horses that received 4 mg of intravitreal gentamicin did not show recurrent or persistent ocular inflammation with a minimum of 30 days between treatment and follow-up (Fischer et al. 2019). And another study showed that 91,8% (56 of 61) treated eyes did not show ocular inflammation over a period that ranged between two and 96 months after treatment (Kleinpeter et al. 2019). The intravitreal injection of low-dose

gentamicin may therefore be a considerable alternative treatment option of horses with equine recurrent uveitis.

Conclusion

This study showed that between 85% (74% FOC, 11% NOIS) of the eyes evaluated and 91% (73% FOC, 18% NOIS) of the eyes reexamined showed an improvement (IMP) of the recurrent uveitic episodes after the vitrectomy. A total of 87% (128/147) of the reexamined eyes showed a positive dazzle reflex and a positive menace response after the vitrectomy at the time of ocular reexamination for the current study.

The odds of having a recurrence were higher if no leptospiral DNA or antibodies were detected. However, genetic and potentially autoimmunogenic factors, as well as age, breed and preexisting ocular damage appears to influence the long-term prognosis. Therefore, an early vitrectomy of horses with a reliable diagnosis of classic ERU should be advocated.

Manufacturer's addresses

- ¹ IsoptoMax[®], Alcon, Freiburg, Germany
- ² Atropin-POS[®] 0.5%, Ursapharm Arzneimittel GmbH, Saarbrücken, Germany
- ³ Flunidol[®] RPS 50 mg/ml, CP-Pharma, Burgdorf, Germany
- ⁴ Sulfadimethixin & Trimethoprim 50%[®], Medistar GmbH, Ascheberg; Germany
- ⁵ Ophtho Lavas, Vétoquinol GmbH, Ravensburg; Germany
- ⁶ Gentamicin-ratiopharm[®] 80 mg/2 ml SF, Ratiopharm GmbH, Ulm, Germany
- ⁷ Polysorb[®], 3/0 USP, Covidien Deutschland GmbH, Neustadt/Donau, Germany
- ⁸ Vitrektom, Erbe Elektromedizin, Tübingen, Germany
- ⁹ Heine Omega[®] 500, Heine Optotechnik, Herrsching, Germany
- ¹⁰ BSS PLUS[®], Alcon Laboratories, Inc., Texas, USA
- ¹¹ Vicryl[®], 4/0, Ethicon, Norderstedt, Germany
- ¹² Dexta-ratiopharm[®], Ratiopharm GmbH, Ulm, Germany
- ¹³ Flunidol[®] 5% Gel, CP-Pharma, Burgdorf, Germany
- ¹⁴ IVD GmbH Hannover, Seelze-Letter, Germany
- ¹⁵ Mydriaticum Stulln UD[®], Pharma Stulln GmbH, Stulln, Germany
- ¹⁶ SAS Institute Inc., Cary, NC, USA

Abbreviations

ERU: equine recurrent uveitis;
 MAT: microscopic agglutination test;
 PCR: polymerase chain reaction;
 FOC: free of complaints;
 NOIS: non-specific ocular inflammatory symptoms;
 REC: recurrence of uveitis; IMP: improvement

Animal Welfare statement

Information was obtained from client-owned horses during the study which has been approved by the ethics committee within the University of Veterinary Medicine, Hannover, and the State Office for Con-

sumer Protection and Food Safety in accordance with the German Animal Welfare Law (LAVES – Reference number: Az. 14A 485).

Statement of informed consent

All owners provided informed consent that information can be included in the study.

Conflict of interest statement

The authors declare that they have no competing interests.

Acknowledgements

The authors thank language editor Philip Saunders for the validation of the English language used in this article.

References

- Alexander C. S., Keller H. (1990) Ätiologie und Vorkommen der periodischen Augenentzündung des Pferdes im Raum Berlin. *Tierärztl. Praxis* 18, 623–627
- Angelos J., Oppenheim Y., Rebhun W., Mohammed H., Antczak D. F. (1988) Evaluation of breed as a risk factor for sarcoid and uveitis in horses. *Anim. Gen.* 19, 417–25
- Baake E.I.A. (2017) Studie zur Ursache und Therapie der equinen rezidivierenden Uveitis. *Wissenschaftliche Reihe der Klinik für Pferde*, Band 31, Cuvillier Verlag, Göttingen, ISBN 3736986513, 9783736986510, 1–91
- Baumgart A. (2014) Cyclosporin A und dessen möglicher Einsatz bei der Tigerschecken-Uveitis. *Diss. Med. Vet. München*
- Baumgart A., Gerhards H. (2014) Besonderheiten der Tigerschecken-Uveitis und möglicher Cyclosporin A-Einsatz in der Therapie in Deutschland. *Pferdeheilkunde* 30, 626–632; DOI 10.21836/PEM20140601
- Bellone R. R., Holl H., Setaluri V., Devi S., Maddodi N., Archer S., Sandmeyer L., Ludwig A., Foerster D., Pruvost M., Reissmann M., Bortfeldt R., Adelson D. L., Brooks S. A. (2013) Evidence for a retroviral insertion in TRPM1 as the cause of congenital stationary night blindness and leopard complex spotting in the horse. *PLoS One.* 8, e78280; DOI 10.1371/journal.pone.0078280. eCollection 2013.
- Bonfioli A. A., Curi A. L., Orefice F. (2005) Fuchs' heterochromic cyclitis. *Sem. Ophthalmol.* 20, 143–146; DOI 10.1080/08820530500231995
- Brandes K., Wollanke B., Niedermaier G., Brem S., Gerhards H. (2007) Recurrent uveitis in horses: vitreal examinations with ultrastructural detection of leptospores. *Transbound. Emerg. Dis.* 54, 270–275
- Brem S., Gerhards H., Wollanke B., Meyer P., Kopp H. (1998) Demonstration of intraocular leptospira in 4 horses suffering from equine recurrent uveitis (ERU). *Berl. Münch. Tierärztl. Wschr.* 111, 415–417
- Brem S., Gerhards H., Wollanke B., Meyer P., Kopp H. (1999) 35 leptospira isolated from the vitreous body of 32 horses with recurrent uveitis (ERU). *Berl. Münch. Tierärztl. Wschr.* 112, 390–303
- Castle W. E. (1954) Coat Color Inheritance in Horses and Other Mammals. *Genetics* 39, 35–44
- Cogan D. G. (1962) Anatomy of lens and pathology of cataracts. *Experiment. Eye Res.* 1, 291–295
- Curling (2011) Equine recurrent uveitis: Treatment. *Comp. Cont. Educ. Vet.* 33, E1

- Davatchi F., Shahram F., Chams-Davatchi C., Sadeghi Abdollahi B., Shams H., Nadjji A., Faezi T., Akhlaghi M., Ghodsi Z., Larimi R., Ashofteh F. (2012) Behcet's disease: is there a gender influence on clinical manifestations? *Int. J. Rheumatic Dis.* 15, 306–314; DOI 10.1111/j.1756-185X.2011.01696.x.
- Deeg C. A. (2008) Ocular immunology in equine recurrent uveitis. *Veterinary Ophthalmology* 11 (SI), 61–65; DOI 10.1111/j.1463-5224.2008.00625.x.
- Deeg C. A., Kaspers B., Gerhards H., Thurau S. R., Wollanke B., Wildner G. (2001) Immune responses to retinal autoantigens and peptides in equine recurrent uveitis. *Investigative Ophthalmol. Visual Sci.* 42, 393–398
- Dorrego Keiter E., Tóth J., Dikker L., Sielhorst J., Schusser G. F. (2017) Langzeitergebnisse der Pars-Plana-Vitrektomie in Abhängigkeit vom Leptospiren-Antikörper-Nachweis im Glaskörper bei 118 Pferden mit Equiner Rezidivierender Uveitis (ERU). *Pferdeheilkunde* 33, 112–118; DOI 10.21836/PEM20170201
- Dorrego-Keiter E., Tóth J., Dikker L., Sielhorst J., Schusser G. F. (2016) Detection of leptospira by culture of vitreous humor and detection of antibodies against leptospira in vitreous humor and serum of 225 horses with equine recurrent uveitis. *Berl. Münch. Tierärztl. Wschr.* 129, 209–215
- Dwyer A. E., Crockett R. S., Kalsow C. M. (1995) Association of leptospiral seroreactivity and breed with uveitis and blindness in horses: 372 cases (1986–1993). *J. Am. Vet. Med. Assoc.* 207, 1327–1331
- Faber N. A., Crawford M., LeFebvre R. B., Buyukmihci N. C., Madigan J. E., Willis N. H. (2000) Detection of *Leptospira* spp. in the Aqueous Humor of Horses with Naturally Acquired Recurrent Uveitis. *Clin. Microbiol.* 38, 2731–2733
- Fischer B. M., Mc Mullen R. J., Reese S., Brehm W. (2019) Intravitreal injection of low-dose gentamicin for the treatment of recurrent or persistent uveitis in horses: Preliminary results. *BMC Vet. Res.*; DOI 10.1186/s12917-018-1722-7
- Frellstedt L. (2009) Equine recurrent uveitis: A clinical manifestation of leptospirosis. *Equine Vet. Educ.* 21, 546–552
- Fritz K. L., Kaese H. J., Valberg S. J., Hendrickson J. A., Rendahl A. K., Bellone R. R., Dynes K. M., Wagner M. L., Lucio M. A., Cuomo F. M., Brinkmeyer-Langford C. L., Skow L. C., Mickelson J. R., Rutherford M. S., McCue M. E. (2014) Genetic risk factors for insidious equine recurrent uveitis in Appaloosa horses. *Anim. Gen.* 45, 392–399; DOI 10.1111/age.12129.
- Frühauß B., Ohnesorge B., Deegen E., Boevé M. (1998) Surgical Management of equine recurrent uveitis with single port pars plana vitrectomy. *Vet. Ophthalmol.* 1, 137–151
- Gerding J. C., Gilger B. C. (2016) Prognosis and impact of equine recurrent uveitis. *Equine Vet. J.* 48, 290–298; DOI 10.1111/evj.12451
- Gerhards H., Wollanke B. (2001) Uveitis bei Pferden - Diagnose und Therapie. *Pferdeheilkunde* 17, 319–329; DOI 10.21836/PEM20010402
- Gilger B. C. (2010) Equine recurrent uveitis The viewpoint from the USA. *Equine Vet. J.* 42 (S37), 57–61
- Gilger B. C., Allen J. B. (1998) Cyclosporine A in veterinary ophthalmology. *Vet. Ophthalmol.* 1, 181–187
- Gilger B. C., Malok E., Stewart T., Ashton P., Smith T., Jaffe G. J., Allen J. B. (2000) Long-term effect on the equine eye of an intravitreal device used for sustained release of cyclosporine A. *Vet. Ophthalmol.* 3, 105–110
- Gilger B. C., Salmon J. H., Na Y. Y., Barden C. A., Chandler H. L., Wendt J. A., Colitz C. M. (2008) Role of bacteria in the pathogenesis of recurrent uveitis in horses from the southeastern United States. *Am. J. Vet. Res.* 69, 1329–1335; DOI 10.2460/ajvr.69.10.1329.
- Gilger B. C., Wilkie D. A., Clode A. B., McMullen R. J., Utter M. E., Komaromy A. M., Brooks D. E., Salmon J. H. (2010) Long-term outcome after implantation of a suprachoroidal cyclosporine drug delivery device in horses with recurrent uveitis. *Vet. Ophthalmol.* 13, 294–300 DOI 10.1111/j.1463-5224.2010.00807.x.
- Halliwell R. E., Brim T. A., Hines M. T., Wolf D., White F. H. (1985) Studies on equine recurrent uveitis. II The role of infection with *Leptospira interrogans* serovar pomona. *Curr. Eye Res.* 4, 1033–40
- Heusser H. (1948) Die periodische Augenentzündung, eine Leptospirose? *Schweiz. Arch. Tierheilk.* 90, 287–314
- Kleinpeter A., Göpfert A., Köhler E., Brehm W. (2019) Intravitreale Low-Dose-Gentamicininjektion zur Behandlung ERU-erkrankter Pferde / Intravitreal injection of low-dose gentamicin for the treatment of ERU-affected horses. *Tierärztl. Praxis G*; DOI 10.1055/a-0816-7156
- Kulbrock M., Lehner S., Metzger J., Ohnesorge B., Distl O. (2013a) A genome-wide association study identifies risk loci to equine recurrent uveitis in German warmblood horses. *PLoS One* 8, e71619; DOI 10.1371/journal.pone.0071619.
- Kulbrock M., von Borstel M., Rohn K., Distl O., Ohnesorge B. (2013b) Studie zu Häufigkeit und Schweregrad der Equinen Rezidivierenden Uveitis bei Warmblütern. *Pferdeheilkunde* 29, 27–36; DOI 10.21836/PEM20130105
- Lavach J. D. (1990) Large animal ophthalmology. St. Louis: Mosby.
- McLaughlin, S. A., Whitley, R. D., Gilger, B. C. (1992) Diagnosis and treatment of lens diseases. *Vet. Clin. North Am. Equine Pract.* 8, 575–85
- McMullen Jr. R. (2015) Intravitreal injection of low-dose gentamicin in horses for treatment of chronic recurrent or persistent uveitis: preliminary results. Conference Paper, International Equine Ophthalmology Consortium/Acrivet, Inc. Symposium
- Niedermaier G., Wollanke B., Hoffmann R., Brem S., Gerhards H. (2006) Detection of leptospira in the vitreous body of horses without ocular diseases and of horses with equine recurrent uveitis (ERU) using transmission-electron microscopy. *Deutsch. Tierärztl. Wschr.* 113, 418–422
- O'Brien J. M., Albert D. M., Foster C. S. (1994) Anterior uveitis. Principles and practice of ophthalmology. Philadelphia: Saunders, 1, 407–423
- Pearce J. W., Galle L. E., Kleiboeker S. B., Turk J. R., Schommer S. K., Dubielzig R. R., Mitchell W. J., Moore C. P., Giuliano E. A. (2007) Detection of *Leptospira interrogans* DNA and antigen in fixed equine eyes affected with end-stage equine recurrent uveitis. *Vet. Diagn. Invest.* 19, 686–690; DOI 10.1177/104063870701900611
- Polle F., Storey E., Eades S., Alt D., Hornsby R., Zuerner R., Carter R. (2014) Role of Intraocular *Leptospira* Infections in the Pathogenesis of Equine Recurrent Uveitis in the Southern United States. *J. Equine Vet. Sci.* 34, 1300–1306; DOI 10.1016/j.jevs.2014.09.010
- Rimpau W. (1947) Leptospirose beim Pferd (Periodische Augenentzündung). *Tierärztl. Umsch.* 2, 177–178
- Schinagl C. (2017) Pars-Plana-Vitrektomie bei Equiner Rezidivierender Uveitis: Langzeitergebnisse zu Rezidivfreiheit, Sehfähigkeit und Bulbuserhalt bei 654 Augen von 549 Pferden. *Diss. Med. Vet. München*
- Schwink K., Crisman M., Rigg D. (1989) Chronic recurrent uveitis in a horse with an elevated aqueous humor antibody titer to *Leptospira interrogans* serovar autumnalis. *Equine Pract.* 11, 41–43
- Sillerud C. L., Bey R. F., Ball M., Bistner S. I. (1987) Serologic correlation of suspected *Leptospira interrogans* serovar pomona-induced uveitis in a group of horses. *J. Am. Vet. Med. Assoc.* 191, 1576–1578
- Szemes P., Gerhards H. (2000) Untersuchungen zur Prävalenz der equinen rezidivierenden Uveitis im Grossraum Köln-Bonn. *Prak. Tierarzt* 81, 408–420
- Tömördy E., Haessig M., Spiess B. M. (2010) The outcome of pars plana vitrectomy in horses with equine recurrent uveitis with regard to the presence or absence of intravitreal antibodies against various serovars of *Leptospira interrogans*. *Pferdeheilkunde* 26, 251–254; DOI 10.21836/PEM20100222
- von Borstel M., von Oppen T., Glitz F., Frühauß B., Deegen E., Boeve M. H., Ohnesorge B. (2005) Langzeitergebnisse der Pars plana Vitrektomie (double port) bei equiner rezidivierender Uveitis. *Pferdeheilkunde* 21, 13–18; DOI 10.21836/PEM20050102

- von Borstel M., Oey L., Strutzberg-Minder K., Boevé M. H., Ohnesorge B. (2010) Direkter und indirekter Nachweis von Leptospiren aus Glaskörperproben von Pferden mit ERU. *Pferdeheilkunde* 26, 219–225; DOI 10.21836/PEM20100217
- Werry H., Gerhards H. (1992) Zur operativen Therapie der equinen rezidivierenden Uveitis (ERU). *Tierärztl. Praxis* 20, 178–186
- Werry H., Gerhards H. (1991) Möglichkeiten der und Indikationen zur chirurgischen Behandlung der equinen rezidivierenden Uveitis (ERU). *Pferdeheilkunde* 7, 321–331; DOI 10.21836/PEM19910602
- Wiehen L. E. (2012) Retrospektive Analyse zum Vorkommen der Equinen rezidivierenden Uveitis -unter Berücksichtigung der Leptospireninfektion- an der LMU München von 01.2005 bis 06.2010 Diss. Med. Vet. München
- Winterberg A., Gerhards H. (1997) Langzeitergebnisse der Pars-plana-Vitrectomie bei equiner rezidivierender Uveitis. *Pferdeheilkunde* 13, 377–383; DOI 10.21836/PEM19910602
- Wollanke B. (1995) Untersuchungen zur Ätiologie der equinen rezidivierenden Uveitis (ERU). Diss. Med. Vet. München
- Wollanke B., Gerhards H. (2009) Equine rezidivierende Uveitis. *Cont. Vet. Educ.* 1, 1–14
- Wollanke B., Gerhards H., Brem S., Kopp H., Meyer P. (1998) Intraokulare und Serumantikörpertiter gegen Leptospiren bei 150 wegen equiner rezidivierender Uveitis (ERU) vitrektomierten Pferden. *Berl. Münch. Tierärztl. Wschr.* 111, 134–139
- Wollanke B., Gerhards H., Brem S., Meyer P., Kopp H. (2004) Ätiologie der equinen rezidivierenden Uveitis (ERU): Autoimmunkrankheit oder intraokulare Leptospireninfektion. *Pferdeheilkunde* 20, 327–340; DOI 10.21836/PEM20040403
- Wollanke B., Gerhards H., Brem S., Wolf E., Kopp H., Meyer P. (2000) Zur Leptospirenätiologie der equinen rezidivierenden Uveitis (ERU): Ergebnisse der Untersuchungen von Serum- und Glaskörperproben. *Tierärztl. Praxis* 28, 153–158
- Wollanke B., Rohrbach B. W., Gerhards H. (2001) Serum and vitreous humor antibody titers in and isolation of *Leptospira interrogans* from horses with recurrent uveitis. *J. Am. Vet. Med. Assoc.* 219, 795–800