

# **Visual field examination in children with brain disorders**

Yvonne Koenraads  
2016

## **Visual field examination in children with brain disorders**

PhD thesis, Utrecht University, the Netherlands

Cover design      Yvonne Koenraads & Fotografie UMC Utrecht, afdeling oogheelkunde  
Layout             Yvonne Koenraads  
Printed by         Proefschriftmaken.nl & Uitgeverij BOXPress  
ISBN                978-90-393-6545-8

© 2016 Yvonne Koenraads

All rights reserved. No parts of this publication may be reproduced or transmitted in any form or by any means, electronical or mechanical, including photocopy, recording, or any information storage or retrieval system, without permission in writing from the author. The copyright of the articles that have been published had been transferred to the respective journals.

### **Correspondence**

Yvonne Koenraads, University Medical Center Utrecht, Department of Ophthalmology,  
P.O. Box 85500, 3508 GA, Utrecht. E-mail: [y.koenraads@umcutrecht.nl](mailto:y.koenraads@umcutrecht.nl)

# **Visual field examination in children with brain disorders**

**Gezichtsveldonderzoek  
bij kinderen met hersenaandoeningen**  
(met een samenvatting in het Nederlands)

## **Proefschrift**

ter verkrijging van de graad van doctor aan de Universiteit Utrecht  
op gezag van de rector magnificus, prof.dr. G.J. van der Zwaan,  
ingevolge het besluit van het college voor promoties in het openbaar te verdedigen  
op dinsdag 14 juni 2016 des ochtends te 10.30 uur

door

**Yvonne Koenraads**  
geboren op 31 december 1986  
te Eindhoven

**Promotoren** Prof.dr. K.P.J. Braun  
Prof.dr. S.M. Imhof

**Copromotor** Dr. G.L. Porro

**The research described in this thesis was financially supported by**

Dr. F.P. Fischer Stichting (through UitZicht), ODAS, Rotterdamse Stichting Blindenbelangen, Stichting Nederlands Oogheelkundig Onderzoek & Stichting Vrienden UMC Utrecht.

**Publication of this thesis was kindly supported by**

Rotterdamse Stichting Blindenbelangen, Stichting Blindenhulp, Stichting voor Ooglijders, Landelijke Stichting voor Blinden en Slechtzienenden, Allergan, Bayer, BCRM, Chipsoft, Medical Workshop, Procornea, Rockmed, Thea Pharma, Tramedico, UCB Pharma & Visser contactlenzen.

*Aan mijn nichtje & neefje*

±03.06.2016 & ±21.08.2016

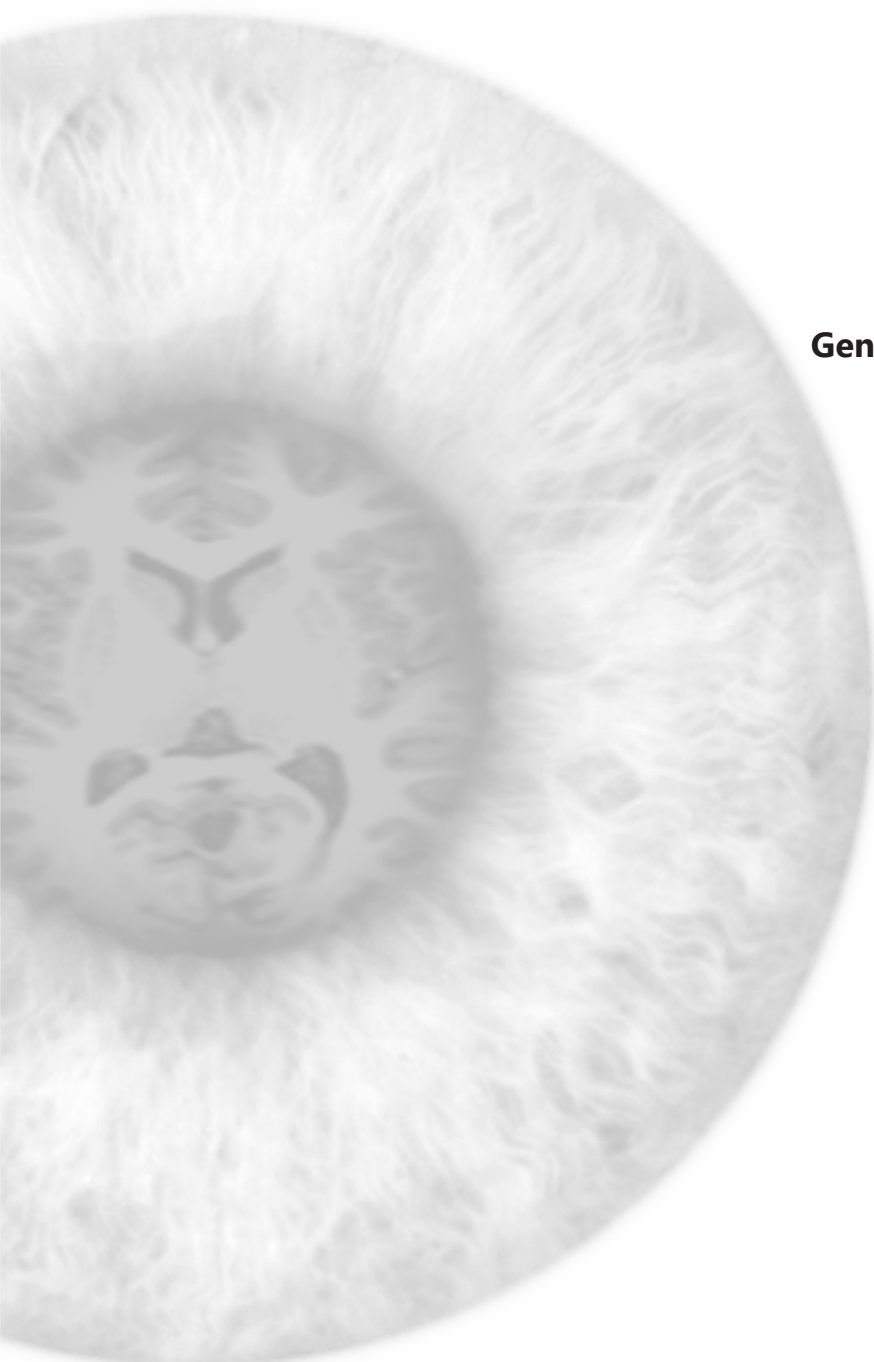
# Contents

<b>Chapter 1</b>	General introduction	9
<b>Chapter 2</b>	Perimetry in young and neurologically impaired children: the Behavioral Visual Field (BEFIE) Screening Test revisited <i>JAMA Ophthalmology 2015 Mar;133(3):319-25</i>	27
<b>Chapter 3</b>	Prediction of visual field defects in newborn infants with perinatal arterial ischemic stroke using early MRI and DTI-based tractography of the optic radiation <i>European Journal of Paediatric Neurology 2016 Mar;20(2):309-18</i>	47
<b>Chapter 4</b>	Visual field findings in children with suspicion of increased intracranial pressure <i>Submitted</i>	73
<b>Chapter 5</b>	Visual outcome in Sturge-Weber syndrome: a systematic review and Dutch multicenter cohort <i>Accepted for publication in Acta Ophthalmologica</i>	101

<b>Chapter 6</b>	Visual function and compensatory mechanisms for hemianopia after hemispherectomy in children <i>Epilepsia 2014 Jun;55(6):909-17</i>	127
<b>Chapter 7</b>	Summary and general discussion Nederlandse samenvatting	151 177
<b>Chapter 8</b>	List of abbreviations Contributors Assessment committee Dankwoord Curriculum vitae List of publications	182 184 187 188 196 198







# 1

**General introduction**

## INTRODUCTION TO THIS THESIS

Cerebral visual impairment (CVI, see Box 1) is nowadays the leading cause of child blindness in developed countries.<sup>1-5</sup> Beside a decrease in the prevalence of treatable and preventable vision impairing disorders, the increased survival rate of premature and low birth weight infants is a major cause of the growing proportion of visual impairment due to brain injury.<sup>6</sup> However, the true prevalence of CVI is probably even higher than currently estimated, because better diagnostic techniques are being developed to examine children with visual impairment due to brain disorders.<sup>2</sup> While other sequelae of cerebral injury, such as epilepsy, motor dysfunction and mental retardation are clinically evident, impairment of visual functions, such as visual acuity (VA) and visual field (VF), may easily escape identification.<sup>7,8</sup>

The assessment of visual function, especially VF examination, is essential in children with brain disorders for several reasons. For instance, early recognition of visual problems is important for correct interpretation of a child's behavior, parent counseling, and for the timely initiation of an appropriate rehabilitation strategy. Besides, assessment of visual function may play a significant role in monitoring the progression of a brain disorder, in determining a child's prognosis and in evaluating the presence of a preexisting VF defect in children eligible for epilepsy surgery. Furthermore, results of visual examination may also facilitate the diagnosis of cerebral disorders.

Unfortunately, assessment of visual function represents a major challenge in young and neurologically impaired children. In addition, available methods, mainly those used to assess the VF in these children, are relatively unknown and not widely used.

## VISUAL PATHWAYS OF THE BRAIN

Visual information enters the eye and subsequently travels from the neurons of the retina via the optic nerve to the optic chiasm. After crossing of the bilateral nasal fibers in the chiasm, it continues through the optic tracts, and subsequently travels from the lateral geniculate body through the optic radiation (OR) to the primary striate visual cortex located in the occipital lobe, in which basic processing takes place (see Figure 1).<sup>9,10</sup> Development of this visual system progresses rapidly in the first years of life by influence of changes in photoreceptor organization, myelination of the visual pathways and developing neural connectivity.<sup>11</sup>

These changes are responsible for a rapid development of VA in the first few months of life, followed by a slower development until adult levels are reached by the age of 3-4 years.<sup>11</sup> In parallel, the extension of the VF expands with age in the first years of life.<sup>12,13</sup> However, the exact course of development of the VF is unknown, since the assessed boundaries of the VF also depend on the examination method used.<sup>12,14</sup>

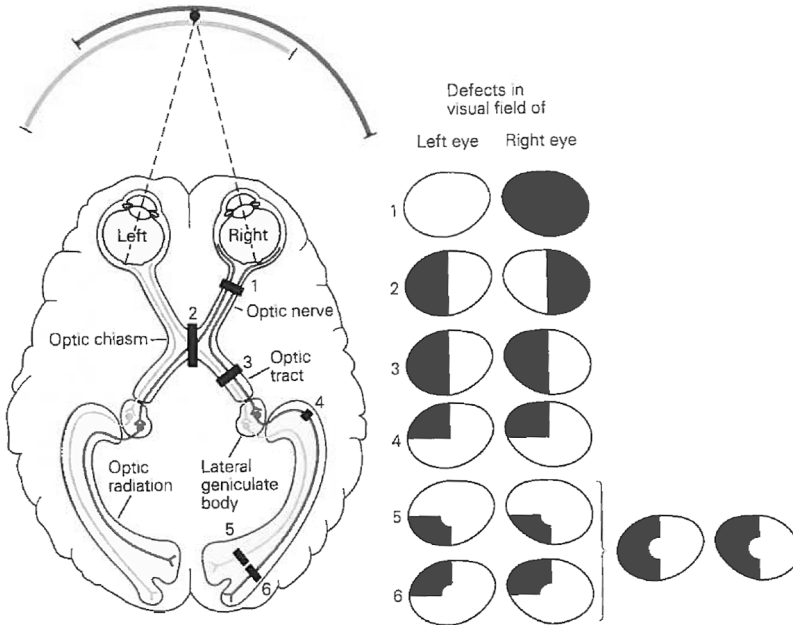
The cerebral part of the visual system can be affected in several ways, for instance by genetic disorders, malformations, metabolic diseases, hypoglycemic injury, hypoxic-ischemic injury,

### **Box 1. Cerebral Visual Impairment**

Cerebral Visual Impairment (CVI) is defined as *“visual malfunction due to retro-chiasmal visual and visual association pathway pathology, which can be isolated or accompany anterior visual pathway dysfunction”*.<sup>5</sup> It is a heterogeneous disorder, which forms a major cause of visual impairment in children worldwide. CVI is also referred to as cortical visual impairment, however, this term is less adequate, since the neurological pathology causing CVI does not necessarily have to be limited to the visual cortex, but may also comprise the optic radiation, visual association areas or the pathways responsible for higher visual functioning.<sup>81</sup> Formerly, the disorder was known as cortical blindness. This term was abandoned since nearly all patients have a certain degree of vision and are rarely completely blind.<sup>81</sup>

infection, elevated intracranial pressure (ICP), epilepsy or traumatic injury.<sup>5,15</sup> All these disorders may impair development of, or cause damage to, neurons along the visual pathways. As consequence of this neuronal pathology, anterograde – “dying forward”, caused by loss of input – or retrograde transneuronal degeneration – “dying backward”, caused by loss of trophic support from the target – may occur.<sup>16</sup>

**Figure 1. Defects in the visual field produced by lesions at various points along the visual pathways**



Source: Kandel, E.R., Schwartz, J.H. & Jessell, T.M. Principles of Neural Science, 4/e. The McGraw-Hill Companies. Part V: Perception, Chapter 27: Central Visual Pathways, p544 (2000).

The kind of visual impairment caused by brain disorders mainly depends on the location of injury.<sup>17</sup> Figure 1 gives a systematic overview on how the VF is generally affected by brain lesions on different locations along the visual pathways.

The visual system is a complex entity, and several additional factors may play a role in the perceived (functional) visual impairment. For instance, there are various extrastriate visual association areas located near the primary striate visual cortex, each responsible for different visual aspects e.g. processing motion, depth perception, color, size estimation, three-dimensional features, visual search or target selection.<sup>18</sup> Injury to a selection of these areas may impair specific aspects of vision.

In addition, damage of the pathways that serve the higher visual functions, such as the dorsal (“where”) and the ventral (“what”) stream, may impair interpretation of the visual information received by the visual cortex. In particular, damage of the dorsal stream, reaching to the posterior parietal lobes, may impair visual search and visually guided movement, while damage of the ventral stream, reaching to the temporal lobes, may impair recognition.<sup>5,18</sup> Furthermore, compensation or restoration of visual impairment, optimizing functional visual capacities by means of physical adaptations or neuronal plasticity, might occur.<sup>19–21</sup>

Regarding physical adaptations, an anomalous head posture (AHP)<sup>22–26</sup> and exotropia (XT)<sup>23,25,27–32</sup> contralateral to the side of brain damage may compensate a VF defect in children and adults with early brain injury. In fact, an XT may create a more panoramic view and broaden the functional VF, while an AHP may center the VF and enables efficient scanning of the surroundings. In addition, possible neuronal plasticity, mainly present in the developing infant brain, might result in a more favorable outcome than expected when considering a child’s brain damage.<sup>20,21</sup> Possible explanations of this phenomenon include formation of new interhemispheric connections, reorganization in nearby unaffected cortex or changes in functional interaction between higher-level visual cortical areas and the primary visual areas.<sup>33</sup>

## EXAMINATION OF VISUAL FUNCTION

Assessment of the visual functions in young or neurologically impaired children requires an alternative approach than the standard conventional perimetry (SCP) methods used in adults. There are several methods available for children in specific functional age ranges according to the expected capabilities of the child at that particular age. These methods are described below, with focus on the techniques that are applied in the studies described in this thesis.

### Visual field assessment

Table 1 provides an overview of available VF examination methods that can be used in young or neurologically impaired children, separated into SCP,<sup>34</sup> confrontational behavioral (see Figure 2 & 3), eye-tracker and multifocal Visual Evoked Potential (mVEP) methods.

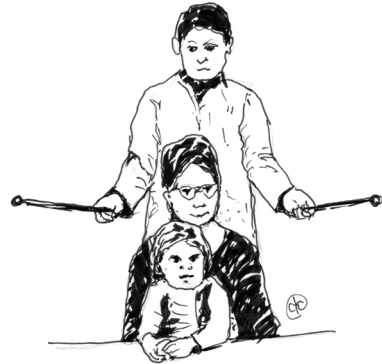In general, standard computer assisted perimetry techniques are preferred in both research and patient care, since they are found to be sensitive and reliable. Moreover, they provide quantitative data. Most of these techniques are difficult for children to perform, since they require comprehension, full cooperation, prolonged attention and visual fixation.<sup>35,36</sup> Consequently, when these characteristics are lacking, such as in young or multi handicapped patients, an appropriate alternative must be chosen with an adequate balance between feasibility and reliability of the method.

The standard perimetry of choice performed in our center by older and more cooperative children is the Rodenstock Peritest.<sup>37</sup> This technique enables the detection of concentric, hemianopic and quadrantanopic VF defects, as well as enlarged blind spots, widespread defects, central scotomas, sensitivity decreases, paracentral scotomas, nasal restrictions (or step) and arcuate defects. SCP methods such as Goldmann<sup>34,38</sup>, Frequency Doubling Technology (FDT)<sup>39,40</sup>, SITA Fast<sup>34,41</sup> or standard Humphrey perimetry<sup>42</sup> were also sometimes used in the children described in this thesis. Although these SCP could be adapted to the needs of children (i.e. shorter testing time or intervals), they are still often unsuccessful in healthy children younger than 6 years of age, despite extensive explanation and coaching by the examiner.<sup>43</sup>

**Figure 2. Confrontational behavioral visual field examination methods**




**A. Donder's confrontational method<sup>44</sup>**



**B. Stycar balls<sup>45-47</sup>**



**C. Double-arc perimeter<sup>25,49,50</sup>**



**D. Translucent sphere perimeter<sup>45,51</sup>**

Source: Drawn by Anton Koenraads, inspired on figures in "Dutton, G. & Bax, M. Visual impairment in children due to damage to the brain. Clin. Dev. Med. No. 186. Mac Keith Press (2010)", "Good, W. V et al. Cortical visual impairment in children. Surv. Ophthalmol. 1738, 351-364 (1994)" and "Stilma, J. S. & Voorn, T. B. in Praktische huisartsgeneeskunde: Oogheelkunde 40-43 (2002)"

**Table 1. Visual field examination methods that can be used in young or neurologically impaired children**

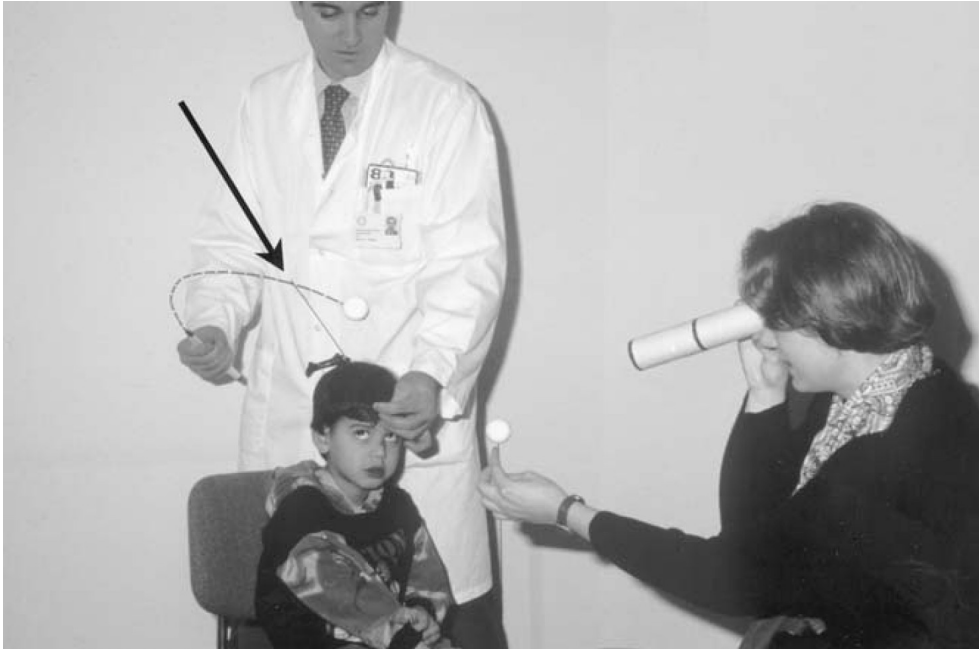<b>Method</b>	<b>Principle</b>	<b>Advantage</b>	<b>Disadvantage</b>
<b>Conventional (SCP)</b>			
<b>Octopus perimetry</b> <sup>34,35</sup>	Automatic static	Short test duration	Preliminary familiarization phase Requires cooperation & steady fixation
<b>Humphrey SITA Fast</b> <sup>34,41</sup>	Automatic static	Short test duration	Requires cooperation & steady fixation
<b>FDT perimetry</b> <sup>39,40</sup>	Automatic static	Short test duration Attractive target Less frightening (no bowl)	Only central VF Requires steady fixation
<b>Rodenstock Peritest</b> <sup>37</sup>	Automatic and semi-automatic static	Can be adjusted to the child's needs	Requires steady fixation
<b>Goldmann perimetry</b> <sup>34,38</sup>	Manual kinetic	Most effective conventional method in young children	Requires a trained examiner Requires steady fixation
<b>Confrontational behavioral</b>			
<b>Donder's confrontational method</b> <sup>44</sup>	Detection of moving fingers of examiner	No tools are needed	Requires cooperation of the child Very imprecise assessment
<b>Stycar balls</b> <sup>45-47</sup>	Black sticks with white balls (different sizes)	Easy to perform Can be performed from the age of 6 months	Only evident VF defects can be detected
<b>Double-arc perimeter</b> <sup>48,49,50</sup>	Two graded arcs with a white fixation target in the middle	Examination of horizontal, vertical and diagonal meridians	Not much freedom of movement The arc construction might be frightening Only peripheral VF



<b>Translucent sphere perimetry</b> <sup>4,5,51</sup>	Graded translucent sphere on which lights are applied	Assessment of all possible locations in VF Fixation point can be turned off	Might be frightening Not much freedom of movement
<b>BEFIE test</b> <sup>13,48</sup>	Graded arc, fixation target and positioning stick (see Figure 3 & Chapter 2)	Assessment of horizontal, vertical and diagonal meridians Child has freedom of movement Is considered a game	Requires trained observer & examiner Only peripheral VF
<b>Eye-tracker</b> <sup>52-58</sup>			
<b>SVOP</b> <sup>52,53,57</sup>	White dots/pictograms appear on the screen on different positions	Relatively objective	Requires concentration & cooperation Moderate freedom of movement Only central VF Not possible with nystagmus
<b>Bartiméus perimetry</b> <sup>56,58</sup>	Moving fixation target (pictogram), stimulus appears on position relative to it	Relatively objective Moving fixation target is attractive to children Comparable to Goldmann V4/III	Moderate freedom of movement Measures only mid-peripheral VF (20 to 40 degrees)
<b>Preferential Looking Perimeter</b> <sup>54</sup>	Screen with webcam, cartoon with sound suddenly moves to another place	Cartoon with sound is attractive to children	Tracking of eye-movements by observer → less objective Only central VF
<b>Multifocal VEP</b> <sup>59-6</sup>			Objective Imprecise measurement Measures only primary visual cortex

To solve this problem, confrontational behavioral methods have been developed to assess the VF of children who are unable to perform SCP (see Figure 2). While Donders' confrontational method<sup>44</sup> and 'binocular directional preference' using two Stycar balls on a stick<sup>45-47</sup> were used in few children described in this thesis, the preferred type of confrontational behavioral method that is frequently used in our center is the BEhavioral visual FIEld (BEFIE) screening test<sup>13,48</sup> (see Figure 3 & Chapter 2). This device was developed in 1995 by Porro et al.<sup>13</sup> in order

**Figure 3. BEhavioral visual FIEld (BEFIE) screening test**



Source: Porro, G., et al. A new behavioural visual field test for clinical use in pediatric neuro-ophthalmology. *Neuro-Ophthalmology* 19, 205-214 (1998).

to measure the peripheral VF in young and neurologically impaired children. With the BEFIE test, concentric, hemianopic and quadrantanopic VF defects can be easily detected from the age of four months onwards, even in children with brain disorders. Although not yet widely in use elsewhere, in our experience the BEFIE test can play an important role in the examination of VFs in young children with (suspected) brain disorders.

### **Visual acuity assessment**

There are several methods to assess VA in young or neurologically impaired children. VA examination methods used in our center and described in this thesis, from easiest to most difficult to perform, include the Teller Acuity Cards (TAC)<sup>45,65</sup>, the Cardiff Acuity Test<sup>66,67</sup>, the Kays Picture Chart<sup>68-70</sup> and Snellen Charts.<sup>71</sup> The most appropriate method is individually chosen depending on the age and cooperation of the child.

The TAC<sup>45,65</sup> and the Cardiff Acuity Test<sup>66,67</sup> both can be performed from very young age onwards. These techniques make use of the 'forced preferential looking' principle, that is based on the observation that infants have a greater tendency to look at a pattern stimulus than at a homogeneous field. Both techniques measure resolution acuity, which is the smallest separation between bars in a grating (or dots) that can be resolved. When a child is able to recognize and name pictograms, the Kays Picture Chart<sup>68-70</sup> can be performed, which measures recognition acuity. Recognition acuity is based on the detail in the smallest pictogram (or number or letter) that can be recognized. In older children and adults, Snellen Charts<sup>71</sup> such as Landolt rings and E-hooks – *measuring resolution acuity* – or numbers and letters – *measuring recognition acuity* – are being used.<sup>72</sup>

Since the results obtained with these various techniques have different underlying principles, they are very difficult to compare. Therefore, the best way to present these heterogeneous results together is after transformation to Logarithm of the Minimum Angle of Resolution (LogMAR).<sup>73</sup> On the LogMAR-scale, 0.0 LogMAR represents normal vision, low vision is defined as a VA worse than 0.5 LogMAR and blindness as worse than 1.3 LogMAR, established by the World Health Organization.<sup>74</sup>

If quantitative VA assessment cannot be performed, observation of visual fixation may provide some information about the presence or absence of visual perception.

### **Optic disc assessment**

The optic disc can be assessed by means of dilated funduscopy. However, uncooperative children, especially those who are neurologically impaired, may be difficult to examine. As they refuse funduscopy or only permit a short observation, an experienced examiner is often required. If successful, observation of the optic disc through funduscopy may provide information on the existence of e.g. elevated ICP (papilledema or atrophy), retrograde transneuronal degeneration (atrophy) or glaucoma (excavation). In addition to funduscopy, optic disc abnormalities can be objectified by ancillary investigations such as Ultrasonography (USG), Fluorescein Angiography (FA) or Optical Coherence Tomography (OCT).

### **Orthoptic exam and postural observations**

Ocular alignment and eye movement of the child can be assessed by an orthoptist by means of light reflexes, the covertest and pursuit movements.<sup>75</sup> This examination may e.g. reveal strabismus, such as an exodeviation (exotropia, XT) or esodeviation (esotropia, ET), which may be intermittent or continuous.

Postural observation may reveal a head turn or torticollis, sometimes used by children to optimize visual functioning.

### **Neuroimaging of the visual pathways**

To assess the integrity of the visual pathway, neuroimaging can be performed using Magnetic Resonance Imaging (MRI). Advanced MRI techniques such as Diffusion Tensor Imaging (DTI)<sup>76-78</sup> and functional MRI (fMRI)<sup>79</sup> are used, mainly in investigational settings, to gain more information about the integrity of visual tracts, and localization of visual functions.

The DTI technique relies on the fact that diffusion of water molecules in brain tissue is not free but restricted, reflecting the interaction with e.g. macromolecules, fibers and membranes.<sup>78</sup>

By measuring the directionality of water diffusion in white matter of the brain, the probable topographic location and integrity of white matter tracts (such as the OR) can be assessed noninvasively. With tractography, probable white matter structures that connect two parts in the brain can be visualized three-dimensionally. In addition, for quantitative analysis, measures of anisotropy – such as *fractional anisotropy (FA)*, *axial diffusivity ( $\lambda_{\parallel}$ )*, *radial diffusivity ( $\lambda_{\perp}$ )* – and of overall diffusion – *mean diffusivity (MD)* – can be determined.

The fMRI technique can be used to gain functional information of cortical representation of visual functions.<sup>80</sup>

## AIM AND CONTENT OF THIS THESIS

The general aim of the studies described in this thesis was to gain more insight in the diagnostic and prognostic implications of visual field (VF) examination in children with brain disorders. With this work, we hope to create more awareness of cerebral visual impairment (CVI) and of the possibilities to assess the VFs of young and neurologically impaired children.

The specific aims of this thesis were:

- ▶ To evaluate all VF examinations that were performed with the BEhavioral visual FIEld (BEFIE) screening test, a device developed in 1995 by Porro et al.<sup>13</sup> in order to measure the peripheral VF in young and neurologically impaired children (Chapter 2). We aimed to assess its applicability, reliability, consistency of findings across time, and potential diagnostic value compared with standard conventional perimetry (SCP)
- ▶ To explore the possibility to predict clinical VF defects based on neuroimaging abnormalities at the age of 3 months in infants after perinatal arterial ischemic stroke (PAIS) (Chapter 3)
- ▶ To evaluate the VF defects found in children suspected of intracranial pressure (ICP) elevation, and to describe long-term visual outcome in those with increased ICP who underwent repeated testing (Chapter 4)
- ▶ To present a systematic review of previous literature on visual outcome of patients with Sturge-Weber syndrome (SWS), and report on the visual acuity (VA) and VF examination findings in a Dutch multicenter cohort of patients with SWS (Chapter 5)
- ▶ To investigate the visual outcome and the prevalence of compensatory mechanisms (CMs) for homonymous hemianopia (HH) after hemispherectomy in children (Chapter 6)

## REFERENCES

1. Chong, C. & Dai, S. Cross-sectional study on childhood cerebral visual impairment in New Zealand. *J. AAPOS* **18**, 71–74 (2014).
2. Boonstra, N. *et al.* Changes in causes of low vision between 1988 and 2009 in a Dutch population of children. *Acta Ophthalmol.* **90**, 277–286 (2012).
3. Kong, L. An update on progress and the changing epidemiology of causes of childhood blindness worldwide. *J. AAPOS* **16**, 501–507 (2012).
4. Durnian, J. M. *et al.* Childhood sight impairment: a 10-year picture. *Eye (Lond)*. **24**, 112–117 (2010).
5. Philip, S. S. & Dutton, G. N. Identifying and characterising cerebral visual impairment in children: a review. *Clin. Exp. Optom.* **97**, 196–208 (2014).
6. Good, W. V, Jan, J. E., Burden, S. K., Skoczinski, A. & Candy, R. Recent advances in cortical visual impairment. *Dev. Med. Child Neurol.* **43**, 56–60 (2001).
7. Dutton, G. & Bax, M. Visual impairment in children due to damage to the brain. *Clin. Dev. Med. No. 186. Mac Keith Press* (2010).
8. Harbert, M. J., Yeh-Nayre, L. a, O'Halloran, H. S., Levy, M. L. & Crawford, J. R. Unrecognized visual field deficits in children with primary central nervous system brain tumors. *J. Neurooncol.* **107**, 545–9 (2012).
9. De Moraes, C. G. Anatomy of the visual pathways. *J. Glaucoma* **22 Suppl 5**, S2–7 (2013).
10. Goodale, M. A. The functional organization of the central visual pathways. Chapter 1 in: Visual impairment in children due to damage to the brain (Edited by G.N. Dutton & M. Bax). *Clin. Dev. Med. No. 186. Mac Keith Press* (2010).
11. The Eye M.D. Association. Pediatric Ophthalmology and Strabismus. American Academy of Ophthalmology.
12. Delaney, S. M. *et al.* Stimulus Motion Increases Measured Visual Field Extent in Children 3.5 to 30 Months of Age. *Optom. Vis. Sci.* **77**, 82–89 (2000).
13. Porro, G., *et al.* A new behavioural visual field test for clinical use in pediatric neuro-ophthalmology. *Neuro-Ophthalmology* **19**, 205–214 (1998).
14. Mercuri, E. *et al.* Neonatal cerebral infarction and visual function at school age. *Arch Dis Child* **88**, F487–F491 (2003).
15. Soul, J. & Matsuba, C. Common aetiologies of cerebral visual impairment. Chapter 2.1 in: Visual impairment in children due to damage to the brain (Edited by G.N. Dutton & M. Bax). *Clin. Dev. Med. No. 186. Mac Keith Press* (2010).
16. Beatty, R., Sadun, A., Smith, L., Vonsattel, J. & Richardson, E. Direct demonstration of transsynaptic degeneration in the human visual system: a comparison of retrograde and anterograde changes. *J. Neurol. Neurosurg. Psychiatry* **45**, 143–146 (1982).
17. Kandel, E. R., Schwartz, J. H. & Jessell, T. M. Principles of Neural Science, 4/e. The McGraw-Hill Companies. Part V: Perception, Chapter 27: Central Visual Pathways. 544 (2000).
18. Suter, P. S. & Harvey, L. H. Vision Rehabilitation: Multidisciplinary Care of the Patient Following Brain Injury. Taylor & Francis Group, LLC. CRC Press. (2011).
19. Koenraads, Y. *et al.* Visual function and compensatory mechanisms for hemianopia after hemispherectomy in children. *Epilepsia* **55**, 909–917 (2014).
20. Guzzetta, A. *et al.* Plasticity of the visual system after early brain damage. *Dev. Med. Child Neurol.* **52**, 891–900 (2010).
21. Guzzetta, A., Fiori, S., Scelfo, D., Conti, E. & Bancalè, A. Reorganization of visual fields after periventricular haemorrhagic infarction: potentials and limitations. *Dev. Med. Child Neurol.* **55 Suppl 4**, 23–6 (2013).
22. Paysse, E. A. & Coats, D. K. Anomalous Head Posture With Early-Onset. *J AAPOS* **1**, 209–13 (1997).

## Chapter 1

23. Donahue, S. P. & Haun, A. K. Exotropia and face turn in children with homonymous hemianopia. *J. Neuroophthalmol.* **27**, 304–7 (2007).
24. Zangemeister, W. H., Meienberg, O., Stark, L. & Hoyt, W. F. Eye-head coordination in homonymous hemianopia. *J. Neurol.* **226**, 243–54 (1982).
25. Good, W. V. *et al.* Cortical visual impairment in children. *Surv. Ophthalmol.* **1738**, 351–364 (1994).
26. Porro, G., van der Linden, D., van Nieuwenhuizen, O. & Wittebol-Post, D. Role of visual dysfunction in postural control in children with cerebral palsy. *Neural Plast.* **12**, 205–10; discussion 263–72 (2005).
27. Jacobson, L., Lennartsson, F., Pansell, T., Oqvist Seimyr, G. & Martin, L. Mechanisms compensating for visual field restriction in adolescents with damage to the retro-geniculate visual system. *Eye (Lond)*. **26**, 1437–45 (2012).
28. Herzau, V., Bleher, I. & Joos-kratsch, E. Infantile exotropia with homonymous hemianopia : a rare contraindication for strabismus surgery. *Graefe 's Arch. Ophthalmol.* **1**, 148–149 (1988).
29. Levy, Y., Turetz, J., Krakowski, D., Hartmann, B. & Nemet, P. Development of compensating exotropia with anomalous retinal correspondence after early infancy in congenital homonymous hemianopia. *J. Pediatr Ophthalmol Strabismus* **3**, 236–238 (1995).
30. Saleh, G., Sivaprasad, S. & Hammond, C. Homonymous hemianopia and exotropia: an important management issue. *Eye (Lond)*. **20**, 1402–1404 (2006).
31. Gote, H., Gregersen, E. & Rindziunski, E. Exotropia and panoramic vision compensating for an occult congenital homonymous hemianopia. A case report. *Binoc Vis. Eye Muscle Surg Q* **8**, 129–132 (1993).
32. Gamio, S. & Melek, N. When the patient says no. Management of exotropia with hemianopic visual field defects. *Binocul Vis Strabismus Q* **18**, 167–170 (2003).
33. Urbanski, M., Coubar, O. a & Bourlon, C. Visualizing the blind brain: brain imaging of visual field defects from early recovery to rehabilitation techniques. *Front. Integr. Neurosci.* **8**, 74 (2014).
34. Patel, D. E. *et al.* Study of optimal perimetric testing in children (OPTIC): Feasibility, reliability and repeatability of perimetry in children. *PLoS One* **10**, 1–12 (2015).
35. Safran, a B. *et al.* Feasibility of automated visual field examination in children between 5 and 8 years of age. *Br J Ophthalmol* **80**, 515–518 (1996).
36. Tschopp, C. *et al.* Automated visual field examination in children aged 5–8 years. Part I: Experimental validation of a testing procedure. *Vision Res.* **38**, 2203–10 (1998).
37. Greve, E. L., Dannheim, F. & Bakker, D. The Peritest, a new automatic and semi-automatic perimeter. *Int. Ophthalmol.* **5**, 201–14 (1982).
38. Kolling, G. H. & Wabbels, B. Symposium Proceedings Part II Kinetic perimetry in neuroophthalmological practice. **8**, (2000).
39. Blumenthal, E. Z., Haddad, A., Horani, A. & Anteby, I. The reliability of frequency-doubling perimetry in young children. *Ophthalmology* **111**, 435–9 (2004).
40. Quinn, L. M., Gardiner, S. K., Wheeler, D. T., Newkirk, M. & Johnson, C. a. Frequency doubling technology perimetry in normal children. *Am. J. Ophthalmol.* **142**, 983–9 (2006).
41. Donahue, S. P. & Porter, a. SITA visual field testing in children. *J. AAPOS* **5**, 114–7 (2001).
42. Beck RW, Bergstrom TJ, L. P. A clinical comparison of visual field testing with a new automated perimeter, the Humphrey Field Analyzer, and the Goldmann perimeter. *Ophthalmology*. **92**, 77–82 (1985).
43. Porro, G. L. & Wittebol-Post, D. Impairment of peripheral vision and its measurement. Chapter 5 in: Visual impairment in children due to damage to the brain (Edited by G.N. Dutton & M. Bax). *Clin. Dev. Med. No. 186. Mac Keith Press* (2010).



44. Stilma, J. S. & Voorn, T. B. in *Praktische huisarts-geneeskunde: Oogheelkunde* 40–43 (2002).
45. Mohn, G. & Van Hof-van Duin, J. Behavioural and electrophysiological measures of visual functions in children with neurological disorders. *Behav. Brain Res.* **10**, 177–87 (1983).
46. Hermans, A., Van Hof-van Duin, J. & Oude-sluis-Murphy, A. Visual outcome of low-birth-weight infants (1500–2500 g) at one year of corrected age. *Acta Paediatr.* **83**, 402–7 (1994).
47. Sheridan MD. The STYCAR graded-balls vision test. *Dev Med Child Neurol.* **15**, 423–32 (1973).
48. Koenraads, Y., Braun, K. P. J., van der Linden, D. C. P., Imhof, S. M. & Porro, G. L. Perimetry in Young and Neurologically Impaired Children: The Behavioral Visual Field (BEFIE) Screening Test Revisited. *JAMA Ophthalmol.* **133**, 319–25 (2015).
49. Quinn, G. E. *et al.* Visual Fields Measured with Double-arc Perimetry in Eyes with Threshold Retinopathy of Prematurity from the Cryotherapy for Retinopathy of Prematurity Trial. *Ophthalmology* **103**, 1432–1437 (1996).
50. Dobson, V., Brown, a M., Harvey, E. M. & Narter, D. B. Visual field extent in children 3.5–30 months of age tested with a double-arc LED perimeter. *Vision Res.* **38**, 2743–60 (1998).
51. Mayer, D. L., Fulton, a B. & Cummings, M. F. Visual fields of infants assessed with a new perimetric technique. *Invest. Ophthalmol. Vis. Sci.* **29**, 452–9 (1988).
52. Murray, I. C. *et al.* Feasibility of saccadic vector optokinetic perimetry: a method of automated static perimetry for children using eye tracking. *Ophthalmology* **116**, 2017–26 (2009).
53. Murray, I. *et al.* Saccadic Vector Optokinetic Perimetry (SVOP): A novel technique for automated static perimetry in children using eye tracking. *Conf Proc IEEE Eng Med Biol Soc.* **2013**, 3186–9 (2013).
54. Allen, L. E., Slater, M. E., Proffitt, R. V, Quanton, E. & Pelah, A. A new perimeter using the preferential looking response to assess peripheral visual fields in young and developmentally delayed children. *J. AAPOS* **16**, 261–5 (2012).
55. Pel, J. J. M., van Beijsterveld, M. C. M., Thepass, G. & van der Steen, J. Validity and Repeatability of Saccadic Response Times Across the Visual Field in Eye Movement Perimetry. *Transl. Vis. Sci. Technol.* **2**, 3 (2013).
56. De Wit, G. Bartimeus eyetracker project. at <<https://www.bartimeus.nl/expertise/projecten/projectresultaten/project-eyetracker>>
57. Tailor, V. *et al.* Saccadic vector optokinetic perimetry in neuro-disability or isolated visual pathway lesions: observational cohort study. *Under Rev.* 1–6 (2016).
58. Wit, G. C. de, Hoeven, F. & Genderen, M. van. Objectieve gezichtsveldbepaling bij verdenking conversie met behulp van eye-tracking. *NOG Congr. Groningen* (2015).
59. Harding, G. F. a, Spencer, E. L., Wild, J. M., Conway, M. & Bohn, R. L. Field-specific visual-evoked potentials: identifying field defects in vigabatrin-treated children. *Neurology* **58**, 1261–5 (2002).
60. Kim, Y.-J., Yukawa, E., Kawasaki, K., Nakase, H. & Sakaki, T. Use of multifocal visual evoked potential tests in the objective evaluation of the visual field in pediatric epilepsy surgery. *J. Neurosurg.* **104**, 160–5 (2006).
61. Klistorner, a I., Graham, S. L., Grigg, J. & Balachandran, C. Objective perimetry using the multifocal visual evoked potential in central visual pathway lesions. *Br. J. Ophthalmol.* **89**, 739–44 (2005).
62. Spencer, E. L. & Harding, G. F. a. Examining visual field defects in the paediatric population exposed to vigabatrin. *Doc. Ophthalmol.* **107**, 281–7 (2003).
63. Yukawa, E., Kim, Y.-J., Kawasaki, K., Taketani, F. & Hara, Y. A child with epilepsy in whom multifocal VEPs facilitated the objective measurement of the visual field. *Epilepsia* **46**, 577–9 (2005).
64. Yukawa, E., Matsuura, T., Kim, Y.-J., Taketani, F. & Hara, Y. Usefulness of multifocal VEP in a child requiring

- perimetry. *Pediatr. Neurol.* **38**, 360–2 (2008).
65. Teller, D., McDonald, M., Preston, K., SL, S. S. & Dobson, V. Assessment of visual acuity in infants and children: the acuity card procedure. *Dev Med Child Neurol.* **28**, 779–89 (1986).
66. Adoh, T., Woodhouse, J. & Oduwaiye, K. The Cardiff Test: A New Visual Acuity Test for Toddlers and Children with Intellectual Impairment. A Preliminary Report. *Optom. Vis. Sci.* **69**, 427–432 (1992).
67. Adoh, T. O. & Woodhouse, J. M. The Cardiff acuity test used for measuring visual acuity development in toddlers. *Vision Res.* **34**, 555–560 (1994).
68. Jones, D., Westall, C., Averbeck, K. & Abdolell, M. Visual acuity assessment: A comparison of two tests for measuring children's vision. *Ophthalmic Physiol. Opt.* **23**, 541–546 (2003).
69. Kay, H. New method of assessing visual acuity with pictures. *Br. J. Ophthalmol.* **67**, 131–133 (1983).
70. Elliott, M. C. & Firth, a Y. The logMAR Kay picture test and the logMAR acuity test: a comparative study. *Eye (Lond).* **23**, 85–88 (2009).
71. Hetherington, R. The Snellen chart as a test of visual acuity. *Psychol Forsch.* **24**, 349–57 (1954).
72. Pointer, J. S. Recognition versus Resolution: a Comparison of Visual Acuity Results Using Two Alternative Test Chart Optotype. *J. Optom.* **1**, 65–70 (2008).
73. Rosser, D. a, Laidlaw, D. a & Murdoch, I. E. The development of a 'reduced logMAR' visual acuity chart for use in routine clinical practice. *Br. J. Ophthalmol.* **85**, 432–436 (2001).
74. World Health Organization. *International Statistical Classification of Diseases and Related Health Problems 10th Revision. ICD-10 Version.* (2010). at <<http://apps.who.int/classifications/icd10/browse/2010/en>>
75. Blaikie, a. J. & Dutton, G. N. How to assess eyes and vision in infants and preschool children. *Bmj* **350**, h1716–h1716 (2015).
76. Feldman, H. M., Yeatman, J. D., Lee, E. S., Barde, L. H. F. & Gaman-bean, S. Diffusion Tensor Imaging : A Review for Pediatric Researchers and Clinicians.
77. Ramenghi, L. a *et al.* Neonatal neuroimaging: going beyond the pictures. *Early Hum. Dev.* **85**, S75–7 (2009).
78. Basser, P. J., Mattiello, J. & LeBihan, D. MR Diffusion Tensor Spectroscopy and Imaging. *Biophys. J.* **66**, 259–267 (1994).
79. Ogawa, S., Lee, T., Nayak, A. & Glynn, P. Oxygenation-sensitive contrast in magnetic resonance image of rodent brain at high magnetic fields. *Magn Reson Med.* **14**, 68–78 (1990).
80. McFadzean, R., Condon, B. & Barr, D. Functional magnetic resonance imaging in the visual system. *J Neuroophthalmol.* **19**, 186–200 (1999).
81. Ospina, L. Cortical visual impairment. *Pediatr Rev.* **30**, e81–90 (2009).

# 2

## **Perimetry in young and neurologically impaired children: The Behavioral Visual Field (BEFIE) Screening Test revisited**

Yvonne Koenraads

Kees P.J. Braun

Denise C.P. van der Linden

Saskia M. Imhof

Giorgio L. Porro



*JAMA Ophthalmology* 2015 Mar;133(3):319-25

## ABSTRACT

### Importance

Visual field examination in young or neurologically impaired children is a challenge. As a result, the BEhavioral visual FIEld (BEFIE) screening test was developed in 1995.

### Objectives

To evaluate the applicability of the BEFIE test in a large population of young or neurologically impaired children, its reliability and consistency of findings across time, and its potential diagnostic value compared with standard conventional perimetry.

### Design, setting, and participants

The BEFIE tests were performed at an academic tertiary center and measured the peripheral visual field extension in degrees by observing an individual's response to a stimulus on a graded arc that moved from the periphery to the center of the visual field along different meridians. Patient files from all children who underwent this test were retrospectively analyzed. In total, 1788 BEFIE tests were performed in 835 children (median age, 3.4 years).

### Main outcomes and measures

Reliability and results of all tests were longitudinally evaluated. The diagnostic value of the BEFIE test was assessed by comparing monocular BEFIE test results with those of standard conventional perimetry in children who underwent both.

### Results

Of 1788 tests, 74% (95% CI, 72%-76%) were considered reliable from the age of 4 months and older, with increasing success with higher ages; 56%reliable in children younger than 1 year; 71%reliable in children between 1 and 2 years; and more than 75%reliable in children 2 years and older (Spearman  $r=0.506$ ;  $P=0.11$ ). Peripheral visual field defects were found in 28% (95%

CI, 25%-31%) of all first reliable tests. In 75% of children who underwent serial testing, results were consistent and there were good explanations in the case of discrepancies. Comparison of monocular BEFIE tests with standard conventional perimetry results in 147 eyes yielded a positive predictive value of 98% (95% CI, 94%-100%), negative predictive value of 66% (95% CI, 56%-75%), specificity of 98% (95% CI, 95%-100%), sensitivity of 60% (95% CI, 50%-71%), and superior sensitivity of 80% (95% CI, 70%-91%) when only absolute peripheral visual field defects at standard conventional perimetry were accounted for.

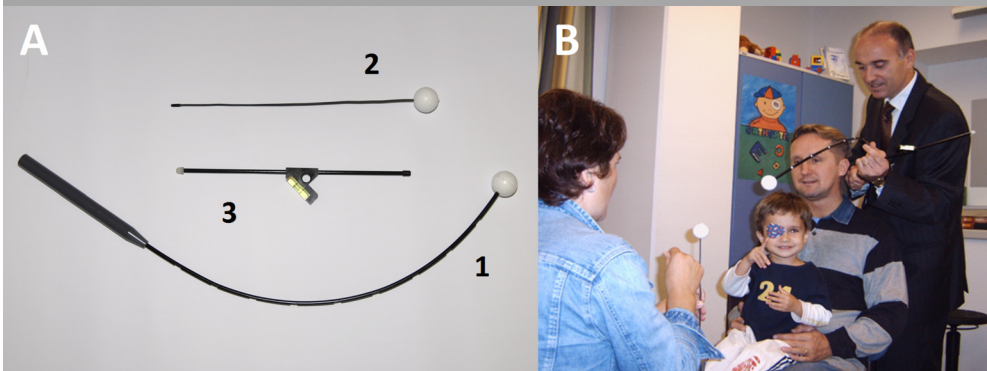
### **Conclusions and relevance**

These data suggest that the BEFIE test is a valuable tool to detect peripheral visual field defects when standard conventional perimetry cannot be performed in young or neurologically impaired children.

## INTRODUCTION

Visual field (VF) examination in young or neurologically impaired children is a challenge.<sup>1-3</sup> Standard conventional perimetry (SCP) requires full cooperation. Even the simpler versions, such as the Goldmann perimeter,<sup>4</sup> Peritest,<sup>5</sup> Humphrey Swedish Interactive Thresholding Algorithm Fast VF Analyzer,<sup>6</sup> or frequency-doubling technology perimetry,<sup>7,8</sup> are often unsuccessful in children younger than 6 years.<sup>1</sup> There is a need for an easy, reliable method to assess the VFs of young children in a clinical setting. In the past, attempts to create an adequate VF test have included techniques that used eye movement observations and eye tracking systems.<sup>9-12</sup> Although these methods have the potential to examine complete VFs in children, it remains a challenge to keep the child focused and attentive, especially when they are too young or disabled. For the same reasons, multifocal visual evoked potential<sup>13</sup> proved not suitable for this population. The known techniques designed to measure VFs in young or neurologically impaired children consist of behavioral methods such as confrontational methods,<sup>3,14</sup> binocular directional preference,<sup>15</sup> kinetic double-arc perimetry,<sup>2,16,17</sup> and translucent sphere perimetry.<sup>3,18</sup> While the simpler behavioral methods only provide a global impression of the peripheral VF, the more sophisticated ones that measure the VF extension in degrees are often insufficient in gaining the cooperation of the child and are difficult to integrate in a consulting room. In 1995, we modified the arc perimeter into a simple behavioral kinetic perimetry device to satisfy the needs of the target population and created the BEhavioral visual FIEld (BEFIE) screening test.<sup>19</sup> This method can be applied to children who are preverbal ages and older. It is based on a graded semicircular arc with a stimulus at the end introduced from behind the VF of the child from the periphery to the center (see Figure 1). The individual's visual (or verbal) response to the stimulus is reported by an observer. This technique combines the advantages of all other behavioral methods; because it quantifies VF extension in degrees, it is easy to perform in clinical practice and is well accepted because the interaction between the observer and the child is considered a game.

**Figure 1. The BEhavioral visual Field (BEFIE) screening test**

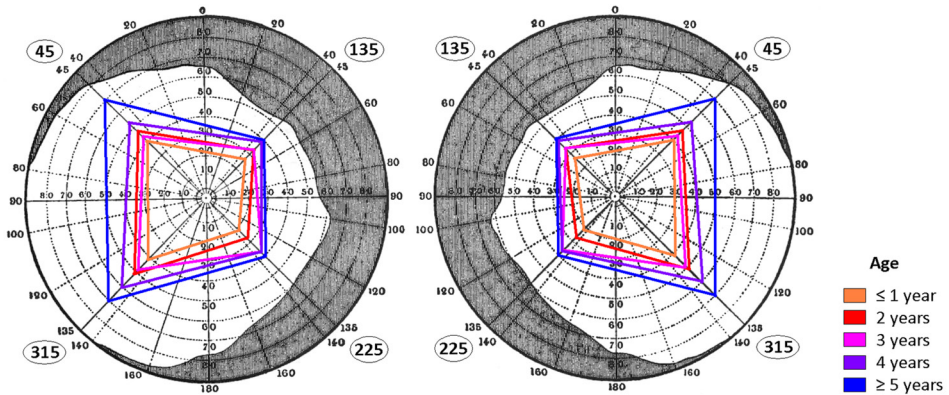


**A Equipment:** (1) graded semicircular black metal arc with a stimulus at the end, (2) fixation target on a stick and (3) stick with a level attached to it, used for positioning.

**B Typical example of the performance:** The arc is rotated by an examiner from behind around the head of the subject in such a way that the white ball moves from the periphery towards the center of the VF, where the fixation target is positioned at 35cm distance by an observer who is facing the child that sits in a (wheel)chair or on its parents lap. When fixation of the child is steadily captured, the ball is introduced into the VF and the observer reports the subject's response (i.e. eye (and head or hand) movements or any verbal answer related to the peripheral stimulus). At the moment of response, the degrees of VF extension along the corresponding half-meridian is measured on the semicircular arc by the examiner. The peripheral stimulus is presented at random along one of the four quadrants and along the horizontal axis (half-meridian at 0, 45, 135, 180, 225, 315 degrees). Each half-meridian is tested three times, of which the mean is noted as the result of that meridian. Before the procedure starts, the examiner familiarizes the child with the stimulus. Subsequently, a binocular test is performed. If a child allows occlusion of an eye with an orthoptic patch, a monocular test is performed.

Since its development, we have extensively applied the BEFIE test. The aim of this study was to retrospectively evaluate its applicability in a large population of young or neurologically impaired children, its reliability and consistency of findings across time, and its potential diagnostic value compared with SCP.

**Figure 2. Age-dependent pathological peripheral visual field limits of the diagonal meridians for the BEFIE test**





## **METHODS**

### **Patient Selection**

All children (<18 years at the first examination) who underwent the BEFIE test between February 1, 1995, and December 31, 2013, were included. The study was approved by the institutional ethical committee of the University Medical Center Utrecht. Written informed consent was obtained, authorizing publication of the child pictured in the photograph in Figure 1. For the other 834 children in the study, our institutional ethical committee decided that written informed consent was not needed.

### **Data Collection**

Patient files were retrospectively analyzed. Demographic and clinical characteristics that were collected included sex, type, location of (suspected) pathology (defined as postchiasmal or prechiasmal), and age at examination.

The BEFIE test was performed with a graded semicircular arc with a white ball (stimulus) at the end, with a fixation target and a stick with a level attached to it used for positioning (see Figure 1).<sup>19</sup> All BEFIE tests were taken by a senior orthoptist (observer) and a pediatric neuro-ophthalmologist (examiner). The methods and test procedure are described more extensively in another study by Porro et al.<sup>19</sup> The test is available at the Medical Workshop (<http://www.medicalworkshop.nl/International>).

### **BEFIE Test Reliability**

Based on the descriptions of the test results noted at the time of assessment, reliability was rated as unsuccessful, doubtful, or reliable by an unblinded assessor, according to predefined criteria. An unsuccessful test included unsuccessful attempts with incomplete final results or results obtained with alternative confrontational approaches such as using toys. A test was rated doubtful when there was an annotation of slow reactions, discordance of the 3 consecutive measurements, more than 3 spontaneous looks, comments of poor cooperation (such

as lack of interest or crying), or absence of a definite conclusion with examiners expressing their uncertainty in the report (using terms such as *possible* or *perhaps*). A test was considered reliable when annotations on good cooperation were made or if none of the criteria listed here indicating impaired reliability were present.

### **Analysis of BEFIE Test Results**

Results of the BEFIE test (binocular and/or monocular) were categorized as normal when the extension was 40° or more nasally and 70° or more temporally, corresponding to the maximum measurable VF with the Peritest method or when the peripheral borders on the diagonal meridians exceeded the age-dependent pathological limits (see Figure 2).<sup>19</sup> For subclassification of abnormal peripheral VF (PVF) defects, see Box 1.

#### **Box 1. Subclassification of peripheral visual field defects**

Results of the BEFIE tests (bin- and/or monocular) were dichotomized as 'normal' or 'abnormal'. A PVF was considered 'normal' when it extended  $\geq 40$  degrees nasally and  $\geq 70$  degrees temporally, corresponding to the maximum measurable VF with the Peritest method. The PVF of children under five years of age was considered 'normal' if the peripheral borders on the diagonal meridians exceeded the age-dependent pathological limits (see Figure 2).<sup>19</sup> A PVF was considered 'abnormal' in all other situations, with a subclassification into (1) symmetric (concentric) PVF defects and (2) asymmetric or homonymous (hemianopic and quadrantanopic) PVF defects. 'Symmetric' and 'asymmetric' PVF defects were further classified in 'severe concentric' or 'complete homonymous' if the peripheral limits reached  $< 20$  degrees nasally or  $< 30$  degrees temporally. The other PVF defects were considered 'incomplete homonymous' or 'moderate concentric' or 'mild concentric' (reaching  $\geq 30$  degrees nasally and  $\geq 60$  degrees temporally). Scotomas were not included in this classification since the test only examines the PVF.

To assess the consistency of results, a longitudinal analysis was done in all children who underwent more than 1 reliable test. We described whether results remained stable, deteriorated, or improved over time and explored possible causal factors for alterations.

### **Comparison With SCP**

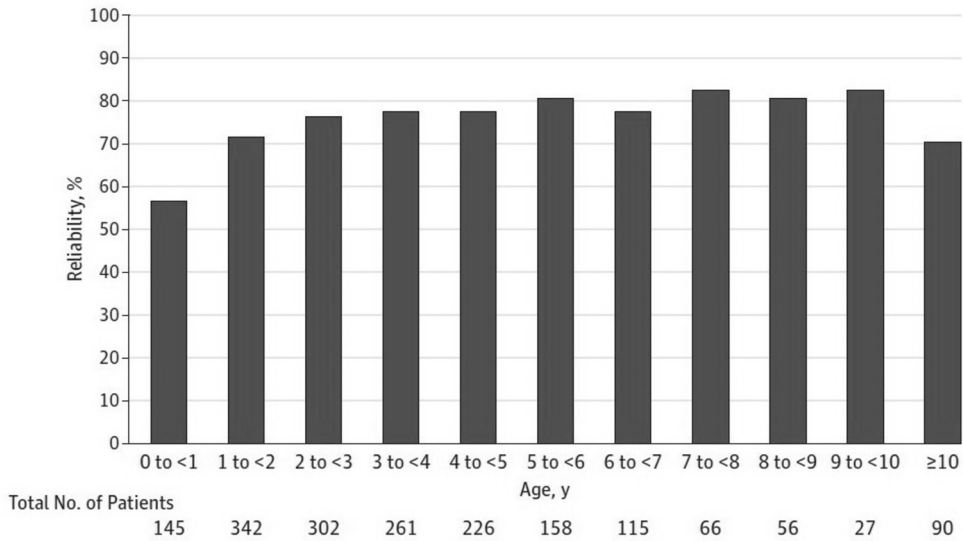
The diagnostic value of the BEFIE test was assessed by comparing its results with those of SCP (reference test). For this purpose, we included all children who underwent a reliable monocular BEFIE test and SCP of the entire VF (including periphery) on the same day or at some time after the BEFIE test. Children with proven progressive underlying disease that could have caused discordance between both results were excluded. When multiple reliably performed BEFIE tests were taken, the one closest in time to the reference test was selected. Different types of SCP used in our center included manual kinetic testing on the Goldmann perimeter, semiautomatic-static testing on the Peritest, or automatic-static testing on the Humphrey Field Analyzer.<sup>5,20</sup> Any of these tests used could be included as reference tests for the analysis. When different SCPs were performed, the Goldmann perimeter was preferred as a reference because its manual kinetic testing was best comparable with the BEFIE test. Measurements on the Humphrey Field Analyzer were least preferred because it was often difficult to perform in children from our cohort. Furthermore, if multiple tests of the same method were present, the first test with the least VF defects was selected to reduce the chance of false-positive VF defects in the reference test itself.

The results of monocular VF measurements of all separate eyes were presented in a frequency table. When static (instead of kinetic) perimetry was used as reference test, the test result was considered normal if fewer than 3 stimuli were missed during the measurement. Visual field measurements not meeting these criteria were considered abnormal. Abnormal VF defects measured with the reference test were further dichotomized into absolute PVF defects and absolute scotomas or relative VF defects. Absolute scotomas included holes in the VF that did not extend to the peripheral borders of the VF or were too small to contain 1 of the half-meridians at 0°, 45°, 135°, 180°, 225°, or 315°. Relative VF defects comprised defects on static perimetry that were not totally missed but only seen at an increased intensity compared with the rest of the VF. All other defects were rated as absolute PVF defects. Positive predictive value, negative predictive value, additional value, specificity, and sensitivity of the BEFIE test were calculated. Possible causes for false-positive or false-negative results were explored.

### Statistical Analysis

Data were analyzed using IBM SPSS Statistics 21 and 95% CI's were calculated for proportions and diagnostic values. The changes in percentages across time were assessed by calculating Spearman correlation coefficients.

**Figure 3. Reliability of all performed BEFIE tests at different ages**



## **RESULTS**

A total of 1788 BEFIE tests were performed in 835 patients (468 male) at a median age of 3.4 years (range, 0.3-27.1 years). The location of (suspected) pathology was postchiasmal in 512 patients.

### **BEFIE Test Reliability**

The first tests (both binocular and monocular) were performed at a median age of 3.1 years (range, 0.3-17.9 years) and were rated as reliable in 69% (95% CI, 66%-72%). Of the 697 children who underwent at least 1 reliable test, the first was performed at the median age of 3.2 years (range, 0.4-17.8 years).

The overall performance was reliable in 74% (95% CI, 72%-76%), doubtful in 14% (95% CI, 12%-16%), and unsuccessful in 12% (95% CI, 10%-14%). The percentage of reliably performed tests increased with age from 56% in children younger than 1 year to 71% in children between 1 and 2 years and more than 75% in children from the age of 2 years (Spearman  $r=0.506$ ;  $P=0.11$ ; see Figure 3). In children 10 years or older, reliability tended to drop. Of all 1330 reliable tests, the percentage of examinations that could be performed monocularly increased with age (Spearman  $r=0.882$ ;  $P=0.001$ ); stabilizing at approximately 80% in children at 6 years (see eFigure).

### **BEFIE Test Results**

Of all 697 first reliable tests (52% monocular), results were normal in 72% ( $n=500$ ; 95% CI, 69%-75%). The abnormal results in the remaining tests included 6% mild concentric, 7% moderate concentric, 5% severe concentric, 11% incomplete hemianopic, 48% complete hemianopic, 13% incomplete quadrantanopic, and 10% complete quadrantanopic PVF defects.

Of the first reliable tests, 431 were performed in patients with (suspected) postchiasmal pathology. Of these tests, 35% (95% CI, 31%-40%) were abnormal (11%, concentric; 64%, hemianopic; and 25%, quadrantanopic) compared with 17% (95% CI, 13%-22%) of the 266 first

reliable tests performed in patients with (suspected) prechiasmal pathology (41%, concentric; 43%, hemianopic; and 16%, quadrantanopic).

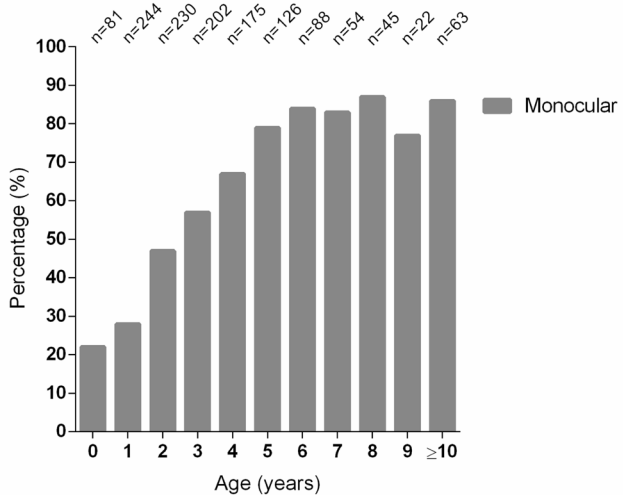
### Longitudinal Results After Repeated Testing

Of the 697 children who underwent at least 1 reliable BEFIE test, 304 had multiple reliable tests (median, 2; range, 2-14) during a median follow-up duration of 1.8 years (range, 0.01-11.4 years). Of these children, 189 had a normal PVF at first examination. In 90% of those, the final measurement still showed normal results. However, 5 children (3%) had 1 abnormal test result during their follow-up. In 19 children (10%), a deterioration of the PVF was seen after the first (normal) test, 8 of whom had developed complete hemianopia after epilepsy surgery during follow-up. Repeated BEFIE tests revealed new concentric PVF abnormalities in 2 children who used vigabatrin and in 3 children

with a possibly progressive disease (Alström syndrome, elevated intraocular pressure, and Leber congenital amaurosis). In the remaining 6 children who all had perinatal ischemic cerebral injury, a suboptimal PVF was already detected at the first examination but did not exceed the age dependent pathological limit and, therefore, was initially scored as normal.

In 115 of the children (38%) with multiple reliable tests, an abnormal PVF was present at the first examination. During a

**Figure. Percentage of reliable BEFIE tests in which monocular examination was feasible as a function of age**

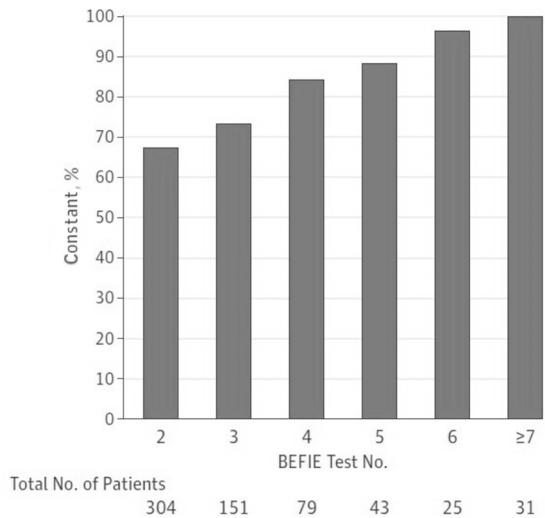


median follow-up of 3 measurements (range, 2-14) in 1.8 years (range, 0.1-9.5 years), 50% had a stable PVF defect, 8% had progressive abnormalities, and 42% revealed improvement of PVF defects. Among the 9 children with deterioration over time, 3 showed a difference of 20° or less while 1 showed homonymous hemianopia secondary to hemispherectomy. Peripheral VF measurements of the other 5 children deteriorated at the transition of a binocular to a monocular measurement. In some children, the first binocular PVF measurements may have been influenced by compensatory strabismus, which was documented in 3 of these children.<sup>21</sup>

Of the 48 children whose PVF improved with longitudinal BEFIE testing, 21 had a normal measurement at the end of follow-up. In 22 children, improvement was 20° or less. Furthermore, in 30 children, improvement was seen during binocular measurements or at the transition of a binocular to monocular measurement or vice versa, 12 of whom had documentation of either convergent or divergent strabismus that could have influenced the binocular measurement.<sup>21</sup> In the remaining 9 children, the cause of PVF improvement was unclear. Learning effects, expansion with age,<sup>22-24</sup> varying attention shifts,<sup>25</sup> and incorrect measurement or neuronal plasticity<sup>26-28</sup> might have played a role.

In Figure 4, the alterations in results of reliable BEFIE tests after multiple examinations in single individuals are summarized by BEFIE test numbers.

**Figure 4. Alterations in results of reliable BEFIE tests after multiple examinations in single individuals after a certain number of BEFIE tests**



### Comparison With SCP

In total, 147 eyes of 79 children without proven progressive underlying disease underwent both a reliable monocular BEFIE test and, after a median period of 1.0 year (range, 0.0-10.7 year), the SCP of the entire VF (61, Goldmann; 79, Peritest; and 7, Humphrey Field Analyzer) at a median age of 8.4 years (range, 5.2-17.5 years). Table 1 shows the results of monocular VF measurements of separate eyes.

The positive predictive value was 98%, with a prior probability of an abnormal VF of 56%. The negative predictive value was 66%. Specificity and sensitivity were 98% and 60%, respectively. The BEFIE method a priori did not allow the detection of relative VF defects or absolute scotomas. Therefore, we recalculated the sensitivity of the BEFIE test when only absolute PVF defects at SCP were taken into account, which was 80% (see Table 1).

There was only 1 false-positive BEFIE test result. In this child, a difference of 25° was found between the BEFIE and Goldmann tests.

Sixty-seven percent of false-negative BEFIE tests showed limited VF defects (either absolute scotomas or relative defects) at SCP. The 11 false-negative BEFIE tests with absolute reference PVF defects included 4 mild concentric defects (2 with vigabatrin use between BEFIE and reference test), 2 moderate concentric defects with a maximal difference of 30° (1 suspected of a central scotoma), 3 incomplete quadrantanopias with a maximal difference of 30°, and 2 complete hemianopias, of which the discrepancy with the BEFIE test remained unexplained.

Of all true-positive VF defects, 80% of BEFIE test results were similar to those of the reference test (with a maximal difference of 20°). Three of the 9 monocular BEFIE tests in which the extent of abnormalities did not completely correspond with the reference test results were performed in children in whom underlying disease may theoretically have progressed during follow-up, although not documented as such (2 with elevated intracranial pressure and 1 with optic pathway glioma). The remaining 6 measurements were performed in children with perinatal brain injury and differences with reference tests included alterations from incomplete hemianopia to complete hemianopia (2 patients), incomplete hemianopia to incomplete quadrantanopia (1 patient), incomplete quadrantanopia to complete quadrantanopia (2 patient) and moderate concentric PVF defect to quadrantanopia (1 patient).



**Table 1. Frequency table of the monocular VF measurements of all separate eyes**

		Standard conventional perimetry (reference test)			
		Normal	Abnormal		Total
			'Absolute PVF defects'	'Absolute scotomas' or 'relative VF defects'	
BEFIE test	Normal	<b>63</b> G(19) P(44) H(0)	<b>11</b> G(8) P(3) H(0)	<b>22</b> G(1) P(14) H(7)	<b>96</b>
	Abnormal	<b>1</b> G(1) P(0) H(0)	<b>45</b> G(32) P(13) H(0)	<b>5</b> G(0) P(5) H(0)	<b>51</b>
	Total	<b>64</b>	<b>56</b>	<b>27</b>	<b>147</b>
			<b>83</b>		

PVF, peripheral visual field; VF, visual field; G, Goldmann perimeter (n); P, Peritest (n); H, Humphrey Field Analyzer (n)

*Absolute scotomas:* 'holes' in the VF that (1) did not extend to the peripheral borders of the VF or (2) were too small to contain one of the half-meridians at 0, 45, 135, 180, 225, 315 degrees.

*Relative VF defects:* defects on static perimetry that were not totally missed, but only seen at an increased intensity compared to the rest of the VF. *Absolute PVF defects:* all other defects.

**Diagnostic value:**

- ✓ Prior probability of an abnormal VF\*:  $83/147 = 56\%$  (95% CI 48-64%)
- ✓ Posterior probability of an abnormal VF\* (positive predictive value): probability of an abnormal VF\* given an abnormal BEFIE test:  $(45+5)/51 = 98\%$  (95% CI 94-100%)
- ✓ Prior probability of a normal VF\*:  $64/147 = 44\%$  (95% CI 36-52%)
- ✓ Posterior probability of a normal VF\* (negative predictive value): probability of a normal VF\* given a normal BEFIE test:  $63/96 = 66\%$  (95% CI 56-75%)
- ✓ Specificity: probability of a normal BEFIE test given the presence of a normal VF\*:  $63/64 = 98\%$  (95% CI 95-100%)
- ✓ Sensitivity: (1) probability of an abnormal BEFIE test given the presence of an abnormal VF\*:  $(45+5)/83 = 60\%$  (95% CI 50-71%). (2) probability of an abnormal BEFIE test given the presence of an absolute PVF defect\*:  $45/56 = 80\%$  (95% CI 70-91%)

\* according to the reference test

## DISCUSSION

The data of this large single-center reappraisal of the BEhavioral visual FIEld (BEFIE) screening test suggest that the test may be a valuable tool to detect PVF defects when SCP cannot be performed in very young or neurologically impaired children.

A limitation of this study was that the pediatric neuro-ophthalmologist who performed all BEFIE tests was aware of the child's clinical background and (suspected) pathology. In addition, the assessor who rated the reliability according to predefined criteria was not blinded because the test results were retrieved from the patient files. Although the results might have been influenced inherent to the retrospective study design, the test proved to aid in the determination of PVF defects in a clinical setting from the age of 4 months onwards in this considerable cohort collected during the previous 19 years. These PVF defects would otherwise have remained unnoticed because there was no alternative in children who were not able to perform SCP.

When possible, SCP remains the first choice of VF examination. However, even the simplest SCP methods, such as Goldmann perimetry, are often unsuccessful in healthy children younger than 6 years.<sup>1</sup> In accordance, the first successful SCP in our cohort was performed at the age of 5.2 years. Neurologically impaired children may remain incapable to perform SCP, while VF examination is often indicated in this group. This also explains the relatively small proportion of our cohort that was able to perform SCP during their follow-up.

Although the BEFIE test requires some investment of time, material, and personnel, it is easy to implement in a routine clinical setting and is, with an average duration of 5 minutes, much faster than SCP to perform. In the development of the test, we searched for a balance to test less-cooperative children and obtain an objective measure as PVF expressed in degrees. This test can be performed in a standard consulting room and needs 1 examiner and observer. It is recommended to train 1 or 2 BEFIE experts in each clinic because test characteristics may prove less robust in the hands of less experienced examiners owing to inter- and intra-examiner variability in the speed and extent of movement of the handheld peripheral stimulus.

Use of the BEFIE test both in nonacademic and academic settings could prevent diagnostic delays in diseases such as craniopharyngiomas and optic pathway gliomas, or following stroke. It is helpful in the early diagnosis of hemianopias and quadrantanopias, of which parents should be aware to have a correct interpretation of their child's behavior.

The overall learning or aging effect in the performance of the BEFIE test was demonstrated by the positive correlation between age and reliability and the possibility to perform a monocular test. The sudden decrease of its reliability in the pooled group of children 10 years and older was probably biased toward the most severely handicapped children because most other children were able to perform SCP at that age. Most children (75%) who underwent multiple BEFIE tests had consistent results. If there were discrepancies in longitudinal test findings, most could be explained. When comparing monocular BEFIE tests with SCPs performed later on, positive predictive value (98%) and specificity (98%) were high. Therefore, we concluded that the BEFIE test was able to detect rather than exclude VF defects.

The BEFIE test proved less sensitive than specific mainly owing to undetected absolute scotomas and relative VF defects for which it is expected the BEFIE test is not suitable. In some children, possible undetected or undocumented progressive underlying disease may have played a role. In addition, the lower sensitivity may be partly explained by a differential verification, such as comparison with different reference SCPs, given their different underlying principles and varying difficulty. In infants and toddlers, it was described that the VF extent may vary with stimulus flicker rate<sup>29,30</sup> and may be larger for moving targets than for static targets.<sup>17,31</sup> Finally, the phenomenon of blindsight, such as the perception of movement in a visually blind field,<sup>32</sup> may underlie the finding in 1 of our patients, who had a complete homonymous hemianopia at the Peritest reference test that was missed at the monocular BEFIE tests.

## CONCLUSIONS

2 This study shows that the BEFIE test can be reliably performed in most children who are too young or neurologically impaired to perform SCP. The test had particularly high positive predictive value and specificity in children who were able to perform both BEFIE and SCP examinations. These data suggest that the BEFIE test may be a valuable tool to detect PVF defects when SCP cannot be performed in children with (suspected) postchiasmal or prechiasmal pathology. This test can be taken from a very young age, is easy to implement in everyday clinical practice, and allows early detection and quantification of PVF abnormalities that would otherwise remain unnoticed.

## REFERENCES

1. Porro, G. L. & Wittebol-Post, D. Impairment of peripheral vision and its measurement. Chapter 5 in: Visual impairment in children due to damage to the brain (Edited by G.N. Dutton & M. Bax). *Clin. Dev. Med. No. 186*. Mac Keith Press (2010).
2. Good, W. V *et al.* Cortical visual impairment in children. *Surv. Ophthalmol.* **1738**, 351–364 (1994).
3. Mohn, G. & Van Hof-van Duin, J. Behavioural and electrophysiological measures of visual functions in children with neurological disorders. *Behav. Brain Res.* **10**, 177–87 (1983).
4. Kolling, G. H. & Wabbels, B. Symposium Proceedings Part II Kinetic perimetry in neuroophthalmological practice. **8**, (2000).
5. Greve, E. L., Dannheim, F. & Bakker, D. The Peritest, a new automatic and semi-automatic perimeter. *Int. Ophthalmol.* **5**, 201–14 (1982).
6. Donahue, S. P. & Porter, a. SITA visual field testing in children. *J. AAPOS* **5**, 114–7 (2001).
7. Blumenthal, E. Z., Haddad, A., Horani, A. & Anteby, I. The reliability of frequency-doubling perimetry in young children. *Ophthalmology* **111**, 435–9 (2004).
8. Quinn, L. M., Gardiner, S. K., Wheeler, D. T., Newkirk, M. & Johnson, C. a. Frequency doubling technology perimetry in normal children. *Am. J. Ophthalmol.* **142**, 983–9 (2006).
9. Murray, I. C. *et al.* Feasibility of saccadic vector optokinetic perimetry: a method of automated static perimetry for children using eye tracking. *Ophthalmology* **116**, 2017–26 (2009).
10. Murray, I. *et al.* Saccadic Vector Optokinetic Perimetry (SVOP): A novel technique for automated static perimetry in children using eye tracking. *Conf Proc IEEE Eng Med Biol Soc.* **2013**, 3186–9 (2013).
11. Allen, L. E., Slater, M. E., Proffitt, R. V, Quarton, E. & Pelah, A. A new perimeter using the preferential looking response to assess peripheral visual fields in young and developmentally delayed children. *J. AAPOS* **16**, 261–5 (2012).
12. Pel, J. J. M., van Beijsterveld, M. C. M., The-pass, G. & van der Steen, J. Validity and Repeatability of Saccadic Response Times Across the Visual Field in Eye Movement Perimetry. *Transl. Vis. Sci. Technol.* **2**, 3 (2013).
13. Harding, G. F. a, Spencer, E. L., Wild, J. M., Conway, M. & Bohn, R. L. Field-specific visual-evoked potentials: identifying field defects in vigabatrin-treated children. *Neurology* **58**, 1261–5 (2002).
14. Sheridan MD. The STYCAR graded-balls vision test. *Dev Med Child Neurol.* **15**, 423–32 (1973).
15. Hermans, A., Van Hof-van Duin, J. & Oude-sluids-Murphy, A. Visual outcome of low-birth-weight infants (1500-2500 g) at one year of corrected age. *Acta Paediatr.* **83**, 402–7 (1994).
16. Quinn, G. E. *et al.* Visual Fields Measured with Double-arc Perimetry in Eyes with Threshold Retinopathy of Prematurity from the Cryotherapy for Retinopathy of Prematurity Trial. *Ophthalmology* **103**, 1432–1437 (1996).
17. Dobson, V., Brown, a M., Harvey, E. M. & Narter, D. B. Visual field extent in children 3.5-30 months of age tested with a double-arc LED perimeter. *Vision Res.* **38**, 2743–60 (1998).
18. Mayer, D. L., Fulton, a B. & Cummings, M. F. Visual fields of infants assessed with a new perimetric technique. *Invest. Ophthalmol. Vis. Sci.* **29**, 452–9 (1988).
19. Porro, G., *et al.* A new behavioural visual field test for clinical use in pediatric neuro-ophthalmology. *Neuro-Ophthalmology* **19**, 205–214 (1998).
20. Beck RW, Bergstrom TJ, L. P. A clinical comparison of visual field testing with a new automated perimeter, the Humphrey Field Analyzer, and the Goldmann perimeter. *Ophthalmology.* **92**, 77–82 (1985).
21. Koenraads, Y. *et al.* Visual function and compensatory mechanisms for hemianopia after hemi-



- spherectomy in children. *Epilepsia* **55**, 909–917 (2014).
22. Lewis, T. L. & Maurer, D. The development of the temporal and nasal visual fields during infancy. *Vision Res.* **32**, 903–11 (1992).
23. Tschopp, C. *et al.* Does visual sensitivity improve between 5 and 8 years? A study of automated visual field examination. *Vision Res.* **39**, 1107–19 (1999).
24. Allen, D., Tyler, C. W. & Norcia, a M. Development of grating acuity and contrast sensitivity in the central and peripheral visual field of the human infant. *Vision Res.* **36**, 1945–53 (1996).
25. Clohessy, a B., Posner, M. I. & Rothbart, M. K. Development of the functional visual field. *Acta Psychol. (Amst)*. **106**, 51–68 (2001).
26. Seghier, M. L. *et al.* Visual recovery after perinatal stroke evidenced by functional and diffusion MRI: case report. *BMC Neurol.* **5**, 17 (2005).
27. Van der Aa, N. E. *et al.* Neonatal posterior cerebral artery stroke: clinical presentation, MRI findings, and outcome. *Dev. Med. Child Neurol.* **55**, 283–90 (2013).
28. Guzzetta, A. *et al.* Plasticity of the visual system after early brain damage. *Dev. Med. Child Neurol.* **52**, 891–900 (2010).
29. Delaney, S. M., Dobson, V. & Mohan, K. M. Measured visual field extent varies with peripheral stimulus flicker rate in very young children. *Optom. Vis. Sci.* **82**, 800–6 (2005).
30. Mohan, K., Dobson, V., Harvey, E., Delaney, S. & Leber, N. Does rate of stimulus presentation affect measured visual field extent in infants and toddlers? *Optom Vis Sci.* **76**, 234–40 (1999).
31. Delaney, S. M. *et al.* Stimulus Motion Increases Measured Visual Field Extent in Children 3.5 to 30 Months of Age. *Optom. Vis. Sci.* **77**, 82–89 (2000).
32. Boyle, N. J., Jones, D. H., Hamilton, R., Spowart, K. M. & Dutton, G. N. Blindsight in children: does it exist and can it be used to help the child? Observations on a case series. *Dev. Med. Child Neurol.* **47**, 699–702 (2005).

# 3

## **Prediction of visual field defects in newborn infants with perinatal arterial ischemic stroke using early MRI and DTI-based tractography of the optic radiation**

Yvonne Koenraads

Giorgio L. Porro

Kees P.J. Braun

Floris Groenendaal

Linda S. de Vries

Niek E. van der Aa

*European Journal of Paediatric Neurology* 2016 Mar;20(2):309-18

## ABSTRACT

### Purpose

Visual field (VF) defects are common sequelae of perinatal arterial ischemic stroke (PAIS). The aim of this study was to investigate the predictive value of magnetic resonance imaging (MRI) and diffusion tensor imaging (DTI) for VF defects following PAIS.

### Methods

Nineteen infants with unilateral PAIS, who underwent conventional MRI (T1/T2) and DTI at three months of age and a VF examination later in life (median age 3.2 yrs) were included. Conventional T1-weighted MRI was used to assess asymmetry of the optic radiation (OR). DTI-based tractography of the bilateral OR was performed, and the average fractional anisotropy (FA), axial ( $\lambda_1$ ), radial ( $\lambda_{23}$ ) and mean diffusivity (MD) were extracted. Asymmetry of the OR on MRI and DTI was used as a predictor of VF defects using receiver operating characteristic (ROC) analysis.

### Results

Of the 19 infants, nine had a normal VF, eight had a VF defect (six hemianopia and two quadrantanopia), and two had an inconclusive VF test. The presence or absence of a VF defect could be correctly predicted using conventional MRI assessment in the majority of the infants, with an area under the curve (AUC) of 0.90 (95% CI 0.66-0.99). Prediction based on DTI parameter asymmetry indices showed an AUC of 0.96 (95% CI 0.74-1.00), 0.78 (95% CI 0.52-0.94), 0.93 (95% CI 0.70-1.00) and 0.90 (95% CI 0.66-0.99) for FA,  $\lambda_1$ ,  $\lambda_{23}$  and MD, respectively.

### Conclusions

VF defects following PAIS can be reliably predicted by assessment of asymmetry of the OR at three months on conventional MRI and DTI-based tractography with comparable predictive values. Conventional T1-weighted MRI can be used in clinical practice.



## **INTRODUCTION**

Perinatal arterial ischemic stroke (PAIS) is not uncommon, with an incidence of one out of 1600-5000 live births.<sup>1</sup> Patients may present in the neonatal period with seizures or encephalopathy. Alternatively, they may be first diagnosed at a few months of age, when hemiparesis becomes overt and are then referred to as 'presumed' perinatal stroke.<sup>2</sup> Later in life, patients may suffer from motor deficits, epilepsy and problems with language, cognition and vision, depending on the extent and location of brain injury.<sup>2</sup> Current literature is mainly focused on motor problems and there are few studies on visual functioning following PAIS. The studies that describe visual outcome reported visual impairments in 15-28% of all cases<sup>3,4</sup> with a high prevalence of visual field (VF) defects (13-53%).<sup>3,5-8</sup>

A visual impairment, including VF defects, in the developing child can have serious consequences on a child's motor, emotional, social and psychological development.<sup>9</sup> Furthermore it may affect education and future social and economic prospects. If VF defects are detected early, a rehabilitation program, including an adjusted approach at daycare or school, can be initiated in order to fulfill their needs and stimulate the child's development.<sup>10,11</sup>

However, identification of children at risk for development of a VF defect may be challenging, especially in young, noncooperative infants. Examination of their VF requires specialized techniques, which are not yet widely used in everyday clinical practice, e.g. simple behavioral kinetic perimetry such as the BEFIE test (acronym for 'BEhavioral visual FIEld screening test').<sup>12</sup> MRI has been shown to be an early predictor of visual outcome in infants at risk for cerebral visual impairments.<sup>9,13</sup> Following PAIS, Mercuri et al. found that only half of the infants with involvement of the optic radiation (OR) on conventional MRI developed a VF defect.<sup>3</sup> In a previous study we were able to demonstrate a clear correlation between asymmetry of the optic radiation at three months and development of VF defects among ten infants with a posterior cerebral artery (PCA) stroke.<sup>6</sup> Besides conventional MRI, diffusion tensor imaging (DTI) is increasingly being used in neonatal imaging and provides insight in microstructural development and injury.<sup>14</sup> In preterm born infants, a relation was found between visual function and

### Chapter 3

early fractional anisotropy (FA) values of the OR in preterm infants.<sup>13</sup> In addition, in a cohort of term born infants who suffered from PAIS, we previously reported that FA values of the OR at three months of age were lower in infants who did develop VF defects compared to those with a normal VF on follow up.<sup>15</sup>

The predictive value of early MRI and DTI for the presence of VF defects and a comparison between qualitative and quantitative neuroimaging techniques has not been investigated before. Therefore, the aim of this study was to investigate in more detail the predictive value of conventional MRI assessment and DTI-based tractography of the OR at three months of age in the prediction of VF defects after PAIS.

## MATERIALS AND METHODS

### Patient selection

Infants diagnosed with MRI-confirmed unilateral PAIS, and admitted to the neonatal intensive care unit of the Wilhelmina Children's Hospital between September 2006 and December 2013, were eligible for this study. Inclusion criteria required an MRI scan including DTI obtained at the age of three months and a VF examination later in infancy or childhood. No permission was required from the hospital's medical ethics committee for retrospective, anonymous data analysis.

### Data collection

#### *Magnetic resonance imaging*

At the age of three months, MRI scans were acquired on a 1.5-Tesla Philips Gyroscan (Philips Medical Systems, Best, the Netherlands). Infant movement was limited by the use of a vacuum pillow (Med-Tec, Orange City, IA) and sedation using a combination of chlorpromazine (0.5 mg/kg), pethidine (2 mg/kg), and promethazine (0.5 mg/kg) intramuscularly. Minimuffs (Natus Medical Inc, San Carlos, CA) as well as Earmuffs 4 kids (Culver City, CA) were used for hearing protection. Heart rate and transcutaneous oxygen saturation were monitored by pulse oximetry (Nonin, Minneapolis, MN) as well as respiration rate (Philips, ACS-NT, Best, the Netherlands).

Conventional MRI data, including a T2-weighted turbo spin echo (TR/TE 5860/150 ms) and a T1 inversion recovery (TR/TI/TE 4000/600/30 ms), were acquired using 50 2 mm slices with 256 x 256 matrix and a field of view of 180 x 180 mm<sup>2</sup>. DTI data were acquired using a single-shot echoplanar imaging sequence (50 slices with thickness 2 mm without gap, echoplanar imaging factor 41, TR/TE 6817/87 ms, field of view 190 x 190 mm<sup>2</sup>, acquisition matrix 96 x 96 and reconstruction matrix 128 x 128). Images were acquired in the axial plane with a single b=0 s/mm<sup>2</sup> image and diffusion gradients applied in 32 noncollinear directions with a b-value of 800 s/mm<sup>2</sup>. In five infants a different DTI sequence was acquired on a 3.0-Tesla Philips Achieva scan-

## Chapter 3

ner, using 45 non-collinear diffusion weighted images (50 slices, 2 mm thickness, echoplanar imaging factor 61, TR/TE 6500/80 ms, field of view 160 x 160 mm, acquisition matrix 80 x 80).

### *Postprocessing*

DTI data were analyzed with ExploreDTI (<http://www.exploredti.com>). To correct for eddy current induced geometric distortions and subject motion diffusion weighted images were re-aligned to the b0-image. In this procedure, the diffusion tensor was fitted for each voxel after adjusting the diffusion gradients with the proper b-matrix rotation.<sup>16</sup> To correct for any asymmetry in the axial plane due to the scan angulation, all DTI scans were rigidly transformed to a neonatal DTI template during this processing step.<sup>17</sup> After these procedures, the transformed DWIs were exported, along with the new b-matrix and a brain mask.

FSL v5.0 was used for all further analyses. Fractional anisotropy (FA) maps were generated by fitting the diffusion tensor model to the data. Tractography of the bilateral OR was performed as previously described by Counsell et al.<sup>18</sup> This was done by a single observer (NvdA), who was unaware of the outcome of the VF tests. Standardized seed masks (9 voxels) were positioned in the white matter lateral to the lateral geniculate nuclei. These were identified in the axial plane at the level of the transition from the posterior limb of the internal capsule to the cerebral peduncle. Waypoints were defined in the distal ORs. Exclusion masks in the sagittal and coronal plan were used to restrict the pathway to the region ipsilateral to the seed mask and posterior to the third ventricle.<sup>19</sup> Connectivity distributions were generated from every voxel in the seed mask passing through the waypoint and were thresholded to include only those pathways with a probability of  $\geq 10\%$ . Previous studies have shown that this type of analysis results in a high inter- and intra-observer agreement.<sup>18,20</sup>

The mean FA, mean diffusivity (MD), axial diffusivity ( $\lambda_1$ ) and radial diffusivity ( $\lambda_{23}$ ) of the connectivity distributions were determined. Subsequently, for each infant, an asymmetry index (%) was calculated with the following formula:  $100 * (\text{DTI parameter ischemic hemisphere} - \text{DTI parameter healthy hemisphere}) / \text{DTI parameter healthy hemisphere}$ .

### *Assessment of conventional MRI*

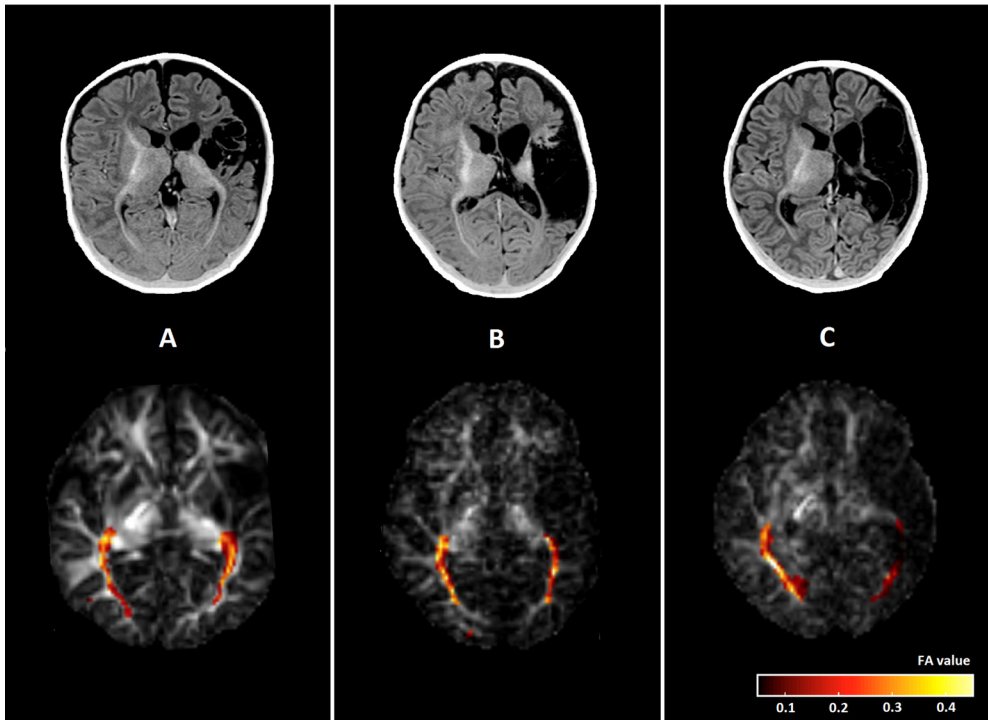
The inversion recovery sequence, obtained at three months of age was used to score the symmetry - in terms of presence, integrity and myelination - of the bilateral OR. This was done independently by two experienced neonatologists (LdV and FG) who were blinded for both the results of the VF examination and the outcome of the DTI parameters. Discrepancies between both assessments were resolved by consensus discussion. The ORs were scored as 'symmetrical', 'mildly asymmetrical' or 'severely asymmetrical', examples of which are shown in Figure 1.

### *Assessment of visual field defects*

VF measurements were performed with the BEFIE test<sup>12</sup> ('BEhavioral visual FIEld screening test') from preverbal age onwards and with conventional (semi-)automatic static perimetry on the Peritest in older infants ( $\geq$  six years of age). The BEFIE test is a simple behavioral kinetic perimetry method that is based on a graded semicircular arc with a stimulus at the end that is introduced from behind in the VF of the infant, from the periphery to the center. The subject's visual (or verbal) response to the stimulus is reported by an observer. Results of the VF examination were categorized as 'normal', 'homonymous quadrantanopia' or 'homonymous hemianopia'. Infants with inconclusive results in longitudinal follow-up of VF examinations, i.e. VF results that changed over time, were described but were excluded from the prediction analysis.

In addition, we collected information on visual fixation, visual acuity, ocular alignment, eye movement and optic discs. Visual fixation was rated as 'continuously present', 'intermittent' or 'absent'. Visual acuity measurements were performed with the Cardiff Acuity Test, the Kays Picture Chart or the Snellen Chart, corresponding to the age and cooperation of the infant. Best corrected visual acuity at the highest applicable test was documented. Values were transformed to LogMAR (Logarithm of the Minimum Angle of Resolution), in which -0.2 to 0.1 LogMAR is classified as a normal vision, 0.2-0.5 LogMAR as mild visual impairment (VI), 0.6-0.9 LogMAR as moderate VI, 1.0-1.3 LogMAR as severe VI, 1.4-1.7 LogMAR as profound VI, and 1.8-2.0 LogMAR as (near-) blindness, according to the International Classification of Diseases.<sup>21</sup>

**Figure 1. Example of symmetrical, mildly asymmetrical or severely asymmetrical appearance of the optic radiations**



The upper row shows illustrative T1 inversion recovery MRI images of the three optic radiation (OR) scores: **A.** Symmetrical OR: both ORs are present with a similar volume and myelination. **B.** Mildly asymmetrical OR: though both ORs are present, the affected OR has a smaller volume and the distal part of the affected OR is less well myelinated. **C.** Severely asymmetrical OR: hardly any OR present in the affected hemisphere. The lower row illustrates the corresponding results of the DTI-based tractography of these infants.

Ocular alignment and eye movement were assessed by an experienced orthoptist by means of light reflexes, the covertest and pursuit movements. Optic discs were assessed by means of dilated fundoscopy by an experienced pediatric ophthalmologist.

### **Statistical analysis**

Statistical analysis was performed using SPSS 21.0 (IBM SPSS statistics, Armonk, New York, USA). Differences between groups were assessed using the Fischer exact test or the Mann-Whitney U test where appropriate. Results were corrected for multiple testing using a Bonferroni-Holm correction. A p-value below 0.05 was considered statistically significant.

Finally, receiver operator characteristic (ROC) curves were created with MedCalc Version 14.10.2 (MedCalc Software, Ostend, Belgium) to determine the area's under the curve (AUC) and calculate the optimal cutoff values for determining the sensitivity, specificity, positive (PPV) and negative predictive value (NPV) of MRI and DTI in the prediction of VF defects. Differences between the AUCs of the individual predictors were tested with a pairwise comparison according to the DeLong et al. methodology.<sup>22</sup>

## RESULTS

### Patients

Nineteen infants (14 male) with unilateral PAIS who were born at term were included in this study. The clinical characteristics and outcome of some of these infants have previously been reported.<sup>6,15</sup> Demographic and clinical characteristics of the infants in the current study are shown in Table 1.

**Table 1. Patient characteristics**

	<b>Complete MCA</b> n=10	<b>Cortical MCA branch</b> n=3	<b>PCA</b> n=6	<b>p-value</b>
	n (%) or median [range]	n (%) or median [range]	n (%) or median [range]	
<b>Gender, male</b>	8 (80)	1 (33)	5 (83)	NS
<b>Gestational age, wk</b>	39 <sup>+5</sup> [37 <sup>+1</sup> – 41 <sup>+0</sup> ]	39 <sup>+0</sup> [38 <sup>+4</sup> – 40 <sup>+3</sup> ]	39 <sup>+6.5</sup> [39 <sup>+0</sup> – 41 <sup>+3</sup> ]	NS
<b>Birth weight, g</b>	3357.5 [2450 – 3572]	3170 [3000 – 4040]	3143.5 [2145 – 3880]	NS
<b>VF defect</b>				
Hemianopia	4 (40)	0 (0)	2 (33)	NS
Quadrantanopia	2 (20)	0 (0)	0 (0)	
Inconclusive	1 (10)	0 (0)	1 (17)	
<b>USCP</b>	10 (100)	1 (33)	1 (17)	0.005
<b>Epilepsy</b>	1 (10)	0 (0)	1 (17)	NS

MCA, middle cerebral artery; PCA, posterior cerebral artery; VF, visual field; NS, not significant; USCP, unilateral spastic cerebral palsy

### Visual field

The patients underwent one (n=6) or multiple (n=13) VF measurements (median 4, range 2-7). BEFIE tests were performed in all infants between the age of four months and 6.3 years (median last examination 3.2, range 0.5-6.3 years). Three infants were also tested using conventional (semi-)automatic static perimetry on the Peritest (6.3, 7.4 and 8.0 years of age).



During the first VF measurement nine infants had a normal VF (median age 0.9, range 0.4-5.3 years) and ten a VF defect (median age 0.6, range 0.5-2.1 years), including six hemianopias and four quadrantanopias. After a median follow-up of 2.9 (range 0.6-7.3) years, in two of the four infants with a quadrantanopia (that was assessed at multiple VF examinations before the age of three years) the VF defect could no longer be confirmed; both infants showed a normal VF that was first observed at the age of three years. These two children (one right PCA and one right MCA PAIS) were excluded from the prediction analysis because of their inconclusive VF results. All other infants who underwent multiple VF measurements had consistent VF findings over time.

### **Conventional MRI and visual field**

The MRI scans were obtained at a median age of 97 days (range 80-127). In six infants the OR was scored symmetrical, in five mildly asymmetrical and in eight severely asymmetrical. All six infants whose MRI scan was scored as symmetrical had a normal VF (see Table 2). Among the five infants with mildly asymmetrical ORs, two had a VF defect, two had a normal VF and one had inconclusive results. Six of the eight infants assessed with a severely asymmetrical OR had a VF defect, one was normal and one had an inconclusive VF assessment. ROC analysis of the 17 infants with a conclusive VF examination, revealed an AUC of 0.90 (95% CI 0.66-0.99).

There was a high inter-observer agreement. In 17 out of 19 infants, asymmetry of the ORs was scored identically by both observers. The MRIs of the remaining two infants were each scored as severely asymmetrical by one of the observers (LdV and FG) while the other observer scored it as mildly asymmetrical (FG and LdV). After reviewing the MRIs again, consensus was reached and both MRIs were scored as mildly asymmetrical.

### **DTI and visual field**

The ORs could be tracked in all patients. In Figure 1, examples of tractography results in infants with a symmetrical, mildly asymmetrical and severely asymmetrical OR on conventional MRI are shown. The asymmetry indices of the DTI parameters of the OR are presented in

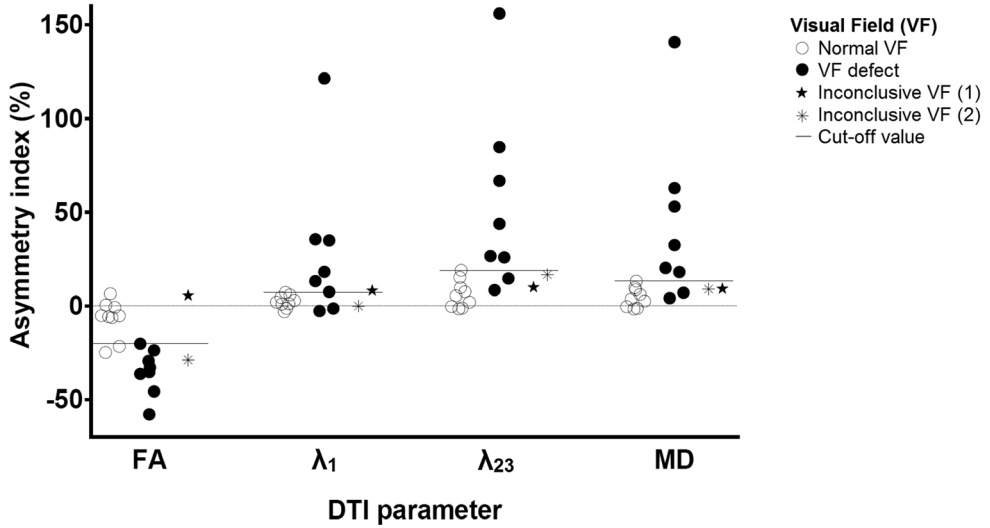
**Table 2. Optic radiation asymmetry on conventional MRI versus DTI parameter asymmetry**

		OR DTI parameter asymmetry index							
		FA		$\lambda_1$		$\lambda_{23}$		MD	
		> -20.3%	$\leq$ -20.3%	$\leq$ 7.2%	> 7.2%	$\leq$ 19.0%	> 19.0%	$\leq$ 13.2%	> 13.2%
OR assessment on MRI	Symmetrical	○ ○ ○ ○	□	○ ○ ○ ○	□ □	○ ○ ○ ○	□ □	○ ○ ○ ○	□ □
	Mildly asymmetrical	○	●	○ ●	□ ◆	○ ●	□ ◆	○ ●	□ ◆
	Severely asymmetrical		○ ● ● ●	○ ● ◆	● ● ● ●	○ ● ◆	● ● ● ●	○ ● ◆	● ● ● ●

The relation between the visually scored asymmetry of the OR and the asymmetry of the DTI parameters of the OR are given for 17 infants with a stroke in the territory of the middle cerebral artery (○/●) or posterior cerebral artery (□/■). Infants with a normal VF are depicted as open symbols, whilst those with a VF defect are depicted as a filled symbol. Results of the two infants with an inconclusive VF are also given (◆). Cut off values for the asymmetry indices of the DTI parameters were determined using ROC analysis.

DTI, diffusion tensor imaging; MRI, magnetic resonance imaging; VF, visual field; OR, optic radiation; FA, fractional anisotropy;  $\lambda_1$ , axial diffusivity;  $\lambda_{23}$ , radial diffusivity; MD, mean diffusivity;

Figure 2. Asymmetry of DTI parameters of the optic radiation



The asymmetry indices of the DTI parameters of the optic radiation of all individual infants are plotted. Infants with a normal VF are depicted as open symbols (○), infants with a VF defect as a filled symbol (●) and the two infants with an inconclusive VF are each depicted as a star (\*).

DTI, diffusion tensor imaging; VF, visual field; FA, fractional anisotropy;  $\lambda_1$ , axial diffusivity;  $\lambda_{23}$ , radial diffusivity; MD, mean diffusivity;

Figure 2. Infants with a VF defect showed a larger asymmetry, with median differences of 29% (FA,  $p=0.002$ ), 14% ( $\lambda_1$ ,  $p=0.059$ ), 30% ( $\lambda_{23}$ ,  $p=0.005$ ) and 23% (MD,  $p=0.007$ ), for the different parameters (see Table 3). ROC curve analysis for predicting VF defects (of the 17 infants with conclusive VF measurements) revealed high AUCs, especially for the FA (AUC=0.96) and  $\lambda_{23}$  (AUC=0.93) asymmetry indices. However, these AUCs were not significantly different from the

**Table 3. Diagnostic values of MRI and DTI parameter asymmetry indices to predict**

<i>n</i> =17	<b>Asymmetry on MRI</b>		<b>FA asymmetry index (%)</b>		<b><math>\lambda_1</math> asymmetry index (%)</b>	
	p-value or 95%CI		p-value or 95%CI		p-value or 95%CI	
<b>Median (range)</b>						
*Normal VF ( <i>n</i> =9)	na		<b>-5.4</b> (-25.0, 6.4)		<b>2.0</b> (-3.2, 7.2)	
*VF defect ( <i>n</i> =8)	na		<b>-34.1</b> (-58.0, -20.3)	0.002	<b>15.7</b> (-2.7, 121.4)	0.059
<b>ROC curve</b>						
*AUC	<b>0.903</b>	0.000 (0.661-0.991)	<b>0.958</b>	0.000 (0.738-1.000)	<b>0.778</b>	0.061 (0.515-0.939)
*Cut-off value			<b>≤ -20.3</b>		<b>&gt;7.2</b>	
*Sensitivity	<b>100%</b>	(63.1-100)	<b>100%</b>	(63.1-100)	<b>75.0%</b>	(34.9-96.8)
*Specificity	<b>66.7%</b>	(29.9-92.5)	<b>77.8%</b>	(40.0-97.2)	<b>100%</b>	(66.4-100)
*PPV	<b>72.7%</b>	(39.0-94)	<b>80.0%</b>	(44.4-97.5)	<b>100%</b>	(54.1-100)
*NPV	<b>100%</b>	(54.1-100)	<b>100%</b>	(59.0-100)	<b>81.8%</b>	(48.2-97.7)

MRI, magnetic resonance imaging; DTI, diffusion tensor imaging; FA, fractional anisotropy;  $\lambda_1$ , diffusivity; VF, visual field; ROC, receiver operator characteristic; AUC, area under the curve; PPV, value;

AUC of the prediction based on conventional MRI assessment ( $p=0.250$  and  $p=0.686$ ).

Table 2 provides a complete overview of both MRI and DTI assessments in infants with and without a VF defect. The correlation between the asymmetry of DTI parameters and the severity of the VF defects can be found in the eFigure.

**visual field defects**

<b><math>\lambda_{23}</math> asymmetry index (%)</b>	<b>p-value or 95%CI</b>	<b>MD asymmetry index (%)</b>	<b>p-value or 95%CI</b>
<b>5.4</b> (-1.6, 19.0)	0.005	<b>3.5</b> (-1.7, 13.2)	0.007
<b>35.1</b> (8.4, 155.9)		<b>26.3</b> (4.0, 140.7)	
<b>0.931</b> > <b>19.0</b>	0.000 (0.698-0.997)	<b>0.903</b> > <b>13.2</b>	0.000 (0.661-0.991)
<b>75.0%</b>	(34.9-96.8)	<b>75.0%</b>	(34.9-96.8)
<b>100%</b>	(66.4-100)	<b>100%</b>	(66.4-100)
<b>100%</b>	(54.1-100)	<b>100%</b>	(54.1-100)
<b>81.8%</b>	(48.2-97.7)	<b>81.8%</b>	(48.2-97.7)

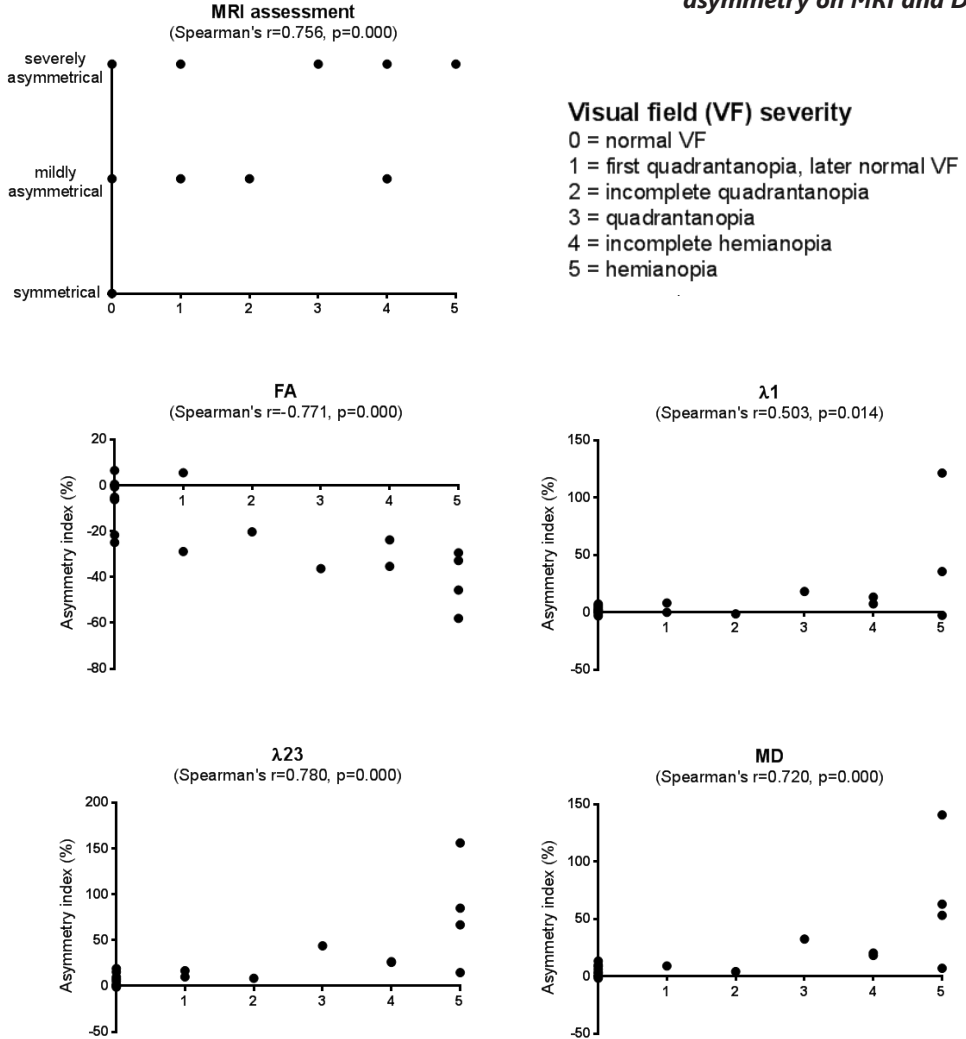
axial diffusivity;  $\lambda_{23}$ , radial diffusivity; MD, mean positive predictive value; NPV, negative predictive

**Secondary outcomes**

The median last ophthalmological visit was at 3.2 (range 0.5-7.7) years of age, with two infants still younger than one year of age. All 19 infants had a good, continuously present visual fixation. Visual acuity was tested in 13 infants and was performed with the Cardiff Acuity Test (n=1), the Kays Picture Chart (n=7) or the Snellen Chart (n=5). Visual acuity was normal (median 0.0, range -0.1 to 0.1 LogMAR) in all but one infant, who had a visual acuity of 0.2 LogMAR (without refractive correction) and was classified as having mild visual impairment. There was no significant difference in visual acuity between infants with (median 0.0, range -0.1 to 0.0 LogMAR) and without (median 0.0, range 0.0-0.1 LogMAR) a VF defect (p=0.08), neither was there a correlation with one of the DTI parameters. Regarding ocular alignment, which was tested in all 19 infants, three infants had an exotropia (two with and

one without a VF defect) and one had an esotropia (with VF defect). All four deviations were present in the eye contralateral to the PAIS. Eye movements were abnormal in one infant who had a V-pattern due to an overactive inferior oblique muscle. Assessment of the optic disc was abnormal (temporal paleness) in one infant who had hemianopia after a PAIS of the left MCA.

**Figure. Correlation between the severity of the visual field defects and optic radiation asymmetry on MRI and DTI**



## DISCUSSION

This study focused on the diagnostic value of neuroimaging of the OR at three months of age in the prediction of VF defects detected in infancy and childhood. In our cohort of infants with unilateral PAIS, we found that both an asymmetry of the OR on conventional MRI and DTI-based tractography can be used to predict VF defects. Although enabling a more exact quantitative assessment of the integrity of the OR, in our relatively small cohort DTI did not significantly better predict VF defects than conventional MRI assessment. Therefore we may conclude that, in everyday clinical practice, assessment of asymmetry of the OR on conventional MRI at three months can be used for the prediction of VF defects in children with unilateral brain damage.

### DTI tractography-based prediction

DTI allows assessment of the white matter tracts noninvasively by measuring water diffusion in brain tissue.<sup>23</sup> In intact single fiber tracts, the largest diffusivity is measured parallel to the fiber direction and smallest perpendicular to it, presumably due to cohesiveness and compactness of the fiber tracts and myelination.<sup>23</sup> This is a rather simple model however and the interpretation of changes in diffusion parameters should be performed with care. Many factors influence the diffusion tensor including factors as subject age, crossing fibers, image noise, artifacts and partial volume effects.<sup>24</sup> Despite these considerations, DTI is a sensitive marker for neuropathology.

In infants with PAIS, proximal axonal or cell body injury occurs, initiating different pathophysiological cellular responses that result in anterograde degeneration of axons and myelin sheaths, also known as Wallerian degeneration.<sup>25,26</sup> Disruption of the ordered axonal arrangements and the integrity of the myelin sheath causes changes in the diffusivity influencing the DTI parameters of the involved fiber tract. The correspondence between the histological responses and DTI changes after brain damage was studied in rats, in which particularly a decrease in FA and increase in  $\lambda_{23}$  were found to correlate with persistent axonal degeneration.<sup>27</sup>

DTI tractography studies in adults extensively studied the exact location of the OR in order to reduce the risk of a postoperative visual field defect following temporal lobe epilepsy surgery.<sup>28</sup> In patients with iatrogenic VF defects following temporal lobe resection, reduced FA values, increased MD values and visually assessed disruptions of the OR were found.<sup>29,30</sup> Also in patients with ophthalmological diseases such as glaucoma and retinitis pigmentosa that impair the VF, decreased FA values and increased diffusivity values of the OR were found compared to healthy controls.<sup>31,32</sup> A study in adults with stroke performed serial scanning at five time points post stroke and documented decreasing FA values and increasing MD values of the OR over time.<sup>25</sup>

DTI studies of the OR in infants have mainly focused on premature infants and reported that FA values at term equivalent age were significantly correlated with visual functioning scores based on functions as fixation, motility, tracking and visual acuity.<sup>13,33,34</sup> To the best of our knowledge, the prediction of VF defects in infants has not been previously studied. In the current study in infants with unilateral PAIS, we found that FA was also the best predictor for VF defects with a high AUC in ROC curve analysis.

### **Conventional MRI-based prediction**

The OR is part of the posterior visual pathway that transfers visual input that arrives via the retina, optic nerve, chiasm and optic tract from the lateral geniculate nucleus to the visual cortex.<sup>35</sup> Myelination of the OR starts around 33-36 gestational weeks and progresses rapidly in the first 2 years of life.<sup>36</sup> Using T1-weighted imaging, myelination of the posterior limb of the internal capsule, the middle cerebral peduncle and cerebellar white matter can be visualized at term age.<sup>37</sup> Myelination of the OR can be visualized from three months onwards. As a consequence, timing of the MRI to assess myelination of the OR is crucial, as lack of myelination on an MRI before the age of three months may be a consequence of either normal, but not yet visible myelination or delayed or absent myelination due to pathologic conditions. Therefore, we chose to assess the MRI at three months instead of the neonatal MRI.

It is of interest that prediction based on conventional MRI assessment in our study was com-



parable to DTI based prediction. All eight infants with a VF defect showed an asymmetry of the OR. However, two infants with mild and one with severe OR asymmetry on conventional MRI had a normal VF assessment with the BEFIE test (age 3.4, 2.2 and 0.5 years). This is in line with previous studies that described that not all infants with OR injury on neuroimaging develop VF defects.<sup>3,6-9</sup>

The predictive value of a symmetrical OR for a normal VF in our study was very high, since all infants with a symmetrical T1 appearance of the OR had a normal VF. Previous studies reported VF defects in some infants with PAIS without involvement of the OR.<sup>6-8</sup> This discrepancy might relate to possible presence of injury in other areas of the visual network that are required for visual functioning.<sup>38</sup>

Tractography of the OR may assist in predicting outcome in those infants in whom conventional MRI is inconclusive. In five infants, conventional MRI was scored as mildly asymmetrical and four of them had a conclusive VF measurement. In two of these infants, all DTI parameters were normal, suggesting a normal VF which was indeed confirmed at follow-up. The two infants who developed a VF defect both showed a low FA in the affected OR, while the other DTI parameters were normal in one and abnormal in the other. The number of infants with an inconclusive conventional MRI was small however, and larger cohorts are needed to draw firmer conclusions.

### **Visual field recovery**

The VF in healthy infants is not stable from birth onwards. The peripheral VF of infants increases with age.<sup>39</sup> The exact peripheral extents are unknown, since results of different VF examination methods performed at the same time may provide varying results because of their different underlying principles and varying difficulty.<sup>3</sup> For example, the VF extent of infants and toddlers may be larger for moving than for static targets.<sup>39</sup> In addition, longitudinal differences in VF examination results during follow-up might be present as a result of varying attention which may be age-dependent or due to injury to areas of complex higher visual functions.<sup>3</sup> Such mechanisms might be responsible for inconsistent longitudinal VF examination results during follow-up after PAIS that were previously reported by others<sup>3</sup> and observed in two infants in our study.

Brain plasticity, which has been suggested to explain the visual recovery described in case reports by Seghier et al.<sup>40</sup> and Groenendaal et al.,<sup>41</sup> represents another mechanism that might play a role in changing VF results.<sup>6,42</sup> This phenomenon seems especially present in the developing infants brain and early timing of PAIS is thought to contribute to the degree of this plasticity.<sup>43</sup> However, recovery of VF defects has also been reported in adults and different mechanisms of brain plasticity and cortical reorganization have been proposed.<sup>44</sup> Proposed mechanisms include new interhemispheric connections, reorganization in nearby unaffected cortex and changes in functional interaction between higher-level visual cortical areas and the primary visual areas. The retrospective design of our study does not allow us to study the underlying mechanisms, but future studies combining fMRI and novel diffusion weighted imaging techniques<sup>45</sup> may elucidate the underlying processes.

### **Limitations**

In the current study we only examined the OR, though the visual system consists of a complex network in which not only the OR but also other areas may be injured following stroke, complicating OR integrity based prediction of VF defects.<sup>38</sup>

We tried to use multiple VF examinations for each infant to improve the reliability of the VF

outcome. However, some infants were only tested once or twice and it is uncertain whether these infants with a relatively short follow up (under the age of three) would have shown improvement of their VF on longer follow-up.

The use of two different DTI sequences and the wide range in age at scan (ranging from 80 to 127 days) prevented us from using the individual FA values from the ipsilateral OR - rather than the asymmetry index - to predict VF defects. Asymmetry indices are frequently used however, and have been related to clinical outcome before.<sup>20</sup>

Another explanation for the reduced FA observed in the affected OR is a partial volume effect. It is well known that partial volume effects affect both fiber tractography and the derived DTI parameters.<sup>46</sup> In ORs with a smaller volume due to degeneration of axons, the contribution of partial volume contaminated voxels is likely to be higher. It has been suggested to incorporate partial volume effects related factors in DTI analyses, but the sample size of the current study was too small to do so.

## CONCLUSION

This study shows that assessment of asymmetry of the OR on both conventional MRI and DTI-based tractography at three months of age can be used to predict VF defects after unilateral PAIS with comparable predictive values. Based on our findings, we propose that an accurate follow-up with multiple VF examinations is indicated in children with OR asymmetry on a MRI performed at three months, in order to ensure early diagnosis of VF defects and subsequent start of rehabilitation. Our current data do suggest that there is no need for visual follow-up in the presence of a symmetrical OR on conventional T1-weighted imaging, however, this finding needs to be confirmed by others before applied to clinical practice.

## REFERENCES

1. Van der Aa, N. E., Benders, M. J. N. L., Groenendaal, F. & de Vries, L. S. Neonatal stroke: a review of the current evidence on epidemiology, pathogenesis, diagnostics and therapeutic options. *Acta Paediatr.* **103**, 356–64 (2014).
2. Kirton, A., Deveber, G., Pontigon, A.-M., Macgregor, D. & Shroff, M. Presumed perinatal ischemic stroke: vascular classification predicts outcomes. *Ann. Neurol.* **63**, 436–43 (2008).
3. Mercuri, E. *et al.* Neonatal cerebral infarction and visual function at school age. *Arch Dis Child* **88**, F487–F491 (2003).
4. Sreenan, C., Bhargava, R. & Robertson, C. M. Cerebral infarction in the term newborn: clinical presentation and long-term outcome. *J. Pediatr.* **137**, 351–5 (2000).
5. Trauner, D., Chase, C., Walker, P. & Wulfeck, B. Neurologic Profiles of Infants and Children after Perinatal Stroke. *Pediatr Neurol* 1993;9:383-6. **9**, 383–386 (1993).
6. Van der Aa, N. E. *et al.* Neonatal posterior cerebral artery stroke: clinical presentation, MRI findings, and outcome. *Dev. Med. Child Neurol.* **55**, 283–90 (2013).
7. Guzzetta, A. *et al.* Visual function in children with hemiplegia in the first years of life. *Dev. Med. Child Neurol.* **43**, 321–329 (2001).
8. Mercuri, E. *et al.* Visual outcome in children with congenital hemiplegia: correlation with MRI findings. *Neuropediatrics* **27**, 184–8 (1996).
9. Van Hof-van Duin, J., Bertucclii, B., Fazzi, B. & Maris, S. Visual outcome at 5 years ' of newborn infants at risk of cerebral visual impairment. *Dev. Med. Child Neurol.* **40**, 302–309 (1998).
10. Dale, N. & Salt, A. Early support developmental journal for children with visual impairment: the case for a new developmental framework for early intervention. *Child. Care. Health Dev.* **33**, 684–90 (2007).
11. Good, W. V *et al.* Cortical visual impairment in children. *Surv. Ophthalmol.* **1738**, 351–364 (1994).
12. Koenraads, Y., Braun, K. P. J., van der Linden, D. C. P., Imhof, S. M. & Porro, G. L. Perimetry in Young and Neurologically Impaired Children: The Behavioral Visual Field (BEFIE) Screening Test Revisited. *JAMA Ophthalmol.* **133**, 319–25 (2015).
13. Bassi, L. *et al.* Probabilistic diffusion tractography of the optic radiations and visual function in preterm infants at term equivalent age. *Brain* **131**, 573–82 (2008).
14. Ramenghi, L. a *et al.* Neonatal neuroimaging: going beyond the pictures. *Early Hum. Dev.* **85**, S75–7 (2009).
15. Van der Aa, N. E. *et al.* Quantification of white matter injury following neonatal stroke with serial DTI. *Pediatr. Res.* **73**, 756–62 (2013).
16. Leemans, A. & Jones, D. K. The B-matrix must be rotated when correcting for subject motion in DTI data. *Magn. Reson. Med.* **61**, 1336–49 (2009).
17. Oishi, K. *et al.* Multi-contrast human neonatal brain atlas: application to normal neonate development analysis. *Neuroimage* **56**, 8–20 (2011).
18. Counsell, S. J. *et al.* Thalamo-cortical connectivity in children born preterm mapped using probabilistic magnetic resonance tractography. *Neuroimage* **34**, 896–904 (2007).
19. Ciccarelli, O. *et al.* From diffusion tractography to quantitative white matter tract measures: a reproducibility study. *Neuroimage* **18**, 348–359 (2003).
20. Van der Aa, N. E. *et al.* Does diffusion tensor imaging-based tractography at 3 months of age contribute to the prediction of motor outcome after perinatal arterial ischemic stroke? *Stroke.* **42**, 3410–4 (2011).
21. World Health Organization. *International Statistical Classification of Diseases and Related Health Problems 10th Revision. ICD-10 Version.* (2010). at <http://

## Chapter 3

apps.who.int/classifications/icd10/browse/2010/en>

22. DeLong, E. R., DeLong, D. M. & Clarke-Pearson, D. L. Comparing the areas under two or more correlated receiver operating characteristic curves: a non-parametric approach. *Biometrics* **44**, 837–845 (1988).
23. Basser, P. J., Mattiello, J. & LeBihan, D. MR Diffusion Tensor Spectroscopy and Imaging. *Biophys. J.* **66**, 259–267 (1994).
24. Alexander, A. L., Lee, J. E., Lazar, M. & Field, A. S. Diffusion tensor imaging of the brain. *Neurotherapeutics* **4**, 316–329 (2007).
25. Zhang, Y., Wan, S. & Zhang, X. Geniculocalcarine Tract Disintegration after Ischemic Stroke: A Diffusion Tensor Imaging Study. *AJNR Am J Neuroradiol* **34**, 1890–94 (2013).
26. Groenendaal, F., Benders, M. J. & de Vries, L. S. Pre-wallerian degeneration in the neonatal brain following perinatal cerebral hypoxia-ischemia demonstrated with MRI. *Semin. Perinatol.* **30**, 146–50 (2006).
27. Tuor, U. I. *et al.* Cellular correlates of longitudinal diffusion tensor imaging of axonal degeneration following hypoxic-ischemic cerebral infarction in neonatal rats. *NeuroImage. Clin.* **6**, 32–42 (2014).
28. Lilja, Y. & Nilsson, D. T. Strengths and limitations of tractography methods to identify the optic radiation for epilepsy surgery. *Quant Imaging Med Surg* **5**, 288–299 (2015).
29. Powell, H. W. R. *et al.* MR tractography predicts visual field defects following temporal lobe resection. *Neurology* **65**, 596–599 (2005).
30. Wieshmann, U. C. *et al.* Wallerian Degeneration in the Optic Radiation After Temporal Lobectomy Demonstrated In Vivo with Diffusion Tensor Imaging. *Epilepsia* **40**, 1155–1158 (1999).
31. Ohno, N. *et al.* Alteration of the optic radiations using diffusion-tensor MRI in patients with retinitis pigmentosa. *Br. J. Ophthalmol.* 1–4 (2015).
32. Kaushik, M., Graham, S. L., Wang, C. & Klistorner, A. A topographical relationship between visual field defects and optic radiation changes in glaucoma. *Invest. Ophthalmol. Vis. Sci.* **55**, 5770–5 (2014).
33. Groppo, M. *et al.* Development of the optic radiations and visual function after premature birth. *Cortex* **56**, 30–7 (2014).
34. Berman, J. I. *et al.* Quantitative fiber tracking analysis of the optic radiation correlated with visual performance in premature newborns. *AJNR. Am. J. Neuroradiol.* **30**, 120–4 (2009).
35. De Moraes, C. G. Anatomy of the visual pathways. *J. Glaucoma* **22 Suppl 5**, S2–7 (2013).
36. Iai, M., Yamamura, T. & Takashima, S. Early Expression of Proteolipid Protein in Human Fetal and Infantile Cerebri. *Pediatr Neurol* **17**, 235–239 (1997).
37. Barkovich, A., Kjos, B., Jackson, D. & Norman, D. Normal maturation of the neonatal and infant brain: MR Imaging at 1.5T. *Neuroradiology* 173–180 (1988).
38. Govaert, P. *et al.* Network injury to pulvinar with neonatal arterial ischemic stroke. *Neuroimage* **39**, 1850–7 (2008).
39. Delaney, S. M. *et al.* Stimulus Motion Increases Measured Visual Field Extent in Children 3.5 to 30 Months of Age. *Optom. Vis. Sci.* **77**, 82–89 (2000).
40. Seghier, M. L. *et al.* Visual recovery after perinatal stroke evidenced by functional and diffusion MRI: case report. *BMC Neurol.* **5**, 17 (2005).
41. Groenendaal, F. & van Hof-van Duin, J. Partial visual recovery in two fullterm infants after perinatal hypoxia. *Neuropediatrics* **21**, 76–8 (1990).
42. Guzzetta, A., Fiori, S., Scelfo, D., Conti, E. & Bancalè, A. Reorganization of visual fields after periventricular haemorrhagic infarction: potentials and limitations. *Dev. Med. Child Neurol.* **55 Suppl 4**, 23–6 (2013).
43. Nelson, K. B. & Lynch, J. K. Stroke in newborn infants. *Lancet Neurol* **3**, 150–158 (2004).

44. Urbanski, M., Coubard, O. a & Bourlon, C. Visualizing the blind brain: brain imaging of visual field defects from early recovery to rehabilitation techniques. *Front. Integr. Neurosci.* **8**, 74 (2014).
45. Tuch, D. S. *et al.* High angular resolution diffusion imaging reveals intravoxel white matter fiber heterogeneity. *Magn. Reson. Med.* **48**, 577–82 (2002).
46. Vos, S. B., Jones, D. K., Viergever, M. a & Leemans, A. Partial volume effect as a hidden covariate in DTI analyses. *Neuroimage* **55**, 1566–76 (2011).

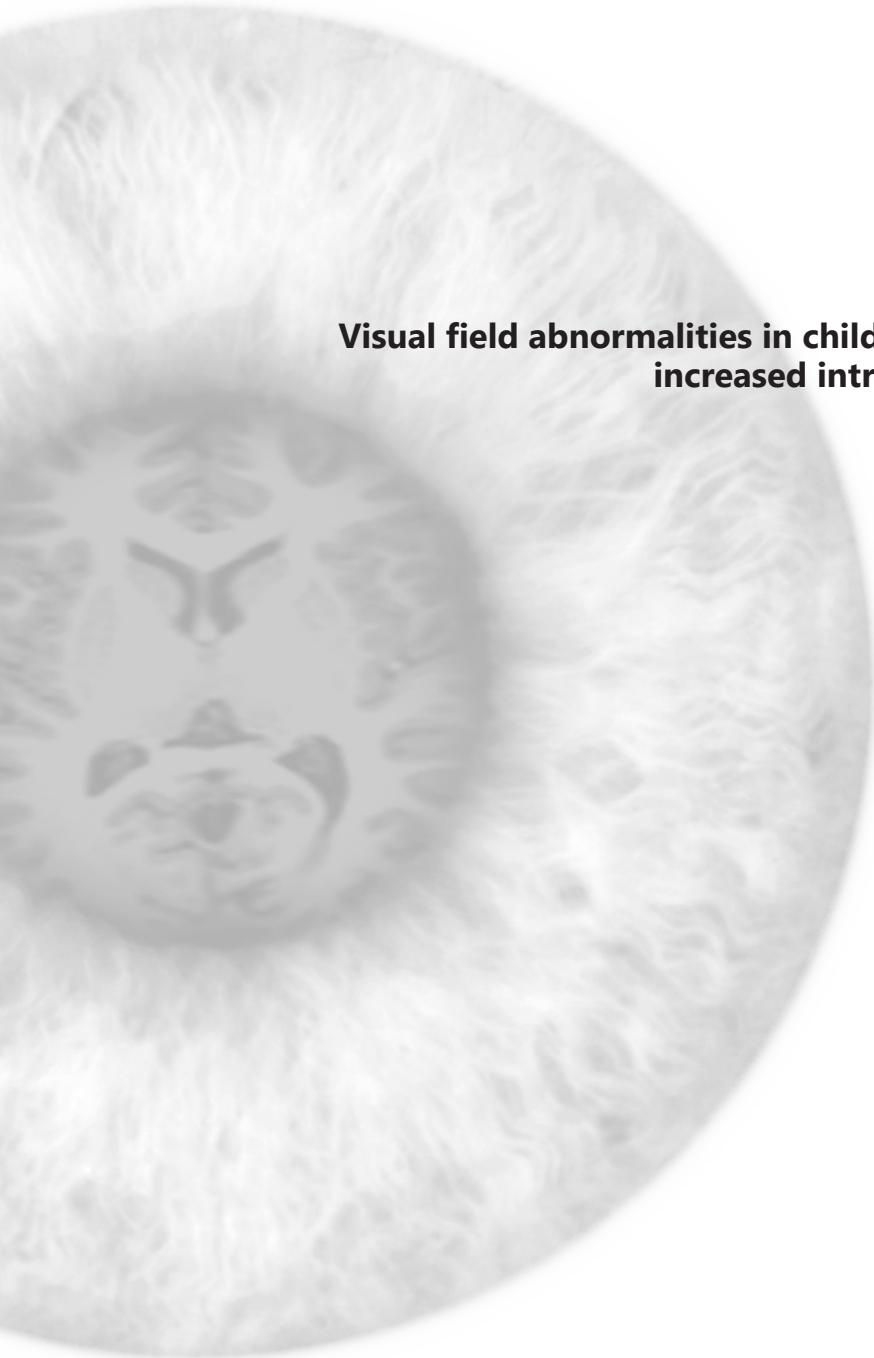




# 4

## **Visual field abnormalities in children suspected of increased intracranial pressure**

Yvonne Koenraads  
Kees P.J. Braun  
Saskia M. Imhof  
Giorgio L. Porro



## ABSTRACT

### Purpose

Aim of this study was to describe the ophthalmological findings, with emphasis on prevalence and type of visual field defects (VFDs), in children suspected of increased intracranial pressure (ICP).

### Methods

Patient files of 192 children referred to our tertiary center between August 1997 and September 2011 because of suspicion of ICP increase were retrospectively analyzed up to September 2015. Ophthalmological findings were presented for children with and without current ICP elevation, differentiating between patients with and those without previous episodes of increased ICP or other pathology. Contribution of clinical characteristics at presentation in demonstrating ICP elevation was explored with receiver operating characteristic analysis. Furthermore, the association between final visual outcome and clinical characteristics at presentation was investigated for children with intracranial hypertension.

### Results

Of the 142 children with normal ICP, 70% had normal VA, 41% normal funduscopy findings, and 67% normal VF examination, in contrast with 82% , 18% , and 34% of 50 children with increased ICP respectively. Majority (46%) of VFDs in children with increased ICP consisted of blind spot enlargement, which had no diagnostic contribution to funduscopy findings (AUC 85% and 83% respectively). In children with isolated ICP elevation, both VA impairment and VFDs at presentation predicted VFDs at follow-up.

**Conclusions**

VF examination at presentation in children suspected of increased ICP does not differentiate between children with and those without intracranial hypertension. However, in children with ICP elevation, standard conventional perimetry (SCP) could provide arguments to start therapy and may help to predict final VF outcome.

## INTRODUCTION

Optic disc swelling or papilledema is often observed at fundoscopy in children with increased intracranial pressure (ICP).<sup>1</sup> Although papilledema in increased ICP can be objectified with fluorescein angiography (FA), optical coherence tomography (OCT),<sup>2-6</sup> ultrasound (USG) or orbital CT-scan, it is easily confused with other forms of optic disc swelling that are not caused by increased ICP, e.g. papillitis, compressive optic neuropathy or pseudopapilledema.<sup>7,8</sup> Symptoms of ICP elevation in children are also non-specific and may mimic migraine or ophthalmological disorders with visual impairment and secondary headache.

Visual loss, particularly manifesting as visual field defects (VFD), has been extensively reported as an important ophthalmological consequence of ICP elevation, mainly in idiopathic intracranial hypertension (IIH).<sup>1-3,6,8-30</sup> Until VF loss is profound, patients may be unaware of these deficits.<sup>19,23,31,32</sup> Therefore, most authors state that VF examination is essential for diagnosis and start of treatment in case of suspected ICP increase.<sup>8,17,19,26,33,34</sup> However, interpretation of VFDs may be difficult since VFDs also occur in other ophthalmological – some of which accompanied with papillary abnormalities – or neurological pathology, or they may have developed during an earlier episode of increased ICP, while pressure at time of presentation is normal.<sup>8,35</sup> Moreover, inability of children to understand the test and poor attention span may bias the VF test results with false positive findings.<sup>8,19</sup> In addition, simplified methods developed for VF examination in young children, such as the BEFIE test, are not specifically adapted to study the consequences of ICP elevation since they only detect peripheral VFDs.<sup>36</sup>

The principal aim of this retrospective study was to describe the ophthalmological findings, with emphasis on the prevalence and type of VFDs, in all children suspected of increased ICP, seen in our center. In particular, we correlated ophthalmological findings with the eventual diagnosis – i.e. ICP elevation or not – taking into account the absence or presence of previous episodes of ICP elevation or other pathology that may influence VFs. Finally, we aimed to relate clinical characteristics and ophthalmological findings at presentation with final visual outcome of children with increased ICP.

## METHODS

### Patient selection

All children referred to our center between August 1997 and September 2011 because of suspicion of ICP increase, who underwent standard conventional perimetry (SCP), were consecutively included. To select these patients, medical files of 1696 children who underwent 3259 SCPs were screened using the following criteria: (1) annotations in the medical files of possibly elevated ICP, or the need to rule out ICP elevation, or (2) symptoms consistent with elevated ICP, such as headache, nausea, vomiting, transient visual obscuration or papilledema<sup>37</sup>, present around time of SCP. If a child underwent more than one SCP examination in our center, only the first examination was selected. Unreliable SCP measurements or those performed only after treatment, were excluded. The study was approved by our institutional medical ethical committee.

### Data collection

Demographic and clinical characteristics were retrospectively collected from the patient files up to September 2015.

SCP was performed with the Goldmann perimeter, Rodenstock Peritest<sup>38</sup> or Humphrey Field Analyzer. Possible VFDs included enlarged blind spots (EBS) (graded as *mild/severe*), widespread defects (*few/extensive*), central scotomas (*relative/absolute*), homonymous defects (*incomplete/complete quadrantanopia/hemianopia*), concentric defects (*mild/severe*), overall sensitivity decreases (*mild/severe*), paracentral scotomas, nasal restrictions (or step), altitudinal defects (*incomplete/complete*), arcuate defects, or bitemporal defects.

Visual acuity (VA) measurements were performed with the Kays Picture or Snellen Chart. Best corrected VA was converted to LogMAR and classified as normal (-0.2-0.1), mildly impaired (0.2-0.5), moderately impaired (0.6-0.9), severely impaired (1.0-1.3), profound (1.4-1.7) or (near-)blind (1.8-2.0).<sup>39</sup>

Optic discs were assessed by means of dilated fundoscopy and classified as normal, (suspect) papilledema or optic atrophy or paleness. According to the annotations in the medical files, the appearance of (suspect) papilledema was graded (*possible/mild/moderate/severe*) based on the Frisén Papilledema Grading Scale.<sup>40</sup> Children in whom it was noted in the chart that there was any uncertainty about the optic disc appearance were again examined by a more experienced ophthalmologist or underwent ancillary investigation of the optic disc by means of USG, FA or OCT. Eventual interpretation of the optic disc abnormality, as noted in the medical files, was based on these findings and on additional clinical information, and was classified as '*chronic papilledema*', '*optic atrophy/paleness*', '*idiopathic pseudopapilledema*', '*optic disc drusen*', '*tilted optic disc*', '*hypoplastic/dysplastic optic disc*' or '*papillitis*' based on the differential diagnosis of papilledema by Friedman.<sup>41</sup>

4 Findings on neuro-imaging were classified as '*possible clue for increased ICP*', '*doubtful clue*' or '*other*', according to the annotations made by the radiologist. 'Possible' clues were categorized as '*new findings*' or '*abnormalities that were non-progressive over time*' and included a hydrocephalus, cerebral venous thrombosis or cerebral tumor with mass effect, while 'doubtful' clues comprised a small cerebral tumor, slightly dilated ventricular system or small intracranial hemorrhage. Neuro-imaging findings classified as 'other' included normal scans and scans with abnormalities not related to ICP increase.

### **ICP categories**

We classified patients into two categories, based on the eventual assessment of ICP, as either 'elevated' or 'normal'. Children in whom ICP increase was uncertain were excluded from further analysis. Within the category 'elevated ICP', a subgroup was considered to suffer from 'proven' ICP increase, when fulfilling one or more of the following criteria: (1) cerebrospinal fluid pressure (CSFP) measurement above 30cm H<sub>2</sub>O, (2) CSFP measurement above 25cm H<sub>2</sub>O and disease course suiting ICP elevation or (3) symptoms that decreased after treatment for elevated ICP. Within the category 'normal ICP', children were designated as 'proven normal', when (1) CSFP measurement was under 15cm H<sub>2</sub>O, (2) they had another established diagnosis

explaining symptoms and signs or (3) they had another diagnosis with a follow-up of at least one year without other signs of increased ICP.

VFDs at presentation may have also been caused by focal central nervous system (CNS) pathology itself, or by ophthalmological diagnoses that led to the suspicion of raised ICP. We therefore presented ophthalmological findings of children with such disorders separately from those without. Furthermore, we differentiated between patients with and without previous episodes of ICP elevation.

### **Final visual outcome**

Visual outcome at the end of follow-up, consisting of VA, optic disc and VF assessment, was collected of children with ICP elevation at presentation or in the past, but no other CNS or ophthalmological pathology. To explore possible predictive factors, the relation between final visual outcome and clinical characteristics at presentation with ICP elevation was investigated.

### **Statistical analysis**

Statistical analysis was performed using SPSS 21.0.<sup>42</sup> ROC-curves were created to determine the differences in the area's under the curve (AUC), representing the contribution of clinical characteristics and ophthalmological findings at presentation to establish ICP elevation. Associations between possible predictive factors and final visual outcome in children with ICP elevation at first examination in our center were assessed using Fischer's exact or Mann-Whitney U tests.

## RESULTS

### Patients

Of all 216 children, selected out of 1696, who performed reliable SCP, 23% (n=50) were retrospectively categorized as having increased ICP at time of SCP, while 66% (n=142) were considered to have normal ICP. In 11% of children, presence or absence of ICP elevation remained inconclusive, leaving 192 children for further analysis.

Diagnoses of children with increased ICP included IIH, hydrocephalus, drain dysfunction, cerebral venous thrombosis or chronic meningitis. The group without ICP elevation (and without other pathology that may cause VFDs) included children with CSF over-drainage, refractive errors, accommodation problems, postprandial hypoglycemia, simulation disorder, tonsillitis, headache, fatigue, unexplained neurologic symptoms or visual complaints unrelated to ICP elevation, or children who turned out to have normal ICP while being investigated because of suspected papilledema, macrocephaly, ventriculomegaly, craniosynostosis or osteopetrosis. Clinical diagnoses in all separate groups are listed in the eTable.

### Findings at presentation

#### *Clinical symptoms*

Baseline characteristics of children with and without ICP elevation are presented in Table 1. Ages were comparable between groups. Complaints were relatively least frequent in children with no current nor previous ICP elevation. In most of these children without complaints the suspicion of ICP elevation arose because suspect papilledema was observed at fundoscopy. In children with current ICP elevation and a previous history of intracranial hypertension, complaints were most often (67%) acute (<6 wks), while they were least often (16%) acute in children without current, but with previous ICP elevation. Complaints consisted mainly of headache, except in children without ICP elevation but with other (VF influencing) pathology (41%), in whom visual complaints were more frequent (76%).



**eTable. Clinical diagnoses of children suspected of ICP increase**

	ICP elevation	No ICP elevation
No other (focal CNS or ophthalmological) pathology	Benign/idiopathic intracranial hypertension (n=23), Chronic sterile meningitis (n=1), Hydrocephalus (n=2), Cerebral venous thrombosis (n=3).	Accommodation problems (n=3), Chronic fatigue syndrome (n=1), Craniosynostosis without elevated ICP (n=2), Physiologic macrocephaly (n=4), Physiologic ventriculomegaly (n=1), Idiopathic pseudopapilledema (n=21), Headache not related to elevated ICP (n=33), Osteopetrosis without elevated ICP (n=1), Postprandial hypoglycemia (n=1), Refractive error (n=3), Unexplained visual complaints (n=5).
Previous ICP elevation	Benign/idiopathic intracranial hypertension (n=4), Drain dysfunction (n=4), Hydrocephalus (n=2).	Fatigue (n=2), Headache not related to elevated ICP (n=14), Over-drainage (n=2), Refractive error (n=1), Simulation (n=1), Tonsillitis (n=1), Unexplained visual complaints (n=4).
Focal CNS or ophthalmological pathology	Benign/idiopathic intracranial hypertension (also panuveitis) (n=1), intracranial hemorrhage (n=1), Drain dysfunction (also manifestations of tuberous sclerosis in brain and eye) (n=1), cerebral tumor (n=8).	Check-up after traumatic brain injury (n=1), Cone dysfunction (n=1), Diffuse encephalopathy with focal lesions on MRI (n=1), Headache not related to elevated ICP (but also optic disc atrophy or previous cerebral tumor) (n=5), Hypoplastic/dysplastic optic disc (n=4), Optic atrophy (n=4), Optic disc drusen (n=8), Optic neuritis/papillitis (n=9), Optic pathway glioma (n=1), Refractive error (but also hypoplastic/dysplastic optic disc, optic disc atrophy or tilted disc) (n=3), Tilted disc (n=1), Unexplained neurologic symptoms (but previous intracranial hemorrhage) (n=1), Unexplained visual complaints (but also optic disc atrophy or cone dysfunction) (n=3).

**Table 1. Baseline characteristics of 192 children suspected of ICP increase**

Focal CNS or ophthalmological pathology	ICP increase (n=50) median [range] or % (n)		
	- (n=39)	+	+
Previous ICP elevation	- (n=29)	+ (n=10)	+/- (n=1/10)
<b>Age at first episode of ICP elevation (yrs)</b>	<b>11.5</b> [5.4-17.6]	<b>2.4</b> [0.0-17.1]	<b>12.2</b> [5.1-16.9]
<b>Sex (male)</b>	<b>38%</b> (11/29)	<b>30%</b> (3/10)	<b>64%</b> (7/11)
<b>Age, yrs</b>	<b>11.4</b> [5.3-17.6]	<b>14.0</b> [5.2-17.8]	<b>12.2</b> [5.1-16.9]
<b>COMPLAINTS</b>	<b>97%</b> (28/29)	<b>90%</b> (9/10)	<b>100%</b> (11)
<b>Duration, wks</b>	<b>13.8</b> [0.6-584.2]	<b>3.8</b> [0.2-22.3]	<b>8.4</b> [1.4-20.0]
Acute (< 6 wks)	<b>43%</b> (12/28)	<b>67%</b> (6/9)	<b>45%</b> (5/11)
<b>Type</b>			
Headache	<b>79%</b> (22/28)	<b>78%</b> (7/9)	<b>73%</b> (8/11)
Visual complaint	<b>36%</b> (10/28)	<b>33%</b> (3/9)	<b>55%</b> (6/11)
Nausea/vomiting	<b>39%</b> (11/28)	<b>33%</b> (3/9)	<b>55%</b> (6/11)
Cognitive problems	<b>7%</b> (2/28)	<b>11%</b> (1/9)	<b>18%</b> (2/11)
Fatigue	<b>11%</b> (3/28)	-	-
Other	<b>29%</b> (8/28)	<b>22%</b> (2/9)	<b>55%</b> (6/11)
<b>NEUROIMAGING CLUES</b>			
Possible <sup>1</sup> , new finding	<b>21%</b> (6/28)	<b>50%</b> (5/10)	<b>18%</b> (2/11)
Possible <sup>1</sup> , non-progressive	<b>4%</b> (1/28)	<b>10%</b> (1/10)	<b>9%</b> (1/11)
Doubtful <sup>2</sup>	<b>7%</b> (2/28)	-	<b>73%</b> (7/11)
<b>ICP CLASSIFICATION</b>			
Proven elevated ICP <sup>4</sup>	<b>97%</b> (28/29)	<b>100%</b> (9/9)	<b>91%</b> (10/11)
Proven normal ICP <sup>5</sup>	-	-	-

ICP, intracranial pressure; CNS, central nervous system; VF, visual field; <sup>1</sup> Possible clue for ICP system, cerebral venous thrombosis or cerebral tumor with mass effect; <sup>2</sup> Doubtful clue for ICP mor, slightly dilated ventricular system or intracranial hemorrhage; <sup>3</sup> physiologically enlarged surement above 30cm H<sub>2</sub>O, (2) a CSFP measurement above 25cm H<sub>2</sub>O and a disease course creased after treatment for elevated ICP; <sup>5</sup> Proven normal ICP, (1) CSFP measurement was uning symptoms and signs or (3) another diagnosis with a follow-up of at least one year without

Visual field findings in increased intracranial pressure

ICP normal (n=142) median [range] or % (n)		
- (n=100)		+
- (n=75)	+	+/- (n=6/36)
		n=5
-	<b>0.3</b> [0.0-15.7]	<b>5.2</b> [0.1-14.3]
<b>32%</b> (24/75)	<b>28%</b> (7/25)	<b>45%</b> (19/42)
<b>11.3</b> [5.4-18.0]	<b>13.7</b> [6.8-16.8]	<b>10.7</b> [6.7-17.6]
<b>73%</b> (55/75)	<b>100%</b> (25/25)	<b>88%</b> (37/42)
<b>14.3</b> [0.0-560.0]	<b>15.6</b> [1.1-82.0]	<b>7.9</b> [0.0-273.3]
<b>25%</b> (14/55)	<b>16%</b> (4/25)	<b>46%</b> (17/37)
<b>80%</b> (44/55)	<b>84%</b> (21/25)	<b>41%</b> (15/37)
<b>47%</b> (26/55)	<b>28%</b> (7/25)	<b>76%</b> (28/37)
<b>20%</b> (11/55)	<b>24%</b> (6/25)	<b>11%</b> (4/37)
<b>7%</b> (4/55)	<b>4%</b> (1/25)	<b>5%</b> (2/37)
<b>13%</b> (7/55)	<b>12%</b> (3/25)	<b>3%</b> (1/37)
<b>20%</b> (11/55)	<b>20%</b> (5/25)	<b>24%</b> (9/37)
<b>9%</b> (3/32) <sup>3</sup>	<b>4%</b> (1/23) <sup>3</sup>	-
<b>6%</b> (2/32) <sup>3</sup>	<b>9%</b> (2/23)	<b>3%</b> (1/29)
<b>3%</b> (1/32) <sup>3</sup>	<b>13%</b> (3/23)	<b>14%</b> (4/29)
-	-	-
<b>71%</b> (53/75)	<b>92%</b> (23/25)	<b>81%</b> (34/42)

elevation on neuroimaging, such as a dilated ventricular elevation on neuroimaging, such as a small cerebral tu-ventricular system; <sup>4</sup> Proven elevated ICP, (1) a CSFP measuring ICP elevation or (3) symptoms and/or signs that der-der 15cm H<sub>2</sub>O, (2) another established diagnosis explain-other signs of increased ICP.

Visual acuity

VA was normal in 70% (95/135) of children with normal ICP and in 82% (37/45) of children with increased ICP (see Table 2). In the group without ICP elevation but with other CNS or ophthalmological pathology, VA was impaired most often (49%), corresponding to the higher percentage of visual complaints.

Fundusoscopic findings

Findings at fundoscopy were normal in 41% (58/142) of children with normal ICP and in 18% (9/49) of children with increased ICP. Suspect papill- edema was present in ~75% of children with ICP elevation (without other pathology), in ~90% of children with in- creased ICP and other pa- thology, and in up to 60% of children who were eventually diagnosed with normal ICP. Presence and severity of (sus-



pect) papilledema in each subcategory are shown in eFigure 1. ICP was assessed as elevated in only 35% (39/112) of children with (suspect) papilledema. In 21% (23/112) of children, the assumed papilledema was eventually – after ancillary investigations or a second look – diagnosed as optic disc drusen (n=8), tilted optic disc (n=2), hypoplastic/dysplastic optic disc (n=5) or papillitis (n=8). In the remaining 45% (50/112) of children with (suspect) papilledema, ICP was assessed to be normal and the observed papilledema was assumed to be chronic (n=6) or classified as idiopathic pseudopapilledema (n=44). An overview of final optic disc classifications is given in Figure 1.

**Table 2. Visual acuity impairment among all children suspected of ICP increase**

	ICP elevation	No ICP elevation
No other (focal CNS or ophthalmological) pathology	<b>14%</b> (4/28) *3 mildly [2] *1 severely [1]	<b>19%</b> (13/70) *10 mildly [2] *3 mild and moderately [3]
Previous ICP elevation	<b>22%</b> (2/9) *2 mildly [1]	<b>29%</b> (7/24) *7 mildly [4]
Focal CNS or ophthalmological pathology	<b>25%</b> (2/8) *1 mildly [1] *1 nearly blind [0]	<b>49%</b> (20/41) *12 mildly [4] *8 moderately to blind [6]

Percentage (n) and severity of visual acuity (VA) impairment in each subcategory of children with and without ICP elevation [number of children in which both eyes are affected] ICP, intracranial pressure; CNS, central nervous system.

#### Visual field examination

SCP was performed with the Rodenstock Peritest (95%), Goldmann perimeter (1%) or Humphrey Field Analyzer (5%). Results were normal in 67% (95/142) of children with normal ICP

**eFigure 1. Presence and severity of (suspect) papilledema at fundoscopy in all children suspected of ICP increase**

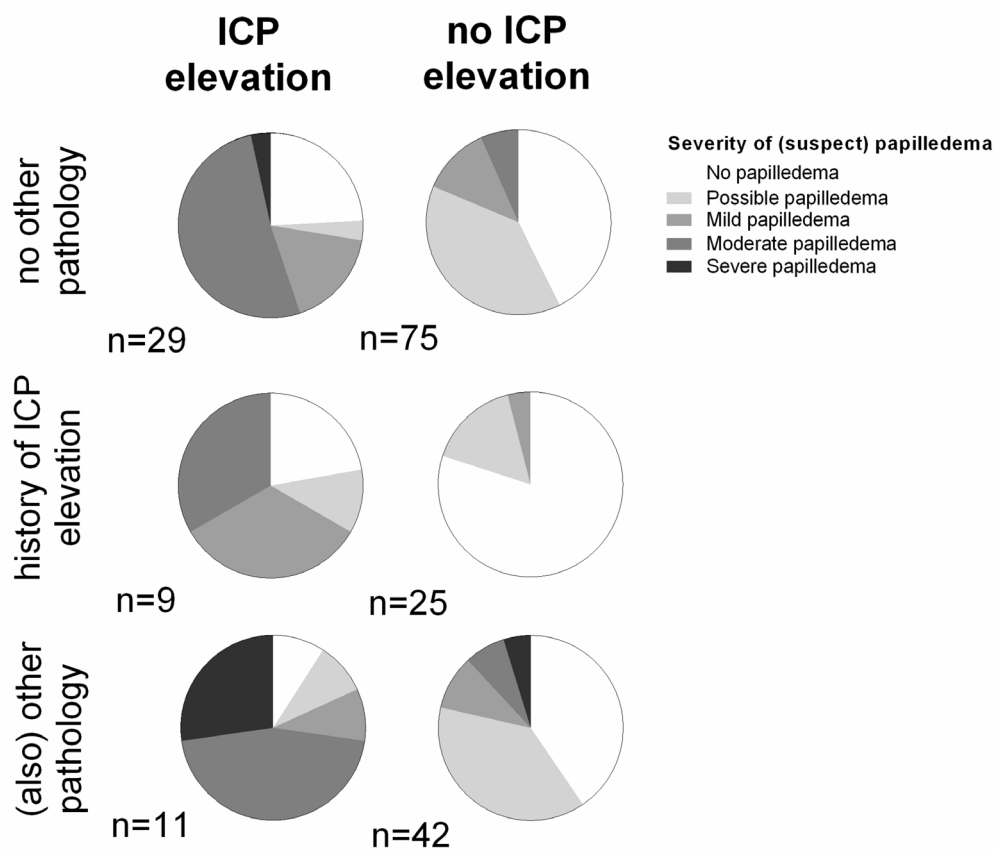
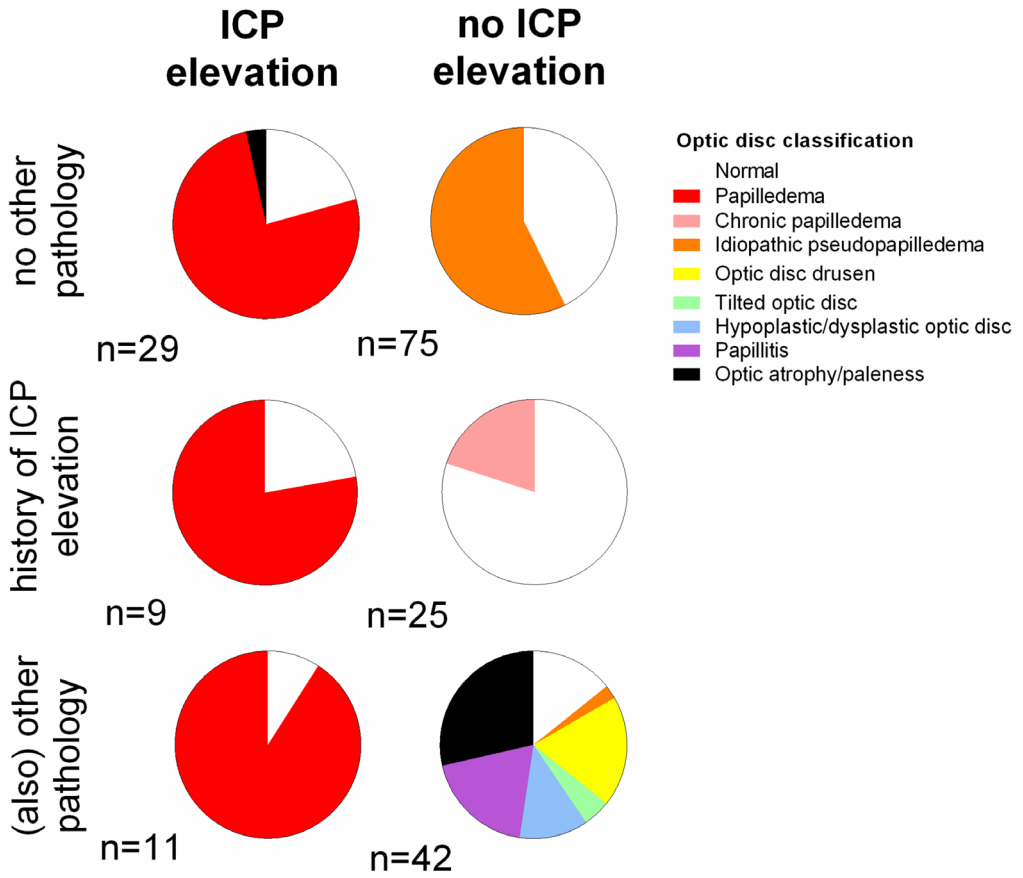


Figure 1. *Optic disc classifications of all children suspected of ICP increase*



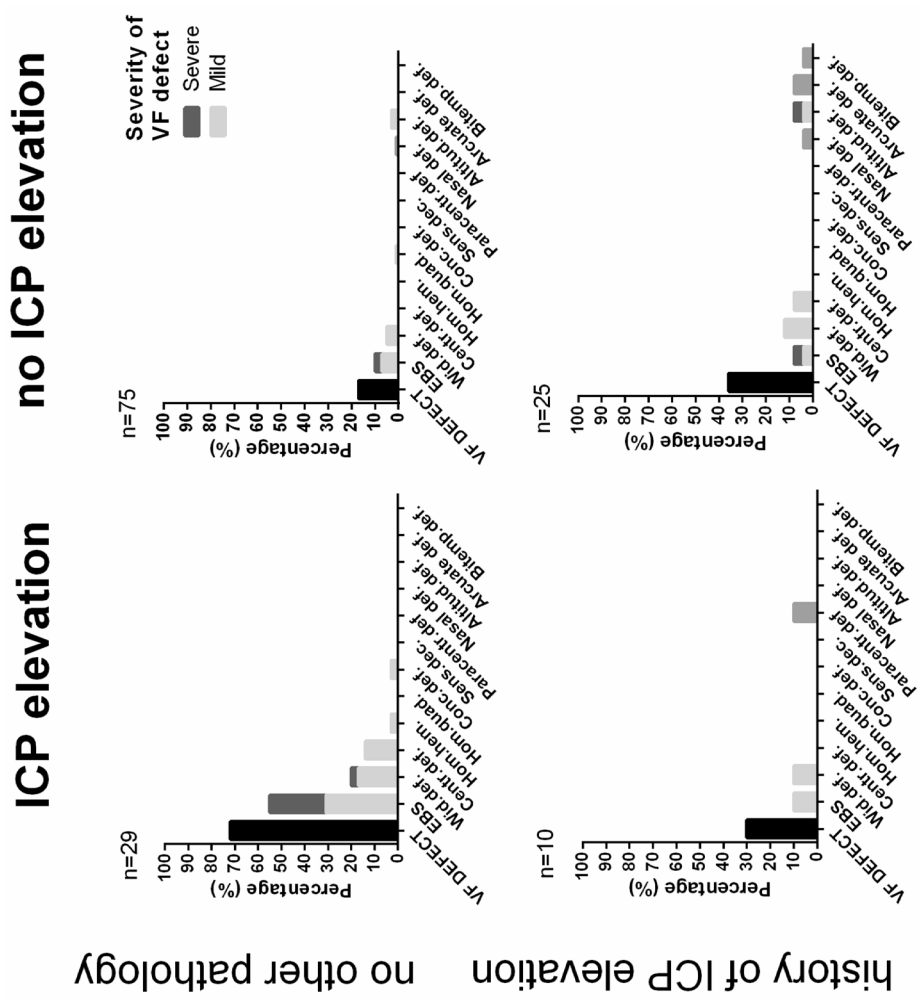
and in 34% (17/50) of children with increased ICP. In children with a first episode of ICP elevation, VFDs were present in 72% (see Figure 2). In this group, VFDs mainly consisted of EBS (55%). In some children widespread defects (21%), central scotoma (14%), homonymous defect (3%) or concentric VFD (3%) were reported. In both groups with previous ICP elevation (with and without current ICP elevation) VFDs occurred in approximately one third of children. Remarkably, 17% (13/75) of children with normal ICP without previous ICP elevation and no other pathology (that may cause VFDs) still had VFDs. These children had idiopathic pseudo-papilledema (n=5), headache unrelated to ICP elevation (n=2) or both (n=6), and showed EBS (n=7), widespread defects (n=4), a nasal restriction with a peripheral inferior defect (n=1) and a peripheral superior defect with a homonymous component (n=1) on SCP. The latter was a coincidental finding without presence of any neurologic abnormality on neuroimaging. EBS also occurred in 11 children with papillitis (n=4), optic drusen (n=3), optic atrophy (n=2) or previous ICP elevation (n=2). In addition, other kinds of VFDs were seen in children with these (n=19) and other (n=9) pathologies.

While complaints, VA and VFDs other than EBS were aspecific, the presence and severity of (suspect) papilledema and EBS on SCP were more distinctive for having ICP elevation. To investigate whether the finding of an EBS on SCP contributes to the assessment of the optic disc in the diagnosis of increased ICP, the predicted probabilities of these parameters were combined in a ROC-curve (see eFigure 2). This analysis revealed that adding results of EBS assessment on SCP to the fundoscopy findings did not essentially change the AUC (83% [95%CI 0.75-0.90] and 85% [95%CI 0.78-0.91] respectively).

### **Visual outcome of children after elevated ICP**

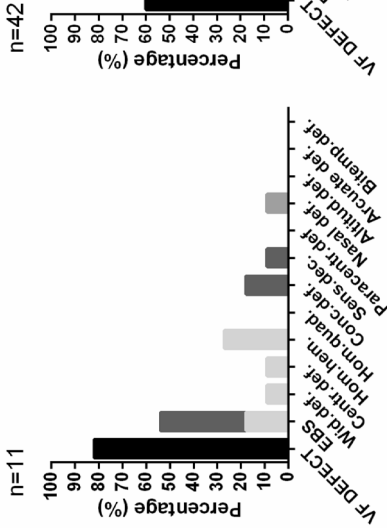
Of all 64 children with current or previous ICP elevation without other pathology, 51 underwent ophthalmological follow-up (final median age 15.8, range 6.2-28.0 yrs). Of the 50 children with multiple VA and optic disc assessments, 86% had a normal and 12% a mildly impaired final VA. One child with IIH seemed (near-)blind but was suspected of conversion disorder, based on VEP and eye-tracker examinations. Final assessment of the optic discs revealed (possible)

Figure 2. Visual field defects on standard conventional perimetry in all children suspected of ICP increase





(also) other pathology



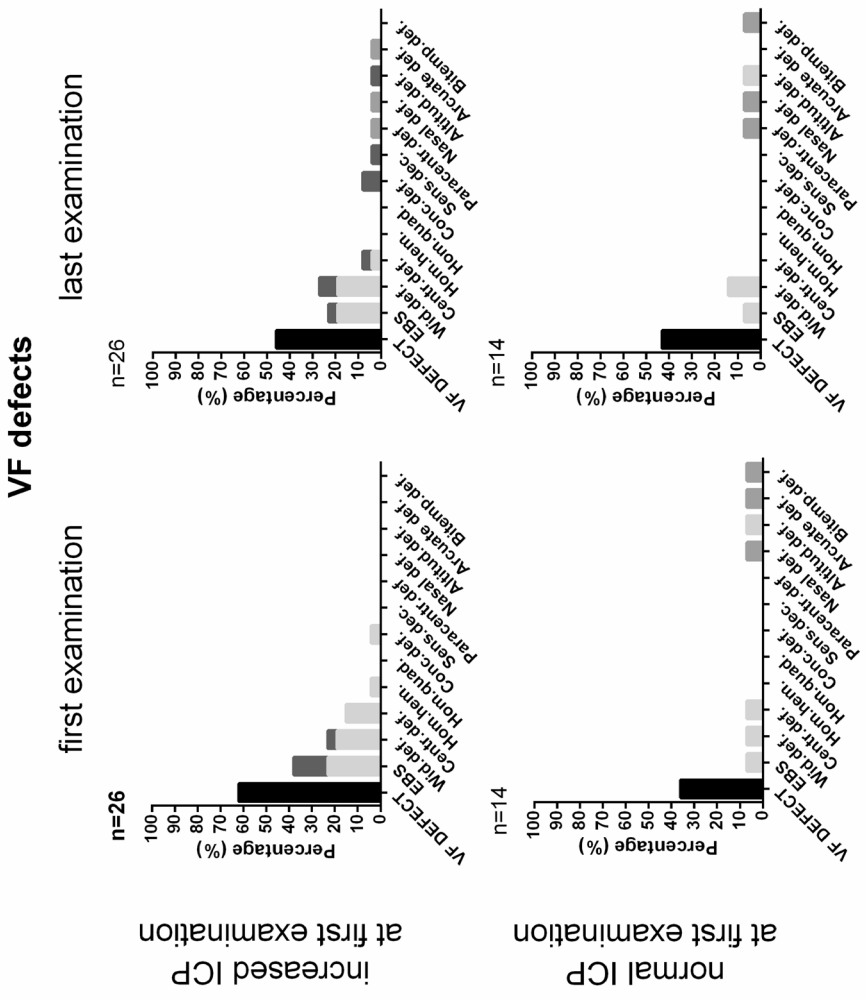
Total percentage of visual field defects (in black) and type and severity of visual field defects of all children suspected of ICP increase are presented for each subcategory.

EBS, enlarged blind spot [mild/severe]; Wid.def, widespread defects [mild=few, severe=extensive]; Centr.def, central scotoma [mild= <18 dB (relative), severe= >18dB (absolute)]; Hom.hem., homonymous hemianopia [mild=incomplete, severe=complete]; Hom.quad., homonymous quadrantanopia [mild=incomplete, severe=complete]; Conc.def., concentric defect [mild/severe]; Sens.dec., overall sensitivity decrease [mild= <8 dB, severe= >8dB]; Paracentr.def., paracentral scotoma; Nasal def, nasal step/restriction; Altitud.def., altitudinal defect [mild=incomplete, severe=complete]; Arcuate def, arcuate defect; Bitemp.def., bitemporal defect

papilledema in 12% and paleness or atrophy in 8% of children.

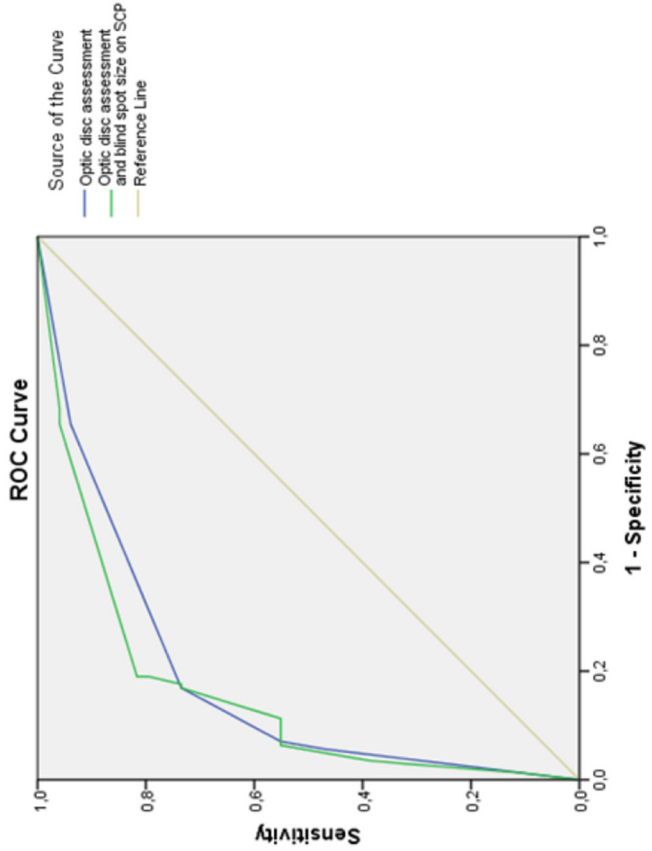
Of the 40 children who underwent multiple VF examinations, 45% had a VFD at final follow-up or at presentation (20 Humphrey, 20 Peritest), including widespread defects (50%), EBS (39%), altitudinal, nasal, paracentral, central, and concentric defects (each 11%), and arcuate scotomas, bitemporal defects and overall sensitivity decreases (each in 6%). An overview of the VFDs found at first and last examination, separately displayed for the 26 children with, and 14 without ICP elevation during first examination, is shown in eFigure 3.

**Figure 3. VF defects at first and last examination of children with ICP elevation without other pathology who had a SCP follow-up, separately displayed for children with, and those without ICP elevation during first examination**



Total percentage of visual field defects (in black) and type and severity of visual field defects. EBS, enlarged blind spot [mild/severe]; Wid.def, widespread defects [mild=few, severe=extensive]; Centr.def, central scotoma [mild= <18 dB (relative), severe= > 18dB (absolute)]; Hom.hem., homonymous hemianopia [mild=incomplete, severe=complete]; Hom.quad., homonymous quadrantanopia [mild=incomplete, severe=complete]; Conc.def., concentric defect [mild/severe]; Sens.dec., overall sensitivity decrease [mild= <8 dB, severe= >8dB]; Paracentr.def., paracentral scotoma; Nasal def., nasal step/restriction; Altitud.def., altitudinal defect [mild=incomplete, severe=complete]; Arcuate def., arcuate defect; Bitemp.def., bitemporal defect

**Figure 2. Receiver Operating Characteristic curve of the contribution of optic disc assessment and blind spot enlargement on SCP to demonstrate ICP elevation**



Visual field findings in increased intracranial pressure

**Table 3. Association between characteristics at presentation and visual outcome at final examination in children with ICP elevation**

<i>Median [range] in yrs or n (%)</i>	<b>Final VF defect</b> 12/26 children	p-value	<b>Final VA impairment</b> 5/30 children	p-value
<b>Sex</b>		0.43		1.00
Male	3 (33%)		2 (20%)	
Female	9 (53%)		3 (15%)	
<b>Pathology</b>		0.83		0.17
Hydrocephalus	2 (50%)		2 (33%)	
BIH/IIH	8 (42%)		2 (10%)	
Other	2 (67%)		1 (33%)	
<b>Age at first ICP elevation</b>	11.4 [0.0-17.6]	0.60	11.9 [0.0-17.6]	0.87
<i>Whole VF group 10.4 [0.0-17.6]</i>				
<i>Whole VA group 10.4 [0.0-17.6]</i>				
<b>Age at presentation</b>	11.4 [5.3-17.6]	0.35	12.1 [11.4-17.8]	0.10
<i>Whole VF group 11.2 [5.2-17.6]</i>				
<i>Whole VA group 11.5 [5.2-17.8]</i>				
<b>VA at presentation</b>		<b>0.03</b>		<b>0.003</b>
Normal	8 (36%)		1 (4%)	
Impaired	4 (100%)		4 (67%)	
<b>Optic disc at presentation</b>		0.60		1.00
Normal	1 (25%)		1 (17%)	
Abnormal	11 (50%)		4 (17%)	
<b>VF at presentation</b>		<b>0.05</b>		1.00
Normal	2 (20%)		2 (20%)	
VF defect	10 (63%)		3 (15%)	
<b>Recurrences</b>		1.00		<b>0.003</b>
No	7 (44%)		0 (0%)	
Yes	5 (50%)		5 (45%)	

VF, visual field; VA, visual acuity; VA impairment, worse than 0.1 LogMAR in one or two eyes; BIH/IIH, benign or idiopathic intracranial hypertension; Other, other kinds of underlying pathology including cerebral venous thrombosis, cranium deformations, intracranial hemorrhages or inflammation; presentation, first examination in our center at the moment of ICP elevation; Recurrences, recurrences between presentation and final visit.

### *Visual field findings in increased intracranial pressure*

All children with final VA impairment also had VFDs if SCP was performed. The association between characteristics at presentation and the final presence of a VFD or VA impairment was investigated in the children with ICP elevation during first examination (see Table 3). VFDs at final examination were associated with VA impairment and the presence of a VFD at presentation, while VA impairment at final examination was associated with VA impairment and recurrent episodes of increased ICP between first and last examination. Remarkably, ICP recurrences did not seem to influence final presence or absence of a VFD.

## DISCUSSION

This study describes the ophthalmological findings in 192 children suspected of ICP elevation, with emphasis on the prevalence and type of VFDs. Of 142 patients with normal ICP 41% had normal funduscopic and 67% normal VF findings, in contrast to 18% and 34% of 50 children with increased ICP respectively. Only 35% of children with suspected papilledema were diagnosed with increased ICP. Eventual follow-up of children with documented intracranial hypertension revealed a normal VA in 86%, mildly impaired VA in 12%, and VFDs in 45% of patients. SCP findings were rarely distinctive for ICP elevation, while they might – together with VA findings – predict final VF outcome in children with ICP elevation at presentation.

VFDs in children with ICP elevation include deficits secondary to (1) optic nerve compression with axoplasmic flow stasis in papilledema<sup>8,19</sup> such as EBS<sup>17</sup> and glaucomatous-like nerve fiber layer (NFL) defects,<sup>2,8,11,18-28</sup> or (2) compression of the retrochiasmatic pathways (e.g. in hydrocephalus) which may provoke homonymous VFDs.<sup>30</sup> In this study we noticed that in children with ICP elevation VFDs at presentation mainly consisted of EBS while other VFDs were scarce and also occurred in children with other pathology than ICP elevation.

EBS presumably arises secondary to a refractive scotoma, caused by displacement of the peripapillary rods and cones by swollen axons, and could confirm papilledema.<sup>2,8,17</sup> However, our ROC analysis revealed that it did not significantly contribute to optic disc assessment in children suspected of ICP elevation. Corresponding to previous reports, EBS in our study was not present in all children with papilledema, while other children, who were referred for the evaluation of possibly increased ICP because of suspected papilledema but were eventually diagnosed with other papillary abnormalities, could also have an EBS.<sup>2,19,27</sup>

Glaucomatous-like NFL defects may also occur in an early stage of ICP elevation and probably result from mechanical compression and ischemic damage, which provokes paracentral, nasal, altitudinal and arcuate VFDs.<sup>18,20,27</sup> Surprisingly, these VFDs were rarely seen at presentation in patients with ICP elevation while they did occur in children without ICP elevation but with previous ICP elevation, papillitis, cone dysfunction or optic atrophy. Possibly the NFL was not

yet damaged at the moment of presentation in children with ICP elevation. Alternatively the Peritest, used in most children because of feasibility reasons, may have a lower sensitivity to pick up these kind of VFDs compared to Humphrey VF testing.

VFDs that were present at presentation in some children with ICP elevation included concentric and (relative) central VFDs, known as late findings caused by expanding edema, but also homonymous and widespread defects.<sup>2,8,18,19,24,27,29</sup> Corresponding to the literature, all these VFDs were not specific for increased ICP, being also detected in children without ICP elevation. At the end of follow-up most children had a favorable VA but VFDs were regularly present, especially in children who had an impaired visual function (VA or VF defects) at presentation. In contrast, Gospe et al.<sup>43</sup> recently showed that mainly the grade of papilledema was highly predictive for (permanent) VA or VF loss in 31 children with IIH.

In contrast to the finding of Pollak et al.<sup>44</sup> that adult IIH patients with recurrent ICP elevation showed more VFDs than those without, we found that (1) recurrent episodes of ICP increase seemed not associated with the presence of VFDs at the end of follow-up, and (2) VFDs at presentation in children with increased ICP occurred less often in children with previous episodes of ICP elevation, compared to those who had their first episode. A possible explanation, supported by the short duration of symptoms in most children with previous ICP increase, may be that an increased awareness in these patients has resulted in earlier diagnosis of their recurrent ICP elevation.

Our study mainly focused on VF measurements, as perimetry is one of the oldest methods used in the assessment of ICP elevation<sup>54</sup> and VFDs are considered one of the most important consequences of ICP elevation.<sup>1-3,6,9-16,19,26,27,46,47</sup> However, in current ophthalmological practice various alternative methods to objectify papilledema, assess the presence of ICP increase, and monitor disease progression, are often used. These methods include assessment of leakage and disc fluorescence on FA, optic nerve sheath diameter on USG<sup>48</sup> or CT scan of the orbits and peripapillary and perimacular retinal NFL thickness on OCT.<sup>2-6</sup> While USG examination of the optic disc is crucial to rule out optic neuropathies such as optic disc drusen,<sup>8</sup> OCT might monitor disease progression in children who cannot reliably perform SCP.<sup>5</sup>

## Chapter 4

Limitations of our study included a possible selection bias due to exclusion of children with uncertain ICP, unreliable SCPs, or those who performed SCP after start of treatment. In addition, the classification used was based on eventual ICP assessment, which could not guarantee the demonstration or exclusion of actual ICP elevation at time of SCP in all cases. Finally, since it was impossible in the group of children classified with 'idiopathic pseudopapilledema' to distinguish between false positive or true pseudopapilledema, some children with pseudopapilledema and secondary VFDs might have been mistakenly classified in the group without other pathology.



## **CONCLUSIONS**

SCP findings in children rarely contribute to the diagnostic work-up at moment of first evaluation in case of suspected ICP elevation. In our series, EBS had no additional diagnostic value to the presence of (suspect) papilledema, while other VFDs were scarce and should not be confused with those attributable to other or former pathology. The current study shows that SCP should not necessarily be used for diagnostic purposes in daily ophthalmological practice when increased ICP is suspected in children. The presence of VFDs in children with ICP elevation may, however, provide arguments to initiate therapy and may help to predict a child's final VF outcome.

## REFERENCES

1. Soiberman, U. *et al.* Idiopathic intracranial hypertension in children: visual outcome and risk of recurrence. *Childs. Nerv. Syst.* **27**, 1913–8 (2011).
2. Kosmorsky, G. S. Idiopathic Intracranial Hypertension : Pseudotumor Cerebri. *Headache Curr.* 389–393 (2014).
3. Dagi, L. R. *et al.* Using spectral-domain optical coherence tomography to detect optic neuropathy in patients with craniosynostosis. *J. Am. Assoc. Pediatr. Ophthalmol. Strabismus* **18**, 543–549 (2014).
4. Marzoli, S. B. *et al.* Quantitative analysis of optic nerve damage in idiopathic intracranial hypertension (IIH) at diagnosis. *Neurol. Sci.* **34 Suppl 1**, S143–5 (2013).
5. Kuper-Smith, M. J. OCT Sub-Study Committee for the NORDIC Idiopathic Intracranial Hypertension Study Group. Baseline OCT Measurements in the Idiopathic Intracranial Hypertension Treatment Trial, Part I: Quality Control, Comparisons, and Variability. *Invest. Ophthalmol. Vis. Sci.* **55**, 8180–8188 (2014).
6. Chern, J. J., Tubbs, R. S., Gordon, A. S., Donithorne, K. J. & Oakes, W. J. Management of pediatric patients with pseudotumor cerebri. *Childs. Nerv. Syst.* **28**, 575–8 (2012).
7. Jung, J. J., Baek, S.-H. & Kim, U. S. Analysis of the causes of optic disc swelling. *Korean J. Ophthalmol.* **25**, 33–6 (2011).
8. Friedman, D. I. Papilledema and Idiopathic Intracranial Hypertension. 857–876 (2014).
9. Lessell S. Pediatric pseudotumor cerebri (idiopathic intracranial hypertension). *Surv Ophthalmol.* **37**, 155–66 (1992).
10. Ko, M. W. & Liu, G. T. Pediatric idiopathic intracranial hypertension (pseudotumor cerebri). *Horm. Res. paediatrics* **74**, 381–9 (2010).
11. Cinciripini, G. S., Donahue, S. & Borchert, M. S. Idiopathic intracranial hypertension in prepubertal pediatric patients: characteristics, treatment, and outcome. *Am. J. Ophthalmol.* **127**, 178–82 (1999).
12. Salman, M. S., Kirkham, F. J. & Macgregor, D. L. Idiopathic 'Benign' Intracranial Hypertension: Case Series and Review. *J Child Neurol.* **16**, 465–470 (2001).
13. Kesler, a. & Fattal-Valevski, a. Idiopathic Intracranial Hypertension in the Pediatric Population. *J. Child Neurol.* **17**, 745–748 (2002).
14. Phillips, P. H., Repka, M. X. & Lambert, S. R. Pseudotumor cerebri in children. *J. AAPOS* **2**, 33–8 (1998).
15. Ravid, S., Shahar, E., Schif, A. & Yehudian, S. Visual Outcome and Recurrence Rate in Children With Idiopathic Intracranial Hypertension. *J. Child Neurol.* 5–9 (2015).
16. Wolf, A. & Hutcheson, K. a. Advances in evaluation and management of pediatric idiopathic intracranial hypertension. *Curr. Opin. Ophthalmol.* **19**, 391–7 (2008).
17. Wakerley, B. R., Tan, M. H. & Ting, E. Y. Idiopathic intracranial hypertension. *Cephalalgia* **35**, 248–61 (2015).
18. Sergott, R. C. Headaches associated with papilledema. *Curr. Pain Headache Rep.* **16**, 354–8 (2012).
19. Wall, M. The importance of visual field testing in idiopathic intracranial hypertension. *Continuum (N. Y.)* **20**, 1067–74 (2014).
20. Keltner, J. L., Johnson, C. a, Cello, K. E. & Wall, M. Baseline Visual Field Findings in the Idiopathic Intracranial Hypertension Treatment Trial (IIHTT). *Invest. Ophthalmol. Vis. Sci.* **55**, 3200–7 (2014).
21. Weisberg, L. A. Benign Intracranial Hypertension. *Med. (Baltimore)* **54**, 197–207 (1975).
22. Lysak, W. R. & Svien, H. J. Long-term follow-up on patients with diagnosis of pseudotumor cerebri. *J. Neurosurg.* **25**, 284–287 (1966).
23. Bruce, B. B., Biousse, V. & Newman, N. J. Update on idiopathic intracranial hypertension. *Am. J. Ophthalmol.* **152**, 163–169 (2011).

## Visual field findings in increased intracranial pressure

24. Rangwala, L. M. & Liu, G. T. Pediatric idiopathic intracranial hypertension. *Surv. Ophthalmol.* **52**, 597–617 (2007).
25. Wall, M. *et al.* The Idiopathic Intracranial Hypertension Treatment Trial. *JAMA Neurol.* **1091**, 1–9 (2014).
26. Thurtell, M. J. & Wall, M. Idiopathic intracranial hypertension (Pseudotumor Cerebri): Recognition, treatment, and ongoing management. *Curr. Treat. Options Neurol.* **15**, 1–12 (2013).
27. Rowe, F. J. Assessment of visual function in idiopathic intracranial hypertension. *Br. J. Neurosurg.* **25**, 45–54 (2011).
28. Digre, K. B. *et al.* A comparison of idiopathic intracranial hypertension with and without papilledema. *Headache* **49**, 185–193 (2009).
29. Rudolph, D. *et al.* Visual field constriction in children with shunt-treated hydrocephalus. *J. Neurosurg. Pediatr.* **6**, 481–5 (2010).
30. Andersson, S. *et al.* Vision in children with hydrocephalus. *Dev. Med. Child Neurol.* **48**, 836–41 (2006).
31. Yri, H. M., Wegener, M., Sander, B. & Jensen, R. Idiopathic intracranial hypertension is not benign: a long-term outcome study. *J. Neurol.* **259**, 886–94 (2012).
32. Standridge, S. M. Idiopathic intracranial hypertension in children: a review and algorithm. *Pediatr. Neurol.* **43**, 377–90 (2010).
33. Mukherjee, N. & Bhatti, M. T. Update on the surgical management of idiopathic intracranial hypertension. *Curr. Neurol. Neurosci. Rep.* **14**, 438 (2014).
34. Jirásková, N. & Rozsival, P. Idiopathic intracranial hypertension in pediatric patients. *Clin. Ophthalmol.* **2**, 723–726 (2008).
35. Tibussek, D. *et al.* Clinical spectrum of the pseudotumor cerebri complex in children. *Childs. Nerv. Syst.* **26**, 313–21 (2010).
36. Koenraads, Y., Braun, K. P. J., van der Linden, D. C. P., Imhof, S. M. & Porro, G. L. Perimetry in Young and Neurologically Impaired Children: The Behavioral Visual Field (BEFIE) Screening Test Revisited. *JAMA Ophthalmol.* **133**, 319–25 (2015).
37. Smith, J. L. Whence Pseudotumor Cerebri? *J. Clin. Neuro-ophthalmol.* **5**, 55–56 (1985).
38. Greve, E. L., Dannheim, F. & Bakker, D. The Peritest, a new automatic and semi-automatic perimeter. *Int. Ophthalmol.* **5**, 201–14 (1982).
39. World Health Organization. *International Statistical Classification of Diseases and Related Health Problems 10th Revision. ICD-10 Version.* (2010). at <<http://apps.who.int/classifications/icd10/browse/2010/en>>
40. Frisén, L. Swelling of the optic nerve head: a staging scheme. *J. Neurol. Neurosurg. Psychiatry* **45**, 13–18 (1982).
41. Olson, J. Walsh and Hoyt's Clinical Neuro-Ophthalmology. *Br. J. Ophthalmol.* **83**, 1096 (1999).
42. IBM Corp. Released 2012. IBM SPSS Statistics for Windows, Version 21.0. Armonk, NY: IBM Corp.
43. Gospe, S. M., Bhatti, M. T. & El-Dairi, M. a. Anatomic and visual function outcomes in paediatric idiopathic intracranial hypertension. *Br. J. Ophthalmol.* [Epub ahead of print] (2015).
44. Pollak, L., Zohar, E., Glovinsky, Y. & Huna-Baron, R. Reevaluation of presentation and course of idiopathic intracranial hypertension--a large cohort comprehensive study. *Acta Neurol. Scand.* **127**, 406–12 (2013).
45. Baker, R. S., Baumann, R. J. & Buncic, J. R. Idiopathic intracranial hypertension (pseudotumor cerebri) in pediatric patients. *Pediatr. Neurol.* **5**, 5–11 (1989).
46. Babikian P, Corbett J, B. W. Idiopathic intracranial hypertension in children: the Iowa experience. *J Child Neurol.* **9**, 144– (1994).
47. Rowe, F. J. & Sarkies, N. J. Assessment of visual function in idiopathic intracranial hypertension: a prospective study. *Eye (Lond)* **12 (Pt 1)**, 111–8 (1998).

48. Newman, W. D., Hollman, a S., Dutton, G. N. & Carachi, R. Measurement of optic nerve sheath diameter by ultrasound: a means of detecting acute raised intracranial pressure in hydrocephalus. *Br. J. Ophthalmol.* **86**, 1109–13 (2002).



# 5

## **Visual outcome in Sturge-Weber syndrome: a systematic review and Dutch multicenter cohort**

Yvonne Koenraads  
Michelle B. van Egmond-Ebbeling  
Joke H. de Boer  
Saskia M. Imhof  
Kees P.J. Braun  
Giorgio L. Porro

*on behalf of the SWS study group:*

*Nomdo M. Jansonius  
Carlien A. Bennebroek  
Nicoline E. Schalijs-Delfos  
Chris C.M. Nielsen  
Mirjan van Dijk  
Wouter B.H.J. Vehmeijer*

*Accepted for publication in Acta Ophthalmologica*

## ABSTRACT

### Purpose

Visual functions in Sturge-Weber syndrome (SWS) may be impaired by glaucoma, diffuse choroidal hemangioma (DCH) or leptomeningeal angioma. Aim of this study was to gain better insight in the visual deficits of SWS patients.

### Methods

A systematic literature search using Pubmed and Embase medical databases was performed to identify articles describing visual acuity (VA) and/or visual field (VF) findings in SWS patients. In addition, a Dutch multicenter cohort with 33 SWS patients was collected and the combined results of VA and VF findings are presented.

### Results

VA results of 25 studies and VF results of 12 studies were suitable for data-extraction. Description of the combination of both VA and VF findings was scarce. Homonymous hemianopia (HH) was present in 42% of SWS patients. Seventy per cent of eyes had a (near)normal vision, while VA of eyes with glaucoma or DCH was severely impaired in 28% and 67%, respectively. In the Dutch cohort only 18% (6/33) of patients had (near)normal findings of both visual parameters. In addition, half of the patients with glaucoma suffered from a combination of a HH and VA impairment.

### Conclusions

Although SWS patients are exposed to severe functional visual impairment due to the possible cumulative consequences of glaucoma, DCH and cerebral injury, description of the combination of both VA and VF results is scarce in the literature. Particularly the combination of visual impairment due to glaucoma or DCH, and HH might be invalidating.

## INTRODUCTION

The Sturge-Weber syndrome (SWS) is a rare congenital disorder with angiomatous vascular malformations in the meninges, dermis and eye, affecting one in 20,000-50,000 people.<sup>1,2</sup> In the literature, three types of SWS are described.<sup>3</sup> SWS type I, on which this study is mainly focused, includes a facial port-wine stain and leptomeningeal angioma with possible ocular abnormalities such as glaucoma. SWS type II comprises a facial port-wine stain (with possible glaucoma) without evident cerebral involvement, while SWS type III consists of an exclusive leptomeningeal angioma.

The most visible sign of SWS is the port-wine birthmark which typically affects the ophthalmic division of the trigeminal nerve.<sup>1</sup> The leptomeningeal angioma, mainly unilateral and located in the occipital or posterior parietal lobe, may initially be unnoticed.<sup>1,4,5</sup> However, during the first years of life, impaired venous outflow may lead to progressive ischemic cerebral damage, atrophy and calcification in the brain region below the angioma.<sup>1,6</sup> These cerebral manifestations, which can be confirmed by neuroimaging (CT or MRI), regularly cause neurological problems such as seizures (72-97%), motor deficits, cognitive decline and visual field (VF) defects.<sup>7,8</sup>

Ocular vascular abnormalities include hemangioma of the conjunctiva, episclera, iris (heterochromia), ciliary body, choroid and retina.<sup>2,9,10</sup> A diffuse choroidal hemangioma develops in approximately one-third of SWS patients and may cause visual loss from hyperopia, amblyopia, secondary exudative retinal detachment or cystoid macular edema.<sup>11-13</sup> The most common eye disease in SWS is uni- or bilateral glaucoma which occurs in 30-70% of patients.<sup>2,14-16</sup> It may present around birth (60%) secondary to trabecular dysgenesis inducing buphthalmos, or develop in child- or adulthood (40%) due to increased episcleral venous pressure, and may result in VF and visual acuity (VA) impairment.<sup>2,5,14,16-19</sup>

Most studies on SWS are reported from a strictly ophthalmological perspective, focusing on diffuse choroidal hemangioma (DCH) or glaucoma and mostly reporting only data of VA outcomes, or a neurological perspective, focusing on homonymous VF defects secondary to ce-

rebral involvement. However, accurate description of the consequences of SWS-related combined ocular and neurological disorders, such as glaucoma and leptomeningeal angioma, for VF and VA is lacking in the current literature.

Collection of information on visual functioning of SWS patients may encounter difficulties, since patients are often young and sometimes mentally retarded. Especially examination of the VFs, which may be impaired both in case of glaucoma and occipital leptomeningeal angioma, is very challenging in this patient population and therefore may have to be omitted.

The aim of the present study is to gain better insight in the visual prognosis of SWS patients, first by providing a systematic review of visual outcome, as previously described in the literature, and second by presenting a Dutch multicenter cohort with focus on the combination of VA and VF findings.

**eTable 1. Syntax for search on visual outcome in Sturge-Weber syndrome in medical databases**

Search terms used in Pubmed and Embase	
<b>Domain</b>	(((((("sturge weber"[Title/Abstract]) OR "encephalotrigeminal angiomatosis"[Title/Abstract]) OR "encephalo trigeminal angiomatosis"[Title/Abstract]) OR "sturge kalischer weber"[Title/Abstract]) OR "meningo oculo facial"[Title/Abstract])) AND
<b>Outcome</b>	(((((((((((((((((((((((((((((((((Visual) OR Ophthalmology) OR Ophthalmologic) OR Ophthalmologics) OR Ophthalmological) OR Ophthalmologically) OR Ophthalmologist) OR Ophthalmologists) OR Ophthalmic) OR Ophthalmics) OR Ophthalmical) OR Ophthalmically) OR Visually) OR Eye) OR Eyes) OR Vision) OR Ocular) OR Optic) OR Optics) OR Optical) OR Optically) OR Perimetry) OR Perimetric) OR Perimetrics) OR Perimetrical) OR Perimetrically) OR Octopus) OR Goldmann) OR Humphrey) OR Rodenstock)



## METHODS

### **Systematic review of the literature**

#### *Search strategy and selection*

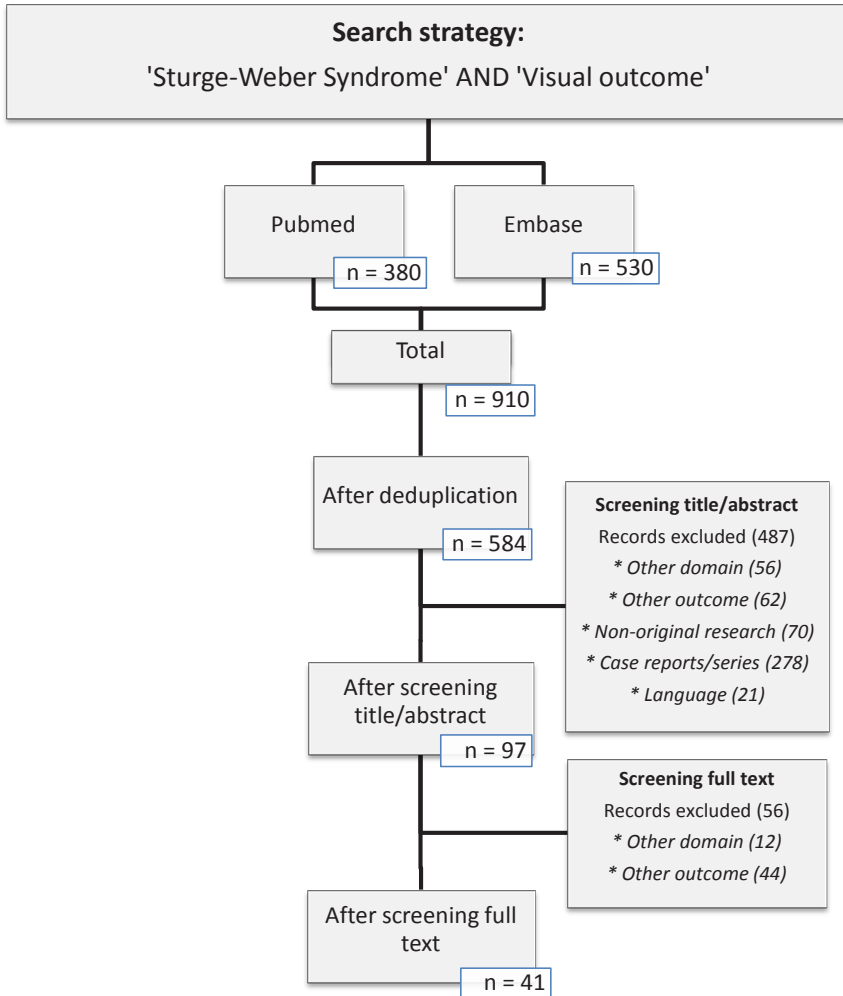
On June 19<sup>th</sup> 2015, a structured literature search was performed using Pubmed and Embase medical databases. A syntax was designed to search for visual outcome in SWS by combining a series of synonyms (see eTable 1). After eliminating duplicates, titles and abstracts were independently screened by two authors (ME and YK) on predefined inclusion and exclusion criteria (see Figure 1). All articles that included SWS patients and might describe visual function were included. Exclusion criteria were (1) population without SWS patients, (2) description of visual outcome highly improbable, (3) non-original research (reviews) or abstracts of a conference, (4) case reports or series of less than 4 patients or (5) language other than English, Dutch, German, French, Spanish, Portuguese, Italian or Russian.

Subsequently, of all selected articles, full text was screened on the presence of a description of VA or VF examination in patients with SWS. Doubtful cases were discussed until consensus was reached by the two authors.

#### *Quality assessment and data extraction*

The selected articles were independently appraised by the two authors on different aspects of validity for the purpose of this study (see eTable 2). Regarding the domain, neuroimaging confirmation of the diagnosis (type I or III SWS) and way of selection of patients with SWS was assessed. Regarding the VA or VF outcome, description of the method of examination, description of the outcome itself and percentage of missing data were assessed. Discrepancies were resolved by consensus discussion. Studies in which (1) the validity of the outcome was assessed as 'poor' (red) on all three items, (2) only a mean score for the outcome was given, or (3) less than four VF or VA results were reported, were not used for the data-extraction. VA results of all reported eyes were presented of the studies that described general SWS populations. In addition, VA results of eyes affected with glaucoma or a DCH were described of all

Figure 1. Flowchart of search strategy



studies that also – or solely – reported results of children with these disorders separately. In the presentation of the VF results, studies that used standard perimetry and confrontational methods were separated because standard perimetry is more sensitive for glaucomatous defects than confrontational methods.

### **Dutch multicenter cohort**

#### *Subjects*

Summer 2015, we approached all ophthalmologists of the Dutch Pediatric Ophthalmology Society to cooperate in this study to collect data from as many as possible Dutch SWS patients. All available neuroimaging-confirmed SWS patients who visited a society member Dutch ophthalmologist were included.

The study was approved by the institutional ethical committee of the University Medical Center Utrecht, which concluded that the Dutch Medical Research Involving Human Subjects Act did not apply and written informed consent was not needed, since the study was confined to a retrospective, anonymized data collection.

#### *Data collection*

All patient files were retrospectively analyzed. Demographic and clinical characteristics collected consisted of gender, presence of a facial port-wine stain, location of leptomeningeal vascular malformation, age of last ophthalmological examination, final VA, findings on final VF, presence of ophthalmological morbidity and treatment, presence of epilepsy and its treatment, developmental delay, hemiparesis or other relevant comorbidity.

The use of a formal definition of glaucoma, based on optic disc appearance and glaucomatous VF defects, would result in a high percentage of underdiagnosis or misclassification in this group of patients. Therefore, we categorized patients as having glaucoma if they had, either medical or surgical, glaucoma treatment. VA measurements were performed with the Kays Picture or Snellen Chart, depending on the age and cooperation of the child. Best corrected VA was transformed to LogMAR (Logarithm of the Minimum Angle of Resolution) and cate-

**Table 2. Critical appraisal of articles on visual outcome in Sturge-Weber syndrome**

Article	Cases	Eyes	Timepoint age	Age (range) yrs mean, median	Population	Selection of patients	SWS		Outcome		
							Diagnosis	Selection	Method	Description	Missing data in %
Jeong'15	10		o	4, 4 (2-7)	S <sup>E10</sup>	Unilateral SWS, occipital leptomeningeal angioma in the occipital lobe			VF	0	
Kubicka-T'15	5	5	o	20 (10-40)	D	Ruthenium-106 plaque radiotherapy treatment			VA	0	
Lance'14	12		t	11 (5-19)	S <sup>E12</sup>	Stimulant medication (prescribed for e.g. ADHD)			VF	?	
Jagtap'13	30		d	11 (0-43)	S <sup>E30</sup> G <sup>9</sup>	-			VF	67	
Lance'13	93		t	1 (0-12)	S <sup>E1+93</sup>	Low-dose aspirin (3-5 mg/kg/d) therapy			VF	62	
Parsa'13	14		o	15, 20 (1-45)	S <sup>G5E9</sup>	-			VF	0	
Conway'12	16	32	o	23	S <sup>G7E14</sup>	-			VA	0	
Khatri'12		16	d	0 (0-6)	G	-			VA	0	
Saltzman'12	4	6	o	8	G	Pseudo 360-degree primary trabeculectomy			VA	0	
Chan'10	6	6	o	12, 13 (8-15)	D	Light-field proton beam irradiation			VA	0	
Zaber'10	4		o	9, 9 (8-9)	S	Children with different characteristics			VF	0	
Kossoff'09	77		d	5 (1-43)	E	At least one witnessed seizure			VF	0	
Sharan'09	41		d	(3-26)	S <sup>G24</sup> G <sup>24</sup>	-			VA	?	
Horgan'08	10	10	o	8, 7 (1-15)	D	-			VA	0	
Pascual-Castr'08	55		d	2 (0-12)	S	Occipital leptomeningeal angioma			VA	?	
Amini'07	7	9	o	12, 11 (8-20)	G	Primary single-plate Molteno tube implantation			VA	0	
Barista'07	17		o	6, 6 (2-10)	E	Unilateral SWS and posterior cerebral involvement			VF	0	
Hafstad'07	14		o	10, 6 (0-38)	S <sup>G6E12</sup>	Unilateral SWS			VF	0	
Hocht'06	8	8	t	19	D	Symptomatic DCH, photon(7)/proton(1) irradiation			VA	13	
Kelley'05	18		o	8, 5 (1-38)	S <sup>G7E16</sup>	Unilateral SWS			VF	0	
Rumen'02	6	7	o	15 (6-23)	D	Irradiation for exsudative retinal detachment			VA	0	
Arziman'00	20		o	21, 15 (1-45)	E	Epilepsy surgery			VF	?	
Budenz'00	9	10	o	9, 9 (1-16)	G	Two-staged implantation of a Baerveldt implant			VA	10	
Celebi'00	7	7	o	28, 22 (18-52)	S	-			VA	0	
									VF	86	

Van Emelen'00	19	0	13 (2-33)	S	-				VF	?
				G					VA	50
Awad'99	18	0	2 (0-20)	S	-				VA	94
				S					VF	94
Irkeç'99	6	7	0 10, 12 (2-17)	G	Glaucoma surgery				VA	0
Mandal'99	9	10	0 4, 3 (1-11)	G	Early-onset + prim. trabeculectomy-trabeculectomy				VA	60
Taylor'99	30	d	1, 1 (0-6)	G	-				VA	47
				G					VF	100
Olsen'98	14	16	0 6 (1-19)	G	Infantile glaucoma (<4yrs)				VA	13
Zografos'98	5	6	0 20 (10-33)	D	Planned for treatment with proton beam irradiation				VA	0
Schilling'97	12	15	0 24 (10-44)	D	Low dose ocular irradiation for retinal detachment				VA	0
Agarwal'93	16	19	0 5 (1-15)	G	Combined trabeculectomy-trabeculectomy treatment				VA	32
Sullivan'92	36	51	-	G	-				VA	14
Alt'90	6	7	0 26, 34 (9-43)	G	Treated with trabeculectomy				VA	0
Wagner'88	6	12	0 8, 6 (3-15)	G	Trabeculectomy combined with cyclotherapy				VA	17
Rosenb.'82	6	6	0 (1-13)	S	-				VF	67
Uram'82	35	0	(1-48)	S E <sup>34</sup>	-				VF	29
Feng'80	22	d	(1-33)	S	-				VF	?
Witschel'76	17	17	d 8 (0-52)	D	-				VA	6
Stokes'57	7	14	d 28, 28 (0-63)	S	-				VA	21
				S					VF	71
				G <sup>4</sup>					VA	25

**Timepoint age:** o, at outcome determination; t, at start therapy; d, at diagnosis

**Method:**

Method described

\*Method not described, but derivable from outcome

Method not described or confrontational assessment during physical examination

**Description:**

Detailed description of the VA or VF outcome

\*Ordinal categorization of the outcome in 3 categories

Dichotomous description of the outcome

**Missings:**

No missing data OR less than 15% missing data

\*Not sure if everyone was tested OR 15-70% missing data

Amount of missing data unknown OR 70-100% missing data

**Diagnose:**

SWS with neuroimaging confirmation

\*SWS 'confirmed', but unclear how or there was neuroimaging confirmation in most cases

SWS, criteria not described

**Selection:**

All cases in a certain period and/or center

The authors made a selection or it was not described

## Chapter 5

gorized as (near)normal ( $\leq 0.30$  LogMAR), moderately impaired ( $> 0.30 - < 1.00$  LogMAR) or severely impaired ( $\geq 1.0$  LogMAR).

VF measurements were performed by means of confrontational measurement during neurological examination, behavioral confrontational peripheral VF testing with Stycar balls or the BEFIE test<sup>20</sup>, automatic static VF testing with Frequency Doubling Technology (FDT) perimetry, manual kinetic VF testing on the Goldmann perimeter, (semi-)automatic static VF testing on the Rodenstock Peritest or automatic static VF testing on the Humphrey Field Analyzer. VF defects were categorized as normal, homonymous quadrantanopia or hemianopia, glaucomatous defects, concentric defect, sensitivity decrease or a combination of defects.

## RESULTS

### Systematic review of the literature

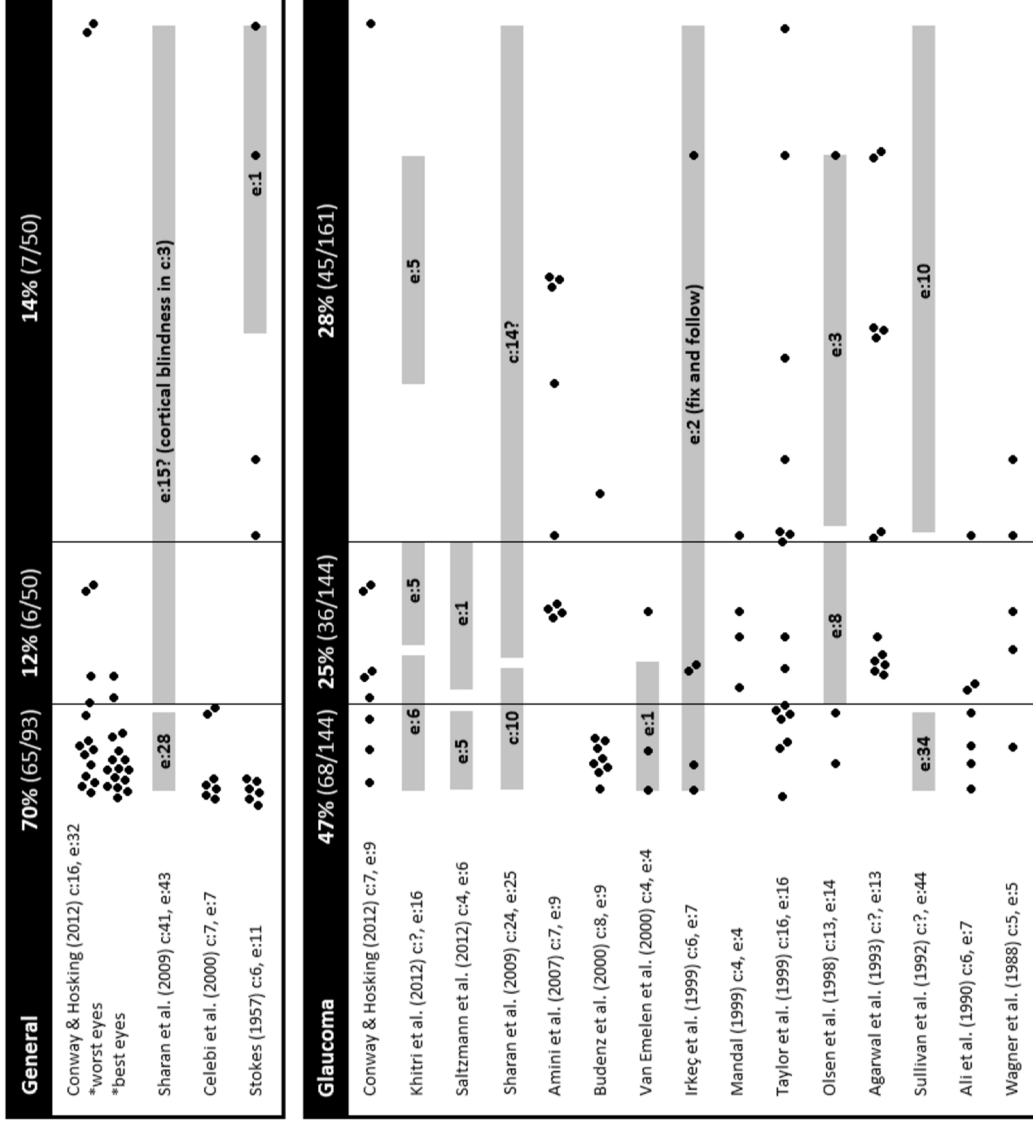
In total, 41 articles were retrieved that described VA (n=20)<sup>2,9,11-13,17,19,21-33</sup>, VF (n=12)<sup>7,8,34-43</sup> or both (n=9)<sup>4,5,44-50</sup> assessments in patients with SWS (see eTable 2). Articles reported general SWS populations (n=18)<sup>4,5,8,21,34-36,38,39,41-47,49,50</sup> or only selected cohorts of patients who suffered from a specific SWS-related disorder, such as glaucoma (n=12)<sup>2,9,17,19,22,23,25,28,29,32,33,48</sup> epilepsy (n=3)<sup>7,37,40</sup> or a diffuse choroidal hemangioma (DCH) (n=8).<sup>11-13,24,26,27,30,31</sup> In addition, from 12 of the 'general SWS' articles, outcomes of patients with glaucoma (n=3),<sup>45,46,49</sup> epilepsy (n=4)<sup>4,34,35,42</sup> or from both subcategories (n=5)<sup>21,36,38,39,44</sup> could be retrieved separately.

Many studies, particularly those on SWS-related glaucoma or DCH, included patients who underwent a specific treatment or diagnostic examination. Ten articles mentioned confirmation of the SWS diagnosis by means of neuroimaging (see eTable 2). Methods for VA (n=10) or VF (n=3) assessment were properly described in 13 articles and were derivable from the VA (n=16) or VF (n=2) result in 16 articles. The quality of the description of VA and VF results itself and the percentage of missing data in the outcome varied strongly between studies.

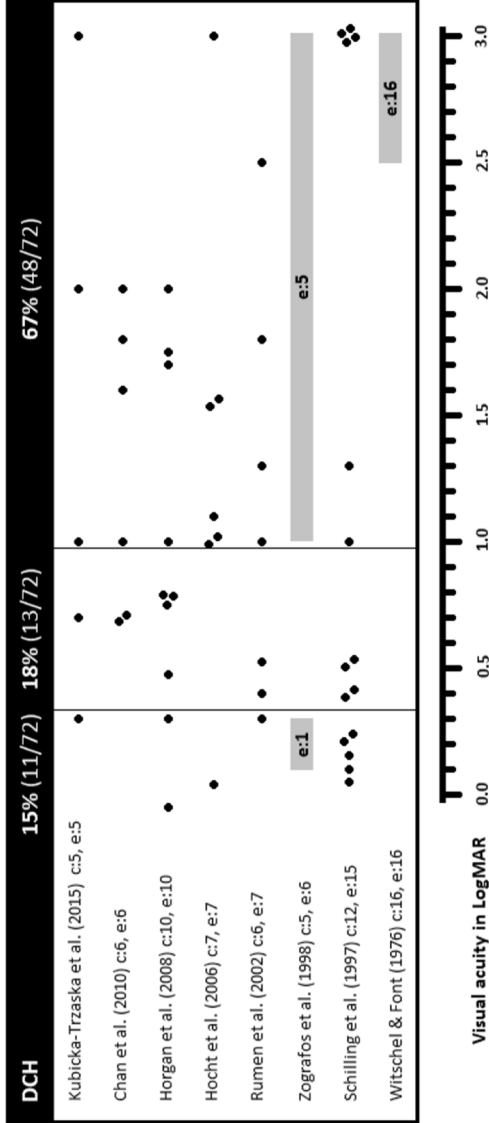
Results of VA (n=3)<sup>4,5,44</sup> or VF (n=3)<sup>5,40,48</sup> measurements of five studies were not used for data-extraction since validity of the visual outcome for the purpose of the systematic review – i.e. method, description, missing data – were all assessed as 'poor' (red). The VF results of one article could not be further evaluated since solely an overall mean score was given.<sup>7</sup> Five studies were withdrawn from data-extraction since from less than four patients the VA results (n=1)<sup>47</sup> or VF results (n=4)<sup>47,41,49,43,50</sup> were reported. Therefore, VA results of 25 studies<sup>2,9,11-13,17,19,21-33,45,46,48-50</sup> (see Figure 2) and VF results of 12 studies<sup>4,8,34-39,42,44-46</sup> (see Table 1) were suitable for data-extraction.

Of the four articles that described VA results from general SWS populations,<sup>21,45,49,50</sup> the pooled percentage of all reported eyes with a (near)normal VA was 70% (see Figure 2). The presence of moderate and severely impaired VA could be pooled from three articles and were found to occur in 12% and 14% of eyes, respectively.<sup>49,50,21</sup> VA of eyes affected by glaucoma or DCH was severely impaired in 28% and 67%, respectively.

Figure 2. Visual acuity outcome of studies on Sturge-Weber syndrome







Visual acuity (VA) results of 25 studies are separately presented for general SWS populations, patients with glaucoma and patients with a diffuse choroidal haemangioma (DCH). Of the studies that described general SWS populations, VA results of all reported eyes were presented. VA results of patients with glaucoma or DCH was described of affected eyes of all studies that also – or solely – reported results of children with these disorders. The black dots represent the individual VA outcomes of separate eyes. The gray beams represent ranges in which the VA outcomes of a certain number of eyes (e) are situated. Cases are abbreviate as 'c': VA results are separated by vertical lines in three different categories of VA impairment, i.e. (near) normal, moderately impaired and severely impaired VA. Pooled percentages of eyes in each category of VA impairment are given in the black beams.

Among the articles that report VF outcome, only three performed standard conventional perimetry in (a selection of) the included patients and demonstrated defects that are considered typical of glaucoma in 21% of patients diagnosed with glaucoma (see Table 1).<sup>44,36,45</sup> The other studies tested the VF only using confrontational measurements and reported homonymous defects only. A homonymous hemianopia (HH) was found in 42% of patients when data of all 12 studies were pooled.

**Table 1. Visual field outcome of studies on Sturge-Weber syndrome**

Article	Cases (glaucoma)	Homonymous hemianopia (complete) <sup>a</sup>	Glaucomatous defect		
			Arcuate defect	Nasal field loss	Enlarged blind spot
<b>Standard perimetry</b>					
Jagtap et al. (2013) <sup>b</sup>	10 (9)	2	< ----- 3 ----- >		
Parsa (2013) <sup>b</sup>	14 (5)	7		1	
Sharan et al. (2009) <sup>c</sup>	14 (14)	5	1		1
<b>Pooled (glaucoma patients)</b>	<b>38 (28)</b>			<b>21% (6/28)</b>	
<b>Confrontational</b>					
Jeong et al. (2015)	10	7			
Lance et al. (2014)	12	6			
Lance et al. (2013)	35	10 (3)			
Zabel et al. (2010)	4 (2)	2 (1)			
Batista et al. (2007) <sup>d</sup>	17 (6)	12 <sup>e</sup>			
Hatfield et al. (2007)	14 (4)	9 (7)			
Kelley et al. (2005)	18 (7)	8			
Van Emelen et al. (2000) <sup>f</sup>	19 (8)	1			
Uram & Zubillaga (1982) <sup>f</sup>	25 (11)	11			
<b>Pooled (all patients)</b>	<b>192</b>	<b>42% (80/192)</b>			

<sup>a</sup>, number of complete hemianopias are given in brackets for all articles that made distinction between incomplete and complete homonymous hemianopias; <sup>b</sup>, not sure if all patients were tested with standard perimetry; <sup>c</sup>, all patients tested with Goldmann perimetry; <sup>d</sup>, patients were tested with a simple behavioral kinetic method; <sup>e</sup>, in 4 patients the presence of a VF defect was uncertain; <sup>f</sup>, uncertain whether patients were tested confrontatively or with standard perimetry.

From five articles, the relation between the location of the leptomeningeal angioma and the presence of a VF defect could be retrieved. In total, 16 of 47 (34%) patients reported in these studies had a normal VF despite occipital involvement.<sup>4,8,36-38</sup>

A history of epilepsy surgery was reported in 3-27% of patients in five (other) studies.<sup>2,44,48,45,42</sup> The authors of the study by Jagtap et al.<sup>44</sup> mentioned that the VF defects in patients after epilepsy surgery were pre-existent in the two patients that could be tested. However, the study by Arzimanoglou et al.<sup>40</sup>, describing a SWS cohort in which solely patients who underwent epilepsy surgery were included, reported that 3 of 14 patients who underwent a resection of the angiomatous cortex acquired a VF defect. Of note, the occipital angiomatous lesion in one patient was not removed to avoid a VF defect.

Only few authors described the combination of VA and VF impairments that may occur in SWS. Jeong et al.<sup>4</sup> reported that one child (age 3 yrs) had a homonymous left field deficit in combination with impaired right eye VA due to glaucoma. Awad et al.<sup>47</sup> and Stokes et al.<sup>49</sup> reported in total three patients with glaucomatous arcuate scotomas, of which two had a normal VA and one an unilaterally impaired VA of 1.3 LogMAR. Jagtap et al.<sup>44</sup> mentioned that five patients suffered from impairment of both VA and VF. Batista et al.<sup>37</sup> correlated homonymous field defects to the visual cortex glucose metabolism in a neuroradiological study and reported six patients affected by glaucoma without a severely impaired VA.

### **Dutch multicenter cohort**

In total, data from 33 SWS patients with neuroimaging confirmation (type I or III) could be collected from our (n=19) and other centers (n=14) in the Netherlands. Baseline characteristics of patients are listed in Table 2.

Visual outcome results including both VA and VF are presented in Table 3. VA was (near)normal in 72%, moderately impaired in 20% and severely impaired in 8% of the 50 eyes that underwent a VA assessment. VA was moderately or severely impaired in 44% (7/16) and 19% (3/16) of glaucomatous eyes that were tested, and in 50% (4/8) and 25% (2/8) of eyes with a DCH, respectively. A retinal detachment occurred in 38% (3/8) of the eyes in which a DCH was re-

**Table 2. Baseline characteristics**

	<b>total (n)</b>	<b>n (%) or median [range]</b>
<b>Gender, male</b>	33	<b>16 (48)</b>
<b>Center</b>	33	
-Utrecht		19 (58)
-Groningen		7 (21)
-Leiden		3 (9)
-Amsterdam		3 (9)
-Nijmegen		1 (3)
<b>Age last FU, yrs</b>	33	<b>9 [3-26]</b>
<b>Facial port-wine stain</b>	32	<b>26 (81)</b>
-unilateral		21 (81)
-bilateral		5 (19)
<b>DCH</b>	30	<b>6 (20)</b>
-unilateral		4 (67)
-bilateral		2 (33)
<b>Glaucoma</b>	29	<b>16 (55)</b>
-unilateral		12 (75)
-bilateral		4 (25)
<b>Leptomeningeal angioma</b>	33	<b>33 (100)</b>
-bilateral		3 (9)
-left		12 (36)
-right		18 (55)
<b>Number of lobes affected</b>	30	<b>2 [1-4]</b>
-frontal		14 (47)
-temporal		14 (47)
-parietal		17 (57)
-occipital		22 (73)
<b>Epilepsy</b>	32	<b>30 (94)</b>
<b>Neurosurgery</b>	30	<b>11 (37)</b>
-hemispherectomy		7 (64)
-focal resection		4 (36)
<b>Developmental delay</b>	29	<b>21 (72)</b>
<b>Hemiparesis</b>	30	<b>16 (53)</b>

total (n), number of patients of whom data was available; FU, follow-up; DCH, diffuse choroidal hemangioma.

ported. Of the 15 patients who underwent one or multiple surgical interventions for glaucoma, none had an intraoperative or postoperative suprachoroidal hemorrhage. VF examination was performed with the Humphrey Field Analyzer in 17% (5/30), the Rodenstock Peritest in 23% (7/30), the Goldmann perimeter in 7% (2/30), FDT in 3% (1/30), the BEFIE test in 33% (10/30)<sup>20</sup>, the Stycar balls in 3% (1/30) and confrontational methods during neurological examination in 13% (4/30) of patients. In three patients VF findings were unknown.

Possible glaucomatous VF defects [arcuate scotoma on Peritest (n=1), few inferior defects on FDT (n=1), superior constriction on Goldmann (n=1), VF defect exceeding the vertical meridian of the HH on Humphrey (n=1), partial defect of the nasal inferior quadrant on Humphrey (n=1) VF testing] were found in 5 of 14 (36%) patients with glaucoma who were tested with Humphrey (n=2),

**Table 3. Visual acuity and visual field outcome of patients with Sturge-Weber syndrome**

		Best eye			
		≥0.3	<1.0 - >0.3	≤1.0	no VA available
Worst eye	≥0.3	<p>39% (13/33)</p>			
	<1.0 - >0.3	<p>18% (6/33)</p>	<p>3% (1/33)</p>		
	≤1.0	<p>9% (3/33)</p>	<p>3% (1/33)</p>		
	no VA available	<p>3% (1/33)</p>	<p>3% (1/33)</p>		<p>21% (7/33)</p>

VA, visual acuity in LogMAR; VF, visual field; ○, normal VF; ◡, few VF defects; ⊙, arcuate scotoma; ◐, superior constriction; ◑, unilateral inferior sensitivity decrease; ◒, homonymous quadrantanopia; ◓, homonymous hemianopia (HH); ◔, HH and unilateral VF defect exceeding the vertical meridian; ◕, HH and unilateral partial defect of the nasal inferior quadrant; ◖, HH and unilateral concentric restriction; ◗, bilateral concentric VF; ◘, no VF assessment; DCH, diffuse choroidal haemangioma; blue, glaucoma patient; red, patient with DCH; purple, patient with glaucoma and DCH.

## Chapter 5

Peritest (n=2), Goldmann (n=2), FDT (n=1), BEFIE (n=3), Stycar (n=1) or confrontational (n=3) VF examination. However, the latter three defects might also have been a result of the DCH present in these eyes, while the superior constriction also could be explained by the ptosis on that side. In addition, in one of the other three patients with DCH (without glaucoma), an inferior sensitivity decrease was found on Humphrey VF testing.

A HH was present in 57% (17/30) and quadrantanopia in 3% (1/30) of patients. These 18 patients with homonymous VF defects underwent hemispherectomy (n=7) or suffered from an occipital involvement of the leptomeningeal angioma (n=10) or an occipital cyst (n=1). However, 38% (8/21) of all patients with occipital involvement who underwent VF examination did not show any homonymous defect. In six of the seven patients who underwent epilepsy surgery and performed a pre-operative VF assessment, the VF defect was already present before surgery. One patient had a normal VF before undergoing a hemispherectomy which caused a HH.

In two patients who suffered from hydrocephalus and were treated with a ventriculo-peritoneal shunt, no VF defects other than a HH were found. These children, however, underwent BEFIE and confrontational VF testing only, which are not sensitive enough for the detection of VF defects resulting from elevated intracranial pressure.

Of the seven patients who used the antiepileptic drug Vigabatrin, one had a bilateral concentric defect on BEFIE VF testing. Finally, an unilateral concentric restriction on Goldmann VF testing was found in a patient with DCH and amblyopia in that eye.

In total, half (12/24) of patients who underwent VA assessment of both the right and the left eye, had a bilaterally (near)normal VA. Half of these 12 patients had a homonymous VF defect. Patients with a bilaterally impaired or unilaterally severely impaired VA all had glaucoma in combination with a HH (if VF testing was performed). These six patients represent 46% (6/13) of the total number of glaucoma patients who underwent VA assessment.

One patient (8 yrs) with congenital glaucoma and a HH in whom VA assessment was not possible due to developmental delay, was dyskinetic, confined to a wheelchair and only able to communicate using an eye-controlled computer.

## DISCUSSION

This study describes the visual outcome of patients with SWS, who regularly suffer from a combination of vision impairing disorders such as glaucoma, DCH and cerebral injury. The study comprises first a systematic review, with the aim to extract data from articles describing visual acuity (VA) and/or visual field (VF) findings in SWS patients, and second an analysis of a Dutch multicenter cohort of SWS patients with collected and combined results of VA and VF findings. The systematic review of previous studies revealed that 1) a homonymous hemianopia (HH) was present in 42% of SWS patients, 2) 70% of eyes had a (near)normal vision, while 3) VA of eyes with glaucoma or DCH was severely impaired in 28% and 67%, respectively. In addition, when focusing on the combination of VA and VF findings in the Dutch cohort, we found that only 18% (6/33) of patients had (near)normal findings of both parameters, while half of the patients with glaucoma suffered from a combination of a HH and VA impairment. Description of the combination of VA and VF findings was scarce in the articles included in the systematic review. Ophthalmological studies mainly reported data on VA while neurological studies mainly reported data on VF as part of the neurological examination. In addition, visual parameters such as VA and VF were frequently not the primary outcome, which might partly explain the poor description of VA or VF methods and outcome in several studies. However, as demonstrated in the Dutch cohort, the combination of VA and VF impairment due to multifactorial pathology including glaucoma, DCH and a leptomenigeal angioma in the occipital cortex could be expected in SWS patients and may be very invalidating. In addition, because SWS children often suffer from multiple other disabilities, such as hemiplegia and intellectual disability, vision might be very important for them.

The pathophysiological mechanisms that underlie the SWS-related visual disorder determine its clinical approach, including potential treatment, with the aim to preserve visual function. Glaucoma is related to both the presence of a DCH and a port-wine stain on the eyelids and has a bimodal onset.<sup>2,5,48</sup> Bilateral and contralateral glaucoma with unilateral facial port-wine stain has been reported.<sup>3</sup> Congenital glaucoma may be treated with trabeculotomy or goniot-

omy, while older children are controlled with medications or filtering procedures.<sup>16,17,51</sup> Khitri et al.<sup>22</sup> found that VA outcome of glaucoma related to SWS was more favorable than that of other secondary glaucoma diagnoses. Regarding complications of glaucoma surgery, most of the articles included in the systematic review reported no intraoperative complications, while relevant intra- and postoperative complications such as suprachoroidal hemorrhages (0-13%)<sup>19,47</sup>, retinal detachment (10-12%)<sup>2,19,25</sup>, cataract (7-11%)<sup>47,25</sup>, or late endophthalmitis (2%)<sup>2</sup> were reported in only few studies. Although in the Dutch cohort no suprachoroidal hemorrhages occurred during surgery and this type of complications was rarely reported in the studies included in the systematic review, the risk of serious complications after glaucoma surgery in SWS patients, especially when a DCH is present, should not be ignored.

Symptoms from the DCH itself usually appear in the second decade of life.<sup>26</sup> DCH can be treated using laser photocoagulation, transpupillary thermotherapy, cryotherapy, radiation therapy or photodynamic therapy.<sup>12,31</sup> DCH particularly impairs VA, but may also provoke VF defects, metamorphopsia, floaters and progressive hypermetropia.<sup>26</sup>

A leptomeningeal angioma may cause a progressive VF defect due to a chronic impairment of cerebral bloodflow, leading to atrophy and calcifications, which is exacerbated by seizures.<sup>52</sup>

In patients with SWS, visual function is often difficult to determine, which may explain the high percentage of missing data in most of the studies included in the systematic review. Pascual-Castroviejo et al.<sup>5</sup>, Awad et al.<sup>47</sup>, Taylor et al.<sup>48</sup> and Rosenbaum et al.<sup>41</sup> explicitly state that reliable testing of particularly VF, but also VA, was difficult or impossible in many patients because of various problems, such as young ages, low VA, photophobia or cognitive impairment. This explains why seven different methods were used to assess the VF field in the Dutch cohort. The use of different VF examination methods in our cohort, but also in the studies included in the systematic review, makes it particularly difficult to demonstrate glaucomatous VF defects, since these are often more subtle and therefore require standard conventional perimetry to be detected.



Beside the high percentage of missing data and the different VF examination techniques used, two other important factors might have caused bias in the results of the systematic review. First, many patients, mainly included in the studies on glaucoma and DCH, were selected for a specific treatment, which might have resulted in a selection towards the more severe cases with possibly worse outcomes. Second, the type of SWS was frequently unknown due to the lack of information on neuroimaging and cerebral manifestations. This, and the uncertainty regarding the number of patients that underwent VF examination in several studies, probably resulted in an underestimation of the overall percentage of VF defects in the systematic review. The higher proportion of patients with homonymous VF defects in the Dutch cohort (60%), compared to the systematic review cohort (42%), may not only be explained by a more consistent use of VF examination, but also by a selection bias towards SWS patients affected more often by cerebral involvement with epilepsy, particularly those undergoing epilepsy surgery. This is explained by the fact that our center serves as a national tertiary referral center for children with refractory epilepsy and epilepsy surgery. Findings of VA examinations, however, were remarkably similar between the systematic review and the Dutch multicenter patient cohorts.

The studies included in the systematic review and the findings of the Dutch cohort reveal that VF defects are detected in two-third of patients with occipital involvement. This finding underlines the necessity of VF examination especially when an occipital leptomeningeal angioma is present. Moreover, in patients who are possible candidates for epilepsy surgery it is essential to evaluate the pre-existence of a VF defect. However, in most of the SWS patients who underwent epilepsy surgery a VF defect already existed before surgery. The functional consequences of a possible deterioration of VF following epilepsy surgery in SWS, especially when also glaucoma is present, should be carefully considered when counselling patients and caregivers who face surgery.

## CONCLUSIONS

Description of VA and VF abnormalities – and particularly the combination thereof – in SWS patients is scarce in the literature. SWS patients may be exposed to severe functional visual impairment due to the possible combination of glaucoma, DCH and cerebral injury. Although VA is generally preserved in SWS patients at presentation, both glaucoma and DCH are associated with worse VA. In addition, the combination with a VF defect, mainly a HH, which was found to be present in about half of SWS patients, might be invalidating. Visual outcome in SWS is heterogeneous, with some patients having a favorable outcome while others suffer from severe visual impairment by a combination of VA and VF deficits. Since the progressive character of glaucoma, DCH, and brain pathology may deteriorate visual function during lifetime, we recommend an adequate visual follow-up of these patients, with VF examinations as early as possible, at least with a confrontational method, alongside the regular ophthalmological follow-up of glaucoma and DCH. Furthermore, the presence or absence of homonymous defects should be re-examined when standard conventional perimetry becomes possible with ageing, or in case of suspicion of progressive cerebral injury based on neuro-imaging findings or symptoms.

### Acknowledgements

We thank Jan van Trier and dr. Nienke Soeters for acquiring all articles that were not retrievable via our institutional library.

## REFERENCES

1. Thomas-Sohl, K. a, Vaslow, D. F. & Maria, B. L. Sturge-Weber syndrome: A review. *Pediatr. Neurol.* **30**, 303–310 (2004).
2. Sullivan, T., Clarke, M. & Morin, J. The ocular manifestations of the Sturge-Weber syndrome. *J Pediatr Ophthalmol Strabismus* **29**, 349–356 (1992).
3. Hoyt, C. S. & Taylor, D. *Pediatric Ophthalmology and Strabismus. Fourth Edition.* (2013).
4. Jeong, J.-W., Tiwari, V. N., Shin, J., Chugani, H. T. & Juhász, C. Assessment of brain damage and plasticity in the visual system due to early occipital lesion: Comparison of FDG-PET with diffusion MRI tractography. *J. Magn. Reson. Imaging* **41**, 431–8 (2015).
5. Pascual-Castroviejo, I., Pascual-Pascual, S., Velazquez-Fragua, R. & Viaño, J. Sturge-Weber syndrome: study of 55 patients. *Can J Neurol Sci.* **35**, 301–7 (2008).
6. Martí-Bonmatí, L., Menor, F. & Mulas, F. The Sturge-Weber syndrome: correlation between the clinical status and radiological CT and MRI findings. *Childs Nerv Syst.* **9**, 107–109 (1993).
7. Kossoff, E. H., Ferenc, L. & Comi, A. M. An infantile-onset, severe, yet sporadic seizure pattern is common in Sturge-Weber syndrome. *Epilepsia* **50**, 2154–7 (2009).
8. Zabel, T. A. *et al.* Neuropsychological features and risk factors in children with Sturge-Weber syndrome: four case reports. *Clin. Neuropsychol.* **24**, 841–59 (2010).
9. Wagner, R. S., Caputo, A. R., Negro, R. G. del & Neigel, J. Trabeculectomy with Cyclocryotherapy for Infantile Glaucoma in the Sturge-Weber Syndrome. *Ann Ophthalmol* **20**, 289–295 (1988).
10. Basler, L. & Sowka, J. Sturge-Weber syndrome and glaucoma. *Optometry* **82**, 306–309 (2011).
11. Kubicka-Trząska, A., Karska-Basta, I., Oleksy, P. & Romanowska-Dixon, B. Management of diffuse choroidal hemangioma in Sturge-Weber syndrome with Ruthenium-106 plaque radiotherapy. *Graefes Arch Clin Exp Ophthalmol* **253**, 2015–9 (2015).
12. Chan, R. V. P. *et al.* Proton beam irradiation using a light-field technique for the treatment of choroidal hemangiomas. *Ophthalmologica.* **224**, 209–16 (2010).
13. Witschel, H. & Font, R. L. Hemangioma of the Choroid. A Clinicopathologic Study of 71 Cases and a review of the Literature. *Surv Ophthalmol.* **20**, 415–431 (1976).
14. Font, R. & Ferry, A. The phakomatoses. *Int Ophthalmol Clin.* **12**, 1–50 (1972).
15. Sujansky, E. & Conradi, S. Sturge-Weber syndrome: age of onset of seizures and glaucoma and the prognosis for affected children. *J Child Neurol.* **10**, 49–58 (1995).
16. Iwach, A., Hoskins, H., Hetherington, J. & Shaffer, R. Analysis of surgical and medical management of glaucoma in Sturge-Weber syndrome. *Ophthalmology.* **97**, 904–9 (1990).
17. Mandal, A. K. Primary combined Trabeculectomy – Trabeculectomy for Early-onset Glaucoma in Sturge-Weber Syndrome. *Ophthalmology* **106**, 1621–1627 (1999).
18. Phelps, C. D. The pathogenesis of glaucoma in Sturge-Weber syndrome. *Ophthalmology* **85**, 276–286 (1978).
19. Budenz, D. L., Sakamoto, D., Eliezer, R., Varma, R. & Heuer, D. K. Two-staged Baerveldt Glaucoma Implant for Childhood Glaucoma Associated with Sturge-Weber Syndrome. *Ophthalmology* **107**, 2105–2110 (2000).
20. Koenraads, Y., Braun, K. P. J., van der Linden, D. C. P., Imhof, S. M. & Porro, G. L. Perimetry in Young and Neurologically Impaired Children: The Behavioral Visual Field (BEFIE) Screening Test Revisited. *JAMA Ophthalmol.* **133**, 319–25 (2015).
21. Conway, M. & Hosking, S. L. Investigation of Ocular Hemodynamics in Sturge-Weber Syndrome. **89**, 922–928 (2012).

## Chapter 5

22. Khitri, M. R., Mills, M. D., Ying, G.-S., Davidson, S. L. & Quinn, G. E. Visual acuity outcomes in pediatric glaucomas. *J. AAPOS* **16**, 376–81 (2012).
23. Saltzmann, R. M., Reinecke, S., Lin, X., Dwight Cavanagh, H. & Whitson, J. T. Long-term outcomes of a pseudo 360-degree trabeculotomy ab externo technique for congenital glaucoma at children 's medical center. *Clin. Ophthalmol.* **6**, 689–698 (2012).
24. Horgan, N., O'Keefe, M., McLoone, E. & Lanigan, B. Fundus Fluorescein Angiographic Characterization of Diffuse Choroidal Hemangiomas. *J. Pediatr. Ophthalmol. Strabismus* **45**, 26–30 (2008).
25. Amini, H., Razeghinejad, M. R. & Esfandiarpour, B. Primary single-plate Molteno tube implantation for management of glaucoma in children with Sturge-Weber syndrome. *Int. Ophthalmol.* **27**, 345–50 (2007).
26. Höcht, S. *et al.* Proton or photon irradiation for hemangiomas of the choroid? A retrospective comparison. *Int. J. Radiat. Oncol. Biol. Phys.* **66**, 345–51 (2006).
27. Rumen, F. *et al.* [Sturge-Weber syndrome: medical management of choroidal hemangiomas]. *J. Fr. Ophthalmol.* **25**, 399–403 (2002).
28. Irkeç, M., Kiratli, H. & Bilgiç, S. Results of trabeculotomy and guarded filtration procedure for glaucoma associated with Sturge-Weber syndrome. *Eur. J. Ophthalmol.* **9**, 99–102 (1999).
29. Olsen, K. E., Huang, A. S. & Wright, M. M. The Efficacy of Goniotomy/Trabeculotomy in Early-Onset Glaucoma Associated With the Sturge-Weber Syndrome. *J. AAPOS* **2**, 365–8 (1998).
30. Zografos, L., Egger, E., Bercher, L., Chamot, L. & Munkel, G. Proton Beam Irradiation of Choroidal Hemangiomas. *Am. J. Ophthalmol.* **126**, 261–268 (1998).
31. Schilling, H. *et al.* Long term results after low dose ocular irradiation for choroidal haemangiomas. *Br J Ophthalmol* **81**, 267–273 (1997).
32. Agarwal, H. C., Sandramouli, S., Sihota, R. & Sood, N. N. Sturge-Weber syndrome: management of glaucoma with combined trabeculotomy-trabeculectomy. *Ophthalmic Surg.* **24**, 399–402 (1993).
33. Ali, M. A., Fahmy, I. A. & Spaeth, G. L. Trabeculectomy for glaucoma associated with Sturge-Weber syndrome. *Ophthalmic Surg.* **21**, 352–355 (1990).
34. Lance, E. I., Lanier, K. E., Zabel, T. A. & Comi, A. M. Stimulant use in patients with sturge-weber syndrome: safety and efficacy. *Pediatr. Neurol.* **51**, 675–80 (2014).
35. Lance, E. I., Sreenivasan, A. K., Zabel, T. A., Kossoff, E. H. & Comi, A. M. Aspirin use in Sturge-Weber syndrome: side effects and clinical outcomes. *J. Child Neurol.* **28**, 213–8 (2013).
36. Parsa, C. F. Focal venous hypertension as a pathophysiologic mechanism for tissue hypertony, port-wine stains, the Sturge-Weber syndrome, and related disorders. *Trans Am Ophthalmol Soc* **111**, 180–215 (2013).
37. Batista, C. E. A., Juhasz, C., Muzik, O., Chungani, D. & Chungani, H. Increased visual cortex glucose metabolism contralateral to angioma in children with Sturge – Weber syndrome. *Dev. Med. Child Neurol.* **49**, 567–573 (2007).
38. Hatfield, L. a *et al.* Quantitative EEG asymmetry correlates with clinical severity in unilateral Sturge-Weber syndrome. *Epilepsia* **48**, 191–5 (2007).
39. Kelley, T. M., Hatfield, L. A., Lin, D. D. M. & Comi, A. M. Quantitative Analysis of Cerebral Cortical Atrophy and Correlation With Clinical Severity in Unilateral Sturge-Weber Syndrome. *J Child Neurol.* **20**, 867–870 (2005).
40. Arzimanoglou, A. A. *et al.* Sturge-Weber syndrome: Indications and results of surgery in 20 patients. *Neurology* **55**, 1472–1479 (2000).
41. Rosenbaum, L. J. Glaucoma in Sturge-Weber syndrome. *Birth Defects Orig.Artic.Ser.* **18**, 645–649 (1982).
42. Uram, M. & Zubillaga, C. The Cutaneous Manifestations of Sturge-Weber Syndrome. *J. Clin. Neuro-ophthalmol.* **2**, 245–248 (1982).

43. Feng, Y. & Yang, Y. Sturge-Weber Syndrome. A report of 22 cases. *Chin.Med.J.(Engl)* **93**, 697–708 (1980).
44. Jagtap, S., Srinivas, G., Harsha, K. J., Radhakrishnan, N. & Radhakrishnan, A. Sturge-Weber syndrome: clinical spectrum, disease course, and outcome of 30 patients. *J. Child Neurol.* **28**, 725–31 (2013).
45. Sharan, S. *et al.* Port-wine vascular malformations and glaucoma risk in Sturge-Weber syndrome. *J. AAPOS* **13**, 374–8 (2009).
46. Van Emelen, C., Goethals, M., Dralands, L. & Casteels, I. Treatment of glaucoma in children with Sturge-Weber syndrome. *J Pediatr Ophthalmol Strabismus.* **37**, 29–34 (2000).
47. Awad, A. H., Mullaney, P. B., Al-mesfer, S. & Zwaan, J. T. Glaucoma in Sturge-Weber Syndrome. *J AAPOS* **3**, 40–45 (1999).
48. Taylor, R. H., Ainsworth, J. R., Evans, A. R. & Levin, A. V. The Epidemiology of Pediatric Glaucoma : The Toronto Experience. *J AAPOS* **3**, 308–315 (1999).
49. Stokes, J. The Ocular Manifestations of the Sturge-Weber Syndrome. *South Med J* **50**, 82–9 (1957).
50. Celebi, S., Alagöz, G. & Aykan, U. Ocular findings in Sturge-Weber syndrome. *Eur J Ophthalmol.* **10**, 239–43 (2000).
51. Audren, F. *et al.* Non-penetrating deep sclerectomy for glaucoma associated with Sturge-Weber syndrome. *Acta Ophthalmol. Scand.* **84**, 656–660 (2006).
52. Comi, A. M. *et al.* Increased fibronectin expression in Sturge-Weber syndrome fibroblasts and brain tissue. *Pediatr. Res.* **53**, 762–769 (2003).



# 6

## **Visual function and compensatory mechanisms for hemianopia after hemispherectomy in children**

Yvonne Koenraads  
Denise C.P. van der Linden  
Monique M.J. van Schooneveld  
Saskia M. Imhof  
Peter H. Gosselaar  
Giorgio L. Porro  
Kees P.J. Braun

*Epilepsia* 2014 Jun;55(6):909-17

## ABSTRACT

### Objective

Little is known about the functional visual outcome of children after hemispherectomy. Several case reports have described an anomalous head posture (AHP) and exotropia (XT) contralateral to the side of early brain damage, as possible compensatory mechanisms (CMs) for homonymous hemianopia (HH). The aim of this study was to determine visual outcome and the prevalence of such CMs in hemispherectomized children.

### Methods

Patient files from all children who underwent hemispherectomy and had a postoperative ophthalmologic examination in the University Medical Center (UMC) Utrecht up to October 2012 were retrospectively reviewed. Preoperative and postoperative clinical information on visual fixation, visual acuity, visual fields, optic discs, head posturing, ocular alignment, and cognitive development was collected. Clinical characteristics were compared between children who developed CMs and those who did not.

### Results

Forty-five children (21 male) underwent a hemispherectomy (22 right) at a median age of 2.1 years. Median ophthalmologic follow-up was 2.3 years. After hemispherectomy, visual fixation was present in all children, and 87% of the examined children had a normal visual acuity or a mild visual impairment. All children who underwent a visual field measurement had an HH. Anomalous head posturing and continuous or intermittent XT contralateral to the side of hemispherectomy were found in 53% and 38% of children, respectively. Children with CMs had more frequently rightsided surgery and earlier onset of epilepsy, and they tended to be younger when they underwent hemispherectomy than children without.



**Significance**

Despite HH, the majority of children who undergo hemispherectomy have a good visual outcome. Furthermore, they frequently develop AHP and continuous or intermittent XT contralateral to the hemispherectomy as part of a coping strategy to optimize the functional visual field.

## INTRODUCTION





Hemispherectomy is an effective treatment for children with pharmaco-resistant epilepsy originating from one hemisphere.<sup>1</sup> Long-term seizure freedom is reached in 63% of children,<sup>2</sup> and mental development often improves after hemispherectomy.<sup>3,4</sup> Postoperatively, all children have homonymous hemianopia (HH), although the majority of patients had already been diagnosed with partial or complete hemianopic visual field defects due to the underlying epileptogenic hemispheric disorder prior to surgery. Until now, three studies have reported on the frequency of visual field defects before and after hemispherectomy in children. Hemianopia was described in 57–79% of patients preoperatively and in all children postoperatively.<sup>5–7</sup> The actual impact of living with HH is unclear.<sup>8</sup> Some children seem to develop coping strategies to maximize the functional visual field. Several case reports and case series have demonstrated that an anomalous head posture (AHP)<sup>9–13</sup> and exotropia (XT)<sup>10,12,14–19</sup> contralateral to the side of brain damage may compensate a hemianopic defect in children and adults with early onset HH. XT contralateral to the brain damage, that is, toward the hemianopic side, may create a more panoramic view and broaden the functional visual field. This XT could be considered a compensatory mechanism (CM), which may be permanently present (continuous XT), or the blind field may be explored by scanning movements (intermittent XT). By AHP to the contralateral side of the brain damage, the visual field will be centered, since the blind field is moved to the side<sup>12</sup> and scanning movements are efficient from this position.<sup>9,11</sup> We do not know how frequently these CMs occur in children who undergo hemispherectomy and which children are prone to develop them.

Furthermore, there are no studies that described visual fixation and visual acuity in hemispherectomized children, and little is known about visual outcome in this cohort of patients. When counseling parents of children who will undergo hemispherectomy, it is important to inform about the expectations of all aspects of visual outcome, including visual fixation, visual acuity, visual field and the possible functional strategies children may develop to compensate for the HH. The aim of this study was to determine visual outcome and the prevalence of CMs,

such as AHP and XT contralateral to the side of the brain damage, in children with HH after hemispherectomy, and to compare children who developed these CMs with those who did not.

**eVideo 1. Movie AHP & eVideo 2. Movie XT**

Scan the code using a QR scan application on your smartphone or tablet, or go to:  
<http://onlinelibrary.wiley.com/doi/10.1111/epi.12615/supinfo>

	<p><b>Anomalous head posture in a child with left hemianopia</b></p>	
<p>The child is performing a task that requires proper visual fixation. At this moment, he shows a head turn in the horizontal plane to the side of the hemianopia.</p>		
	<p><b>Contralateral exotropia in a child with left hemianopia</b></p>	
<p>The child is performing a task that requires proper visual fixation Besides an anomalous head turn, he shows an exotropia to the side of the hemianopia</p>		

## METHODS

### Subjects

All children who were younger than 18 years at the time of surgery and underwent a hemispherectomy in our center between January 1994 and October 2012 were included in the study, provided that they underwent at least one postoperative ophthalmologic examination. The study was approved by the institutional ethical committee of the University Medical Center (UMC) Utrecht, which concluded that the Dutch Medical Research Involving Human Subjects Act did not apply and written informed consent was not needed.

### Data collection

Patient files were retrospectively analyzed. Demographic and clinical characteristics collected consisted of gender, etiology of epilepsy, age of onset of epilepsy, seizure type and frequency, age at hemispherectomy, duration of epilepsy up to hemispherectomy, side of hemispherectomy, postoperative complications, seizure freedom, and number of follow-up investigations. Etiology of epilepsy was classified as developmental, stable acquired, or progressive.<sup>5,20</sup> Postoperative seizure freedom was recorded up to the final ophthalmologic consultation.

Preoperative and postoperative clinical information on developmental status, visual function, head posturing, and ocular alignment was collected. Intelligence quotient (IQ) or mental developmental index (MDI) scores were retrieved from neuropsychological investigations prior to and 1 or 2 years after hemispherectomy. Corresponding to their age and cognitive level, children were assessed using the Dutch versions of the Bayley Scales of Infant and Toddler Development, McCarthy Scales of Children's Abilities, the Groningen developmental scale, Stutsmann intelligence test for infants, Snijders-Oomen Nonverbal Intelligence Test, or Wechsler Intelligence Scales. If mental development could not be determined more precisely than "below the mental development index provided by the manual," a developmental quotient (DQ) was calculated.<sup>20</sup>

### **Visual function**

Visual outcome included information on visual fixation, visual acuity, visual fields, and optic discs. Best presurgical and postsurgical visual fixation was noted. Visual acuity measurements reflect central vision, provided by the approximately 2-degree wide center of the macular region of the retina, also known as the fovea. These measurements were performed with the Teller Acuity Cards, the Cardiff Acuity Test, the Kays/Amsterdam Picture Chart, or the Snellen Chart, corresponding to the age and cooperation of the child. Preoperative and postoperative best corrected visual acuity at the highest applicable test was documented in children older than 3 years of age. Assessments of children with younger age were excluded, since in this specific group of braindamaged children, in our experience, lack of cooperation results in very low visual acuity values, which was expected to strongly influence the reliability of the results. Values were converted into LogMAR (Logarithm of the Minimum Angle of Resolution), in which 0.2 to 0.1 LogMAR represents normal vision, 0.2–0.5 LogMAR mild visual impairment (VI), 0.6–0.9 LogMAR moderate VI, 1.0–1.3 LogMAR severe VI, 1.4–1.7 LogMAR profound VI, and 1.8–2.0 LogMAR (near-)blindness, according to the 10th revision of the International Classification of Diseases.<sup>21</sup> Presence of a continuously present visual fixation and a (near-)normal vision, that is, normal vision or mild visual impairment, was considered a good visual outcome. Preoperative and postoperative visual field measurements were, depending on the age and participation of the child, done by means of the behavioral visual field test (BEFIE test)<sup>22</sup> from preverbal age onward, or with standard conventional static (Peritest/Humphrey Field Analyzer) or kinetic (Goldmann perimeter) visual field tests in the older children. Optic discs were assessed by means of dilated funduscopy by an experienced ophthalmologist.

### **Head posturing**

We noted whether AHP was documented during the course of the ophthalmologic follow-up, at what time AHP was first described, and to what direction the head was turned. We defined AHP as a head turn or torticollis contralateral to the hemispherectomy, that is, toward the hemianopic field.

### **Ocular alignment**

Ocular alignment was assessed by an experienced orthoptist by means of light reflexes and the cover test. Continuous or intermittent XT could either be ipsilateral or contralateral to the hemispherectomy. We defined potential compensatory XT as an exodeviation of the contralateral eye, that is, to the side of the hemianopic field. We noted the first examination during which this contralateral XT was documented. Other ocular alignment abnormalities, for example, esotropia and XT of the ipsilateral eye to the hemispherectomy, were also described. Detailed descriptions of AHP and ocular alignment were often lacking in the retrospective review of the reports of ophthalmologic investigations. To further elucidate the origin and function of the possible CMs in more detail, we paid specific attention on duration and time of occurrence of AHP, and on the intermittent character of contralateral XT in the eight children that visited our outpatient clinical after July 30, 2012.

### **Analysis**

Proportions and median values of all clinical data were calculated, and the prevalence of the possible CMs (AHP and contralateral XT) was determined, as was the time interval between surgery and first description of AHP or contralateral XT. Clinical characteristics were compared between patients who did and those who did not develop CMs. To account for the potential effect of limited follow-up time, children with absent CMs were included only if follow-up duration was considered sufficient to have developed them, that is, at least 2 years after surgery. p-Values of differences between the patient groups were calculated with t-tests and Mann-Whitney U tests for continuous data, depending on the normality of the data. Chi-square tests were used for categorical data. The Fisher exact test was applied if  $\geq 25\%$  of cells had the expected count  $< 5$ .  $p \leq 0.05$  was considered statistically significant.

## RESULTS

Forty-five children (21 male) who all underwent a functional hemispherectomy were included in this study. Demographic and clinical characteristics of the patients are shown in Table 1. Etiology of epilepsy was developmental in 20 children (44%: 10 with hemimegalencephaly [including one with tuberous sclerosis complex], eight with multilobar or hemispheric cortical dysplasia [including one with tuberous sclerosis complex], and two with multidevelopmental anomalies). In 18 children (40%), etiology was considered stable and acquired early in life (10 with perinatal ischemic lesions, 6 with a porencephalic cyst, one with perinatally acquired unilateral traumatic injury, and one with hemiconvulsion hemiplegia epilepsy syndrome). The other seven children (16%) had progressive pathology (three had Sturge-Weber syndrome with progressive atrophy or neurologic deficits, and four had Rasmussen encephalitis). Epilepsy emerged between birth and the age of 10.2 years (median 0.4 years). Seventeen of the children had epileptic spasms at some point during their active epilepsy prior to surgery. In total, only three children had <20 seizures per month. The other 43 children all had multiple seizures a day, 17 of whom had >20 seizures a day or had (repeated) status epilepticus. Hemispherectomy was performed at a median age of 2.1

**Table 1. Demographic and clinical characteristics**

<b>Characteristics</b> (n=45)	n (%) or median [range]
Gender	
Male	21 (47)
Etiology of epilepsy	
Developmental	20 (44)
Stable acquired	18 (40)
Progressive	7 (16)
Age of onset of epilepsy (years)	0.4 [0.0-10.2]
Age at HS (years)	2.1 [0.2-14.3]
Duration of epilepsy up to HS (years)	1.6 [0.1-10.9]
Side of HS	
Right	22 (49)
Seizure freedom at the end of ophthalmological FU	35 (78)
Longest ophthalmological FU after HS (years)	2.3 [0.03-14.7]
Number of FU investigations	2 [1-13]

n, number of patients investigated; %, percentage of patients; HS, hemispherectomy; FU, follow-up.

**Table 2. Pre- and postoperative developmental and ophthalmological findings**

Characteristics	Preoperative		Postoperative	
	n	n (%) or median [range]	n	n (%) or median [range]
Developmental status (IQ/MDI/DQ)	30	50 [3-74]	32	51 [14-95]
Visual fixation	25		45	
Continuously present		20 (80)		41 (91)
Intermittent		4 (16)		4 (9)
Absent		1 (4)		0 (0)
VA				
LogMAR	4	0.19 [0.00-0.78]	30	0.13 [0.00-0.98]
Category				
Normal vision		2 (50)		15 (50)
Mild VI		1 (25)		11 (37)
Moderate VI		1 (25)		3 (10)
Severe VI		0 (0)		1 (3)
Profound VI		0 (0)		0 (0)
Blind		0 (0)		0 (0)
Visual field	18		37	
Hemianopia		13 (72)		37 (100)
Quadrantanopia		1 (6)		0 (0)
Normal		4 (22)		0 (0)
Visual field test performed				
Conventional		3 (17)		10 (27)
BEFIE		15 (83)		27 (73)
Optic disc	22		41	
Pale bilateral		8 (36)		13 (32)
Pale ipsilateral		1 (5)		2 (5)
Pale contralateral		0 (0)		1 (2)
Normal		13 (59)		25 (61)
Anomalous head posture	26	2 (8)	45	24 (53)
Eye deviation	26		45	
Exotropia				
Contralateral to HS		2 (8)		17 (38)
Ipsilateral to HS		3 (12)		7 (16)
Esotropia		6 (23)		4 (9)

n, number of patients investigated; %, percentage of patients; IQ, intelligence quotient; MDI, mental developmental index; DQ, developmental quotient; VA, visual acuity of children >3 years of age; LogMAR, VA measured with Teller Acuity Cards, Cardiff Acuity Test, Kays/Amsterdam Picture Chart or Snellen Chart translated into the international Logarithm of the Minimum Angle of Resolution value; VI, visual impairment; HS, hemispherectomy.



years (range 0.2–14.3 years) after a median epilepsy duration of 1.6 years (range 0.1–10.9 years). Five children had a postoperative complication that required surgical or other invasive treatment in the interval between surgery and last ophthalmologic evaluation. In total, 35 children (78%) were seizure free after a median postoperative follow-up duration of 2.3 years (range 0.03–14.7 years). None of the hemispherectomized children underwent specific visual therapy or rehabilitation.

Patients underwent 1–13 follow-up visual investigations (median 2). Preoperative and postoperative developmental and ophthalmologic characteristics are listed in Table 2. Among the children who underwent neuropsychological assessments, preoperative and postoperative median IQ, MDI, or DQ scores were similar, with median values of 50 and 51, respectively.

### **Visual outcome**

After hemispherectomy, all children showed visual fixation behavior, which was continuously present in 41 patients (91%). Visual acuity varied between 0.00 and 0.98 LogMAR (median 0.13 LogMAR) in postoperative assessments of patients older than 3 years of age. Of these 30 children, 15 (50%) had normal vision. A mild, moderate, severe, and profound visual impairment was present in 11 (37%), 3 (10%), one (3%), and zero (0%) children, respectively. None of the children was blind. In five children, visual acuity was not measurable because of lack of attention or cooperation (median age 2.7 years, range 0.8–5.9 years); four children did not undergo visual acuity measurement (all younger than 3 years of age), and visual acuity measurements of six children were excluded because of age younger than 3 years. Preoperative visual acuity could be measured in only four children older than 3 years of age and varied between 0.00 and 0.78 LogMAR (median 0.19 LogMAR). After hemispherectomy, visual acuity of these four children (two with normal vision; two with mild visual impairment) remained stable. Among the 18 children who had a preoperative visual field measurement, 13 children (72%) already were diagnosed with HH before surgery. After hemispherectomy all children who underwent visual field measurements revealed contralateral HH. Preoperative and postoperative assessment of the optic disc by means of dilated funduscopy showed paleness in 9 (41%) and 16 (39%) of the examined children, respectively.

**Table 3. Clinical characteristics of children who did and those who did not develop**

Characteristics	Anomalous head posture			
	n 24	Yes	n 10	No <sup>a</sup>
		n (%) or median [range]		n (%) or median [range]
Anomalous head posture		-		-
Contralateral exotropia		10 (42)		5 (50)
Gender				
Male		10 (42)		5 (50)
Etiology of epilepsy				
Developmental		13 (54)		3 (30)
Stable acquired		10 (42)		5 (50)
Progressive		1 (4)		2 (20)
Age of onset of epilepsy (years)		<b>0.3 [0.0-2.7]*</b>		<b>1.2 [0.1-10.2]</b>
Age at HS (years)		2.1 [0.2-8.1]		5.1 [0.4-12.4]
Duration of epilepsy up to HS (years)		1.6 [0.2-6.3]		1.6 [0.1-10.9]
Side of HS				
Right		<b>15 (63)*</b>		<b>2 (20)</b>
Seizure freedom at the end of ophthalmological FU		21 (88)		6 (60)
Longest ophthalmological FU after HS (years)		<b>2.4 [0.3-10.3]*</b>		<b>5.7 [2.6-14.7]</b>
Number of FU investigations		3.5 [1-11]		4 [1-13]
Developmental status (IQ/MDI/DQ) #	21	50 [14-95]	6	60 [16-85]
Visual fixation				
Continuously present		24 (100)		9 (90)
Intermittent		0 (0)		1 (10)
Absent		0 (0)		0 (0)
VA #				
LogMAR	19	0.10 [0.00-0.98]	8	0.24 [0.00-0.62]
Optic disc				
Pale bilateral		8 (33)		2 (20)
Pale unilateral		2 (8)		1 (10)
Normal		14 (58)		7 (70)

n, number of patients investigated; %, percentage of patients; HS, hemispherectomy; FU, follow-up; IQ, intelligence quotient; MDI, mental development index; DQ, developmental quotient; VA, visual acuity of children >3 years of age; diff Acuity Test, Kays/Amsterdam Picture Chart or Snellen Chart translated into the international value; VI, visual impairment. <sup>a</sup>, children who did not demonstrate compensatory mechanisms after hemispherectomy; \*, p ≤ 0.05; #, not all children were tested, see aberrant n-value in n-column;

**compensatory mechanisms**

<b>Contralateral exotropia</b>			
n	<b>Yes</b>	n	<b>No<sup>a</sup></b>
17	n (%) or median [range]	12	n (%) or median [range]
	10 (59)		7 (58)
	-		-
	7 (41)		6 (50)
	10 (59)		4 (33)
	6 (35)		6 (50)
	1 (6)		2 (17)
	<b>0.2 [0.0-2.0]*</b>		<b>0.7 [0.0-10.2]</b>
	1.7 [0.2-12.4]		3.9 [0.5-12.1]
	1.3 [0.1-10.9]		1.8 [0.5-10.9]
	<b>11 (65)*</b>		<b>2 (17)</b>
	13 (76)		9 (75)
	4.8 [0.2-14.7]		4.4 [2.0-14.2]
	4 [1-11]		4 [1-13]
10	58 [27-95]	11	52 [14-85]
	15 (88)		12 (100)
	2 (12)		0 (0)
	0 (0)		0 (0)
12	0.23 [0.00-0.62]	11	0.08 [0.00-0.98]
	4 (24)		4 (33)
	2 (12)		1 (8)
	11 (65)		7 (58)

low-up; IQ, intelligence quotient; MDI, mental de-LogMAR, VA measured with Teller Acuity Cards, Carl Logarithm of the Minimum Angle of Resolution after they were followed for at least two years after

Preoperative seizure frequency or postoperative complications were not related to a worse visual outcome. Furthermore, the 25 patients who used vigabatrin (n=20) and/or topiramate (n=13), drugs known to have possible ocular adverse effects, did not have a significantly worse visual outcome than children who did not take these antiepileptic drugs.

**“Dynamic” head posturing**

AHP toward the hemianopic field was documented in 24 (53%) of 45 children after hemispherectomy. Two of these children, who both already had preoperative HH, also showed an AHP before surgery. In 13 of the children with AHP (54%), posturing was first documented before the end of the first postoperative year, and in 19 (79%) within 2 years postoperatively. This AHP, which may compensate for the HH, had a typical presentation (see eVideo 1). Detailed observations of four children with AHP among the eight children who recently visited our clinic revealed that AHP was characterized by an intermittent head turn in

the horizontal plane to the side of the HH, persisting for several seconds each time when it was seen, and occurring especially during tasks that required proper visual fixation, such as visual acuity measurements in the office room. In contrast to torticollis, the presence of this AHP was variably present and activated especially when scanning the environment for targets positioned far away. During this AHP, the eyes were pointed back to the front, that is, ipsilateral to the hemispherectomy.

### **Compensatory exotropia**

Exotropia contralateral to the hemispherectomy, either continuously or intermittently present (see eVideo 2), was documented in 17 (38%) of 45 children postoperatively, compared to documentation in only two (8%) of 26 children preoperatively. Contralateral XT was first described before the end of the first postoperative year in 9 children (53%), and within 2 years postoperatively in 13 children (76%). Its presentation was intermittent in 11 of 17 children (65%). Postoperative esotropia or XT ipsilateral to the hemispherectomy was seen in only four (9%) and seven (16%) children, respectively. During observation of the XT that was present in two of the eight children who recently visited our clinic, we could not detect a consistent pattern in the use of contralateral XT.

### **Predisposition**

We compared clinical characteristics of children who developed CMs with those of children who did not demonstrate CMs but were followed for at least 2 years after hemispherectomy (see Table 3). The distribution of these groups is shown in the Venn diagram in Figure 1. Of all 31 children who developed CMs, 10 showed both AHP and contralateral XT. Only 5 of 26 children who were followed for at least 2 years did not develop any of the two CMs.

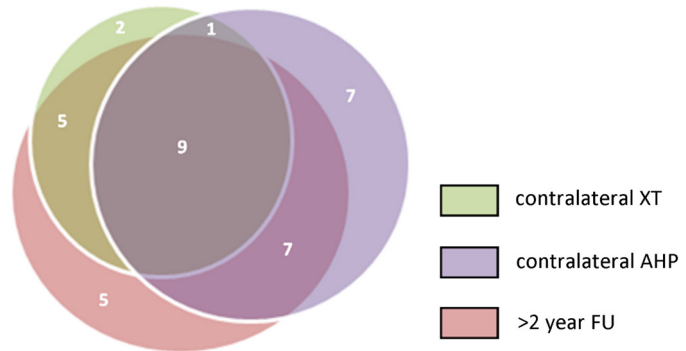
In the group of patients who developed CMs, the percentage of children who underwent right-sided hemispherectomy was higher (AHP: 63%, contralateral XT: 65%) compared to those who did not develop CMs (AHP: 20%, contralateral XT: 17%). This difference reached statistical significance for both AHP (chi-square test:  $p=0.024$ ) as well as for contralateral XT

(chi-square test:  $p=0.010$ ). Furthermore, of the 10 children who developed both CMs, 9 underwent right-sided hemispherectomy compared to none of the five children who did not develop any CM after a follow-up of at least 2 years (Fisher exact test:  $p=0.002$ ).

Children who developed CMs were significantly younger at onset of epilepsy (AHP: median 0.3 years, contralateral XT: median 0.2 years) compared to patients who did not develop these CMs (AHP: median 1.2 years, contralateral XT: median 0.7 years. Mann-Whitney U test: AHP  $p=0.008$ , contralateral XT  $p=0.026$ ). This difference in age at onset of epilepsy was even larger when the 10 children who developed both CMs (median 0.0 years, range 0.0–0.5 years) were compared to children who did not develop any CM after a follow-up of at least 2 years (median 2.0 years, range 0.3–10.2 years, Mann-Whitney U test:  $p=0.004$ ). In addition, children who developed CMs tended to be younger when they underwent surgery (AHP: median 2.1 years, contralateral XT: median 1.7 years) than children who did not develop these CMs (AHP: median 5.1 years, contralateral XT: median 3.9 years).

There were no significant differences in gender, etiology of epilepsy, duration of epilepsy, postoperative seizure freedom, developmental status, visual fixation, visual acuity, and assessment of optic discs between the two groups.

**Figure 1. Venn diagram showing the distribution of children who did and those who did not develop compensatory mechanisms**



XT, exotropia; AHP, anomalous head posture; FU, longest follow-up. Nine children with a FU of <2 years did not develop compensatory mechanisms.

## DISCUSSION

This study focused on visual outcome and the prevalence of compensatory mechanisms (CMs) for homonymous hemianopia (HH) in children who underwent hemispherectomy. In our cohort of 45 hemispherectomized children, we found that anomalous head posture (AHP) and exotropia (XT) contralateral to the hemispherectomy occurred in 24 (53%) and 17 (38%) patients, respectively. We propose that both function as CMs for the visual field defect, since they enable functional visual field optimization.

### Visual outcome

Literature about visual outcome after hemispherectomy is scarce. In our series all children showed visual fixation behavior after hemispherectomy. Normal visual acuity or only mild visual impairment was found in most children (87%) who were able to undergo visual acuity measurements. In five children of the hemispherectomized cohort, visual acuity could not be quantified because of lack of attention or cooperation. In this group, even the Teller Acuity Card or the Cardiff Acuity Test could not be performed, which are both widely used in preverbal children, since they are based on resolution acuity using pattern preferences.<sup>23</sup> Nevertheless, based on the 30 children in whom visual function could be reliably assessed, visual acuity, reflecting central vision, probably remains intact when one hemisphere is eliminated. This might be explained by sparing of the fovea, the main structure to obtain high visual acuity.<sup>24</sup> However, whether the fovea has a bilateral or split representation is still a matter of debate,<sup>25</sup> which cannot be resolved by the findings of our study.

Parents of young children visiting our pediatric neuroophthalmologic outpatient clinic are generally highly positive about their child's postoperative visual development. They are often amazed by the amelioration from an isolated child whose visual functioning is lacking or limited, to an alert and attentive child who fixates, follows moving objects and makes eye contact. These developments, probably based on visual, attentional, and cognitive profits of the hemispherectomy, are essential for social-emotional and further cognitive development and may

be crucial in the parent-child relationship.

All children whose visual fields could be reliably examined had postoperative HH. The majority of them (72%) had already been diagnosed with HH before surgery. To the best of our knowledge, only one child has been reported in the literature with remarkably preserved visual fields after hemispherectomy. Werth et al.<sup>26</sup> described a normal visual field extent in a child with a cerebral malformation, 5.7 years after a complete hemispherectomy at 0.3 years of age. Whether this finding is a consequence of a systematic error in the method of visual field examination, or may be explained by neuronal rerouting and cortical reorganization still has to be elucidated.<sup>26,27</sup> In our cohort, none of the children showed a recovery of the hemianopic visual field. Nevertheless, according to Moosa et al.,<sup>7</sup> daily activities are not disturbed by visual symptoms in up to 46% of children.

Paleness of the optic disc was observed in 16 children (39%) and may be explained by retrograde transsynaptic neuronal degeneration.<sup>28</sup> This retrograde degeneration has been investigated in hemispherectomized monkeys and appeared to be inversely correlated with age at time of the lesion.<sup>29</sup> Correspondingly, children with paleness of the optic disc in our study had earlier onset of epilepsy and underwent hemispherectomy at an earlier age than children without.

### **Compensatory mechanisms for hemianopia**

Abnormal head posturing in children has various origins. It may arise to stabilize nystagmus or incomitant strabismus (i.e., the strabismus angle depends on gaze direction), or it may arise when a visual field defect is present. If AHP occurs directly after hemispherectomy, it might be interpreted as a compensation strategy for a postoperative gaze preference, due to damage of the frontal motor eye fields. However, such a gaze preference nearly always resolves within several weeks.<sup>30,31</sup> Based on previous descriptions of AHP in combination with an (early) visual field defect,<sup>9-13</sup> we hypothesize that AHP is a CM to maximize the use of the functional visual field in children with brain injury.

Remarkably, we show that 24 of 45 hemispherectomized children (53%) develop AHP. Accord-

ing to Good et al.,<sup>12</sup> children with HH attempt to move their blind field to the side, resulting in centralization of the residual visual field. Contrarily, it is frequently observed that children point their eyes back to the front. Possibly children use an AHP to search for their target and subsequently point their eyes back to fixate on this target. Whether this hypothetical mechanism, which might be an extremely rapid movement, is the reason AHP develops could not be established with our observations. In agreement with previous suggestions by Paysse et al.<sup>9</sup> and Donahue et al.,<sup>10</sup> the phenomenon of AHP in hemispherectomized children may also be explained by its efficient position for exploring the blind field by making saccades to the side of the HH. In addition, we speculate that this position is efficient for using a contralateral XT, since the contralateral eye merely has to deviate back into its neutral position to broaden the visual field.

These theories may elucidate why, in our experience, AHP in children with HH is especially observed during tasks that require proper visual fixation, and is mostly activated in scanning the environment for targets positioned far away. Because this AHP is distinguished by its variable and intermittent character, we propose the phenomenon should be named “dynamic” head posturing.

Equally intriguing is the observation that 17 (38%) of 45 hemispherectomized children develop contralateral XT.<sup>10,12,14–19</sup> This phenomenon was first reported by Herzau et al.,<sup>15</sup> who described two adult patients with HH and XT, both existing from early childhood, that led to functional enlargement of the binocular visual field, an observation later confirmed by Saleh et al.<sup>17</sup> and Jacobson et al.<sup>14</sup> In our study, the postoperative shift of ocular alignment to contralateral XT advocates a compensatory origin. However, there is an ongoing debate about the origin of this XT in children with HH. Good et al.<sup>12</sup> suggested that this XT arises coincidentally as a consequence of neurologic damage, whereas according to several other authors XT is a CM to expand the functional visual field.<sup>10</sup> We speculate that these children somehow prefer the expansion of the functional visual field by means of contralateral XT above normal ocular alignment. In addition, several authors have suggested that the expected double vision might be avoided when this functional visual field enlargement by XT is accompanied by an anomalous retinal



correspondence,<sup>16,18,32,33</sup> resulting in continuous XT, or by using scanning movements into the blind field, observed as intermittent XT.<sup>14</sup> Both continuous and intermittent were observed in our hemispherectomized children.

These two CMs might explain the relatively good visual outcome in daily activities found by Moosa et al.<sup>7</sup> The observation that these mechanisms particularly occur after hemispherectomy could relate to attentional and cognitive profits of the surgical procedure, enabling children to develop compensatory strategies to cope with the hemianopic field defect. It is important to note that surgical correction of contralateral XT in these children should be avoided,<sup>15,16,18,19</sup> since it may constrict the functional visual field. In addition, we cannot rule out a possible compensatory component in ipsilateral XT.

If AHP and contralateral XT truly serve as CMs for HH in hemispherectomized children, it is interesting to search for clinical parameters that predispose to the development of compensation. Most of the possible preoperative and surgical determinants tested in this study were not significantly related to the occurrence of AHP or contralateral XT. Remarkably, however, there was a correlation between the side of hemispherectomy and the occurrence of AHP and contralateral XT. The majority of children who developed CMs underwent right-sided hemispherectomy, whereas most children who did not develop AHP or contralateral XT had left-sided surgery. It is unlikely that this could be explained by differences in intelligence, since there were no differences in global cognitive development between left and right-sided hemispherectomized children.<sup>4</sup> Possibly, this finding relates to differences in cerebral specialization between both hemispheres, such as hemispheric lateralization of aspects of the high-level visual processing subsystems, such as visual recognition, navigation, tracking, and imagery.<sup>34–36</sup> Furthermore, children with CMs had an earlier onset of epilepsy and there was a tendency toward hemispherectomy at younger age in children with CMs compared to those without. This suggests that timing of the insult may relate to the potency to develop CMs. According to Jacobson et al.,<sup>14</sup> timing of the lesion might also differentiate between children who develop continuous versus intermittent or scanning XT, a suggestion we could not confirm with the findings of this study.

## Chapter 6

Limitations of our study were the retrospective design with follow-up that varied in time and number of follow-up investigations. Eleven children had only one and 13 had only two follow-up investigations. In addition, follow-up time was sometimes too short to rule out the possible development of CMs later during the time course following surgery. To account for that, we only included children with absent CMs in the comparative analysis who had been followed for at least 2 years. Moreover, by relying on retrospective review of original reports of ophthalmologic assessments, we cannot guarantee that all elements of visual outcome were examined and documented consistently. Possibly, in some patients AHP or XT were seen, but left unrecorded, which may have led to an underestimation of their frequency. Finally, visual acuity may have been overestimated, because results of assessments were available in only 30 children. In the other 15, it was not always clear whether acuity was not documented because of lack of cooperation or because values were immeasurably low.

## **CONCLUSION**

This study shows that the majority of children who undergo hemispherectomy have a good visual outcome. Complete HH is present in all children, and many develop AHP and continuous or intermittent XT contralateral to the hemispherectomy. We suggest that both function as CMs for the visual field defect, since they enable functional visual field optimization. It is still unclear which children are prone to develop these CMs, although right-sided surgery and earlier onset of epilepsy and hemispherectomy seem to predispose.


When examining children prior to and after hemispherectomy, parents should be informed on the visual acuity and visual field consequences of surgery, and on the possible development of compensation mechanisms that may play a role in a coping strategy to maximize the functional visual field. Surgical correction of XT in these children should be avoided.

## REFERENCES

1. Spencer, S. & Huh, L. Outcomes of epilepsy surgery in adults and children. *Lancet Neurol.* **7**, 525–37 (2008).
2. Moosa, A. N. V *et al.* Longitudinal seizure outcome and prognostic predictors after hemispherectomy in 170 children. *Neurology* **80**, 253–60 (2013).
3. Van Schooneveld, M. M. J., Jennekens-Schinke, A., van Rijen, P. C., Braun, K. P. J. & van Nieuwenhuizen, O. Hemispherectomy: a basis for mental development in children with epilepsy. *Epileptic Disord.* **13**, 47–55 (2011).
4. Van Schooneveld, M. M. J. & Braun, K. P. J. Cognitive outcome after epilepsy surgery in children. *Brain Dev.* (2013).
5. Devlin, a. M. Clinical outcomes of hemispherectomy for epilepsy in childhood and adolescence. *Brain* **126**, 556–566 (2003).
6. Basheer, S. N. *et al.* Hemispheric surgery in children with refractory epilepsy: seizure outcome, complications, and adaptive function. *Epilepsia* **48**, 133–40 (2007).
7. Moosa, A. N. V *et al.* Long-term functional outcomes and their predictors after hemispherectomy in 115 children. *Epilepsia* **54**, 1771–9 (2013).
8. Hayes, A., Chen, C. S., Clarke, G. & Thompson, A. Functional improvements following the use of the NVT Vision Rehabilitation program for patients with hemianopia following stroke. *NeuroRehabilitation* **31**, 19–30 (2012).
9. Paysse, E. A. & Coats, D. K. Anomalous Head Posture With Early-Onset. *J AAPOS* **1**, 209–13 (1997).
10. Donahue, S. P. & Haun, A. K. Exotropia and face turn in children with homonymous hemianopia. *J Neuroophthalmol.* **27**, 304–7 (2007).
11. Zangemeister, W. H., Meienberg, O., Stark, L. & Hoyt, W. F. Eye-head coordination in homonymous hemianopia. *J. Neurol.* **226**, 243–54 (1982).
12. Good, W. V *et al.* Cortical visual impairment in children. *Surv. Ophthalmol.* **1738**, 351–364 (1994).
13. Porro, G., van der Linden, D., van Nieuwenhuizen, O. & Wittebol-Post, D. Role of visual dysfunction in postural control in children with cerebral palsy. *Neural Plast.* **12**, 205–10; discussion 263–72 (2005).
14. Jacobson, L., Lennartsson, F., Pansell, T., Oqvist Seimyr, G. & Martin, L. Mechanisms compensating for visual field restriction in adolescents with damage to the retro-geniculate visual system. *Eye (Lond).* **26**, 1437–45 (2012).
15. Herzau, V., Bleher, I. & Joos-kratsch, E. Infantile exotropia with homonymous hemianopia : a rare contraindication for strabismus surgery. *Graefe 's Arch. Ophthalmol.* **1**, 148–149 (1988).
16. Levy, Y., Turetz, J., Krakowski, D., Hartmann, B. & Nemet, P. Development of compensating exotropia with anomalous retinal correspondence after early infancy in congenital homonymous hemianopia. *J Pediat Ophthalmol Strabismus* **3**, 236–238 (1995).
17. Saleh, G., Sivaprasad, S. & Hammond, C. Homonymous hemianopia and exotropia: an important management issue. *Eye (Lond).* **20**, 1402–1404 (2006).
18. Gote, H., Gregersen, E. & Rindziunski, E. Exotropia and panoramic vision compensating for an occult congenital homonymous hemianopia. A case report. *Binoc Vis. Eye Muscle Surg Q* **8**, 129–132 (1993).
19. Gamio, S. & Melek, N. When the patient says no. Management of exotropia with hemianopic visual field defects. *Binocul Vis Strabismus Q* **18**, 167–170 (2003).
20. Boshuisen, K. *et al.* Contralateral MRI abnormalities affect seizure and cognitive outcome after hemispherectomy. *Neurology* **75**, 1623–30 (2010).
21. World Health Organization. *International Statistical Classification of Diseases and Related Health Problems 10th Revision. ICD-10 Version.* (2010). at <<http://apps.who.int/classifications/icd10/browse/2010/en>>

22. Porro, G., et al. A new behavioural visual field test for clinical use in pediatric neuro-ophthalmology. *Neuro-Ophthalmology* **19**, 205–214 (1998).
23. Fantz, R. Pattern vision in young children. *Psychol Rec.* **8**, 43–47 (1958).
24. Chalam, K., Ambati, B., Beaver, H. & et al. Basic and Clinical Science Course, Section 2: Fundamentals and Principles of Ophthalmology. *Am. Acad. Ophthalmol. Eye M.D. Assoc. 2011–2012*
25. Lavidor, M. & Walsh, V. The nature of foveal representation. *Nat. Rev. Neurosci.* **5**, 729–35 (2004).
26. Werth, R. Visual functions without the occipital lobe or after cerebral hemispherectomy in infancy. *Eur. J. Neurosci.* **24**, 2932–44 (2006).
27. Haak, K. V et al. Abnormal visual field maps in human cortex: A mini-review and a case report. *Cortex.* 1–12 (2012).
28. Vanburen, J. M. Trans-Synaptic Retrograde Degeneration in the Visual System of Primates. *J. Neurol. Neurosurg. Psychiatry* **26**, 402–9 (1963).
29. Herbin, M., Boire, D., Théoret, H. & Ptito, M. Transneuronal degeneration of retinal ganglion cells in early hemispherectomized monkeys. *Neuroreport* **10**, 1447–52 (1999).
30. DeJong, R. *The neurologic examination. 4th ed. Hagerstown (MD): Harper & Row.* (1979).
31. Leigh, R. & Zee, D. *No TitleThe neurology of eye movements. New York: Oxford University Press.* (2006).
32. Van Waveren, M., Jägle, H. & Besch, D. Management of strabismus with hemianopic visual field defects. *Graefes Arch. Clin. Exp. Ophthalmol.* (2012).
33. Herzau, V. How useful is anomalous correspondence? *Eye (Lond).* **10 ( Pt 2)**, 266–9 (1996).
34. Laeng, B. Lateralization of categorical and coordinate spatial functions: a study of unilateral stroke patients. *J. Cogn. Neurosci.* **6**, 189–203 (1994).
35. Marsolek, C. J. Abstract visual-form representations in the left cerebral hemisphere. *J. Exp. Psychol. Hum. Percept. Perform.* **21**, 375–86 (1995).
36. Kosslyn, S. M. Seeing and imagining in the cerebral hemispheres: a computational approach. *Psychol. Rev.* **94**, 148–75 (1987).





# 7

**Summary and general discussion**  
**Nederlandse samenvatting**

## SUMMARY

The aim of this thesis is to gain more insight in the diagnostic and prognostic implications of visual field (VF) examination in children with brain disorders. Several aspects of VF examination in children with brain disorders were evaluated.

As a general introduction, **Chapter 1** provides background information on the visual pathways of the brain and on several techniques to examine visual function in young or neurologically impaired children.

In **Chapter 2** we evaluated all VF examinations that were performed with the BEhavioral FIeld (BEFIE) screening test, a technique developed in 1995 by Porro et al.<sup>1</sup> in our center, to measure the peripheral VF of young and neurologically impaired children. We found that 74% of 1788 tests could be reliably performed, and reported increasing success with higher ages. VF defects were found in 28% of the reliably performed tests. Furthermore, results were consistent over time in 75% of the 304 children who underwent multiple reliable tests, with a positive relation between consistency and number of performed tests. When we compared BEFIE test results with standard conventional perimetry (SCP) performed in the same children later in time, a high positive predictive value and specificity of both 98% was found. The negative predictive value was 66% and the sensitivity 60%, which even increased to 80% when only absolute peripheral VF defects were accounted for. We concluded that the BEFIE test is a valuable tool to detect peripheral VF defects when SCP cannot be performed in young or neurologically impaired children.

In **Chapter 3** the possibility to predict VF defects based on neuroimaging of the anatomy of the brain at the age of 3 months was explored in infants after perinatal arterial ischemic stroke (PAIS). In 19 infants with unilateral PIAS, of whom eight turned out to have a VF defect at follow-up, we found that the presence or absence of the VF defect could be correctly predicted



in the majority of infants by both Magnetic Resonance Imaging (MRI) and Diffusion Tensor Imaging (DTI) of the optic radiation (OR) in the brain. This was objectified by a Receiver Operating Characteristic (ROC) analysis, which revealed an area under the curve (AUC) of 0.90 and 0.96 of MRI and DTI, respectively. Conventional MRI seems most suitable to use in clinical practice, since DTI requires a comprehensive analysis per individual while it added little to conventional MRI assessment. An accurate follow-up with multiple VF examinations is indicated especially in children with asymmetry of the OR.

In **Chapter 4** VF defects found in children suspected of intracranial pressure (ICP) elevation were evaluated. Our cohort of 192 children with suspicion of ICP increase revealed that VF defects in children with ICP elevation mainly consisted of blind spot enlargement, which had little additional value to the presence of (suspect) papilledema during fundoscopy performed earlier. Other types of VF defects were scarce in these children at presentation and also occurred in children with suspicion of ICP increase but who turned out to suffer from other pathology than ICP increase. However, in children with documented ICP elevation, the presence of VF defects or visual acuity (VA) impairment at presentation both related to VF defects at final examination. Therefore, we concluded that VF examination at presentation in children suspected of increased ICP does not differentiate between children with or without intracranial hypertension, but that it could provide arguments to start therapy and may help to predict final VF outcome in children with documented ICP increase.

In **Chapter 5** a systematic review of previous literature on the visual outcome of patients with the Sturge-Weber syndrome (SWS) and the results of a Dutch multicenter cohort are presented. SWS is a rare congenital disorder with angiomatous vascular malformations in the meninges, dermis and eye. SWS patients regularly suffer from a combination of vision impairing disorders such as glaucoma, a diffuse choroidal hemangioma (DCH), and a leptomeningeal angioma, which can lead to neurological deficits and epilepsy. Previous reports have described mainly either strictly ophthalmological or neurological findings, with consequent reporting of

## Chapter 7

either VA or VF outcomes. Our systematic review revealed that a homonymous hemianopia (HH) was present in 42% of SWS patients. Of all reported eyes from a general SWS population, 70% had a (near)normal vision, while VA of eyes affected with glaucoma or DCH was severely impaired in 28% and 67%, respectively. Our cohort of 33 Dutch SWS patients, in whom we specifically focused on the combination of VF and VA findings, revealed that only 18% of patients had (near)normal findings for both parameters, while half of patients with glaucoma suffer from a combination of a HH and VA impairment. We recommend adequate follow-up of both VA and VF in patients with SWS.

In **Chapter 6** the visual outcome and the prevalence of compensatory mechanisms (CMs) for HH are described in children who underwent hemispherectomy. Several previous case-reports described an anomalous head posture (AHP) and exotropia (XT) contralateral to the side of early brain damage, as possible CM for HH. In our cohort of 45 hemispherectomized children, we found that visual fixation was present in all children, 87% of the examined children had a normal VA or a mild visual impairment, and all tested children had a HH. Anomalous head posturing and continuous or intermittent XT contralateral to the side of hemispherectomy were observed in 53% and 38% of children, respectively. We found that the children with these CMs had more frequently right-sided surgery and earlier onset of epilepsy. Moreover, they were younger when they underwent hemispherectomy than children without CMs. We concluded that the majority of children who undergo hemispherectomy have a good visual outcome and frequently develop CMs which may optimize their functional VF.

## GENERAL DISCUSSION

Below, the most important themes of research described in this thesis are discussed and suggestions for future research are given.

### Visual field assessment

#### *Standard conventional perimetry*

Visual field (VF) examination in healthy children is possible from the age of 6 years using the Goldmann<sup>2,3</sup>, Peritest<sup>4</sup> and Frequency Doubling Technology (FDT)<sup>5,6</sup> perimetry or the fast programs on the Octopus<sup>3,7</sup> and Humphrey<sup>3,8</sup> VF examiners. If a child cooperates very well, performance of a standard conventional perimetry (SCP) method is preferred, because of its greater accuracy. However, VF examination in children with brain disorders is a major challenge because they are often not able to perform the most simple types of SCP.<sup>9</sup> Although the awareness of the importance of testing VF in this group of children among both pediatric neuro-ophthalmologists and neurologists increases and multiple alternative VF examination methods are being developed, all of them have their own limitations.

#### *Development of confrontational behavioral methods*

The well-known Donder's confrontational method<sup>10</sup>, often used as a standard part of neurological examination, was modified into a the more objective 'binocular directional preference' test, which can be performed using Stycar balls.<sup>11-13</sup> The advantage of the observation of the behavioral reaction of the child on the stimuli, brought into the VF from behind, instead of a patient being asked to tell if fingers were observed during Donder's confrontational testing, makes the 'binocular directional preference' test suitable for children, even those with neurological disabilities. The Double-arc<sup>14-16</sup> and Translucent sphere perimeter<sup>11,17</sup> made VF testing in children more sophisticated and less imprecise, by making use of a half-spherical shape and gradation to measure the peripheral VF extent. However, freedom of movement of the child is limited to perform a reliable test and the observer-child interaction, which is useful to moti-

## Chapter 7

vate a child to cooperate, is minimal. These methods were mostly confined to an experimental setting and rarely implemented in everyday clinical practice.

### *The BEFIE test*

The idea of the BEhavioral visual FIEld (BEFIE) screening test<sup>1,18</sup> arose from the existing confrontational behavioral VF examination methods, in an attempt to solve the limitations associated with those methods and to introduce VF examination of children in a clinical setting.<sup>9</sup> In 1998, the inventor Dr. G.L. Porro stated in his thesis *"An early assessment of the visual field in neuropediatric patients with the BEFIE test is better than no assessment at all"*.<sup>19</sup> By now, we have better insight in the diagnostic capabilities, the limitations as well as the clinical application of this method.<sup>18</sup> Infants seem to react unconsciously to the presented stimulus, while the test is also very well accepted by toddlers and older children, who consider it a play-like game. With the present study, the well-known inability of the BEFIE method to test the central VF or detect VF deficits such as scotomas (holes in the VF) and relative defects was confirmed. In fact, when compared with SCP performed on later age, we found that especially the positive predictive value (98%) and specificity (98%) of the BEFIE test were high. Although this finding might be biased by the probably "less impaired" population in which this comparison was made, this suggests that the test is especially useful to detect rather than to exclude peripheral VF defects. In addition, VF results obtained using this test proved consistent over time in the majority (75%) of children and deteriorations could generally be explained by progressive disease. The improvements of the VF in time observed in a minority of children might be explained by a previous false positive finding, physiological expansion of the VF, improved cooperation with age, or possible neuronal plasticity.

However, the generalization of these results to other clinical settings in other centers might be hampered by the performance of the BEFIE tests by one examiner, resulting in an unknown interobserver variability. In fact, results might be influenced by the learning curve of the examiner, since proper performance of the BEFIE method requires an appropriate training of both the examiner and the observer. Proper performance includes a smooth adequate execution,

effective communication between the examiner and the observer, but also a correct interpretation of the behavioral responses of the child, such as eye movements, finger pointing, verbal responses or rocking movements.<sup>20</sup> For example, the presence of a hemiparesis might be misleading in diagnosing an intact or impaired VF if only the pointing hand gestures are observed, since the child will be unable to point at the target on that side.

Regarding the clinical application, the current 21 years of experience illustrate that the BEFIE test, with its strength to detect peripheral VF defects in children from a very young age onwards, can be implemented in an everyday pediatric neuro-ophthalmological practice. If possible, and when it suits the conditions of the underlying disease, multiple testing is advised, in order to minimize false positive and negative findings with the BEFIE test. After performance of three measurements with intervals of approximately half a year, or shorter when necessary, possible age or mood dependent bias can be excluded and the child can get familiar with the test. This ensures a more secure assessment of VF outcome. When cooperation is sufficient, a VF examination using SCP should always be performed at later age as part of the follow-up, not only to confirm BEFIE results, but also to be informed about the central part of the VF.

#### *Eye-tracker methods*

Considering the need for new and reliable VF examination techniques in children several methods that make use of eye-trackers are under development.<sup>21-27</sup> Most of these methods are still being modified to improve their feasibility for application in the target group of young children. Since most eye-tracker-based VF examination methods measure, in contrast to confrontational behavioral methods, the central VF instead of the peripheral, and are sensitive to scotomas, we strongly believe that the combination of the BEFIE test and eye-tracker VF examination methods would be interesting in order to obtain a reliable impression of the entire spectrum of both central and peripheral VF abnormalities in children. Currently these eye-tracker methods are under development in order to optimize their diagnostic capabilities and to make them attractive enough for young or neurologically impaired children, with great potential for the near future. For instance, at the Bartiméus institute, our collaborating center

## Chapter 7

for diagnostics and rehabilitation of visually impaired patients, an eye-tracker program initially used to detect whether patients suffer from a VF defect as part of a simulation or conversion disorder, can nowadays also be used for examination of VF defects in children.<sup>25,27</sup>

### *Multifocal VEP*

Multifocal Visual Evoked Potential (mVEP) is described in the literature as a method to detect VF defects when SCP is not possible.<sup>28</sup> This electrophysiological method has mainly been applied to evaluate preoperative and postoperative VF defects in children undergoing epilepsy surgery,<sup>29,30</sup> and in children with epilepsy who use vigabatrin,<sup>31,32</sup> an antiepileptic drug which may induce a concentric VF defect as adverse effect. Although we have no experience with mVEP in our center, several articles have described its applicability in children. However, results should be interpreted with caution, since this method appeared not sensitive for VF defects caused by lesions in the extrastriate cortex, and consequently the VF measurement may not correspond to the real VF defect as would be measured with SCP.<sup>33</sup>

### *How to choose an appropriate method for VF examination in children?*

Pediatric neuro-ophthalmologists should consider several items when confronted with the clinical suspicion of a VF defect. Firstly, the child's mental and physical capabilities to perform standard perimetry should be taken into account. When considered possible, either kinetic or static perimetry can be chosen, based on the required cooperation and requested investigation time of different methods.

Secondly, the expected type of VF defects should be considered. For example, in children with brain disorders along the chiasma or the retrochiasmatic visual pathways, as in those suffering from perinatal arterial ischemic stroke (PAIS), Sturge-Weber syndrome (SWS) or candidates for epilepsy surgery (Chapter 3, 5 & 6), hemianopic VF defects can be expected. This type of VF defect can easily be objectified with both SCP or confrontational behavioral VF examination methods such as the BEFIE test, which measure the peripheral VF. On the contrary, for instance in children with (or suspected of) increased intracranial pressure (ICP), enlarged blind spots

may be expected (Chapter 4). This type of VF defect requires SCP to be detected. In this group of children, the BEFIE test is only useful in profound cases in which more severe VF defects are present. A similar problem arises in the VF examination of children with epilepsy who use vigabatrin. For early detection of toxicity of vigabatrin to the retina monocular VF examination is essential, because the VF defect that vigabatrin might cause starts nasally and expands to a concentric defect in later stage.<sup>34,35</sup> Unfortunately, young children do generally not easily accept patching for monocular VF investigation. So, it should be considered that binocular confrontational behavioral VF examination in these children is not conclusive, as it may underestimate of the vigabatrin related VF defect.

The main difference between VF measurement techniques in children lies in a kinetic or static execution. The perception of moving targets has another underlying mechanism than the perception of static targets and requires interpretation by different visual association areas.<sup>36</sup> Considering that both patients with cerebral visual impairment (CVI) and young children may show a greater sensitivity to observe moving than static targets, this might result in a larger VF extent observed with kinetic compared to static examination.<sup>16,37,38</sup> In addition, other factors, such as a manual execution by an examiner versus automatic computerized execution of the VF examination may influence results. Although manual VF testing is less objective and might introduce bias, it may aid the child's performance and improve the reliability of the test when a child has difficulties with the examination. Furthermore, varying target size, luminance and test algorithms are factors that may cause inequalities in results assessed with different methods.

When a choice for an appropriate VF examination method is made, it is important to continue the VF assessments in time using the same or a rather similar type of VF examination in order to ensure reliable follow-up of VF defects and to avoid discrepancies between methods. In our experience, the BEFIE method corresponds better with kinetic SCP (Goldmann VF examination) than with static perimetry. Since the 'reference' SCP used in Chapter 2 consisted not only of kinetic, but also of static perimetry methods, this may partly explain the differences found in the comparison with the BEFIE test.

*Influence of cognitive and perceptual visual functions on visual function assessment*

An important yet only partly elucidated aspect of the assessment of visual function (VA and VF) in neuro-ophthalmology, is how cognitive and perceptual visual functioning – *enabled by the visual association areas and the higher visual functioning pathways that are responsible for e.g. the different processing of kinetic and static targets* – may influence visual outcomes.<sup>36,39</sup> Beside possible focal damage to these areas and pathways, in children with cerebral injury, exhaustion, distraction and stress are easily provoked and may impair their cognitive and perceptual visual functioning, resulting in problems with e.g. recognition, orientation, handling complex visual scenes, visual guided movement or visual attention.<sup>39</sup> This might influence the child's visual function assessment of both VF and VA, and explains the fluctuating results that are often found when testing visual functions of neurologically impaired children. As an example, crowding, a phenomenon in which a child is unable to see a symbol surrounded by other symbols that crowd the VF, is regularly observed in VA testing in children with brain disorders.<sup>40</sup> Regarding the VF, an impairment of the visual association areas and the higher visual functioning pathways might play a role in the not yet fully understood phenomenon of blindsight.<sup>41,42</sup> This phenomenon, which is observed in few patients with a VF defect due to brain injury, is defined as unconscious perception of objects in the blind field that cannot be observed consciously.<sup>42</sup> Although most children in our studies were tested multiple times and we generally used the best measured outcome in the analyses, it remains unknown to what degree VF measurements were influenced by possibly impaired cognitive and perceptual visual functions.

**Prediction of visual field defects**

*Early prediction by means of neuroimaging*

The alternative perimetry methods for VF assessment in children described above, are not yet widely used. Therefore, early prediction of VF defects that are caused by acquired or developmental brain abnormalities by means of neuroimaging could be useful for academic centers in which only SCP can be performed. To visualize cortical areas and the white matter of visual



pathways, conventional T1 and T2 Magnetic Resonance Imaging (MRI) are generally used in daily clinical practice. However, more advanced MRI methods that enable assessment of functional activity or three-dimensional anatomy of the white matter may provide additional valuable information.

Diffusion Tensor Imaging (DTI) has many applications and can be used to study the integrity of the white matter globally for the whole brain or of specific tracts on anatomical locations.<sup>43</sup> Regarding prediction of visual outcome in infants, DTI literature mainly focused on the association of diffusion parameters at term age with visual function scores based on functions such as fixation, motility, tracking and VA, in premature infants.<sup>44-46</sup> The prediction of VF defects in infants with DTI has not been previously investigated.

In this thesis, we explored the possibility to predict VF defects based on three month MRI and DTI scans in infants after unilateral PAIS and we concluded that both techniques are useful in the prediction of their VF defects. However, MRI is most convenient since it is easier to perform in daily clinical practice. Although not all infants with optic radiation (OR) injury on neuroimaging develop VF defects, we recommended an accurate VF follow-up of children with OR asymmetry on MRI at three months of age, in order to ensure early diagnosis of VF defects and subsequent start of rehabilitation. In addition, since all infants in our study with a symmetrical OR had a normal VF, we suggested that there is no need for visual follow-up in the presence of a symmetrical OR. Obviously, it should not be overlooked that also injury to other areas in the brain responsible for visual functioning, such as the (extra)striate visual cortexes and pathways that serve higher visual functioning, may provoke VF defects in the presence of an symmetrical intact OR,<sup>47-49</sup> and that these children are also entitled to VF examination.

Although we concluded that both MRI and DTI are useful in the prediction of VF defects with comparable predictive values and recommend to use MRI in daily clinical practice, DTI still might play a role in specific cases. For instance, in subjects in whom qualitative conventional MRI assessment of the OR is inconclusive, more sophisticated techniques such as DTI, that provide quantitative data, might assist in predicting VF outcomes. In the few infants in our study

who had a mildly asymmetrical OR, the fractional anisotropy (FA) asymmetry index on DTI gave direction toward the final presence or absence of a VF defect. Though, larger cohorts are needed to confirm this finding. Moreover, DTI might be of additional value to MRI assessment in infants with bilateral brain damage. While asymmetry assessment of the OR on conventional MRI in these infants cannot be used, DTI may provide helpful quantitative data of the individual ORs. Though, the possible variation in outcomes due to individual differences in myelination of the OR should be taken into account.<sup>50</sup> Finally, DTI might be of potential value in predicting what kind of VF defect is present. Although both the qualitative conventional MRI assessment and the quantitative DTI measurements provided too little information to make distinction between incomplete or complete quadrantanopias or hemianopias (HHs) in our study, we found a correlation between the degree of asymmetry and the severity of the VF defect. Separate investigation of specific temporal or parietal parts of the OR with DTI, instead of analyzing the OR as a whole, could be a next step in order to achieve this goal.

### **Visual outcome in pediatric brain diseases**

#### *Difficulties in data collection*

Visual outcome in pediatric brain diseases is often incompletely investigated and reported for several reasons. First, children may be difficult to examine due to other deficits caused by their brain injury, such as severe epilepsy, motor dysfunction and developmental delay. Second, visual outcome might be regarded as relatively less important, compared to motor and cognitive outcome, or might be overlooked in the often complex combination of multiple disabilities.<sup>51–53</sup> Therefore, a multidisciplinary approach by a team of different specialists, such as a child-neurologist, pediatrician, ophthalmologist, orthoptist and physiotherapist is required, but might take effort to accomplish. This collaboration is especially essential in disorders in which both ocular and cerebral deficits that affect visual functioning are present. For instance, in the systematic review on visual outcome in patients with SWS (Chapter 5), who regularly suffer from a combination of glaucoma, a diffuse choroidal hemangioma (DCH) and cerebral

manifestations, we found that the ophthalmological literature was mainly confined to description of VA results, while neurological articles often only described VF outcomes. Nonetheless, it is in particular the combination of visual acuity (VA) and VF impairments that frequently invalidates the child with neuro-ophthalmological disorders. It should always be kept in mind that even in children in whom VA and ophthalmological investigations, including fundoscopy, appear to be normal, VF can be impaired (Chapter 3, 4, 5 & 6) and may cause problems in daily functioning.

Despite the growing incidence of neuro-ophthalmological disorders, most of these are still relatively rare, resulting in small research populations. Conduction of systematic reviews is therefore valuable to draw firmer conclusions, though distortion of results due to selection bias might easily occur when combining outcomes of various studies, and must be taken into account.

#### *Influence of visual field defects on functioning*

Early detection of visual impairment, including VF defects, is meaningful for optimal rehabilitation of the child, with an adjusted approach at daycare or school, in order to restrict the serious consequences it can have on the child's functioning, by affecting motor, emotional, social and psychological development<sup>14,54-57</sup> The exact relation between VF defects and functioning of the child is difficult to investigate, since they frequently suffer from other associated neurological disabilities, such as motor and cognitive impairment, which also influence their functional outcome. In addition, cognitive impairment can make a reliable assessment of the functional outcome, by means of questionnaires, impossible.<sup>58</sup> In fact, although questionnaires can be completed by a proxy when children are too young to do so themselves, the population of children with VF defects is too heterogeneous to be assessed with the same investigative instrument. While the cognitively normal functioning children can be tested with validated questionnaires that are widely used, these instruments are not validated, and therefore less useful, in children with cognitive impairment.

**Box 1. Quality of life and functioning in children and adults with homonymous hemianopia diagnosed in childhood**

Yvonne Koenraads, Giorgio L. Porro, Saskia M. Imhof, Kees P.J. Braun

*Purpose:* Homonymous hemianopia (HH) may have impact on health related quality of life (HRQoL) and functioning, which requires adequate coping. However, literature on the influence of HH on the life of children is lacking. Aim of this study was to investigate the functional outcome of children and adults with HH diagnosed in childhood.

*Methods:* Sixty-one patients (median age 15.0, range 4.3-31.5 yrs), and their caregivers, who were diagnosed with HH before the age of 18 yrs in our center between 1995 and 2014, participated in this study. Questionnaires measuring HRQoL (children: KIDSCREEN-27, adults: SF-36), participation (children: CASP, adults: D-AI2 mobility), symptoms of cerebral visual impairment (CVI-checklist) and additional open questions about the consequences of HH were evaluated. For the analysis, patients were classified in three groups: one group of patients with normal cognition (IQ  $\geq$ 70 or following mainstream education) and normal motor function (NCNM, n=9), a second group of patients with normal cognition and an impaired motor function (NCIM, n=15), and a third and largest group of patients with an impaired cognition (IC, n=37).

*Results:* Nearly all HRQoL domains, of both children and adults with normal cognition, revealed median values in the normal range. In children, there were no major differences between the NCNM and NCIM group, while almost all median scores in adults were lower in the NCIM group than in the NCNM group, of which scores on the domains 'physical functioning' ( $p=0.004$ ), 'general health' ( $p=0.05$ ) and the 'physical component summary' ( $p=0.01$ ) were significantly lower (Mann-Whitney U test). Also regarding participation, both children and adults had relatively normal median scores. Although median participation was

worse in the NCIM than the NCNM group on almost all domains in both children and adults, differences were not significant. At the CVI-checklist, median scores on both dorsal and ventral stream functioning were approximately equally distributed among all three groups. However, dorsal stream functioning was more impaired than the functions of the ventral stream ( $p < 0.001$ , Mann-Whitney U test). Disturbing consequences of the HH listed most frequently included unsafe participation in traffic, bumping into objects, scare & anxiety, orientation & overview and reading difficulties.

*Discussion:* The majority of patients with HH diagnosed in childhood suffer from additional motor or cognitive impairment. This hampers the investigation of the separate impact of HH on functioning. Furthermore, HRQoL and participation questionnaires are not validated for patients with intellectual disability, the largest group in our HH cohort. Although the number of patients with normal cognition was limited, most HRQoL and participation scores were within the normal range, and lower scores in physical domains were mostly explained by impaired motor functioning. There clearly is a need for adequate instruments to investigate HRQoL and participation in children with developmental delay. To establish the independent contribution of HH to the functional outcome of children with or without motor or intellectual impairment, studies should compare patients with and those without HH.

During our attempt to investigate the functional outcome of patients with a HH diagnosed in childhood (before the age of 18 years), we were hampered by the fact that a large proportion of hemianopic patients also had a developmental delay or motor deficits (see Box 1). When excluding patients with cognitive impairment, we were able to compare two groups of children with relatively normal cognitive functioning, those with and without motor dysfunction. Although the number of patients was too low to draw definite conclusions, most health-related quality of life (HRQoL) and participation scores were in the normal range, while lower scores in physical domains were mostly explained by impaired motor functioning. However, it should be considered that patients with brain disorders, and their caregivers, may fill out the ques-

tionnaires from a different perspective than a normal population.<sup>59</sup> Moreover, although the instruments that were applied are properly validated and widely used, maybe they were not sensitive enough for specific disturbances caused by HH.<sup>60-67</sup> When looking at the responses obtained, consequences of the HH that were considered most disturbing included unsafe participation in traffic, bumping into objects, scare & anxiety, orientation & overview and reading difficulties. However, some participants stated that there were no impediments of the HH, or that these were considered unimportant compared to other disabilities. Regardless of this consideration, the actual importance of the VF for a mentally disabled, often wheelchair dependent, child is still unknown. The impression that visual functioning is less important in the presence of more evident motor and cognitive disorders does not mean that VF defects in these children deserve no attention. For instance, visual capability of some multi-handicapped children might be the only possible way to communicate.<sup>68</sup>

*Functional visual field, compensation and plasticity*

Sometimes functional visual capacities improve by compensation or restoration of visual impairment.<sup>69-71</sup> Compensation might be achieved by physical adaptations such as an anomalous head posture (AHP)<sup>14,72-75</sup> and exotropia (XT)<sup>14,73,76-81</sup> contralateral to the side of brain damage. Although we did not objectify the actual optimization of the VF in this thesis, we found that children who underwent hemispherectomy, and therefore all had a HH, regularly showed such compensatory mechanisms (CMs).<sup>69</sup> An AHP can center the VF and enables efficient scanning of the surroundings, while an XT enables a broader 'panoramic' view.

Several case-reports and series already demonstrated the beneficial use of these physical adaptations, but the underlying mechanism of these 'CMs' is still unknown. The association with right sided brain injury suggests that there might be a relation to lateralized cognitive functions present in one of the two hemispheres, such as visual recognition, navigation, tracking, and imagery.<sup>82-84</sup> In addition, the association with an earlier onset of epilepsy and the tendency towards early hemispherectomy in children developing CMs, suggests that especially the developing infant brain enables such adaptations.<sup>69,85</sup> Preference of use of the peripheral

VF above using central vision (VA) by children with, mostly severe, CVI could also play an important role.<sup>14,86</sup> It might explain why the AHP is especially observed during tasks that require proper visual fixation and it is mostly activated while scanning the environment for targets positioned far away.<sup>69</sup>

Regarding the origin of the XT, several theories have been proposed. It might develop as a consequence of neurologic injury,<sup>14,87</sup> or relate to the original function of the nasal and temporal retinal functions,<sup>88,89</sup> while other authors stated that it might arise as CM to expand the functional VF.<sup>73</sup> We speculate that these children somehow prefer the expansion of the functional VF by means of contralateral XT above normal ocular alignment, possibly due to their preference for use of the peripheral VF instead of central vision,<sup>14,86</sup> similar to what a chameleon does to improve its survival chances.

Regardless of the underlying origin, children with a homonymous VF defect and XT frequently suffer from recurrence of XT after strabismus surgery. Together with the probable beneficial function of the XT for the functional VF, we consider the presence of HH a contraindication for strabismus surgery in these patients.

Improvement of functional visual capacities by restoration of visual impairment is also known as neuronal plasticity.<sup>70,71</sup> It might play a role in improving VF results,<sup>47</sup> as has been suggested in the case-reports by Seghier et al.<sup>90</sup> and Groenendaal et al.<sup>91</sup> Mechanisms of neuronal plasticity that have been described include formation of new interhemispheric connections, reorganization in nearby unaffected cortex or changes in functional interaction between higher-level visual cortical areas and the primary visual areas.<sup>92</sup> Neuronal plasticity mainly occurs in the developing brain and might therefore especially be present in congenital disorders that have an effect on the VF in very early stage.<sup>70,85,93</sup>

Using functional MRI (fMRI) in a patient who was born with only one cerebral hemisphere, which is associated with HH, we demonstrated the presence of receptive fields of the bilateral retina in the early visual cortex (see Box 2). This indicates reorganization of intra-cortical wiring of the early visual cortex and confirms neuronal plasticity and reorganization after early brain injury in humans.

**Box 2. Bilateral population receptive fields in congenital hemihydranencephaly**

Alessio Fracasso, Yvonne Koenraads, Giorgio L. Porro, Serge O. Dumoulin  
*Accepted for publication in Ophthalmic and Physiological Optics*

*Purpose:* Congenital hemihydranencephaly is a very rare disorder characterized by prenatal near-complete unilateral loss of the cerebral cortex. We investigated a patient affected by congenital right hemihydranencephaly whose visual field extended significantly into the both visual hemifields, suggesting a reorganization of the remaining left visual hemisphere. We examined the early visual cortex reorganization using functional MRI (7T) and population receptive field (pRF) modeling.

*Methods:* Data were acquired by means of a 7T MRI (Phillips, Best, Netherlands) while the patient affected by hemihydranencephaly viewed conventional population receptive field mapping stimuli. Two possible pRF reorganization schemes were evaluated: where every cortical location processed information from either (i) a single region of the visual field or (ii) from two bilateral regions of the visual field.

*Results:* In the patient affected by hemihydranencephaly, bilateral pRFs in single cortical locations of the remaining hemisphere were found. In addition, using this specific pRF reorganization scheme, the biologically known relationship between pRF size and eccentricity was found.

*Conclusions:* Bilateral pRFs were found in the remaining left hemisphere of the patient affected by hemihydranencephaly, indicating reorganization of intra-cortical wiring of the early visual cortex and confirming brain plasticity and reorganization after an early cerebral damage in humans.



## Future developments

### *Development of visual field examination techniques*

Innovative VF examination methods, such as confrontational behavioral and eye-tracker methods, are being developed to suit VF testing in young and neurologically impaired children.<sup>94</sup> By combining and modifying these existing techniques, the feasibility and accuracy will improve, while limitations will be covered. Essential in this development is a fast, attractive, accepted, play-like and objective measurement that can be performed without distraction of the child by other factors.

Possibly, in addition to these methods, there will be place for objective VF measurements by means of pupillometry or pupillography.<sup>95–98</sup> Such a method is currently being developed and investigated in adult patients in several centers.<sup>96,98</sup> If this technique proves to be valuable, it may have a potential applicability in (neurologically impaired) children.

### *Development of neuroimaging of the visual system*

In the meantime, improving neuroimaging techniques that make use of measuring diffusion, functional activation or connective networks in the brain are potentially useful for objective VF examination.<sup>99,100</sup> At present, DTI tractography already enables identification of (1) fibers that connect brain areas and (2) retinotopic organization of fibers in the splenium, used in higher visual integration, in adults.<sup>99</sup> The methods of measuring diffusion still improve by an increasing spatial resolution of the diffusion-weighted data.<sup>101</sup> In addition, the tractography algorithms, that trace connections, become more sophisticated. fMRI already enables retinotopic mapping in adults, which represents the correspondence between the VF and its cortical representation in the brain.<sup>99,100</sup> Information on fMRI field maps can also be combined with data from electro-encephalography (EEG), magneto-encephalography (MEG) or implanted subdural grid electrodes (electro-corticography) in order to clarify spatial locations of the neural signals.<sup>99</sup> However, since these methods are either time consuming or invasive, they are less suitable for application in children. Although the received signals by the visual cortex cannot confirm actual functional perception, these neuroimaging methods may be more objective

than the current standard VF examination methods.

Beside using one single technique, especially the combination of several techniques might improve our understanding of the visual system by connecting the various aspects that can be measured. Possibly, in the future these techniques may objectively predict or diagnose not only the presence, but also the location and type of VF defects in children. In addition, though neuronal plasticity might occur in a selection of patients and will complicate accurate prediction, these neuroimaging techniques could also be able to reveal the still unknown underlying mechanisms of plasticity.<sup>93</sup>

### **Clinical implications of the findings described in this thesis**

The BEhavioral visual Field (BEFIE) screening test can be reliably performed in most children who are too young or neurologically impaired to perform standard conventional perimetry (SCP), and is particularly valuable in the detection of peripheral visual field (VF) defects. Therefore, the BEFIE test should be performed in young children with (suspected) visual pathway pathology in order to allow early detection and quantification of peripheral VF abnormalities that would otherwise remain unnoticed.

Assessment of asymmetry of the optic radiation (OR) on both conventional MRI and DTI-based tractography at three months of age can be used to predict VF defects after unilateral perinatal arterial ischemic stroke (PAIS) with comparable predictive values.

VF examination by means of SCP in children with the clinical suspicion of increased intracranial pressure (ICP) does not differentiate between children with and those without intracranial hypertension. In children with ICP elevation, SCP can provide arguments to start therapy and help to predict final VF outcome.

In Sturge-Weber syndrome (SWS) patients, a homonymous VF defect (42%) and visual acuity (VA) impairment (30%) regularly occurs. The combination of these two visual parameters is

rarely described in the literature. With the Dutch multicenter cohort we demonstrated and emphasized the combined functional impairments, that may especially be invalidating.

Despite having a homonymous hemianopia (HH), the majority of children who undergo hemispherectomy have a good visual outcome and frequently develop an anomalous head posture (AHP) and continuous or intermittent exotropia (XT) contralateral to the hemispherectomy, which are considered compensatory mechanisms (CMs) that may optimize their functional VF. The presence of these CMs should discourage surgical correction of XT in children with HH.

The diagnostic and prognostic clinical implications described in this thesis contribute to the awareness of cerebral visual impairment (CVI) and its clinical consequences, such as the importance of VF examination, for children with brain disorders.

## REFERENCES

1. Porro, G., et al. A new behavioural visual field test for clinical use in pediatric neuro-ophthalmology. *Neuro-Ophthalmology* **19**, 205–214 (1998).
2. Kolling, G. H. & Wabbels, B. Symposium Proceedings Part II Kinetic perimetry in neuroophthalmological practice. **8**, (2000).
3. Patel, D. E. *et al.* Study of optimal perimetric testing in children (OPTIC): Feasibility, reliability and repeatability of perimetry in children. *PLoS One* **10**, 1–12 (2015).
4. Greve, E. L., Dannheim, F. & Bakker, D. The Peritest, a new automatic and semi-automatic perimeter. *Int. Ophthalmol.* **5**, 201–14 (1982).
5. Blumenthal, E. Z., Haddad, A., Horani, A. & Anteby, I. The reliability of frequency-doubling perimetry in young children. *Ophthalmology* **111**, 435–9 (2004).
6. Quinn, L. M., Gardiner, S. K., Wheeler, D. T., Newkirk, M. & Johnson, C. a. Frequency doubling technology perimetry in normal children. *Am. J. Ophthalmol.* **142**, 983–9 (2006).
7. Safran, a B. *et al.* Feasibility of automated visual field examination in children between 5 and 8 years of age. *Br J Ophthalmol* **80**, 515–518 (1996).
8. Donahue, S. P. & Porter, a. SITA visual field testing in children. *J. AAPOS* **5**, 114–7 (2001).
9. Porro, G. L. & Wittebol-Post, D. Impairment of peripheral vision and its measurement. Chapter 5 in: Visual impairment in children due to damage to the brain (Edited by G.N. Dutton & M. Bax). *Clin. Dev. Med. No. 186. Mac Keith Press* (2010).
10. Stilma, J. S. & Voorn, T. B. in *Praktische huis-artseneeskunde: Oogheekunde* 40–43 (2002).
11. Mohn, G. & Van Hof-van Duin, J. Behavioural and electrophysiological measures of visual functions in children with neurological disorders. *Behav. Brain Res.* **10**, 177–87 (1983).
12. Hermans, A., Van Hof-van Duin, J. & Oude-sluyts-Murphy, A. Visual outcome of low-birth-weight infants (1500–2500 g) at one year of corrected age. *Acta Paediatr.* **83**, 402–7 (1994).
13. Sheridan MD. The STYCAR graded-balls vision test. *Dev Med Child Neurol.* **15**, 423–32 (1973).
14. Good, W. V *et al.* Cortical visual impairment in children. *Surv. Ophthalmol.* **1738**, 351–364 (1994).
15. Quinn, G. E. *et al.* Visual Fields Measured with Double-arc Perimetry in Eyes with Threshold Retinopathy of Prematurity from the Cryotherapy for Retinopathy of Prematurity Trial. *Ophthalmology* **103**, 1432–1437 (1996).
16. Dobson, V., Brown, a M., Harvey, E. M. & Narter, D. B. Visual field extent in children 3.5–30 months of age tested with a double-arc LED perimeter. *Vision Res.* **38**, 2743–60 (1998).
17. Mayer, D. L., Fulton, a B. & Cummings, M. F. Visual fields of infants assessed with a new perimetric technique. *Invest. Ophthalmol. Vis. Sci.* **29**, 452–9 (1988).
18. Koenraads, Y., Braun, K. P. J., van der Linden, D. C. P., Imhof, S. M. & Porro, G. L. Perimetry in Young and Neurologically Impaired Children: The Behavioral Visual Field (BEFIE) Screening Test Revisited. *JAMA Ophthalmol.* **133**, 319–25 (2015).
19. Porro, G. L. Vision and Visual Behaviour in Responsive and Unresponsive Neurologically Impaired Children. *Thesis* (1998).
20. Porro, G. *et al.* Visual behaviours of neurologically impaired children with cerebral visual impairment: an ethological study. *Br. J. Ophthalmol.* **82**, 1231–1235 (1998).
21. Murray, I. C. *et al.* Feasibility of saccadic vector optokinetic perimetry: a method of automated static perimetry for children using eye tracking. *Ophthalmology* **116**, 2017–26 (2009).
22. Murray, I. *et al.* Saccadic Vector Optokinetic Perimetry (SVOP): A novel technique for automated static perimetry in children using eye tracking. *Conf Proc IEEE Eng Med Biol Soc.* **2013**, 3186–9 (2013).

23. Allen, L. E., Slater, M. E., Proffitt, R. V., Quarton, E. & Pelah, A. A new perimeter using the preferential looking response to assess peripheral visual fields in young and developmentally delayed children. *J. AAPOS* **16**, 261–5 (2012).
24. Pel, J. J. M., van Beijsterveld, M. C. M., The-pass, G. & van der Steen, J. Validity and Repeatability of Saccadic Response Times Across the Visual Field in Eye Movement Perimetry. *Transl. Vis. Sci. Technol.* **2**, 3 (2013).
25. De Wit, G. Bartimeus eyetracker project. at <<https://www.bartimeus.nl/expertise/projecten/projectresultaten/project-eyetracker>>
26. Tailor, V. *et al.* Saccadic vector optokinetic perimetry in neuro-disability or isolated visual pathway lesions: observational cohort study. *Under Rev.* 1–6 (2016).
27. Wit, G. C. de, Hoeben, F. & Genderen, M. van. Objectieve gezichtsveldbepaling bij verdenking conversie met behulp van eye-tracking. *NOG Congr. Groningen* (2015).
28. Yukawa, E., Matsuura, T., Kim, Y.-J., Taketani, F. & Hara, Y. Usefulness of multifocal VEP in a child requiring perimetry. *Pediatr. Neurol.* **38**, 360–2 (2008).
29. Kim, Y.-J., Yukawa, E., Kawasaki, K., Nakase, H. & Sakaki, T. Use of multifocal visual evoked potential tests in the objective evaluation of the visual field in pediatric epilepsy surgery. *J. Neurosurg.* **104**, 160–5 (2006).
30. Yukawa, E., Kim, Y.-J., Kawasaki, K., Taketani, F. & Hara, Y. A child with epilepsy in whom multifocal VEPs facilitated the objective measurement of the visual field. *Epilepsia* **46**, 577–9 (2005).
31. Harding, G. F. a, Spencer, E. L., Wild, J. M., Conway, M. & Bohn, R. L. Field-specific visual-evoked potentials: identifying field defects in vigabatrin-treated children. *Neurology* **58**, 1261–5 (2002).
32. Spencer, E. L. & Harding, G. F. a. Examining visual field defects in the paediatric population exposed to vigabatrin. *Doc. Ophthalmol.* **107**, 281–7 (2003).
33. Klistorner, a I., Graham, S. L., Grigg, J. & Balachandran, C. Objective perimetry using the multifocal visual evoked potential in central visual pathway lesions. *Br. J. Ophthalmol.* **89**, 739–44 (2005).
34. James Willmore, L., Abelson, M. B., Ben-Menachem, E., Pellock, J. M. & Donald Shields, W. Vigabatrin: 2008 Update. *Epilepsia* **50**, 163–173 (2009).
35. Kedar, S., Ghate, D. & Corbett, J. J. Visual fields in neuro-ophthalmology. *Indian J. Ophthalmol.* **59**, 103–9 (2011).
36. Suter, P. S. & Harvey, L. H. Vision Rehabilitation: Multidisciplinary Care of the Patient Following Brain Injury. Taylor & Francis Group, LLC. CRC Press. (2011).
37. Delaney, S. M. *et al.* Stimulus Motion Increases Measured Visual Field Extent in Children 3.5 to 30 Months of Age. *Optom. Vis. Sci.* **77**, 82–89 (2000).
38. Roman-Lantzy, C. Cortical Visual Impairment: An Approach to Assessment and Intervention. *AFB Press. Am. Found. Blind. 11 Penn Plaza, Suite 300, New York* 23–24 (2007).
39. Dutton, G. N., Macdonald, E., Drummond, S. R., Saidkasimova, S. & Mitchell, K. Clinical features of perceptual and cognitive visual impairment in children with brain damage of early onset. Chapter 7 in: Visual impairment in children due to damage to the brain (Edited by G.N. Dutton & M. Bax). *Clin. Dev. Med. No. 186. Mac Keith Press* (2010).
40. Good, W. V, Jan, J. E., Burden, S. K., Skoczinski, A. & Candy, R. Recent advances in cortical visual impairment. *Dev. Med. Child Neurol.* **43**, 56–60 (2001).
41. Boyle, N. J., Jones, D. H., Hamilton, R., Spowart, K. M. & Dutton, G. N. Blindsight in children: does it exist and can it be used to help the child? Observations on a case series. *Dev. Med. Child Neurol.* **47**, 699–702 (2005).
42. Cooper, S. A. & O'Sullivan, M. Here, there and everywhere: higher visual function and the dorsal visual stream. *Pract. Neurol. practneurol–2015–001168* (2016).
43. Feldman, H. M., Yeatman, J. D., Lee, E. S., Barde, L. H. F. & Gaman-bean, S. Diffusion Tensor Imaging : A Review for Pediatric Researchers and Clinicians. *J Dev Behav Pediatr.* **31**, 346–56 (2010).

## Chapter 7

44. Bassi, L. *et al.* Probabilistic diffusion tractography of the optic radiations and visual function in preterm infants at term equivalent age. *Brain* **131**, 573–82 (2008).
45. Groppo, M. *et al.* Development of the optic radiations and visual function after premature birth. *Cortex* **56**, 30–7 (2014).
46. Berman, J. I. *et al.* Quantitative fiber tracking analysis of the optic radiation correlated with visual performance in premature newborns. *AJNR. Am. J. Neuroradiol.* **30**, 120–4 (2009).
47. Van der Aa, N. E. *et al.* Neonatal posterior cerebral artery stroke: clinical presentation, MRI findings, and outcome. *Dev. Med. Child Neurol.* **55**, 283–90 (2013).
48. Guzzetta, A. *et al.* Visual function in children with hemiplegia in the first years of life. *Dev. Med. Child Neurol.* **43**, 321–329 (2001).
49. Mercuri, E. *et al.* Visual outcome in children with congenital hemiplegia: correlation with MRI findings. *Neuropediatrics* **27**, 184–8 (1996).
50. Iai, M., Yamamura, T. & Takashima, S. Early Expression of Proteolipid Protein in Human Fetal and Infantile Cerebrum. *Pediatr Neurol* **17**, 235–239 (1997).
51. Dutton, G. & Bax, M. Visual impairment in children due to damage to the brain. *Clin. Dev. Med. No. 186. Mac Keith Press* (2010).
52. Philip, S. S. & Dutton, G. N. Identifying and characterising cerebral visual impairment in children: a review. *Clin. Exp. Optom.* **97**, 196–208 (2014).
53. Harbert, M. J., Yeh-Nayre, L. a, O'Halloran, H. S., Levy, M. L. & Crawford, J. R. Unrecognized visual field deficits in children with primary central nervous system brain tumors. *J. Neurooncol.* **107**, 545–9 (2012).
54. Van Hof-van Duin, J., Bertucceii, B., Fazzi, B. & Maris, S. Visual outcome at 5 years ' of newborn infants at risk of cerebral visual impairment. *Dev. Med. Child Neurol.* **40**, 302–309 (1998).
55. Dale, N. & Salt, A. Early support developmental journal for children with visual impairment: the case for a new developmental framework for early intervention. *Child. Care. Health Dev.* **33**, 684–90 (2007).
56. Fazzi, E., Signorini, S. G. & Lanners, J. The effect of impaired vision on development. Chapter 9 in: Visual impairment in children due to damage to the brain (Edited by G.N. Dutton & M. Bax). *Clin. Dev. Med. No. 186. Mac Keith Press* (2010).
57. Buultjens, M., Hyvarinen, L., Walthes, R. & Dutton, G. N. Strategies to support the development and learning of children with cerebral visual impairment at home and at school: communication, orientation, and mobility. Chapter 15 in: Visual impairment in children due to damage to the brain (Edited by G.N. Dutton . *Clin. Dev. Med. No. 186. Mac Keith Press* (2010).
58. Evenhuis, H. M. Children with intellectual disabilities and cerebral visual impairment: Problems with detection and diagnosis. Chapter 13 in: Visual impairment in children due to damage to the brain (Edited by G.N. Dutton & M. Bax). *Clin. Dev. Med. No. 186. Mac Keith Press* (2010).
59. Schooneveld, M. van. Development after epilepsy surgery in children. *Thesis* (2016).
60. Ravens-Sieberer, U. *et al.* The KIDSCREEN-27 quality of life measure for children and adolescents: psychometric results from a cross-cultural survey in 13 European countries. *Qual. Life Res.* **16**, 1347–1356 (2007).
61. Teunissen, M. *et al.* Quality of life and behavioral functioning in Dutch pediatric patients with hereditary spherocytosis. *Eur. J. Pediatr.* **173**, 1217–23 (2014).
62. Gutter, T., Brouwer, O. F. & de Weerd, a W. Subjective sleep disturbances in children with partial epilepsy and their effects on quality of life. *Epilepsy Behav.* **28**, 481–8 (2013).
63. Van der Heijden, P. G. M., van Buuren, S., Fekkes, M., Radder, J. & Verrips, E. Unidimensionality and reliability under Mokken scaling of the Dutch language version of the SF-36. *Qual. Life Res.* **12**, 189–98 (2003).
64. Aaronson, N. K. *et al.* Translation, validation, and norming of the Dutch language version of the SF-36

- Health Survey in community and chronic disease populations. *J. Clin. Epidemiol.* **51**, 1055–1068 (1998).
65. De Kloet, A. J. *et al.* Psychometric evaluation of the Dutch language version of the Child and Family Follow-up Survey. *Dev. Neurorehabil.* **18**, 357–64 (2015).
66. Bruijning, J. E., van Nispen, R. M. & van Rens, G. H. Feasibility of the Dutch ICF Activity Inventory: a pilot study. *BMC Health Serv. Res.* **10**, 318 (2010).
67. Bruijning, J., Rens, G. van, Knol, D. & Nispen, R. van. Psychometric Analyses to Improve the Dutch ICF Activity Inventory. *Optom. Vis. Sci.* **90**, 806–819 (2013).
68. Sargent, J., Salt, A. & Dale, N. Children with severe brain damage: Functional assessment for diagnosis and intervention. Chapter 11 in: Visual impairment in children due to damage to the brain (Edited by G.N. Dutton & M. Bax). *Clin. Dev. Med. No. 186. Mac Keith Press* (2010).
69. Koenraads, Y. *et al.* Visual function and compensatory mechanisms for hemianopia after hemispherectomy in children. *Epilepsia* **55**, 909–917 (2014).
70. Guzzetta, A. *et al.* Plasticity of the visual system after early brain damage. *Dev. Med. Child Neurol.* **52**, 891–900 (2010).
71. Guzzetta, A., Fiori, S., Scelfo, D., Conti, E. & Bancale, A. Reorganization of visual fields after periventricular haemorrhagic infarction: potentials and limitations. *Dev. Med. Child Neurol.* **55 Suppl 4**, 23–6 (2013).
72. Paysse, E. A. & Coats, D. K. Anomalous Head Posture With Early-Onset. *J AAPOS* **1**, 209–13 (1997).
73. Donahue, S. P. & Haun, A. K. Exotropia and face turn in children with homonymous hemianopia. *J. Neuroophthalmol.* **27**, 304–7 (2007).
74. Zangemeister, W. H., Meienberg, O., Stark, L. & Hoyt, W. F. Eye-head coordination in homonymous hemianopia. *J. Neurol.* **226**, 243–54 (1982).
75. Porro, G., van der Linden, D., van Nieuwenhuizen, O. & Wittebol-Post, D. Role of visual dysfunction in postural control in children with cerebral palsy. *Neural Plast.* **12**, 205–10; discussion 263–72 (2005).
76. Jacobson, L., Lennartsson, F., Pansell, T., Oqvist Seimyr, G. & Martin, L. Mechanisms compensating for visual field restriction in adolescents with damage to the retro-geniculate visual system. *Eye (Lond).* **26**, 1437–45 (2012).
77. Herzau, V., Bleher, I. & Joos-kratsch, E. Infantile exotropia with homonymous hemianopia : a rare contraindication for strabismus surgery. *Graefe 's Arch. Ophthalmol.* **1**, 148–149 (1988).
78. Levy, Y., Turetz, J., Krakowski, D., Hartmann, B. & Nemet, P. Development of compensating exotropia with anomalous retinal correspondence after early infancy in congenital homonymous hemianopia. *J Pediatr Ophthalmol Strabismus* **3**, 236–238 (1995).
79. Saleh, G., Sivaprasad, S. & Hammond, C. Homonymous hemianopia and exotropia: an important management issue. *Eye (Lond).* **20**, 1402–1404 (2006).
80. Gote, H., Gregersen, E. & Rindziunski, E. Exotropia and panoramic vision compensating for an occult congenital homonymous hemianopia. A case report. *Binoc. Vis. Eye Muscle Surg Q* **8**, 129–132 (1993).
81. Gamio, S. & Melek, N. When the patient says no. Management of exotropia with hemianopic visual field defects. *Binocul Vis Strabismus Q* **18**, 167–170 (2003).
82. Laeng, B. Lateralization of categorical and coordinate spatial functions: a study of unilateral stroke patients. *J. Cogn. Neurosci.* **6**, 189–203 (1994).
83. Marsolek, C. J. Abstract visual-form representations in the left cerebral hemisphere. *J. Exp. Psychol. Hum. Percept. Perform.* **21**, 375–86 (1995).
84. Kosslyn, S. M. Seeing and imagining in the cerebral hemispheres: a computational approach. *Psychol. Rev.* **94**, 148–75 (1987).
85. Nelson, K. B. & Lynch, J. K. Stroke in newborn infants. *Lancet Neurol* **3**, 150–158 (2004).
86. Baker-nobles, L. & Rutherford, A. Understanding Cortical Visual Impairment in Children. *Am. J. Occup. Ther.* **49**, 899–903 (1995).

## Chapter 7

87. Ten Tusscher, M. P. A neural model for cyclovertical eye movements and their disorders. *Strabismus* **19**, 162–5 (2011).
88. Ten Tusscher, M. Darwin en de retina. Nasale en temporale retina functioneel verschillend. *Congr. 204e Jaarvergadering NOG*. (2010).
89. Ten Tusscher, M. P. M. Does dominance of crossing retinal ganglion cells make the eyes cross? The temporal retina in the origin of infantile esotropia – a neuroanatomical and evolutionary analysis. *Acta Ophthalmol.* **92**, e419–23 (2014).
90. Seghier, M. L. *et al.* Visual recovery after perinatal stroke evidenced by functional and diffusion MRI: case report. *BMC Neurol.* **5**, 17 (2005).
91. Groenendaal, F. & van Hof-van Duin, J. Partial visual recovery in two fullterm infants after perinatal hypoxia. *Neuropediatrics* **21**, 76–8 (1990).
92. Urbanski, M., Coubard, O. a & Bourlon, C. Visualizing the blind brain: brain imaging of visual field defects from early recovery to rehabilitation techniques. *Front. Integr. Neurosci.* **8**, 74 (2014).
93. Hoffmann, M. B. & Dumoulin, S. O. Congenital visual pathway abnormalities: a window onto cortical stability and plasticity. *Trends Neurosci.* **38**, 55–65 (2015).
94. Koenraads, Y. Visual field examination in children with brain disorders (general introduction). *Thesis* (2016).
95. Carle, C. F., Maddess, T. & James, A. C. Contraction anisocoria: Segregation, summation, and saturation in the pupillary pathway. *Investig. Ophthalmol. Vis. Sci.* **52**, 2365–2371 (2011).
96. Carle, C. F., James, A. C., Kolic, M., Loh, Y.-W. & Maddess, T. High-resolution multifocal pupillographic objective perimetry in glaucoma. *Invest. Ophthalmol. Vis. Sci.* **52**, 604–10 (2011).
97. Maddess, T. *et al.* Multifocal pupillographic perimetry with white and colored stimuli. *J. Glaucoma* **20**, 336–343 (2011).
98. Maddess, T., Bedford, S. M., Goh, X. L. & James, A. C. Multifocal pupillographic visual field testing in glaucoma. *Clin. Exp. Ophthalmol.* **37**, 678–686 (2009).
99. Wandell, B. a & Winawer, J. Imaging retinotopic maps in the human brain. *Vision Res.* **51**, 718–37 (2011).
100. Raz, N. & Levin, N. Cortical and white matter mapping in the visual system—more than meets the eye: on the importance of functional imaging to understand visual system pathologies. *Front. Integr. Neurosci.* **8**, 1–11 (2014).
101. Tuch, D. S. *et al.* High angular resolution diffusion imaging reveals intravoxel white matter fiber heterogeneity. *Magn. Reson. Med.* **48**, 577–82 (2002).



## SAMENVATTING

Het doel van dit proefschrift was meer inzicht te krijgen in de diagnostische en prognostische implicaties van gezichtsveldonderzoek bij kinderen met hersenaandoeningen. Verschillende aspecten van gezichtsveldonderzoek bij kinderen met hersenaandoeningen werden geëvalueerd.

Als algemene introductie geeft **Hoofdstuk 1** achtergrondinformatie over de visuele banen in de hersenen en over verschillende technieken die gebruikt kunnen worden om de visuele functie te meten in jonge of neurologisch beperkte kinderen.

In **Hoofdstuk 2** evalueerden we alle gezichtsveldonderzoeken die werden uitgevoerd met de "BEhavioral visual FIEld" (BEFIE) screening test, een techniek die in 1995 ontwikkeld werd door Porro et al. in ons centrum, met als doel het perifere gezichtsveld van jonge en neurologisch beperkte kinderen te meten. We vonden dat 74% van de 1788 testen betrouwbaar kon worden uitgevoerd en rapporteerden een toenemend slagingspercentage bij hogere leeftijd. Gezichtsvelddefecten werden gevonden in 28% van de betrouwbaar uitgevoerde testen. Verder waren de resultaten consistent over de tijd bij 75% van de 304 kinderen die meerdere betrouwbare testen ondergingen, met een positieve relatie tussen consistentie en het aantal uitgevoerde testen. Toen we BEFIE test resultaten vergeleken met resultaten gevonden bij standaard conventioneel gezichtsveldonderzoek uitgevoerd bij dezelfde kinderen op een later moment, vonden we een hoge positief voorspellende waarde en specificiteit van beide 98%. De negatief voorspellende waarde was 66% en de sensitiviteit 60%, welke steeg naar 80% als enkel naar absolute perifere gezichtsvelddefecten werd gekeken. We concludeerden dat de BEFIE test een waardevol instrument is om perifere gezichtsvelddefecten te detecteren indien standaard conventioneel gezichtsveldonderzoek niet kan worden uitgevoerd bij jonge of neurologisch beperkte kinderen.

In **Hoofdstuk 3** werd de mogelijkheid onderzocht om gezichtsvelddefecten bij kinderen na een perinataal herseninfarct te voorspellen, gebaseerd op beeldvormend onderzoek van de anatomie van de hersenen op de leeftijd van 3 maanden. Bij 19 kinderen met een perinataal herseninfarct, waarvan acht tijdens follow-up een gezichtsvelddefect bleken te hebben, vonden we dat de aan- of afwezigheid van dit gezichtsvelddefect in de meerderheid van de kinderen juist kon worden voorspeld op basis van zowel een MRI als een DTI scan van de radiatio optica (=onderdeel van de visuele baan) in de hersenen. Dit werd geobjectiveerd met een ROC analyse, waarbij hoge AUC waarden van respectievelijk 0,90 en 0,96 werden gevonden. Een conventionele MRI scan lijkt het meest geschikt om te gebruiken in de klinische praktijk, aangezien een DTI scan een uitgebreide analyse per individu vereist terwijl het weinig toevoegt aan de beoordeling van een conventionele MRI scan. Een accurate follow-up met meerdere gezichtsveldonderzoeken is met name geïndiceerd bij kinderen met asymmetrie van de radiatio optica.

In **Hoofdstuk 4** werden gezichtsvelddefecten bij kinderen die verdacht werden van een verhoogde hersendruk geëvalueerd. Ons cohort van 192 kinderen, waarbij een vermoeden van verhoogde hersendruk bestond, liet zien dat gezichtsvelddefecten bij kinderen met verhoogde hersendruk met name bestonden uit een vergrote blinde vlekken, wat weinig bijdroeg aan de observatie van papiloedeem (=een gezwollen of verheven oogzenuwkop) bij oogspiegelen. Andere typen gezichtsvelddefecten waren schaars bij deze kinderen bij presentatie en kwamen ook voor bij kinderen waarbij een vermoeden was van verhoogde hersendruk maar waarbij uiteindelijk andere pathologie aanwezig bleek te zijn. Echter, bij kinderen met gedocumenteerde verhoogde hersendruk hing de aanwezigheid van een gezichtsvelddefect of een verlaagde gezichtsscherpte bij presentatie allebei samen met de aanwezigheid van een gezichtsvelddefect bij het laatste bezoek. Daarom concludeerden we dat gezichtsveldonderzoek bij de presentatie van kinderen waarbij een vermoeden is van een verhoogde hersendruk niet differentieert tussen kinderen met of zonder verhoogde hersendruk, maar dat het in kinderen met gedocumenteerde hersendrukverhoging wel een argument kan zijn om therapie te

starten en zou kunnen helpen bij het voorspellen van de uiteindelijke aanwezigheid van een gezichtsvelddefect.

In **Hoofdstuk 5** presenteren wij een systematisch uitgevoerd literatuuronderzoek naar de visuele uitkomst van patiënten met het Sturge-Weber Syndroom (SWS) en de resultaten van een Nederlands multicenter cohort. SWS is een zeldzame aangeboren aandoening waarbij vaatmalformaties kunnen optreden in de hersenvliezen, huid en ogen. SWS patiënten lijden regelmatig aan een combinatie van belemmerende aandoeningen voor het zicht zoals glaucoom (=schadelijke hoge oogboldruk), een diffuus choroidaal hemangioom (DCH) (=woekering van bloedvaten in het oog) in het oog en een leptomeningeaal angioom (=woekering van bloedvaten van de hersenvliezen), wat kan leiden tot neurologische gebreken en epilepsie. Eerdere studies beschreven met name de oogheelkundige of de neurologische bevindingen, resulterend in beschrijving van respectievelijk enkel de gezichtsscherpte of enkel het gezichtsveld. Ons systematisch literatuuronderzoek wees uit dat een homonieme hemianopsie (=halfzijdig gezichtsvelddefect) (HH) aanwezig was in 42% van de SWS patiënten. Van alle beschreven ogen van een algemene SWS populatie had 70% een (vrijwel) normale gezichtsscherpte, terwijl de gezichtsscherpte van de ogen met glaucoom of een DCH ernstig aangedaan was bij respectievelijk 28% en 67%. Uit ons cohort van 33 Nederlandse SWS patiënten, waarin we ons specifiek gericht hebben op de combinatie van gezichtsveld en gezichtsscherpte uitkomsten, bleek dat maar 18% van de patiënten (vrijwel) normale bevindingen had op beide visuele parameters, terwijl de helft van de patiënten met glaucoom een combinatie van een HH en een aangedane gezichtsscherpte had. We adviseren een adequaat follow-up onderzoek van zowel de gezichtsscherpte als het gezichtsveld van SWS patiënten.

In **Hoofdstuk 6** werd de visuele uitkomst en de prevalentie van compensatie mechanismen (CMs) voor HH bij kinderen die hemisferectomie (=epilepsie chirurgie waarbij één hersenhelft wordt uitgeschakeld) ondergingen beschreven. Verschillende eerder gepubliceerde case-reports beschreven een abnormale hoofdhouding en exotropie (XT) (=divergent scheelzien)

contralateraal aan de zijde van vroege hersenschade als mogelijke CMs voor HH. In ons cohort van 45 kinderen die hemisferectomie ondergingen vonden we dat alle kinderen visuele fixatie vertoonden, 87% van de onderzochte kinderen een normale of mild aangedane gezichtsscherpte had en alle geteste kinderen een HH hadden. Een abnormale hoofdhouding en een continue of intermitterende XT contralateraal aan de zijde van hemisferectomie werden gezien bij respectievelijk 53% en 38% van de kinderen. De kinderen die deze CMs vertoonden hadden vaker rechtszijdige chirurgie ondergaan en waren jonger toen hun epilepsie begon. Daarnaast waren ze ook jonger op het moment van hemisferectomie dan de kinderen zonder CMs. We concludeerden dat de meerderheid van de kinderen die hemisferectomie ondergaan een goede visuele uitkomst heeft en vaak CMs ontwikkelt welke hun functionele gezichtsveld kunnen optimaliseren.



# 8

**List of abbreviations**

**Contributors**

**Assessment committee**

**Dankwoord**

**Curriculum vitae**

**List of publications**

## LIST OF ABBREVIATIONS

AHP	Anomalous Head Posture
AUC	Area Under the Curve
BEFIE	BEhavioral visual FIEld screening test
BIH	Benign Intracranial Hypertension
CI	Confidence Interval
CM	Compensatory Mechanism
CNS	Central Nervous System
CSF(P)	Cerebrospinal Fluid (Pressure)
CT	Computed Tomography
CVI	Cerebral Visual Impairment
DCH	Diffuse Choroidal Hemangioma
DQ	Developmental Quotient
DTI	Diffusion Tensor Imaging
DWI	Diffusion Weighted Imaging
EBS	Enlarged Blind Spot
ET	Esotropia
FA	Fluorescein Angiography / Fractional Anisotropy
FDT	Frequency Doubling Technology
FU	Follow-Up
HH	Homonymous Hemianopia
HRQoL	Health Related Quality of Life
HS	Hemispherectomy
IC	Impaired Cognition
ICP	Intracranial Pressure
IIH	Idiopathic Intracranial Hypertension
IQ	Intelligence Quotient
$\lambda_1$	Axial Diffusivity

$\lambda_{23}$	Radial Diffusivity
LogMAR	Logarithm of the Minimum Angle of Resolution
MCA	Middle Cerebral Artery
MD	Mean Diffusivity / Doctor of Medicine
MDI	Mental Developmental Index
(f)MRI	(Functional) Magnetic Resonance Imaging
NC	Normal Cognition
NCIM	Normal Cognition & Impaired Motor function
NCNM	Normal Cognition & Normal Motor function
NFL	Nerve Fiber Layer
NPV	Negative Predictive Value
OCT	Optical Coherence Tomography
OR	Optic Radiation
PIAS	Perinatal Arterial Ischemic Stroke
PCA	Posterior Cerebral Artery
PPV	Positive Predictive Value
pRF	Population Receptive Field
PVF	Peripheral Visual Field
ROC	Receiver Operating Characteristic
SCP	Standard Conventional Perimetry
SWS	Sturge-Weber Syndrome
TAC	Teller Acuity Cards
UMC	University Medical Center
USG	Ultrasonography
VA	Visual Acuity
(m)VEP	(Multifocal) Visual Evoked Potential
VF(D)	Visual Field (Defect)
VI	Visual Impairment
XT	Exotropia

## CONTRIBUTORS

Niek E. van der Aa, MD, PhD

*Department of Neonatology, Brain Center Rudolf Magnus, University Medical Center Utrecht, the Netherlands*

Carlien A. Bennebroek, MD

*Department of Ophthalmology, Academic Medical Center Amsterdam, the Netherlands*

Prof. Joke H. de Boer, MD, PhD

*Department of Ophthalmology, University Medical Center Utrecht, the Netherlands*

Prof. Kees P.J. Braun, MD, PhD

*Department of Pediatric Neurology, Brain Center Rudolf Magnus, University Medical Center Utrecht, the Netherlands*

Mirjan van Dijk, MSc

*Department of Ophthalmology, University Medical Center Groningen, the Netherlands*

Prof. Serge O. Dumoulin, MD, PhD

*Department of Experimental Psychology, Helmholtz Institute, Utrecht University, the Netherlands*

Michelle B. van Egmond-Ebbeling, MD

*Department of Ophthalmology, University Medical Center Utrecht, the Netherlands*

Alessio Fracasso, MSc, PhD

*Department of Experimental Psychology, Helmholtz Institute, Utrecht University, the Netherlands*



Floris Groenendaal, MD, PhD

*Department of Neonatology, Brain Center Rudolf Magnus, University Medical Center Utrecht, the Netherlands*

Peter H. Gosselaar, MD, PhD

*Department of Neurosurgery, Brain Center Rudolf Magnus, University Medical Center Utrecht, the Netherlands*

Prof. Saskia M. Imhof, MD, PhD

*Department of Ophthalmology, University Medical Center Utrecht, the Netherlands*

Chris C.M. Nielsen, MD

*Department of Ophthalmology, Canisius Wilhelmina Hospital Nijmegen, the Netherlands*

Prof. Nomdo M. Jansonius, MD, PhD

*Department of Ophthalmology, University of Groningen, University Medical Center Groningen, the Netherlands*

Denise C.P. van der Linden, BSc

*Department of Ophthalmology, University Medical Center Utrecht, the Netherlands*

Giorgio L. Porro, MD, PhD

*Department of Ophthalmology, University Medical Center Utrecht, the Netherlands*

Prof. Nicoline E. Schalij-Delfos, MD, PhD

*Department of Ophthalmology, Leiden University Medical Center, the Netherlands*

## Chapter 8

Monique M.J. van Schooneveld, MSc, PhD

*Department of Pediatric Psychology, Sector Neuropsychology, University Medical Center Utrecht, the Netherlands*

Wouter B.H.J. Vehmeijer, MD

*Department of Ophthalmology, Leiden University Medical Center, the Netherlands*

Prof. Linda S. de Vries, MD, PhD

*Department of Neonatology, Brain Center Rudolf Magnus, University Medical Center Utrecht, the Netherlands*

## **ASSESSMENT COMMITTEE**

Prof. Diederick E. Grobbee, MD, PhD

*Julius Center for Health Sciences and Primary Care, University Medical Center Utrecht, the Netherlands*

Prof. Joke H. de Boer, MD, PhD

*Department of Ophthalmology, University Medical Center Utrecht, the Netherlands*

Prof. Serge O. Dumoulin, MSc, PhD

*Department of Experimental Psychology, Helmholtz Institute, Utrecht University, the Netherlands*

Prof. Nicoline E. Schalijs-Delfos, MD, PhD

*Department of Ophthalmology, Leiden University Medical Center, the Netherlands*

Prof. Johan S.H. Vles, MD, PhD

*Department of Pediatrics, Neonatology and Child Neurology, Maastricht University Medical Center, the Netherlands*

## DANKWOORD

Dan is nu het moment aangebroken waar ik lang naar uitgekeken heb: het moment waarop ik aan het dankwoord kan beginnen! Ik heb een gezellige en leerzame tijd gehad, met leuke en minder leuke momenten (zoals een promotieonderzoek betaamt) en ik ben trots dat ik het volbracht heb! Dat ik dit proefschrift tot een succesvol einde heb kunnen brengen, heb ik te danken aan de mensen om mij heen waar ik de afgelopen jaren hulp en steun van heb gekregen. Zij droegen bij aan de inhoud, hebben mij gecoacht of zorgden voor aangename afleiding.

Dr. G.L. Porro, beste Giorgio, alweer zes jaar geleden leerde ik je kennen als begeleider van mijn eerste wetenschapsstage tijdens de studie geneeskunde. Ik kan me nog goed herinneren dat ik mijn eerste wetenschappelijke verslag bij jou inleverde. Het was een spannend moment. Bij ons daarop volgende overleg zei jij op strenge toon: "Dit is onleesbaar!". Ik moest even slikken. Toen Denise zei dat je me niet zo moest pesten begonnen jullie te lachen en zei je al snel: "Je hebt een veel te klein lettertype gekozen en ik heb mijn leesbril niet bij me!". De toon was gezet en ik ben blij dat je me met veel humor door mijn promotiejaren heen geloofst hebt. Naast je grapjes ben je namelijk een ster in 'motivational talking' en heb je mij vanaf die eerste stage volledig vertrouwd en gesteund. Je gaf mij de kans om als jouw eerste promovenda aan dit onderzoek te beginnen en die kans greep ik met beide handen aan. Dat een promotieonderzoek door tegenslagen ook best zwaar kan zijn, had ik toen misschien wat onderschat en ik weet niet of ik het zonder jou als persoonlijke entertainer en coach zou hebben volgehouden. Wat zeker is, is dat je mijn promotie hierdoor een stuk leuker en minder zwaar voor me hebt gemaakt. Dan heb ik het nog niet eens over jouw wetenschappelijke en vele andere talenten gehad, waar ik de afgelopen jaren van heb mogen leren. Ik heb veel bewondering voor wat jij allemaal gepresteerd hebt. Je bent een echte duizendpoot. Je schreef je proefschrift over de door jou ontwikkelde BEFIE methode en je verdedigde dit in een voor jou toen nog vreemde taal. Je runt de KNC poli in het UMC Utrecht en je bent wetenschap-

pelijk actief in samenwerking met veel verschillende disciplines. Je werkt zowel academisch als perifeer als oogarts en bent perifeer opleider van de AIOS uit Rotterdam. Je bent lid van veel commissies, besturen en verenigingen in Nederland én Italië. Het is wonderbaarlijk dat je daarnaast nog een druk sociaal leven hebt, waarin jij tijd maakt voor jouw grote gezin met vier kinderen, vrienden, familie, vakanties, voetballen en het lopen van vele marathons. Ondanks jouw volle agenda maakte je altijd tijd voor mij met vlotte reacties op al mijn e-mails en gaf je nuttige tips en correcties op de wetenschappelijke stukken die ik je toestuurd. Op de maandagen in Utrecht had je altijd genoeg tijd om te sparren over de problemen en successen. Je hebt mij geïntroduceerd in de wetenschappelijke wereld en alles wat daarbij komt kijken. Je bent een groot voorbeeld voor mij en ik hoop dat we nog veel zullen samenwerken in de toekomst! Caro Giorgio, molte grazie per tutto!

Prof.dr. K.P.J. Braun, beste Kees, aan het begin van mijn promotietraject kwamen Giorgio en ik bij jou langs om te praten over een eventuele samenwerking. Gelukkig was je enthousiast over onze plannen en je hebt uiteindelijk een ontzettend belangrijke rol gespeeld in mijn promotietraject, waar ik erg blij mee ben. Ik heb veel bewondering voor jouw wetenschappelijke talenten. In jouw drukke agenda weet jij genoeg tijd vrij te maken om de vele promovendi die jij onder je hebt aandachtig en toegewijd te begeleiden. Binnen korte tijd corrigeerde en becommentarieerde jij mijn stukken van A tot Z met veel precisie. Ondanks dat de stukken er vaak vrij rood uitzagen, begon jouw begeleidende e-mail meestal met de tekst "je bent goed op weg", wat maakte dat ik vol goede moed aan het herschrijven begon. De stukken werden er altijd vele malen beter van. Ik vind het bijzonder hoe jij zo vlot, zo goed, klinisch en wetenschappelijk kunt redeneren en kunt bedenken wat de meest transparante manier is om de data en de boodschap over te brengen op de lezer. Tijdens het 6-wekelijks gezamenlijke overleg had jij vaak maar een paar woorden nodig om weer volledig in het onderwerp te zitten en daarover te sparren. Terwijl ik dagelijks met het onderzoek bezig was, vereiste het vaak opperste concentratie om jouw snelle gedachtegangen bij te kunnen houden. Ondanks dat ik soms teleurgesteld was als we besloten de plannen toch weer totaal om te gooien, kwam

## Chapter 8

het niet alleen de uiteindelijke artikelen ten goede, maar heeft het mijzelf ook tot een betere onderzoeker gemaakt. Ontzettend bedankt voor de samenwerking en alles wat ik van je heb mogen leren!

Prof.dr. S.M. Imhof, beste Saskia, ook jou wil ik bedanken voor je bijdrage aan dit proefschrift. Als wij tijdens een gezamenlijk overleg te veel neigden af te dwalen, wist jij ons altijd weer terug te brengen naar de hoofdvraag. Dit heeft mij geholpen om me meer te focussen op het uiteindelijke doel van de artikelen. Als een plan niet haalbaar leek of onevenredig met wat het ons aan informatie zou opleveren, stelde jij die vraag hardop. Dit maakte dat ook de tijdspanning aardig goed verliep. Toen duidelijk werd dat ik toch een half jaar zou gaan uitlopen, hielp jij mee met oplossingen zoeken om deze verlenging mogelijk te maken, met tips voor het aanvragen van extra financiering. Ook heb ik me bij jouw initiatief mogen aansluiten om geld in te zamelen voor meer oogheeskundig wetenschappelijk onderzoek. Recent hebben we samen met team UMCU een prachtig bedrag opgehaald voor stichting Niet Blind en zullen we als tegenprestatie in 4 dagen 700km fietsen van Boston naar New York. Een uitdaging waar ik veel zin in heb en die perfect past bij de afsluiting van mijn promotiejaren. De volgende uitdaging na het afronden van deze promotie is de opleiding tot oogarts succesvol te doorlopen. Ik kijk er erg naar uit om weer in de kliniek toe te treden en bij jou op de afdeling als AIOS aan de slag te gaan vanaf juli. Ik ben je dankbaar voor het vertrouwen dat je in me heb gesteld en hoop nog veel van je te mogen leren de komende jaren!

Graag wil ik alle kinderen (en hun ouders) die het Kinder Neuro-ophthalmologisch Centrum (KNC) bezocht hebben en beschreven worden in dit proefschrift bedanken voor het gebruikmaken van hun data. Het heeft veel waardevolle informatie opgeleverd.

Daarnaast wil ik ook de fondsen die het onderzoek, beschreven in dit boek, financieel mogelijk hebben gemaakt, de Dr. F.P. Fischer Stichting, ODAS, Rotterdamse Stichting Blindenbelangen, Stichting Nederlands Oogheeskundig Onderzoek en Stichting Vrienden UMC Utrecht, hartelijk danken voor hun subsidies.

Beste beoordelingscommissie, Prof. Diederick E. Grobbee, Prof. Joke H. de Boer, Prof. Serge O. Dumoulin, Prof. Nicoline E. Schalijs-Delfos en Prof. Johan S.H. Vles, hartelijk dank dat jullie de moeite hebben genomen mijn proefschrift te lezen en te beoordelen.

Prof.dr. L.S. de Vries en Dr. N.E. van der Aa, beste Linda en Niek, ik vond het erg leuk om met jullie vanuit de neonatologie samen het DTI stuk te schrijven. Niek, ik bewonder je efficiënte werkstijl en heb veel van je geleerd. Degene die bij jou gaat promoveren heeft sowieso een top copromotor aan jou!

Prof.dr. S.O. Dumoulin en Dr. A. Fracasso, beste Serge en Alessio, ik heb met plezier deelgenomen aan het overleg over jullie onderzoeksprojecten vanuit de neurowetenschappen en het artikel over de patiënt met hemihydranencefalie. Deze interessante ontwikkelingen zullen in de toekomst zeer waardevol zijn voor de kliniek en de patiënten van het KNC.

Beste mede-auteurs, bedankt voor jullie inzet, hulp, adviezen, aanleveren van data en kritisch bekijken van de stukken. Dit heeft de stukken van hogere kwaliteit gemaakt!

Dr. Dienne Serraris-Post, bedankt voor uw initiatief om samen met Giorgio het KNC op te richten. Zonder dit centrum was het niet mogelijk geweest dit promotieonderzoek te verrichten.

Elsbeth & Michelle, ik heb het erg leuk gevonden dat ik samen met jullie als kinderoogartsen de EPOS congressen kon bezoeken tijdens mijn promotietraject. Elsbeth, bedankt dat je mij 6 jaar geleden hebt geholpen bij mijn eerste wetenschappelijke stage en mij in contact hebt gebracht met Giorgio, wat uiteindelijk heeft geleid tot de totstandkoming van dit proefschrift. Michelle, erg leuk dat we samen een artikel hebben kunnen schrijven. Blijkbaar zijn we een succesvol team aangezien het zonder revisies geaccepteerd werd! Daar kunnen we trots op zijn. Ik hoop de komende 5 jaar veel van jullie beiden te mogen leren over kinderoogheelkunde.

## Chapter 8

Beste orthoptisten, Denise, Aisha, Meike, Pascale, Patricia, Sacha en Simone, bedankt dat ik met jullie poli's mocht meelopen, voor jullie hulp bij mijn vragen over orthoptie, voor het meedenken over mijn onderzoek en de gezellige gezamenlijke lunches op maandag. Denise, jij in het bijzonder bedankt voor je hulp en voor al het werk wat jij samen met Giorgio verricht hebt in de kliniek de afgelopen jaren op de KNC poli.

Beste medewerkers van de functieafdeling oogheelkunde, dank voor jullie hulp bij vragen over de uitvoering en interpretatie van gezichtsveldonderzoek.

Beste Suzan van Zadelhoff, H el ene Willems-van Paridon, Ellis de Vries en Petra Fernhout, bedankt voor jullie hulp bij de moeilijk te plannen afspraken en het regelen van andere praktische zaken rondom mijn promotietraject.

Alle collega onderzoekers van het Rudolf Magnus Hersencentrum en de master Epidemiologie, bedankt voor de leuke samenwerking tijdens alle workshops en cursussen.

Beste AIOS en mede-DOPS-onderzoekers uit oogheelkundig Nederland, bedankt voor alle gezellige congressen, dinertjes, koffietjes, borrels, assistentenweekenden en wintersporten met jullie. Ik ben blij dat ik in zo'n gezellige vakgroep mag werken. Behalve dat ik nog veel van jullie hoop te leren, kijk ik ook alweer uit naar alle leuke activiteiten met jullie samen de komende jaren tijdens de opleiding!

Laura & Nienke, mijn lieve paranimfen, ik ben heel blij met jullie aan mijn zijde op 14 juni! Jullie hebben mijn promotietraject van de eerste tot de laatste dag op de voet gevolgd. Jullie waren enthousiast voor mij als ik succes had, maar jullie waren er ook altijd als ik in de put zat om me een peptalk te geven of gewoon lekker samen te klagen. Laura, wij zijn inmiddels al meer dan 10 jaar vriendinnen en we hebben samen ontzettend veel meegemaakt: in de jaarclub, (te



gast) in Huize de Billi en samen naar Zuid-Afrika voor stage en een mooie reis. Geheel toevallig belandden we naast elkaar op kantoor in het UMC en zien we elkaar vaker dan onze vriendjes. Onze Brabantse roots scheppen een band en we hebben veel lol (tenzij we in onze bubble zitten natuurlijk). Ik vind het superfijn om zo een vertrouwd iemand naast me te hebben en kijk ernaar uit om samen de opleiding tot oogarts te doorlopen. Nienke, jij was mijn eerste kamergenootje hier bij oogheelkunde in 'het hok'. Het ijs was al snel gebroken en je voelde al snel meer als vriendin dan als collega. Ik vind het altijd leuk als jij er bent met jouw nuchtere humor, interesse en vrolijke humeur. We hebben een supergezellige tijd gehad en hoop nog lang met je te mogen samenwerken in het UMCU.

Ymkje, jij bent nu ook klaar, gefeliciteerd met je proefschrift! Wat fijn dat de eindfasen van onze promotietrajecten synchroon liepen. Dit heeft de afronding van m'n proefschrift nog leuker gemaakt. Ik vond het altijd een feest als jij er was op de maandagen en dinsdagen! We konden heerlijk kletsen, lachen en met al jouw ervaring had je ook altijd goede adviezen voor me. Ik vind het ontzettend jammer dat we straks geen directe collega's meer zijn. Een goede reden om de frequentie van onze wetenschapsdinertjes weer wat op te voeren!

Anjo, wat was het heerlijk gezellig met jou op de kamer. Met jouw grappen en relativeringsvermogen werd het onderzoek een stuk aangenamer. Maar ook naast het werk vermaakten we ons goed met een concertje of zetten we ons samen sportief in. Ik vond het dan ook erg jammer dat jij voor een jaar naar het buitenland ging en heb je echt gemist. Ik kijk er naar uit dat we straks weer directe collegaatjes zijn als AIOS!

Viera, toen ik aan mijn onderzoek begon, was jij de mama van de promovendi. Ik heb veel gehad aan jouw 'SPSS reddingsboei voor dummies' en deel deze nog steeds uit aan ieder die mij een vraag over SPSS stelt. (Als ik jou was had ik er patent op aangevraagd.) Nu ik toetreed tot de AIOS ben jij alweer de mama van je AIOS als bijna oogarts. Ik ben benieuwd of ik nog eens onder Prof.dr. Kalinina Ayuso kom te werken...

## Chapter 8

Anne-Mieke en Fleurieke, meisjes van de overkant, bedankt voor de heerlijke 'goede' koffietjes op de nodige momenten! Anne-Mieke, erg leuk dat we samen Ride New York fietsen!

Daniël en Kamil, jullie kwamen als mannelijke versterking in ons team en zijn twee ware aanwinsten voor de Utrecht oogheelkunde onderzoeksgroep!

Anna, jij kwam bij de onderzoekers op het moment dat ik mijn proefschrift inleverde. Welkom bij de club en veel succes met je promotie!

Jonas, bedankt voor het begeleiden van de promovendi-groep, je tips, peptalks en sterke verhalen!

Alle andere medewerkers van de afdeling oogheelkunde bedankt voor jullie bijdrage, in welke vorm dan ook, aan mijn leuke promotietijd.

Lieve vriendinnen van de Otsies, de jaarclub, Eindhoven, sporten, familie en ex-huisgenootjes, jullie zijn superbelangrijk voor mij en geven mijn leven veel kleur! Uit de gezellige momenten met jullie deed ik een hoop energie op om elke dag weer aan de slag te gaan met het onderzoek. Ik heb genoten van de heerlijke zomervakanties, wintersporten, weekendjes weg, tennis-, roei- hardloop- en fietsuurtjes, nichtjesdagen, feestjes, dinertjes, borrels en koffietjes. Ik hoop dat we dit blijven voortzetten tot we bejaard zijn!

Lieve Charlotte, Chotje, erenimf, zo fijn dat ik altijd bij jou terecht kan! Omdat we in hetzelfde schuitje zaten, weet jij precies hoe het promoveren kan zijn in zowel positieve als negatieve zin en je was daardoor een grote steun voor mij. Daarnaast ben ik heel gelukkig met jou als vriendin en is het een eer dat ik in jouw voetsporen mag treden als 2de gepromoveerde Otsie.

## Dankwoord

Lieve Victor & Marijke en Maaïke & Rendert-Jan, ik werd bij jullie in een warm nest ontvangen. De heerlijke dinertjes en het weekend naar Texel vond ik erg gezellig. Dat er nog maar veel meer van deze momenten mogen volgen!

Lieve familie, Papa & Mama, Huug & San en Sab & Rob, bedankt voor jullie onvoorwaardelijke steun! Ik weet dat jullie er voor mij zijn en ik altijd op jullie kan terugvallen, no matter what. Dat doet mij goed en maakt mij sterk. Ik geniet van alle gezellige momenten die we hebben met elkaar (live en sinds een paar jaar ook nog op de groeps-app 😊) en kijk uit naar de familie-uitbreiding deze zomer!

Lief nichtje en neefje Courtens en Koenraads, de nieuwe aanwinsten van onze familie, ik ben zo blij met jullie komst, dat ik mijn boek graag aan jullie op wil dragen, als welkomstcadeau 📖

Lieve Roog, jij bent de liefste en de leukste! Ik ben zo blij dat ik jou heb leren kennen tijdens mijn promotieonderzoek. Je hebt me perfect gesteund wanneer dat nodig was en geeft me daarnaast ook voldoende weerstand wanneer dat nodig is 😊 Ik hou van jouw ondernemende karakter, grapjes en Hollandse nuchterheid en heb altijd zin om jou te zien! Ik vind het heerlijk dat je sinds vorig jaar bij me woont en heb genoten van ons eerste grote avontuur in Colombia. Het smaakte naar meer! Lieverd, ik hou van jou ❤️, op naar onze toekomst! 💋

Yvonne

## CURRICULUM VITAE

Yvonne Koenraads werd geboren op 31 december 1986 in Eindhoven. Hier groeide ze op als jongste dochter in een gezin van drie kinderen en haalde in 2005 haar atheneum diploma cum laude, met de profielen 'natuur & techniek' en 'natuur & gezondheid', aan het Lorentz Casimir Lyceum. In datzelfde jaar begon ze aan de studie Geneeskunde in Utrecht. Tijdens haar studie maakte ze meerdere lange reizen naar Zuid-Afrika, Zuid-Amerika en Azië, welke ze combineerde met een stage of talencursus. Halverwege haar studie ontwikkelde ze haar interesse voor het veelzijdige, klein chirurgische vak oogheelkunde. In het vijfde jaar van haar studie begon ze met het beoefenen van wetenschap op het gebied van visueel functioneren van kinderen met hersenaandoeningen bij oogarts dr. Giorgio Porro in het UMC Utrecht, en schreef ze een onderzoeksvorstel voor een promotieonderzoek dat door verschillende fondsen werd gefinancierd.



In augustus 2012 behaalde Yvonne haar artsexamen en begon aan haar promotieonderzoek als arts-onderzoeker bij de afdeling oogheelkunde, met begeleiding vanuit de kinderneurologie (prof.dr. Kees Braun) en oogheelkunde (prof.dr. Saskia Imhof en dr. Giorgio Porro). In 2013 organiseerde ze samen met enkele collega-promovendi het DOPS wetenschappelijke congres voor promovendi binnen de oogheelkunde in Nederland en België. Ze gaf verschillende presentaties op (inter)nationale congressen (o.a. NOG, EPOS, EPNS en ARVO) en volgde de postgraduate master Epidemiologie bij het Julius centrum van de Universiteit Utrecht, alsmede het 'Clinical & Experimental Neuroscience' PhD programma van de 'Graduate School of Life Sciences' bij het Hersencentrum Rudolf Magnus. In 2015 trad ze toe als kerngroep lid in de

ontwikkeling van een Nederlandse richtlijn voor kinderen met CVI (cerebrale visuele stoornis). Tijdens haar promotieonderzoek is ze ook verschillende sportieve uitdagingen aangegaan zoals het roeien van de Ringvaart roeimarathon en het lopen van de halve marathon van Amsterdam. Daarnaast zal ze rondom haar promotie samen met collega's van Boston naar New York fietsen en met haar fietsvereniging de 'Maratona dles Dolomites' in Italië afleggen. Op 14 juni van dit jaar zal ze haar proefschrift getiteld "*Visual field examination in children with brain disorders*" verdedigen aan de Universiteit Utrecht, waarna ze op 1 juli 2016 aan de opleiding tot oogarts zal beginnen in het UMC Utrecht.

## LIST OF PUBLICATIONS

► **Visual outcome in Sturge-Weber syndrome: a systematic review and Dutch multi-center cohort**

Koenraads Y, van Egmond-Ebbeling MB, de Boer JH, Imhof SM, Braun KPJ, Porro GL, on behalf of the SWS study group

*Accepted for publication in Acta Ophthalmologica*

► **Bilateral population receptive fields in congenital hemihydranencephaly**

Fracasso A, Koenraads Y, Porro GL, Dumoulin SO

*Accepted for publication in Ophthalmic and Physiological Optics*

► **Prediction of visual field defects in newborn infants with perinatal arterial ischemic stroke using early MRI and DTI-based tractography of the optic radiation**

Koenraads Y, Porro GL, Braun KP, Groenendaal F, de Vries LS, van der Aa NE

*European Journal of Paediatric Neurology 2016 Mar;20(2):309-18*

► **Perimetry in young and neurologically impaired children: the Behavioral Visual Field (BEFIE) Screening Test revisited**

Koenraads Y, Braun KP, van der Linden DC, Imhof SM, Porro GL

*JAMA Ophthalmology 2015 Mar;133(3):319-25*

► **Visual function and compensatory mechanisms for hemianopia after hemispherectomy in children**

Koenraads Y, van der Linden DC, van Schooneveld MM, Imhof SM, Gosselaar PH, Porro GL, Braun KP

*Epilepsia 2014 Jun;55(6):909-17*