Reproductive Toxicology 87 (2019) 125–139

Contents lists available at ScienceDirect

Reproductive Toxicology

journal homepage: www.elsevier.com/locate/reprotox

Review

Fetal methotrexate syndrome: A systematic review of case reports

Eline A. Verberne[a,*], Emma de Haan[a], J. Peter van Tintelen[a,b], Dick Lindhout[b], Mieke M. van Haelst[a]

[a] Department of Clinical Genetics, Amsterdam UMC, University of Amsterdam, Meibergdreef 9, 1105 AZ, Amsterdam, The Netherlands
[b] Department of Genetics, University Medical Center Utrecht, Utrecht University, Heidelberglaan 100, 3584 CX, Utrecht, The Netherlands

ARTICLE INFO

Keywords:
Methotrexate
Teratogen
Congenital anomaly
Pregnancy

ABSTRACT

Methotrexate is a folic acid antagonist known to be teratogenic in humans. Several cases of congenital malformations after fetal exposure to methotrexate have been published, resulting in the establishment of the 'fetal methotrexate syndrome'. However, it is unclear which congenital anomalies can truly be attributed to methotrexate exposure. The objective of this review is to delineate a consistent phenotype of the fetal methotrexate syndrome. We performed a systematic review that yielded 29 cases of (congenital) anomalies after *in utero* exposure to methotrexate and compared their malformation pattern to that of children and fetuses with congenital anomalies in general. Statistically significant higher proportions of microcephaly, craniosynostosis, tetralogy of Fallot, pulmonary valve atresia, limb reduction defects and syndactyly were found in the methotrexate group, indicating that these congenital anomalies are truly part of the fetal methotrexate syndrome. These results aid clinicians with diagnosing fetal methotrexate syndrome.

1. Introduction

The teratogenic effect of methotrexate on the developing human has been recognized since the 1960's [1]. Methotrexate is a folic acid antagonist that reversibly inhibits dihydrofolate reductase (DHFR), an enzyme that catalyzes the conversion of dihydrofolate to tetrahydrofolate, an essential cofactor in the synthesis of purine and thymidylate. Inhibition of this pathway by methotrexate results in impaired DNA synthesis and cellular replication. Tissues with high rates of cellular proliferation, like cancer cells or fetal and trophoblastic cells, are most sensitive to the effects of methotrexate [2]. Because of its antineoplastic and immunosuppressant activities, methotrexate is commonly used in the treatment of neoplasias and auto-immune diseases like rheumatoid arthritis and psoriasis. In addition, methotrexate is a well-known alternative for surgical treatment of ectopic pregnancy. Finally, it is used as an abortifacient in countries where mifepristone is not available [3].

Over the last decades, several cases of congenital malformations resulting from fetal exposure to methotrexate have been published. They report on fetal outcome after inadvertent exposure to methotrexate in case of treatment for maternal disease, after treatment of a pregnancy that was misdiagnosed as ectopic or after failed medical abortion. This resulted in the establishment of the 'fetal methotrexate syndrome' or 'methotrexate embryopathy': a congenital malformation syndrome that includes growth deficiency, microcephaly, craniosynostosis, facial dysmorphic features and limb defects [4,5].

However, evaluating single cases hampers the establishment of a complete and accurate description of the fetal methotrexate syndrome. Reported anomalies are not necessarily caused by methotrexate, if they would occur proportionally just as much in the general population as in methotrexate exposed fetuses. Furthermore, reported anomalies could have been the result of preterm birth (for example inguinal hernia) and reported dysmorphic features may be due to inherited familial features (for example clinodactyly or upslanting palpebral fissures). Finally, many case reports involve exposures to multiple drugs, which makes it hard to distinguish the contribution of methotrexate to the fetal outcome from other drugs.

Hyoun et al. (2012) have already tried to overcome some of these limitations by providing an overview of all published cases of *in utero* methotrexate exposure and comparing the proportion of malformations to that reported in a population based birth defects surveillance program [4]. However, they still included cases that were also exposed to other teratogens and their review did not include the documentation of a structured literature search and selection process.

In this review we therefore aim to further delineate a consistent phenotype of fetal methotrexate syndrome, by performing a structured literature search and analyzing all case reports on (congenital) anomalies after fetal exposure to methotrexate without exposure to any

* Corresponding author.
E-mail address: e.verberne@vumc.nl (E.A. Verberne).

https://doi.org/10.1016/j.reprotox.2019.05.066
Received 7 February 2019; Received in revised form 24 May 2019; Accepted 29 May 2019
Available online 08 June 2019

other teratogenic drugs and comparing the malformation pattern to that of children and fetuses with congenital anomalies in general.

Secondly, we will provide an overview of the maternal methotrexate dose and timing of methotrexate exposure, to explore at what dose and during which post-conceptional period methotrexate is teratogenic.

2. Methods

Electronic databases PubMed and EMBASE were searched from inception to May 2018, using terms like 'methotrexate', 'congenital anomalies' and 'pregnancy', to identify case reports of patients with (congenital) anomalies after *in utero* exposure to methotrexate. The full literature search can be found as a supplement to this review (Appendix A).

After removal of duplicates, articles were independently screened on title and abstract by two authors (EAV and EdH). Subsequently, the full texts of the remaining articles were assessed for eligibility. Case reports and case series were included if they described human cases of (congenital) anomalies after *in utero* exposure to methotrexate, without exposure to other known human teratogens. Drugs were considered teratogenic if they were classified by the Netherlands Pharmacovigilance Centre Lareb (https://www.lareb.nl/en/) as 'risk of congenital anomalies' and/or if they were classified by the Food and Drug Administration (FDA) as category D[1] or X[2] . Cohort and case-control studies were included only if detailed clinical information was provided and if it could be verified that the case was not published as a separate case report as well. Studies were excluded if no full text was available or if they were written in another language than English, Dutch, Spanish or Portuguese. Any differences in opinion regarding the in- or exclusion of studies were resolved by consensus or by consultation of a third author (MvH). Reference lists of relevant articles were screened for additional articles that were not yielded by the original search.

Data on timing and dose of methotrexate, pregnancy outcome, congenital anomalies, growth, other clinical features and genetic diagnostic testing were extracted by one author (EAV) and cross-checked by another (EdH). If the birth weight percentile was not given, it was calculated using Dutch Perined birth weight curves (online available https://www.perined.nl/publicaties1/geboortegewichtcurven). If applicable, timing of methotrexate exposure was converted from weeks' gestation to weeks post-conception.

Data were analyzed in Excel using descriptive statistics. Rates of (congenital) anomalies were calculated as a percentage of the total number of cases, as postmortem examination was performed in case of stillbirth or termination of pregnancy. Preterm birth and small for gestational age (SGA (birth weight < 10th percentile)) were calculated as a percentage of the total number of live births.

To correct for the spontaneous occurrence of congenital malformations we performed a disproportionality analysis, comparing the malformation pattern that occurred after *in utero* methotrexate exposure to the malformation pattern of children and fetuses with congenital anomalies in general. The reported anomalies after *in utero* methotrexate use were classified according to Eurocat (a European population-based registry of congenital anomalies) guide 1.4 [6] and numbers of selected major congenital anomalies reported by Eurocat from 1991 to 2016 for all full member countries were used as a control population (tables online available on http://www.eurocat-network.eu/accessprevalencedata/prevalencetables after registration, accessed 31 October 2018). As it is impossible to calculate true incidence rates of the selected major congenital anomalies in the methotrexate group (because the total number of methotrexate exposed fetuses and children is not known), we calculated the proportion of each anomaly as a percentage of the total number of anomalies in that group. Thus, the denominator for the methotrexate group is the total number of anomalies in the methotrexate group and the denominator for the Eurocat group is the total number of anomalies in the Eurocat group. Two-sided Fisher's Exact test was used to calculate statistical significance for differences in the proportion of specific anomalies between the two groups. A p-value of < 0.05 was considered statistically significant.

3. Results

3.1. Study selection

The electronic literature search resulted in 720 citations after removal of duplicates. Based on title and/or abstract, 671 articles were excluded and 44 full-text articles were assessed for eligibility. We excluded 21 articles for various reasons which are described in the flow diagram (Fig. 1). Manual search of reference lists did not yield any additional articles. The 23 articles that were included reported on a total of 29 cases of *in utero* methotrexate exposure [1,7–28].

3.2. General characteristics

Methotrexate was used in 45% (13 out of 29 cases) for treatment of a maternal disease (rheumatoid arthritis, juvenile rheumatoid arthritis, systemic lupus erythematosus, psoriasis or molar pregnancy). Other indications were abortion (31%) and ectopic pregnancy (24%). The 29 pregnancies resulted in 24 live births, two stillbirths and three terminations of pregnancy after detection of malformations by fetal ultrasound (Table 1). Early death (< 1 year) occurred in two cases (Appendix B).

3.3. Genetic testing

A karyotype was reported in 45% (13 out of 29 cases). In one case a *de novo*, apparently balanced reciprocal translocation between chromosomes 5 and 20 (46,XY,t(5:20)(q15;p12)) was reported. In all other cases karyotype was normal. In three cases with a normal karyotype, additional genetic testing was performed, with normal results (see Appendix B for the genetic test results).

3.4. Clinical features

A wide variety of anomalies was reported, involving almost every organ system (Fig. 2). The most frequently reported anomalies will be discussed below. A complete list of the reported anomalies for each case can be found in Appendix B.

In 79% (23/29) facial dysmorphic features were present (Fig. 2). The most commonly reported facial dysmorphisms included low-set ears, retro-/micrognathia, hypertelorism, hypoplastic orbits, prominent eyes, epicanthal folds, auricular malformations, broad nasal bridge and high arched palate (Fig. 3).

One or more limb anomalies were reported in 59% (17/29), including hypoplasia/absence of fingers and/or toes, mesomelia, clinodactyly of finger(s) and abnormal palmar creases (Figs. 2 & 3). Other frequently reported limb anomalies (10–14%) were absent metatarsal or metacarpal bones, syndactyly of fingers, club foot, abnormal thumb (implant) and long fingers.

One or more cranial anomalies were present in 52% (15/29), with craniosynostosis being reported in 41% of all cases (Figs. 2 & 3). Other

[1] There is positive evidence of human fetal risk based on adverse reaction data from investigational or marketing experience or studies in humans, but potential benefits may warrant use of the drug in pregnant women despite potential risks.

[2] Studies in animals or humans have demonstrated fetal abnormalities and/or there is positive evidence of human fetal risk based on adverse reaction data from investigational or marketing experience, and the risks involved in use of the drug in pregnant women clearly outweigh potential benefits.

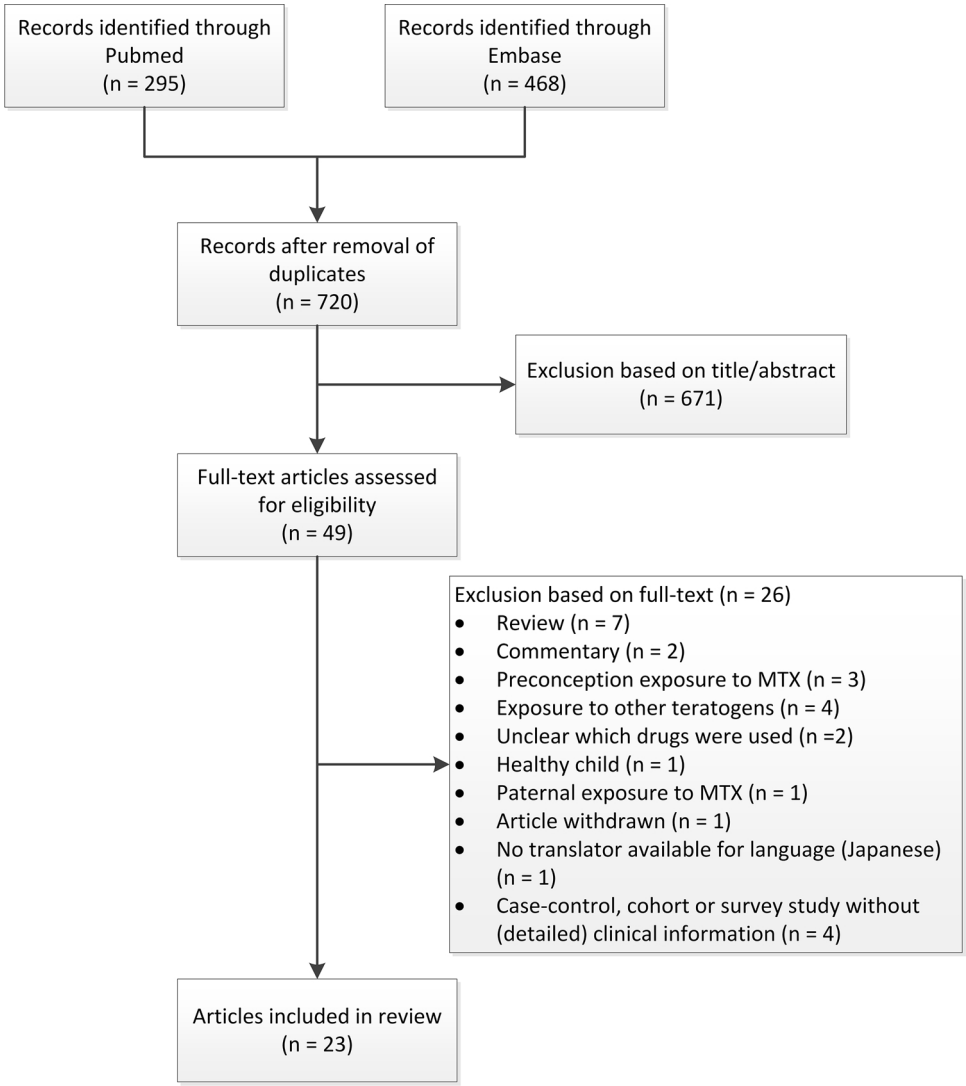

Fig. 1. Flow diagram of study selection, including reasons for exclusion.

common cranial anomalies were large fontanelle(s) and skull defects or hypoplasia of skull bones (Fig. 3).

One or more cardiovascular anomalies occurred in 41% (12/29) (Fig. 2). Ventricular septal defect was the most commonly reported cardiovascular anomaly together with tetralogy of Fallot.

One or more central nervous system anomalies were present in 38% (11/29), with microcephaly being most frequently reported (Figs. 2 & 3). Various other central nervous system anomalies were reported, of which holoprosencephaly and choroid plexus cyst were reported twice (Fig. 3). Neural tube defects occurred only in one case (case 24).

Finally, preterm birth and SGA were reported frequently in the 24 live births (50% and 54%, respectively) (Fig. 2).

3.5. Comparison with congenital anomalies reported by Eurocat

The proportions of microcephaly, craniosynostosis, tetralogy of Fallot, pulmonary valve atresia, limb reduction defects and syndactyly were significantly higher in the methotrexate group compared to the Eurocat group (Table 2).

The proportion of atrial septal defect was significantly higher in the Eurocat group compared to the methotrexate group.

No significant differences were found in the proportion of other frequently reported anomalies, such as ventricular septal defect and club foot.

Some minor anomalies are not reported in the online Eurocat tables (for example facial dysmorphic features, clinodactyly and large fontanelles) and therefore their proportions could not be analyzed.

3.6. Dose and timing of methotrexate

Methotrexate dose varied significantly between the 29 cases, ranging from 2.5 mg per day to 100–200 mg bi-weekly to a single dose of 50 mg/m^2 (Table 1). In seven cases the methotrexate dose was not known. Route of administration was underreported and therefore not listed in Table 1.

The lowest weekly received maternal methotrexate dose was 7.5 mg (case 13 and 24). In both fetuses severe congenital anomalies were present, including central nervous system anomalies, limb anomalies

Table 1
General characteristics of included cases.

Case	Author	MTX dose	MTX timing (post-conception)	Indication	Other medication	Outcome
1	Adam	50 mg/m^2 (2x)	6 and 8 weeks	EP	NR	Live birth
2	Addar	95 mg	3 weeks and 6 days	EP	NR	Live birth
3	Bawle	NR	4 or 6 weeks	A	NR	Live birth
4	Bawle	100 mg bi-weekly + 200 mg bi-weekly	11 weeks and 5 days –17 weeks + 17–23 weeks	A	NR	Live birth
5	Buckley	10–12.5 mg /week	0–8 weeks	JRA	Naproxen, FA	Live birth
6	Corona-Rivera	5 mg / day	5–7 weeks	SLE	Ampicillin, paracetamol, FA	Live birth
7	Del Campo	3 × 12.5 mg / week	0–8 weeks	P	None	Live birth
8	Delatycki	12.5 mg / week	0–6 weeks	RA	NR	Live birth
9	Diniz	5 × 10 mg / month	0–10 weeks	MP	NR	Live birth
10	Granzow	NR	˜6 weeks	MP	NR	Live birth
11	Krähenmann	10 mg (2x)	2 weeks and 6 days + 3 weeks and 6 days	RA	FA	TOP
12	Lorenz	50 mg/m^2	˜4 weeks	A	NR	Live birth
13	Martin	7.5 mg / week	0–8 weeks	RA	Fluconazole, rofecoxib, meprednisone, ranitidine, isoniazid	Live birth
14	Milunsky	2.5 mg / day	5 days at ˜6-8 weeks	A	Multivitamins	Live birth
15	Mulholland	15 mg / week	0-6 or 8 weeks	RA	FA, hydroxychloroquine	Live birth
16	Nguyen	7.5 mg / day	2 days at 3,5 weeks	P	Sertraline	TOP
17	Nurmohammed	50 mg	3 weeks	EP	NR	Live birth
18	Nurmohammed	50 mg (2x)	4 weeks	EP	NR	Stillbirth
19	Piggott	NR	1st trimester	SLE	NR	Live birth
20	Piggott	NR	4–5 weeks	EP	NR	Live birth
21	Poggi	50 mg/m^2	3 weeks and 6 days	EP	FA	Stillbirth
22	Powell	5 mg / day	0–6 or 8 weeks	P	NR	Live birth
23	Seidahmed	7.5 mg / day	4–5 weeks	A	None	Live birth
24	Singh	7.5 mg / week	0–7 weeks	RA	NR	TOP
25	Usta	75 mg	3 weeks	EP	NR	Live birth
26	Zarella	NR	˜7 weeks	A	NR	Live birth
27	Zarella	60 mg	8 weeks	A	NR	Live birth
28	Zarella	NR	4 weeks	A	NR	Live birth
29	Zarella	NR	1th trimester	A	NR	Live birth

MTX = methotrexate; NR = not reported; EP = ectopic pregnancy; A = abortion; JRA = juvenile rheumatoid arthritis; SLE = systemic lupus erythematosus; P = psoriasis; RA = rheumatoid arthritis; MP = molar pregnancy; FA = folic acid; TOP = termination of pregnancy; ˜ = approximately.

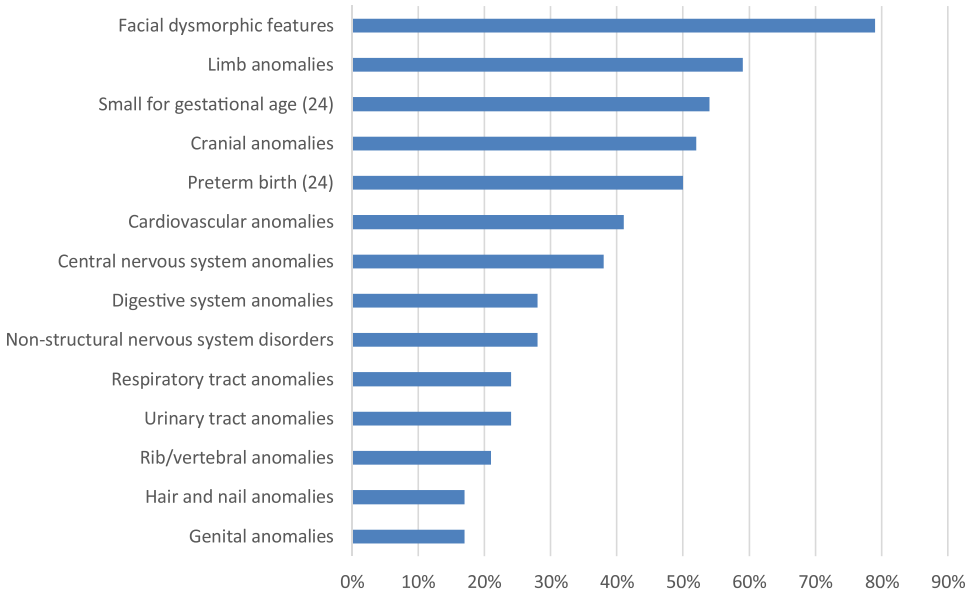

Fig. 2. Clinical features of 29 cases. Frequency of each clinical feature is represented as a percentage of the total of 29 cases, except for preterm birth and small for gestational age, which were calculated as a percentage of the 24 live births.

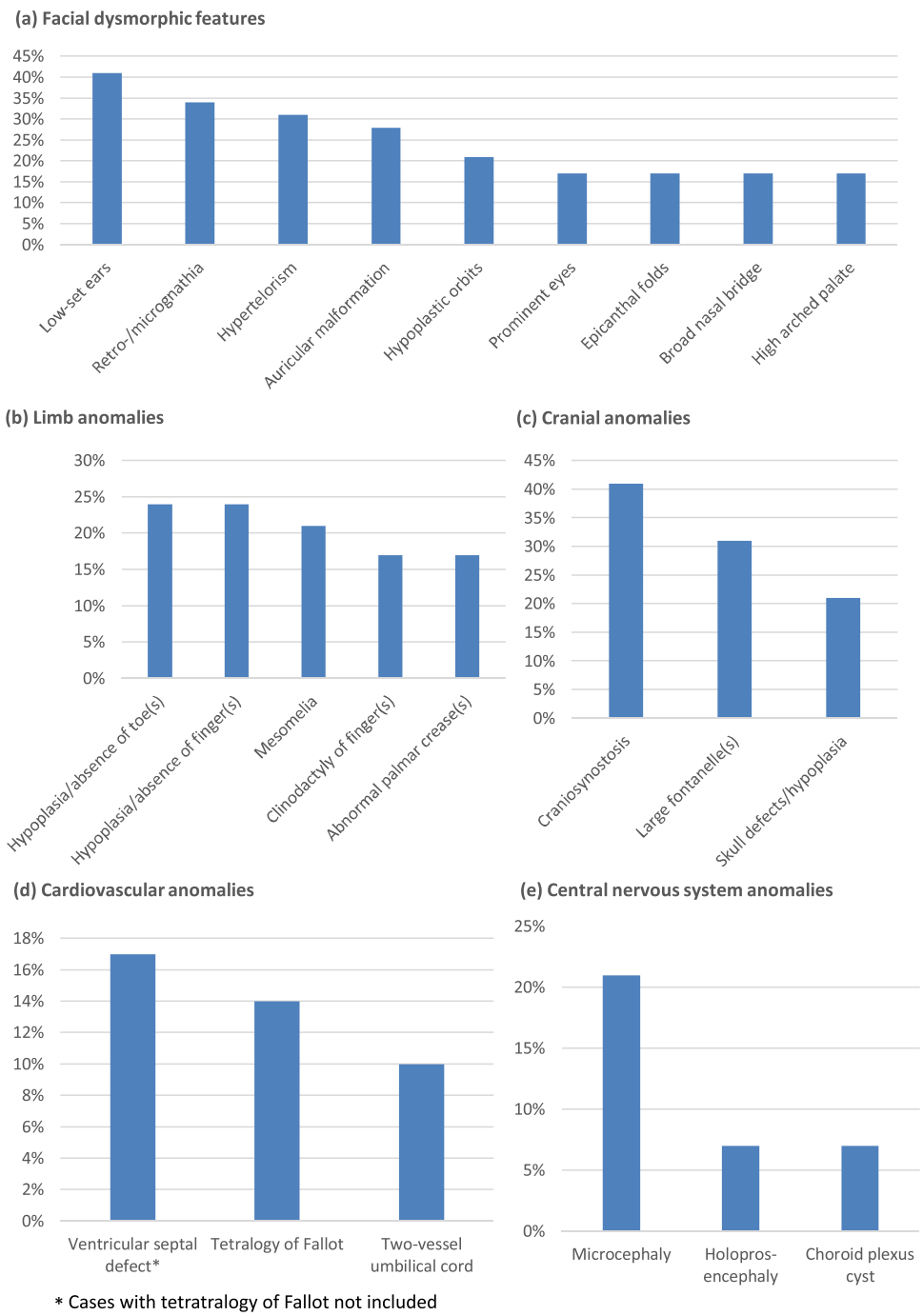

Fig. 3. *Cases with tetratralogy of Fallot not included. Frequency of facial dysmorphic features (a), limb anomalies (b), cranial anomalies (c), cardiovascular anomalies (d) and central nervous system anomalies (e) as a percentage of 29 cases.

and facial dysmorphic features.

Timing of methotrexate exposure ranged from 0-23 weeks post-conception. In several cases the exact timing of methotrexate exposure was unclear. Fig. 4 presents an overview of the timing of methotrexate exposure for each case. In all cases but one, exposure occurred between 0–10 weeks post-conception. Case four was exposed to methotrexate between 11 and 23 weeks. In this case only facial dysmorphic features without major congenital malformations were reported.

As there was no overlapping exposure period between all 29 cases, we looked at cases who were exposed to only a single dose of methotrexate to define a (minimal) critical period. The earliest single dose exposure occurred at three weeks post-conception (case 17 and 25) and the latest at eight weeks (case 27).

Table 2
Proportion of selected major anomalies in the Eurocat group vs. the methotrexate group.

Anomaly	Eurocat group		Methotrexate		p-value
	n	%	n	%	
Anencephalus and similar	5228	1.7	1	1.5	1
Encephalocele	1657	0.5	0	0.0	1
Spina Bifida[a]	6947	2.3	0	0.0	0.409
Hydrocephalus	7778	2.5	1	1.5	1
Microcephaly (< −3 SD)	**3627**	**1.2**	**4**	**6.1**	**0.008**
Arhinencephaly/ holoprosencephaly	1919	0.6	2	3.0	0.064
Anophthalmos	312	0.1	0	0.0	1
Congenital cataract	1690	0.6	0	0.0	1
Congenital glaucoma	408	0.1	0	0.0	1
Anotia	357	0.1	0	0.0	1
Common arterial truncus	975	0.3	0	0.0	1
Double outlet right ventricle	1566	0.5	1	1.5	0.286
Transposition of great vessels	4573	1.5	1	1.5	0.628
Single ventricle	1008	0.3	0	0.0	1
Ventricular septal defect	46356	15.1	5	7.6	0.119
Atrial septal defect[b]	***25207***	***8.2***	***1***	***1.5***	***0.042***
Atrioventricular septal defect	5914	1.9	1	1.5	1
Tetralogy of Fallot	**4392**	**1.4**	**4**	**6.1**	**0.015**
Tricuspid atresia and stenosis	1083	0.4	0	0.0	1
Ebstein's anomaly	665	0.2	0	0.0	1
Pulmonary valve stenosis	5603	1.8	1	1.5	1
Pulmonary valve atresia	**1464**	**0.5**	**2**	**3.0**	**0.040**
Aortic valve atresia/stenosis	1620	0.5	0	0.0	1
Mitral valve anomalies	1686	0.5	0	0.0	1
Hypoplastic left heart	3671	1.2	1	1.5	0.548
Hypoplastic right heart	592	0.2	0	0.0	1
Coarctation of aorta	5227	1.7	0	0.0	0.632
Aortic atresia/interrupted aortic arch	581	0.2	0	0.0	1
Total anomalous pulmonary venous return	827	0.3	0	0.0	1
PDA as only CHD in term infants (> = 37 weeks)	4370	1.4	0	0.0	1
Choanal atresia	1214	0.4	0	0.0	1
Cystic adenomatous malformation of lung	1096	0.4	0	0.0	1
Cleft lip with or without palate	12164	4.0	0	0.0	0.116
Cleft palate[c]	8357	2.7	1	1.5	1
Oesophageal atresia with or without tracheo-oesophageal fistula	3377	1.1	0	0.0	1
Duodenal atresia or stenosis	1793	0.6	1	1.5	0.321
Atresia or stenosis of other parts of small intestine	1225	0.4	0	0.0	1
Ano-rectal atresia and stenosis	4257	1.4	0	0.0	1
Hirschsprung's disease	1753	0.6	0	0.0	1
Atresia of bile ducts	459	0.1	0	0.0	1
Annular pancreas	250	0.1	0	0.0	1
Diaphragmatic hernia	3961	1.3	1	1.5	0.575
Gastroschisis	3570	1.2	0	0.0	1
Omphalocele	4211	1.4	0	0.0	1
Bilateral renal agenesis including Potter syndrome	1906	0.6	0	0.0	1
Multicystic renal dysplasia	4733	1.5	1	1.5	1
Congenital hydronephrosis[d]	16592	5.4	0	0.0	0.051
Bladder exstrophy and/or epispadias	903	0.3	0	0.0	1
Posterior urethral valve and/or prune belly	1491	0.5	0	0.0	1
Hypospadias	22204	7.2	2	3.0	0.238
Indeterminate sex[e]	928	0.3	1	1.5	0.181
Limb reduction defects[f]	**7594**	**2.5**	**12**	**18.2**	**< 0.001**
Club foot - talipes equinovarus	14723	4.8	3	4.5	1
Hip dislocation and/or dysplasia	13528	4.4	0	0.0	0.121
Polydactyly	12629	4.1	1	1.5	0.527
Syndactyly	**6750**	**2.2**	**6**	**9.1**	**0.003**
Craniosynostosis	**3155**	**1.0**	**12**	**18.2**	**< 0.001**
Situs inversus	905	0.3	0	0.0	1
Congenital skin disorders	4158	1.4	0	0.0	1
TOTAL	307189	100	65	100	

Bold rows indicate statistically significant ($p < 0.05$) between the methotrexate group and the Eurocat group: italic indicates a lower proportion of the anomaly in the methotrexate group, upright indicates a higher proportion of the anomaly in the methotrexate group.

[a] Excluded if associated with anencephalus or encephalocele subgroups.

[b] Patent foramen ovale not included.

[c] Excluded when associated with holoprosencephaly or anencephaly subgroups.

[d] Included only if renal pelvis was 10 mm or more after birth.

[e] Ambiguous genitalia with unknown or abnormal sex chromosome complement.

[f] Total or partial absence or severe hypoplasia of skeletal structure of the limbs.

4. Discussion

We performed an extensive literature search and identified 29 case reports of (congenital) anomalies after *in utero* exposure to methotrexate. Analysis of these cases showed that the most common features of the fetal methotrexate syndrome were preterm birth, SGA, facial dysmorphic features, limb, cranial, cardiovascular and central nervous system anomalies. More specifically, these anomalies included mesomelia, hypoplasia/absence and/or clinodactyly of the digits, abnormal palmar creases, craniosynostosis, large fontanelles, skull defects/hypoplasia, microcephaly, ventricular septal defect and tetralogy of Fallot. The most frequently reported facial dysmorphic features were low-set ears, retro-/micrognathia, hypertelorism, hypoplastic orbits, prominent eyes, epicanthal folds, auricular malformations, broad nasal bridge and high arched palate.

To correct for the possibility that some of the anomalies might have occurred spontaneously and were not related to methotrexate, we compared the proportion of selected major congenital anomalies to those reported by Eurocat. We found a different malformation pattern between the two groups, with a statistically significant higher proportion of microcephaly, craniosynostosis, tetralogy of Fallot, pulmonary valve atresia, limb reduction defects and syndactyly in the methotrexate group. A similar analysis by Hyoun et al. found craniosynostosis, pulmonary atresia, and limb deficiencies to be possibly associated with methotrexate exposure as well. However, a prospective cohort study by Weber-Schoendorfer et al. including 188 women exposed to methotrexate (≤ 30 mg/week) during pregnancy found an elevated risk of major birth defects, but none of the malformations were clearly consistent with fetal methotrexate syndrome [29]. This could possibly be explained by differences in study design. The prospective study design chosen by Weber-Schoendorfer is suitable to determine the risk of malformation, but the absolute number of malformed cases is relatively

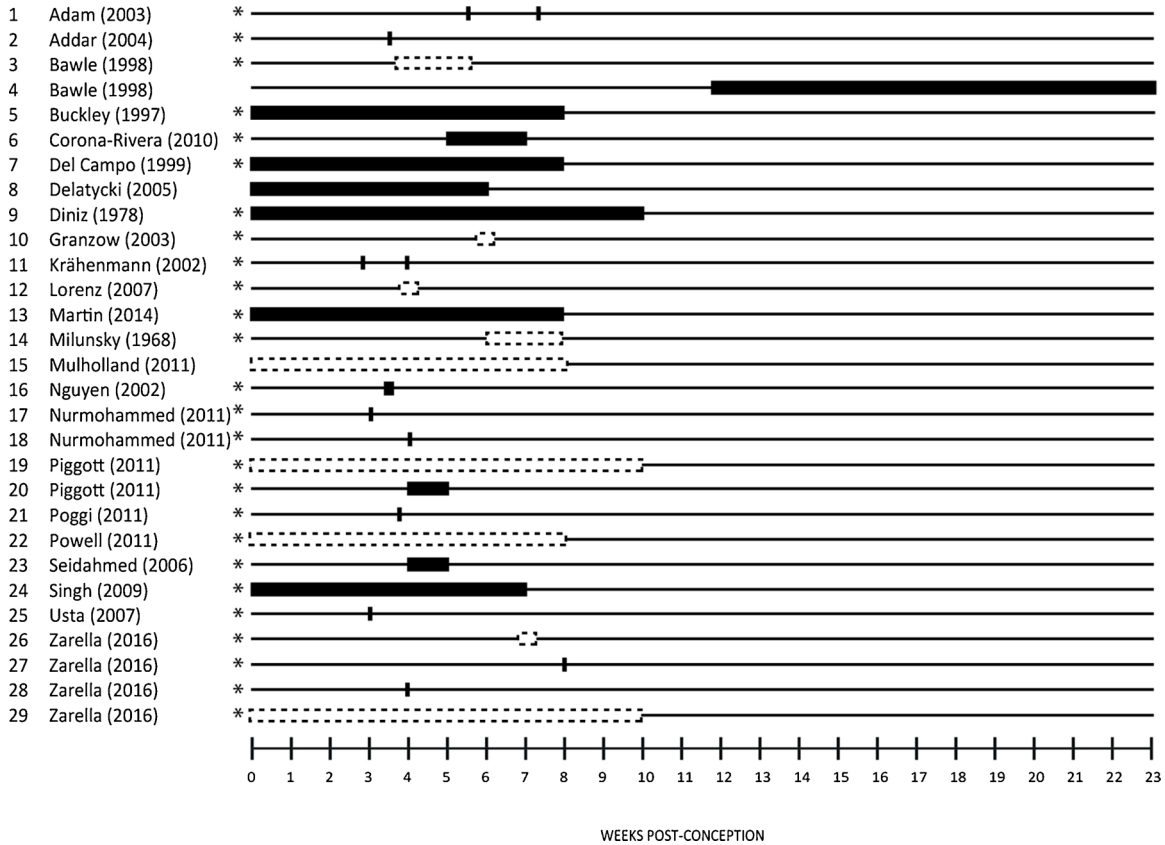

Fig. 4. Timing of methotrexate exposure in weeks post-conception. Dotted line indicates approximate period of methotrexate exposure. Cases with at least one major congenital anomaly (as classified by Eurocat guide 1.4) are indicated by *.

low (only 7 cases). Our study design, although not useful for risk assessment, enables us to collect many cases with congenital malformations and is therefore more suitable to delineate the spectrum of malformations associated with *in utero* methotrexate exposure.

Interestingly, a statistically significant lower proportion of atrial septal defect was found in the methotrexate group. One explanation could be that some diagnoses of atrial septal defect were missed in the methotrexate group, however, this seems unlikely as all patients were thoroughly examined. Alternative explanations could be that there is a protective effect of methotrexate on atrial septal defect or a negative selection of fetuses with atrial septal defect by methotrexate (methotrexate in combination with atrial septal defect being lethal during embryonic development). Another possible explanation could be that methotrexate induces other heart malformations in fetuses with predisposition to atrial septal defect. However, we are unaware of any currently known biological mechanisms that could explain any of these three possibilities. Another explanation could be that cases with atrial septal defect were not considered interesting enough to publish in a case report. Further epidemiological studies are needed to explore whether *in utero* methotrexate exposure is truly associated with a lower proportion of atrial septal defect.

Remarkably, we found no statistically significant difference in the proportion of neural tube defects between the methotrexate group and the Eurocat group. Methotrexate is a folic acid antagonist and it is known that folic acid supplementation reduces the risk of neural tube defects in the general population [30,31]. Folic acid antagonists other than methotrexate have been suggested to increase the risk of neural tube defects [32] and therefore one might have expected to see more of these defects associated with *in utero* exposure to methotrexate. However, if methotrexate exposure would lead to only a small increase in the risk of neural tube defects, our study might have been underpowered to detect a statistically significant difference. Alternatively, the lower than expected rate of neural tube defects might be explained by publication bias, since these defects may be expected based on the teratogenic mechanism of methotrexate and were therefore not considered interesting enough to publish in a case report.

In 1993, Feldkamp and Carey suggested that the teratogenic methotrexate dose is probably above 10 mg per week [33]. However, we identified two cases with congenital anomalies after a maternal methotrexate dose of 7.5 mg per week. In one of these two cases (case 13) the observed anomalies were consistent with fetal methotrexate syndrome and a normal karyotype was found. Thus, in contrast to the frequently cited hypothesis of Feldkamp and Carey, this observation suggests that a methotrexate dose as low as 7.5 mg/week can already be teratogenic.

Furthermore, Feldkamp and Carey suggested a critical period of six to eight weeks post-conception for methotrexate to be teratogenic. The critical period of methotrexate teratogenicity found in our study ranges from at least three to eight weeks post-conception. The case that was not exposed to methotrexate during this critical period of embryonic development (case 4) only showed facial dysmorphic features and was prematurely born, but had no major congenital malformations.

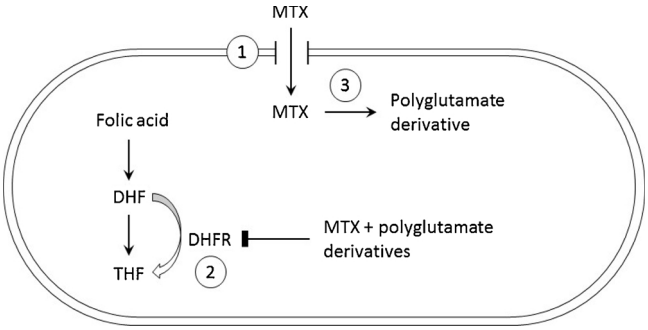

Fig. 5. Methotrexate (MTX) blocks the reduction of dihydrofolate reductase (DHF) to tetrahydrofolate (THF), by inhibiting dihydrofolate reductase (DHFR). Possible genetic mechanisms affecting fetal MTX sensitivity: polymorphisms in MTX transporters leading to either increased or decreased intracellular MTX levels (1), polymorphisms in DHFR leading to altered expression or altered affinity for MTX (2), polymorphisms leading to increased or decreased formation of the active polyglutamate derivatives of MTX (3).

However, these findings regarding critical period of methotrexate teratogenicity should be interpreted with caution, since many pregnancies were dated by last menstrual period and this has an inherent risk of inaccuracy. The fact that methotrexate is converted to active derivatives that are retained within cells and produce prolonged suppression of DHFR further complicates the determination of a critical period [34].

Moreover, timing of methotrexate exposure could be relevant to the type of anomalies observed. It has been suggested that exposure to methotrexate before six weeks post-conception could result in a distinct malformation pattern, of which tetralogy of Fallot may be a feature [4]. This hypothesis is supported by the fact that the heart develops relatively early in the embryonic period compared to the skeleton for example. Indeed, the four cases with tetralogy of Fallot in this review (cases 17, 18, 20 and 21) were all exposed to methotrexate before six weeks post-conception.

It has to be noted that in five cases it was reported that the mother also used folic acid during pregnancy. One might hypothesize that this could have a protective effect, resulting in less severe symptoms of methotrexate teratogenicity or even preventing methotrexate teratogenicity. However, as four out of these five cases had severe congenital anomalies (one with multiple cardiovascular anomalies and early death, one holoprosencephaly, one diaphragmatic hernia and one stillbirth with tetralogy of Fallot), this does not seem plausible. Possibly, the folic acid dose was too low to compensate for the potential effects of methotrexate. Additionally, the use of folic acid might be underreported, as it is often not considered as medication. Finally, it was not possible to truly assess the relation between folic acid use and the occurrence of methotrexate teratogenicity, because we did not include healthy children born after *in utero* methotrexate exposure.

For this review, we only included data derived from published case reports, with inherent limitations. One of these limitations is the risk of publication bias, with only the more severe cases being reported in literature. Another limitation is the absence of a single observer and standardized questionnaire for all cases. This could result in inaccurate or missing documentation of facial dysmorphic features and congenital anomalies, and therefore a possible underestimation of the frequency of these anomalies. Furthermore, data on gestational age in four live-born children were missing and in five cases birth weight was not reported. Since we decided to calculate the rate of preterm birth and SGA as a percentage of the total amount of live births this could have resulted in an underestimation rather than an overestimation of these outcomes. As we did not include preterm birth and SGA in our search strategy, this might also have led to an underestimation of these outcomes. Besides that, preterm birth and SGA are known to be associated with congenital anomalies, and thus these might not be the result of fetal methotrexate exposure. Finally, if the birth weight percentile was not given we calculated this using Dutch Perined birth weight curves. It would have been preferable to use population specific references curves. However, this was not possible as in most cases it could not be traced to which population the patient belonged.

It is important to keep in mind that methotrexate does not always cause embryopathy [5,35,36] and that the exact risk of congenital malformations after *in utero* exposure to methotrexate is unclear. The variability in threshold of methotrexate teratogenicity might be explained by the combination of methotrexate dose, route of administration, timing and individual differences in sensitivity to methotrexate. One explanation for the latter could be genetic polymorphisms affecting methotrexate pharmacokinetics and pharmacodynamics, both in the placenta and the fetus. *In vitro* studies in tumor systems provide examples of such altered methotrexate sensitivity: low expression or loss-of-function mutations of the reduced folate carrier (RFC), a protein that transports methotrexate into the cell, can lead to methotrexate resistance [34]. Other mechanisms of methotrexate resistance have been observed as well, such as mutations leading to impaired formation of active methotrexate derivatives, and mutations in the gene coding for DHFR that result in a decreased affinity for methotrexate or increased expression of the enzyme [34]. One could hypothesize that similar mechanisms (either mutations or genetic polymorphisms) could (partially) explain inter-individual differences in sensitivity to methotrexate teratogenicity (Fig. 5). Of course, many other (genetic) factors influencing methotrexate pharmacokinetics and pharmacodynamics could be of influence on methotrexate sensitivity.

To conclude, we want to emphasize that despite the known teratogenicity of methotrexate, a recent series of cases published in 2016 shows that children are occasionally still exposed to methotrexate *in utero* [28]. Therefore it is important for clinicians to be aware of and recognize the teratogenic effects of fetal methotrexate exposure. This review indicates that the main features of the fetal methotrexate syndrome comprise: microcephaly, craniosynostosis, tetralogy of Fallot, pulmonary valve atresia, limb reduction defects and syndactyly. Furthermore, it seems that doses as low as 7.5 mg methotrexate per week can already be teratogenic and that the critical period probably ranges from at least three to eight weeks post-conception.

Acknowledgement

This research did not receive any specific grant from funding agencies in the public, commercial, or not-for-profit sectors.

Appendix A. Search syntax

Database	Search syntax					Results
	Population		*Exposure*		*Outcome*	
PubMed	“maternal exposure”[Mesh] OR “abortion, induced”[Mesh] OR “pregnancy”[Mesh] OR maternal[tiab] OR intra-uterine[tiab] OR intrauterine[tiab] OR in utero[tiab] OR pregnan*[tiab] OR conception[tiab] OR abortifacient[tiab] OR abortion[tiab] OR fetus[tiab] OR fetal[tiab] OR foetus[tiab] OR foetal[tiab]	AND	“methotrexate”[Mesh] OR methotrexate[tiab] OR MTX[tiab]	AND	“congenital abnormalities”[Mesh] OR “teratogens”[Mesh] OR congenital[tiab] OR embryopathy[tiab] OR teratogen*[tiab] OR anomal*[tiab] OR malform*[tiab]	295
Embase	'maternal exposure'/exp OR 'induced abortion'/exp OR 'pregnancy'/exp OR maternal:ab,ti OR intra-uterine:ab,ti OR intrauterine:ab,ti OR ‘in utero’:ab,ti OR pregnan*:ab,ti OR conception:ab,ti OR abortifacient:ab,ti OR abortion:ab,ti OR fetus:ab,ti OR fetal:ab,ti OR foetus:ab,ti OR foetal:ab,ti	AND	'methotrexate'/exp OR methotrexate:ab,ti OR MTX:ab,ti	AND	'drug induced malformation'/exp OR 'congenital disorder'/exp OR 'teratogenicity'/exp OR congenital:ab,ti OR embryopathy:ab,ti OR teratogen*:ab,ti OR anomal*:ab,ti OR malform*:ab,ti	468

Appendix B. Clinical features of 29 included cases

FEATURE	CASE																													
	1	2	3	4	5	6	7	8	9	10	11	12	13	14	15	16	17	18	19	20	21	22	23	24	25	26	27	28	29	Total
PRETERM BIRTH	+	+		+	+	+	–	–			NA	–	+	+		NA	–	NA	+	+	NA	–	–	NA	–	+	+	–	+	12
SMALL FOR GESTATIONAL AGE*	–	+		–	+	–	+	–	+		NA	–	+	+		NA		NA	+		NA	–	+	NA	+	+	+	+	+	13
FACIAL DYSMORPHIC FEATURES	+	+	+	+	+	+	+		+	+			+	+	+	+			+	+		+	+	+	+	+	+	+	+	23
Retro-/micrognathia	+				+	+			+					+		+			+	+			+			+				10
Small maxilla																										+				1
Bulging forehead				+																										1
Bitemporal narrowing				+																										1
Wide forehead						+																								1
Sloping forehead																+														1
Small, narrow forehead																							+							1
High forehead													+													+				2
Short neck									+				+	+																3
Redundant nuchal skin														+		+														2
Flattened facies														+																1
Right facial hypoplasia																													+	1
Hypertelorism	+		+		+	+			+					+								+	+		+					9
Epicanthal folds	+						+		+					+									+							5
Ptosis			+																											1
Small/ narrow palpebral fissures			+			+																						+		3
Upward slanting palpebral fissures				+		+																					+			3
Hypoplastic orbits					+		+		+					+									+			+				6
Prominent eyes						+			+				+	+									+							5
Epiblepharon + trichiasis						+																								1
Sparse eyebrows			+				+																							2
Absence of lateral eyebrows						+																								1
Long eyelashes																							+							1
Hypoplastic maculae																									+					1
Peters' anomaly															+															1
Preauricular skin tags		+																												1
Low-set ears			+	+		+			+				+	+		+						+	+	+		+			+	12
Posteriorly rotated ears						+																				+				2
Auricular malformation					+	+			+				+	+		+							+		+					8
Closed / absent ear canal					+											+			+											3
Beaked nose																							+							1
Wide / broad nasal bridge						+	+							+								+	+							5
Depressed nasal bridge	+												+									+				+				4
Long nose	+								+																					2
Short and narrow nose																												+		1
Flat nose																+														1
Prominent nose			+																											1
Broad nasal tip				+		+																								2
Anteverted nares							+																							1

Hypoplasia of nasal septum									+																					1
High arched palate				+									+	+											+				+	5
Narrow palate																												+		1
Posterior groove palate					+																									1
Cleft palate						+				+											+									3
Bifid uvula					+																									1
Smooth and/or long philtrum							+														+									2
Small mouth									+																					1
Widow's peak			+																											1
Low posterior hairline														+																1
Low anterior hairline																					+									1
Posteriorly combed hair appearance																					+									1
HAIR AND NAILS				+	+	+	+														+									5
Hypoplastic nails					+	+	+														+									4
Sparse scalp hair				+		+																								2
CRANIAL ANOMALIES	+		+		+	+	+		+				+	+		+				+	+				+	+	+	+		15
Craniosynostosis	+				+	+	+						+	+						+	+				+	+	+	+		12
Widely patent suture(s)	+						+													+										3
Large fontanelle(s)						+	+						+	+		+				+	+				+		+			9
Other fontanelle abnormalities	+				+		+																			+	+			5
Skull defects / hypoplasia			+			+			+					+							+								+	6
Absent ossification / undermineralization						+			+							+														3
LIMB ANOMALIES			+		+	+	+		+	+			+	+		+			+	+	+	+			+	+	+	+		17
Decreased extension elbows							+																							1
Flexion contractures thumbs			+																											1
Subluxation radial heads			+																											1
Absent distal epiphyseal plates of femur									+																					1
Absent ossification centers of distal femoral epiphyses														+																1
Radiohumeral fusions																												+		1
Mesomelia					+	+			+							+					+							+		6
Rhizomelia									+																			+		2
Club foot/feet													+						+									+		3
Missing metatarsal(s)/metacarpal(s)			+		+								+	+																4
Hypoplasia / absence of toe(s)			+			+				+				+							+				+	+				7
Hypoplasia / absence of finger(s)						+	+						+	+		+									+	+				7
Deformed thumb / abnormal thumb inplant					+				+							+														3
Broad great toes			+																											1
Accessory digits																			+											1
Long fingers									+											+		+								3
Finger syndactyly or webbing			+											+						+		+								4
Toe syndactyly					+					+																				2
Finger clinodactyly						+										+										+	+	+		5
Toe clinodactyly										+																				1
Abnormal palmar crease(s)			+		+	+								+											+					5
RIB/VERTEBRAL ANOMALIES		+			+									+		+	+							+						6
Rib anomalies / absent ribs		+												+		+	+													4
Kyphosis					+																									1
Scoliosis		+															+							+						3
Hemivertebrae		+			+											+								+						4

Fusion vertebral bodies / failed segmentation																+									+				2
CENTRAL CERVOUS SYSTEM ANOMALIES	+		+			+							+			+					+	+		+	+		+	+	11
Microcephaly (at last examination) †	+		+										+											+			+	+	6
Small grade I germinal matrix hemorrhage	+																												1
Moderate dilatation of lateral ventricles													+																1
Hydrocephalus						+																							1
Holoprosencephaly						+																		+					2
Periventricular white matter disease																					+								1
Choroid plexus cyst																+						+							2
Anencephaly																									+				1
Spina bifida																									+				1
NON-STRUCTURAL NERVOUS SYSTEM DISORDERS	+					+	+	+	+					+							+					+			8
Mild hypertonia (generalized)	+																												1
(Mild) hypotonia (generalized)						+	+		+					+															4
Vertical nystagmus						+																							1
Epilepsy / seizures						+		+													+								3
Abnormal reflexes									+																				1
Facial nerve palsy																										+			1
CARDIOVASCULAR ANOMALIES					+						+	+		+		+	+	+	+	+	+	+			+	+			12
Double-outlet right ventricle					+																								1
Tetralogy of Fallot																	+	+		+	+								4
Pulmonary atresia																	+		+										2
Hypoplastic left heart																+													1
Atrial septal defect / Patent foramen ovale					+																					+			2
Ventricular septal defect					+							+				+			+							+			5
Atrioventricular septal defect											+																		1
Transposed great arteries					+																								1
Pulmonary stenosis					+																								1
Patent ductus arteriosus					+																								1
Dextroposition heart														+											+				2
Aberrant right subclavian artery					+											+													2
Absent left and right pulmonary arteries																+													1
Aortapulmonary collaterals																			+										1
Two-vessel umbilical cord																+		+				+							3
RESPIRATORY TRACT ANOMALIES							+				+					+			+	+	+					+			7
Tracheal atresia																+													1
Anterior larynx																			+	+									2
Pulmonary hypertension							+																			+			2
Hypoplastic lungs											+					+													2
Horseshoe lung																						+							1
DIGESTIVE SYSTEM ANOMALIES					+	+	+		+		+			+		+			+										8
Liver palpable below right costal margin									+					+															2
Malrotated intestines																+			+										2
Duodenal atresia																+													1
Meckel's diverticulum																+													1
Multiple accessory spleens																+													1
Enlarged loft lobe on the liver																+													1
Diaphragmatic hernia											+																		1
Umbilical hernia					+	+	+																						3
URINARY TRACT ANOMALIES						+			+			+					+	+	+	+									7
Hydronephrosis						+						+							+										3

Vesicoureteral reflux																															1
Partial duplication ureter																															1
Absent kidney																															2
Horseshoe kidney																															1
Multicystic dysplastic kidney																															1
Abnormal renal position																															1
GENITAL ANOMALIES	+			+	+		+																				+				5
Bifid / shawl scrotum	+				+																										2
Micropenis	+																														1
Hypospadia	+			+																											2
Penile curvature				+																											1
Cryptorchidism				+																											1
Prominent labia																											+				1
Underdeveloped labia majora							+																								1
Hypertrophic clitoris							+																								1
Labia minora partially fused in the midline							+																								1
OTHER				+	+		+				+								+		+			+	+				+	9
Hearing loss				+															+					+							3
Sacral dimple							+				+																				2
Skin tag near anus																					+										1
Inguinal hernia																			+												1
Short / small thorax				+			+				+																				3
Hypoplastic nipples				+	+																										2
Wide-spaced nipples																								+							1
Diastasis recti					+																										1
Protruding abdomen							+																								1
Café au lait spot																														+	1
Swallowing dysfunction																			+												1
Prominent xiphoid process																											+				1
GENETIC TESTING	+		+	+	+	+		+		+	+		+					+		+	+			+							13
Abnormal karyotype	–		–	–	–	+		–		–	–		–					–		–	–			–								1
Other genetic testing								+[#]					+[§]					+[^]													3

[*]Birth weight < 10th percentile.
[†]Head circumference < 3th percentile.
[#]No microdeletion 22q11 and no tetrasomy 12p (Pallister-Killian).
[§]Normal chromosomal breakage study.
[^]No 22q11 microdeletion or duplication.
NA = not applicable.

Case	Author	Year
1	Adam (patient 4)	2003
2	Addar	2004
3	Bawle (patient 1)	1998
4	Bawle (patient 3)	1998
5	Buckley	1997
6	Corona-Rivera	2010
7	Del Campo	1999
8	Delatycki	2005
9	Diniz	1978
10	Granzow	2003
11	Krähenmann	2002
12	Lorenz	2007
13	Martin	2014
14	Milunsky	1968
15	Mulholland	2011
16	Nguyen	2002
17	Nurmohamed (patient 1)	2011
18	Nurmohamed (patient 2)	2011
19	Piggott (patient 1)	2011
20	Piggott (patient 2)	2011
21	Poggi	2011
22	Powell	1971
23	Seidahmed	2006
24	Singh	2009
25	Usta	2007
26	Zarella (patient 1)	2016
27	Zarella (patient 2)	2016
28	Zarella (patient 3)	2016
29	Zarella (patient 4)	2016

References

[1] A. Milunsky, J.W. Graef, M.F. Gaynor Jr., Methotrexate-induced congenital malformations, J. Pediatr. 72 (6) (1968) 790–795.
[2] Undp/Unfpa/Who/World Bank Special Programme of Research D, Research Training in Human R. Methotrexate for the termination of early pregnancy: a toxicology review, Reprod. Health Matters 5 (9) (1997) 162–167.
[3] H.E. Jones, White K. O'Connell, W.V. Norman, E. Guilbert, E.S. Lichtenberg, M. Paul, First trimester medication abortion practice in the United States and Canada, PLoS One 12 (10) (2017) e0186487.
[4] S.C. Hyoun, S.G. Obican, A.R. Scialli, Teratogen update: methotrexate. Birth defects research part A, Clin. Mol. Teratol. 94 (4) (2012) 187–207.
[5] B. Lewden, T. Vial, E. Elefant, A. Nelva, P. Carlier, J. Descotes, Low dose methotrexate in the first trimester of pregnancy: results of a French collaborative study, J. Rheumatol. 31 (12) (2004) 2360–2365.
[6] EUROCAT, EUROCAT Guide 1.4: Instruction for the Registration of Congenital Anomalies, EUROCAT Central Registry UoU, 2013.
[7] M.P. Adam, M.A. Manning, A.E. Beck, A. Kwan, G.M. Enns, C. Clericuzio, et al., Methotrexate/misoprostol embryopathy: report of four cases resulting from failed medical abortion, Am. J. Med. Genet. A 123a (1) (2003) 72–78.
[8] M.H. Addar, Methotrexate embryopathy in a surviving intrauterine fetus after presumed diagnosis of ectopic pregnancy: case report, J. Obstet. Gynaecol. Can. 26 (11) (2004) 1001–1003.
[9] E.V. Bawle, J.V. Conard, L. Weiss, Adult and two children with fetal methotrexate syndrome, Teratology 57 (2) (1998) 51–55.
[10] L.M. Buckley, C.A. Bullaboy, L. Leichtman, M. Marquez, Multiple congenital anomalies associated with weekly low-dose methotrexate treatment of the mother, Arthritis Rheum. 40 (5) (1997) 971–973.
[11] J.R. Corona-Rivera, A. Rea-Rosas, A. Santana-Ramirez, J. Acosta-Leon, J. Hernandez-Rocha, K. Miguel-Jimenez, Holoprosencephaly and genitourinary anomalies in fetal methotrexate syndrome, Am. J. Med. Genet. A 152a (7) (2010) 1741–1746.
[12] M. Del Campo, K. Kosaki, F.C. Bennett, K.L. Jones, Developmental delay in fetal aminopterin/methotrexate syndrome, Teratology 60 (1) (1999) 10–12.
[13] M.B. Delatycki, A de novo, apparently balanced reciprocal translocation in a child with developmental delay whose mother was being treated with low-dose methotrexate at the time of conception. Birth defects research Part A, Clin. Mol. Teratol. 73 (4) (2005) 253–254.
[14] E.M. Diniz, H.B. Corradini, J.L. Ramos, R. Brock, [Effect, on the fetus, of methotrexate (amethopterin) administered to the mother. Presentation of a case], Rev. Hosp. Clin. 33 (6) (1978) 286–290.
[15] J.W. Granzow, S.R. Thaller, Z. Panthaki, Cleft palate and toe malformations in a child with fetal methotrexate exposure, J. Craniofac. Surg. 14 (5) (2003) 747–748.
[16] F. Krahenmann, M. ØStensen, T. Stallmach, A. Huch, R. Chaoui, In utero first trimester exposure to low-dose methotrexate with increased fetal nuchal translucency and associated malformations, Prenat. Diagn. 22 (6) (2002) 489–490.
[17] L.B. Lorenz, E.J. Knudtson, Anomalies in a fetus exposed to methotrexate in the first trimester, Am. J. Pharmacol. Toxicol. 2 (4) (2007) 146–147.
[18] M.C. Martin, P. Barbero, B. Groisman, M.A. Aguirre, G. Koren, Methotrexate embryopathy after exposure to low weekly doses in early pregnancy, Reprod. Toxicol. 43 (2014) 26–29.
[19] C.P. Mulholland, T.J. Pollock, The Peters anomaly following antenatal exposure to methotrexate and hydroxychloroquine, Can. J. Ophthalmol. 46 (3) (2011) 289–290.
[20] C. Nguyen, A.J. Duhl, C.S. Escallon, K.J. Blakemore, Multiple anomalies in a fetus exposed to low-dose methotrexate in the first trimester, Obstet. Gynecol. 99 (4) (2002) 599–602.
[21] L. Nurmohamed, M.E. Moretti, T. Schechter, A. Einarson, D. Johnson, S.V. Lavigne, et al., Outcome following high-dose methotrexate in pregnancies misdiagnosed as ectopic, Am. J. Obstet. Gynecol. 205 (6) (2011) 533.e1-3.
[22] K.D. Piggott, A. Sorbello, E. Riddle, W. DeCampli, Congenital cardiac defects: a possible association of aminopterin syndrome and in utero methotrexate exposure? Pediatr. Cardiol. 32 (4) (2011) 518–520.
[23] S.H. Poggi, A. Ghidini, Importance of timing of gestational exposure to methotrexate for its teratogenic effects when used in setting of misdiagnosis of ectopic pregnancy, Fertil. Steril. 96 (3) (2011) 669–671.
[24] H.R. Powell, H. Ekert, Methotrexate-induced congenital malformations, Med. J. Aust. 2 (21) (1971) 1076–1077.
[25] M.Z. Seidahmed, M.M. Shaheed, O.B. Abdulbasit, Dohami H. Al, M. Babiker, M.A. Abdullah, et al., A case of methotrexate embryopathy with holoprosencephaly, expanding the phenotype. Birth defects research Part A, Clin. Mol. Teratol. 76 (2) (2006) 138–142.
[26] Y. Singh, A. Shankar, Fetal anomalies in rheumatoid arthritis patient exposed to low dose methotrexate, Med. J. Armed Forces India 65 (1) (2009) 80–81.
[27] I.M. Usta, A.H. Nassar, K.A. Yunis, A.A. Abu-Musa, Methotrexate embryopathy after therapy for misdiagnosed ectopic pregnancy, Int. J. Gynaecol. Obstet. 99 (3) (2007) 253–255.
[28] C.S. Zarella, F.P. Albino, A.K. Oh, B.C. Wood, C.O. Oluigbo, J.S. Myseros, et al., Craniosynostosis following fetal methotrexate exposure, J. Craniofac. Surg. 27 (2) (2016) 450–452.
[29] C. Weber-Schoendorfer, C. Chambers, E. Wacker, D. Beghin, N. Bernard, S. Shechtman, et al., Pregnancy outcome after methotrexate treatment for rheumatic disease prior to or during early pregnancy: a prospective multicenter cohort study, Arthritis & rheumatology (Hoboken, NJ) 66 (5) (2014) 1101–1110.
[30] M. Viswanathan, K.A. Treiman, J. Kish-Doto, J.C. Middleton, E.J. Coker-Schwimmer, W.K. Nicholson, Folic acid supplementation for the prevention of neural tube defects: an updated evidence report and systematic review for the US preventive services task force, Jama 317 (2) (2017) 190–203.
[31] J. Williams, C.T. Mai, J. Mulinare, J. Isenburg, T.J. Flood, M. Ethen, et al., Updated estimates of neural tube defects prevented by mandatory folic Acid fortification - United States, 1995-2011, MMWR Morb. Mortal. Wkly. Rep. 64 (1) (2015) 1–5.
[32] S. Hernandez-Diaz, M.M. Werler, A.M. Walker, A.A. Mitchell, Neural tube defects in relation to use of folic acid antagonists during pregnancy, Am. J. Epidemiol. 153 (10) (2001) 961–968.
[33] M. Feldkamp, J.C. Carey, Clinical teratology counseling and consultation case report: low dose methotrexate exposure in the early weeks of pregnancy, Teratology

47 (6) (1993) 533–539.
[34] M. Visentin, R. Zhao, I.D. Goldman, The antifolates, Hematol. Oncol. Clin. North Am. 26 (3) (2012) 629–648 ix..
[35] R.D. Kozlowski, J.V. Steinbrunner, A.H. MacKenzie, J.D. Clough, W.S. Wilke, A.M. Segal, Outcome of first-trimester exposure to low-dose methotrexate in eight patients with rheumatic disease, Am. J. Med. 88 (6) (1990) 589–592.
[36] M. Ostensen, H. Hartmann, K. Salvesen, Low dose weekly methotrexate in early pregnancy. A case series and review of the literature, J. Rheumatol. 27 (8) (2000) 1872–1875.