eurobiology of Aging, Vol. 13, pp. 73–81. © Pergamon Press plc, 1991. Printed in the U.S.A. 0197-4580/92 $5.00 + .00

Nimodipine Effects on Cerebral Microvessels and Sciatic Nerve in Aging Rats

G. I. DE JONG,*[1] A. S. P. JANSEN,* E. HORVATH,† W. H. GISPEN‡ AND P. G. M. LUITEN*

*Department of Animal Physiology, University of Groningen, Haren, The Netherlands
†Department of Neurobiology, Troponwerke, Cologne, FRG
and ‡Rudolf Magnus Institute of Pharmacology, University of Utrecht, The Netherlands

Received 7 February 1991; Accepted 25 June 1991

DE JONG, G. I., A. S. P. JANSEN, E. HORVATH, W. H. GISPEN AND P. G. M. LUITEN. *Nimodipine effects on cerebral microvessels and sciatic nerve in aging rats.* NEUROBIOL AGING **13**(1) 73–81, 1992.—At the ultrastructural level different anomalies of the cerebral microvasculature were encountered in the brains of aged rats. These aberrations can either be attributed to degeneration processes or to the perivascular deposition of, e.g., collagen fibrils and other, unidentified, proteinous debris. We previously reported that chronic treatment with the calcium antagonist nimodipine from 24–30 months especially reduced the incidence of aging-related microvascular deposits in the frontoparietal motor cortex of rats. The same drug treatment did not interfere with the degeneration of pericytes. The reduction of the microvascular depositions was, however, not consistent throughout different cortical layers. We now demonstrate that an earlier onset (16–30 months) of the drug application yields a prominent and consistent reduction of microvascular deposits for all cortical layers studied. The earlier onset of the drug treatment again did not influence the quantity of pericyte degeneration. The effect of long-term nimodipine treatment (16–30 months) was also examined in the sciatic nerve. Compared to young animals the sciatic nerve of aged control rats (30 months) showed a variety of alterations of myelinated fiber (MF) morphometry. Nimodipine treatment from 16–30 months did not significantly change these morphometric aging-related changes. Approximately 6% of the MF in aged rats display morphological myelin irregularities. After nimodipine application the frequency of these alterations was reduced, which was, however, only significant for partial demyelination known as myelin ballooning. These results indicate a consistent influence of nimodipine on cerebral microvessels, while there is only a moderate effect on the morphology of sciatic myelinated fibers during the aging process.

Aging Ultrastructure Microvasculature Motor cortex Sciatic nerve Myelinated fibers Morphometry 1,4-Dihydropyridine Nimodipine

AGING of the central nervous system (CNS) coincides with numerous functional and morphological alterations. With respect to the effects of aging on CNS vascular systems, a decreased cerebral blood flow (7), and morphological and ultrastructural changes of the cerebral microvasculature have previously been described in rodents. Aging-related morphological distortions of cerebral microvessels include microvascular fibrosis (9,14), pericyte degeneration (3) and thickening of the basement membrane (8,28), which have been considered to hamper adequate nutrient supply of the neuropil (19) and to disturb neuronal functioning (21).

Since long-term treatment with the 1,4,-dihydropyridine nimodipine (Bay E 9736) was shown to reduce the deterioration of motor performance in aging animals (23), we investigated the effects of such a long-term application of nimodipine on the microvasculature in the frontoparietal motor cortex (FRC). Nimodipine selectively blocks the calcium entry in L-type calcium channels (18) and exerts a preferential cerebrovascular action (12). Previously we have reported (11) that chronic nimodipine treatment from 24–30 months did not influence the degeneration of pericytes, but strongly reduced aberrant perivascular deposits of fibrillar and basement membrane material. The reduction of perivascular deposits, however, was not consistent throughout the different cortical layers.

Nimodipine was also shown to prevent aging-related reduction of nerve conduction velocity in the rat sciatic nerve (29). This reduction coincided with a moderate increase of myelinated fiber density in the sciatic nerve of aged, nimodipine-treated animals (29).

The purpose of the present study is to study the effects of chronic nimodipine application, starting at an earlier stage of the aging process (16–30 months), on cerebrovascular ultrastructure, as compared to the 24–30-month treated cases. We aimed to clarify 1) the differential effect of nimodipine treatment on pericyte degeneration and microvascular deposits, and 2) how the variability of the drug effect in the different cortical layer is influenced by an earlier onset of the drug treatment. Animals aged 16 and 24 months were also included in this study to determine the microvascular integrity at the age on onset of the nimodipine treatments. Furthermore, the effect of chronic nimodipine administration during aging is examined on myelinated fiber morphology and morphometric parameters, such as fascicular area and fiber density, fiber and axon diameter, degree of myelination (g-

[1]Requests for reprints should be addressed to G. I. de Jong, Department of Animal Physiology, P.O.B. 14, 9750 AA Haren, The Netherlands.

ratio) and index of circularity.

METHOD

Thirty male Wistar rats were used to study the effects of chronic nimodipine treatment on microvascular ultrastructure, six of which were treated with nimodipine (860 ppm in daily food) starting at the age of 24 months up to 30 months. A second group of six animals received a similar dose from 16–30 months. Three groups of six animals, respectively 16, 24 and 30 months of age, served as control groups. The dosage of the drug was based on previously demonstrated optimal pharmacological effects (23). The impact of long-term nimodipine treatment on aging-related morphological parameters of the myelinated fibers in the sciatic nerve were studied in six young adult animals (3 months), in the animals treated with nimodipine from 16–30 months (n = 6) and in five animals of the aged control group (30 months). The latter two groups included the same animals used for the examination of the cerebral microvessels. All animals had free access to food and water and were checked daily on physical health conditions.

Upon termination of the experiment the animals were deeply anaesthetized with sodium pentobarbital (60 mg/kg, IP) and transcardially perfused with 2% glutaraldehyde, 1% paraformaldehyde and 3% polyvinyl pyrolidone in 0.1 M phosphate buffer (pH 7.38). Brains and a part of the sciatic nerve, 1 cm distal to the sciatic bifurcation with a length of approximately 1 mm, were removed. Subsequently the brains were cut into 50 μm sections with a vibratome (Oxford). The vibratome sections and sciatic nerve samples were routinely postfixed in 1% osmium tetroxide, stained en bloc with 1% aqueous uranyl acetate, dehydrated in ethanol and propylene oxide and embedded in epon. Semi- and ultrathin sectioning was performed with a Reichert microtome. Ultrathin sections were contrasted with uranyl acetate and Reynolds lead solution and examined with a Philips 201 electron microscope.

Morphometric Examination of Cerebral Microvessels

Of the epon-embedded tissue, ultrathin sections spanning all cortical layers were collected at 200 mesh grids and ultrastructurally examined. Based on previous examinations (11) microvascular aberrations in the aged brain were categorized as 1) membranous inclusions within the basement membrane, 2) microvascular fibrosis, 3) basement membrane thickening (BMT), and 4) a miscellaneous group of more rare deposition products within endothelial cells. The number of microvessels which showed one of the above-mentioned aberrations were counted in layers 1, 3, and 5 of the frontoparietal motor cortex directly from the screen of the electron microscope, as previously described (11). When two categories of microvascular anomalies were encountered within one transverse sectioned microvessel this was separately scored, however, this occured in far less than 1% of the aberrant microvessels examined. When studying the tissue sections, the experimenter was unaware of the kind of treatment given. From the quantitative data we calculated the percentage microvessels which displayed either 1) membranous inclusions, indicative for pericyte degeneration or 2) microvascular deposits, identified either by microvascular fibrosis or BMT or other rare deposition products. The quantitative results were evaluated using the Mann-Whitney U-test, with statistical significance defined as $p<0.05$.

Morphometric Examination of Sciatic Nerve Myelinated Fibers

Semithin transverse sections of the sciatic nerve with a constant thickness of 1 μm were stained with toluidine blue and analyzed with a computerized image analyzing system (Quantimet 520, Cambridge). The fascicular area of the sciatic nerve was measured at a magnification of 10×2, while all other parameters were obtained using a magnification of 10×100. Measure frames of a constant size (2500 μm^2) were systematically sampled in x and y traverse of the fascicular area. Myelinated fibers (MF) situated completely or partly within the frame were measured. A sample size of 1000 MF per nerve was used for each animal. The number of MF per fascicle and per mm^2 were calculated from extrapolation of the studied area. Of each individual MF fiber area and axon area were determined and the equivalent diameter of the fiber and axon were calculated as the diameter of a circle with an equal to the measured area. The g-ratio of the MF was calculated as the ratio axon diameter/fiber diameter in which the value of g expresses the relative thickness of the myelin sheath (6). Furthermore, the index of circularity (IC) was calculated as the ratio axon area/area of a circle with the same perimeter (1). Finally, the number of myelin irregularities was counted directly from the computer screen, and expressed as percentage of the total MF population. These myelin irregularities included 1) infolded myelin loops, 2) reduplication, 3) myelin "ballooning," and 4) remyelinated fibers. In the transverse sections one MF displayed only one category of myelin irregularities. The morphometric data were statistically tested with an ANOVA. When the ANOVA indicated group differences the separate groups were tested with corrected multiple *t*-tests. The relative frequency of myelin irregularities were statistically evaluated using the Mann-Whitney U-test. Statistical significance was defined as $p<0.05$.

RESULTS

Cerebral Microvascular Integrity

As was defined in a previous report (11), microvascular anomalies in the frontoparietal motor cortex in aged rats can roughly be divided into two categories. The first is represented by inclusions of membranous material within the basement membrane (Fig. 1A). Ultrastructural examinations revealed that these membranous inclusions most likely reflect the degeneration of pericytes (3,11). The second category is not attributed to degenerative mechanisms but has been imputed to deposition processes. These aging-related microvascular deposits can contain collagen fibrils (Fig. 1B) or basement membrane material (Fig. 1C). The deposition of collagen fibrils within the microvascular basement membrane has previously been designated as microvascular fibrosis (11,14). The amount of collagen varied from one single fibril up to more than twenty fibrils, which all displayed a characteristic banded pattern with a periodicity of approximately 64 nm. The deposition of basement membrane material leads to a subsequent basement membrane thickening (BMT), which has been reported as an aging-related phenomenon by several authors (8,28). Moreover, microvascular deposits include rare accumulation products such as lipid droplets within the endothelium (Fig. 1D).

The percentage of microvessels with membranous inclusions within the basement membrane in layers 1, 3, and 5 of the motor cortex in the different age and nimodipine-treated groups is shown in Fig. 2. In all three cortical layers examined (FRC 1, 3 and 5), animals of 16 months revealed far less microvessels with membranous inclusions than animals aged 24 months (all layers $p<0.01$). Moreover, significantly more cerebral microvessels showed membranous inclusions in aged (30 months) control animals compared to the control group of 24 months ($p<0.05$; $p<0.01$; $p<0.05$, respectively), which confirms the aging-re-

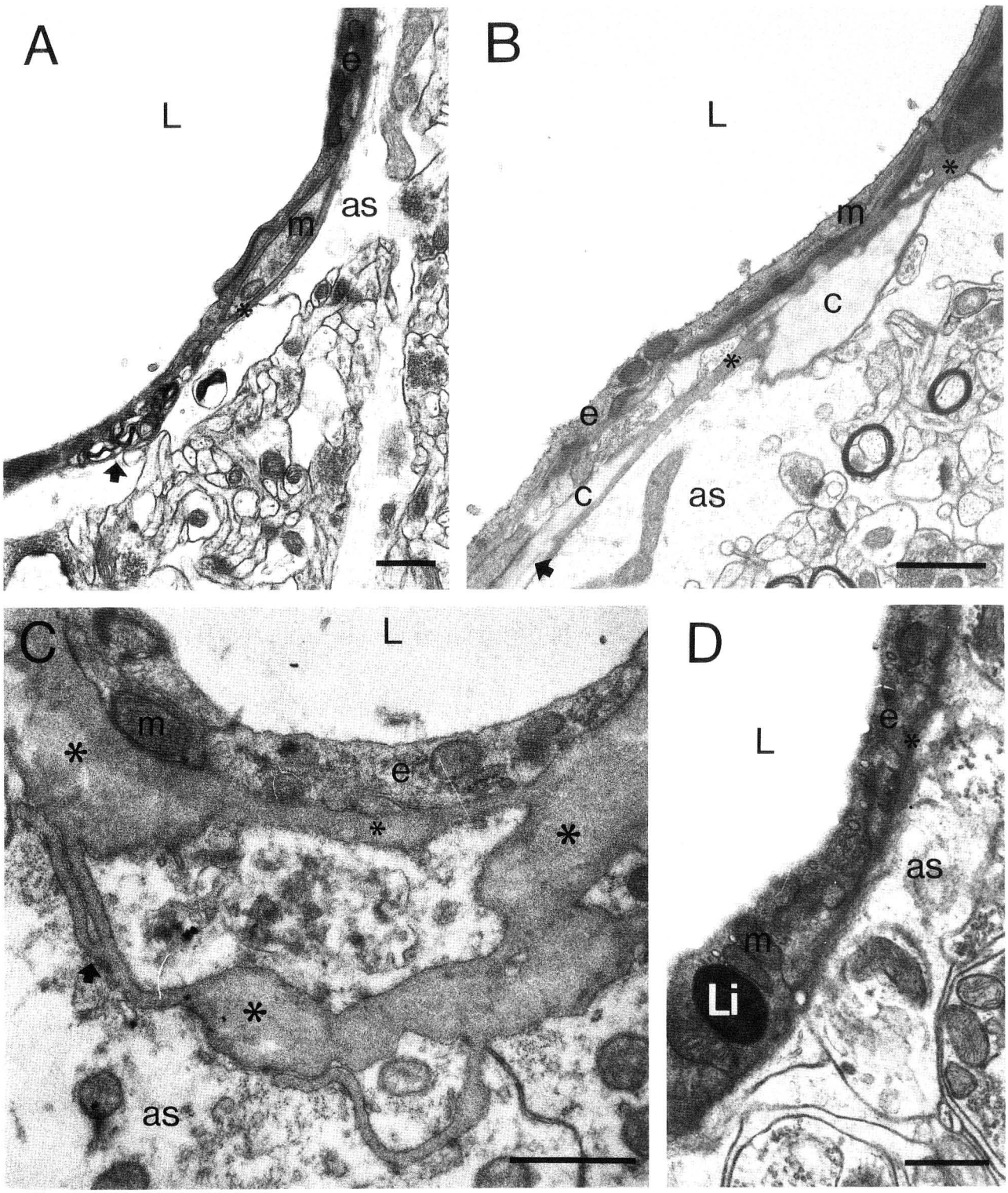

FIG. 1. (A) A membranous inclusion (arrow) within the basement membrane which can be distinguished from normal appearance of pericyte cytoplasm containing mitochondria (m). (B) Shows the deposition of collagen fibrils (c), which display a banded pattern (arrow) within the basement membrane. (C) An example of extensive thickening of the basement membrane. Reduplication of the basement membrane is indicated by an arrow. (D) Displays a lipid droplet (Li) deposited within the endothelium. Abbreviations: as—astrocytic endfeet; e—endothelium; L—microvascular lumen; m—mitochondrion; asterisk—basement membrane. Scale bars for A, B, C = 1 μm; D = 0.5 μm.

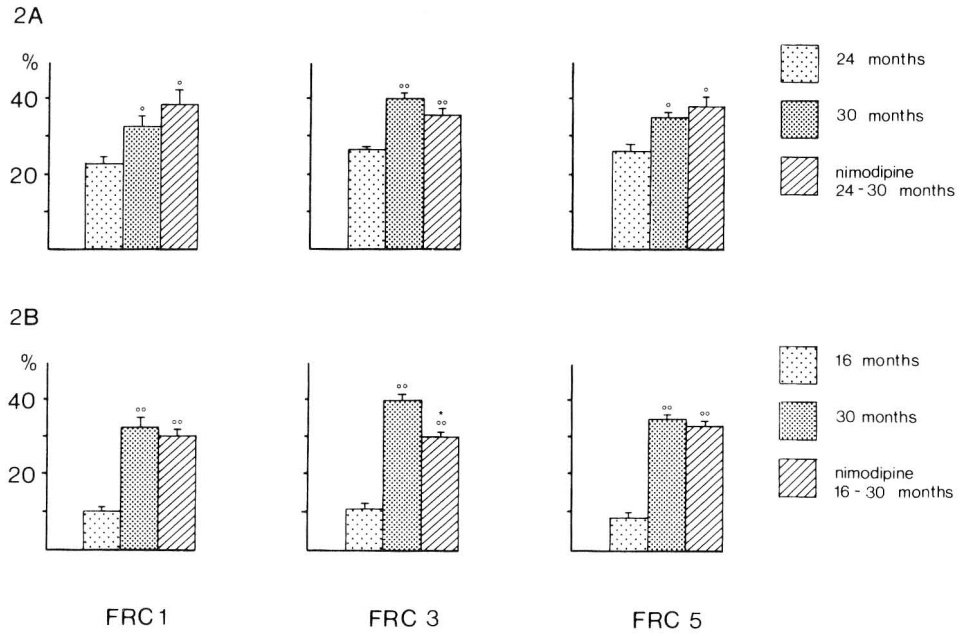

FIG. 2. (A) The incidence of membranous inclusions within the basement membrane in layers 1, 3 and 5 of the frontoparietal motor cortex (FRC) is shown for animals aged 24 and 30 months and of rats treated with nimodipine from 24–30 months. (B) Displays the incidence of membranous inclusions in animals aged 16 and 30 months and the animals treated from 16–30 months. [Mean percentages ±s.e.m.; °$p<0.05$ compared to control; °°$p<0.01$ compared to control (16 or 24 months); *$p<0.05$ compared to aged control; **$p<0.01$ compared to aged control (30 months).]

lated nature of this microvascular anomaly. Treatment with nimodipine from 24–30 (Fig. 2A) did not yield any significant changes in the percentage of microvessels displaying membranous inclusions within the basement membrane of aged rats. The average values of the drug-treated animals of 16–30 months (Fig. 2B) were slightly lower than the 30 months controls, which was only significant in FRC 3 ($p<0.05$). This indicates that nimodipine application has no prominent impact on the degeneration of microvascular pericytes occurring with senescence.

The formation of microvascular deposits, on the other hand, underwent a strong influence of the nimodipine application (Fig. 3). This category of microvascular aberration did also show an aging-related nature, since the percentage of microvessels with deposits significantly increased with advancing age (compare values of 16, 24 and 30 months). Administration of nimodipine from 24–30 months (Fig. 3A) resulted in a significant reduction of the amount of microvessels displaying deposits in layers 1 and 3 (both layers $p<0.01$). There was also an average decrease in FRC layer 5 in the treated cases, which did not, however, reach statistical significance. The frequency of microvessels with deposits in the animals treated from 24–30 months was significantly increased compared to the 24-month control cases ($p<0.05$), while in layers 1 and 3 this percentage was not significantly different and significantly reduced ($p<0.01$), respectively. Earlier onset of the nimodipine treatment at the age of 16 months (Fig. 3B) yielded a significant reduction of the frequency of microvessels displaying deposits in layers 1, 3 and also in layer 5 ($p<0.05$, $p<0.01$ and $p<0.01$, respectively). The incidence of microvessels with aberrant deposits in the animals treated from 16–30 months was moderately albeit significantly increased as compared to the animals aged 16 months ($p<0.05$ in all three layers). This indicated that nimodipine treatment did not result in a complete prevention of the development of microvascular deposits during aging.

In conclusion, the administration of nimodipine from 16–30 months did not exert a prominent influence on the process of pericyte degeneration during aging. On the other hand, the early onset of nimodipine treatment yielded a consistent and significant reduction in the percentage microvessels with deposits in layers 1, 3 and 5 of the frontoparietal motor cortex.

Sciatic Nerve Myelinated Fibers

The myelinated fiber (MF) density (MF/mm^2) was significantly less in aged control and aged, nimodipine-treated groups ($p<0.01$), while the fascicular area of the sciatic nerve was slightly, albeit not significantly, increased during aging (Table 1). The number of MF per fascicle revealed a significant loss of MF of approximately 30% in the sciatic nerve of aged animal (both aged groups $p<0.05$). There was no significant difference between the aged control and aged-treated group.

The mean fiber diameter was significantly larger in both aged groups ($p<0.01$), as was the mean diameter of axons (Table 1; aged group $p<0.05$, nimodipine group $p<0.01$). No significant differences were detectable between the aged control and the aged group treated with nimodipine.

The size-frequency histograms of the equivalent diameter of axons (Fig. 4A) revealed a unimodal distribution in all three groups. The axon diameter ranged from 1–9 μm in young animals and from 1–13 μm in the aged groups. The number of larger axons increased with aging, which is illustrated by a shift of the histogram bars towards the higher diameter values. The axon size-frequency histograms of aged and aged nimodipine treated animals showed no difference. The fiber size-frequency histograms of Fig. 4B displayed a bimodal character. The MF diameter varied from 1–12 μm in young adults from 1–18 μm in aged animals. Furthermore, the bimodal nature of the histogram becomes more prominent in each of the aged groups, while

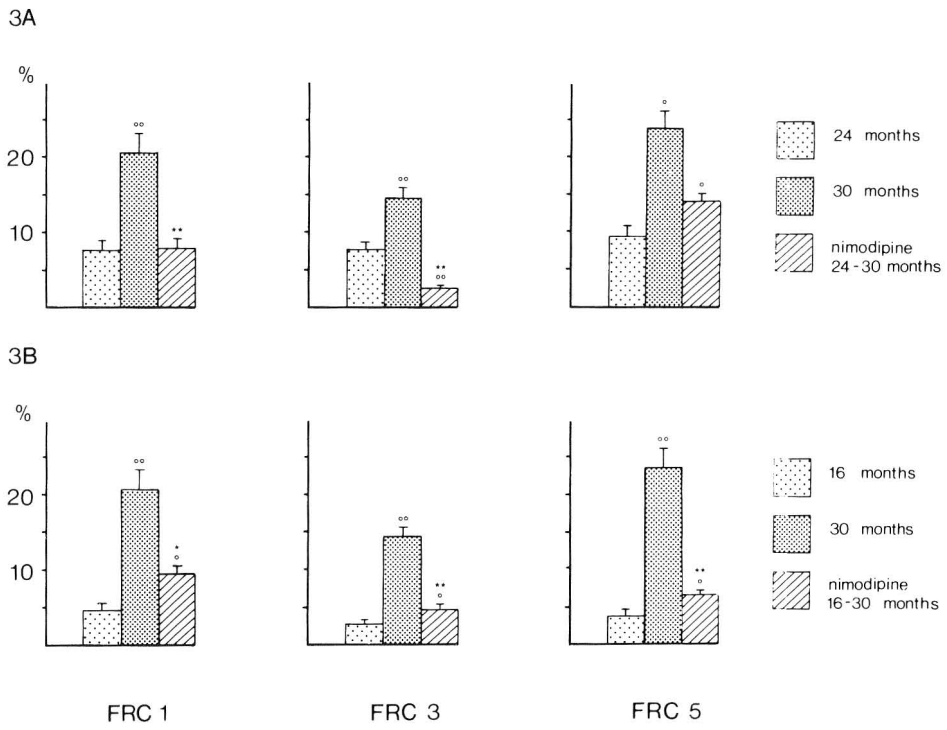

FIG. 3. The amount of microvascular deposits in layers 1, 3 and 5 of the frontoparietal motor cortex (FRC) in (A) animals 24 and 30 months of aged and treated from 24–30 months and in (B) rats aged 16 and 30 months after a treatment period of 16–30 months. (Mean percentages ± s.e.m., °$p<0.05$ compared to control; °°$p<0.01$ compared to control (16 or 24 months); *$p<0.05$ compared to aged control; **$p<0.01$ compared to aged control (30 months).]

no difference between aged and aged, nimodipine-treated groups was present. Both the mean values (Table 1) and the histograms (Fig. 4) indicated an increased diameter of axons as well as MF with aging. Chronic nimodipine treatment did not influence these aging-related alterations.

Also the mean g-ratio of MF was not significantly altered in aged or aged, nimodipine-treated rats (Table 1), while the index of circularity (IC, Table 1) was significantly smaller in aged and nimodipine groups compared to young controls ($p<0.01$). Moreover, the standard error of the mean (s.e.m.; Table 1) is smaller for most of the parameters examined in the nimodipine-treated animals as compared to aged controls. This may probably result from regulatory effects of nimodipine on the aging process within the sciatic nerve.

When the g-ratio is plotted against fiber calibre, there appears slight evidence for two fiber populations in the young animals (Fig. 5A). Such a subdivision in two populations was less obvious in the scatter diagrams of aged and aged, nimodipine-treated rats (Figs. 5B and 5C). The diagrams showed a remarkable increased scatter in both aged groups, indicating that aged rats displayed considerable more fibers with an aberrant g-ratio.

Light microscopic examination revealed no prominent morphological aberrations of blood vessels within the sciatic nerve, while several types of myelin distortions were present. Myelin irregularities were divided into four categories (Fig. 6) including 1) infolded myelin loops, characterized by an inward circle of myelin, 2) reduplication, where a part of the myelin sheath is reduplicated situated as an oval shape against the inner border of the sheath, 3) myelin ballooning, in which the axon is enclosed by a thin myelin sheath, surrounded by a secondary expanded myelin sheath, and 4) remyelinated fibers defined as axons with a relatively thin myelin sheath. These remyelinated fibers were mostly small of size. In the young adults infoldings and remyelinated fibers rarely occurred, whereas myelin ballooning and reduplication were not encountered (Table 2). The incidence of all myelin irregularities significantly increased during aging. In all four categories the incidence was slightly reduced in the nimodipine-treated animals compared to the aged controls (Table 2). This reduction was, however, only significant for the myelin balloon formation ($p<0.05$).

TABLE 1

MORPHOMETRIC PARAMETERS OF MYELINATED FIBERS OF THE SCIATIC NERVE IN YOUNG (3 MONTHS) AGED (30 MONTHS) AND AGED, NIMODIPINE-TREATED (16–30 MONTHS) RATS (MEANS ± S.E.M.)

	Young	Aged	Nimodipine
Fasc. area (mm^2)	0.722 (0.06)	0.849 (0.13)	0.955 (0.12)
MF/mm^2	16475 (452)	10281 (750)†	9263 (461)†
MF/fasc.	12861 (1203)	8587 (1449)*	8896 (1241)*
Fiber dia. (μm)	6.63 (0.10)	7.82 (0.28)†	7.96 (0.17)†
Axon dia. (μm)	3.83 (0.09)	4.36 (0.18)*	4.51 (0.08)†
G-ratio	0.575 (0.03)	0.561 (0.05)	0.566 (0.05)
I.C.	0.762 (0.03)	0.703 (0.05)†	0.711 (0.05)†

Student's *t*-test.
*Significantly different from young controls with $p<0.05$.
†Significantly different from young controls with $p<0.01$.

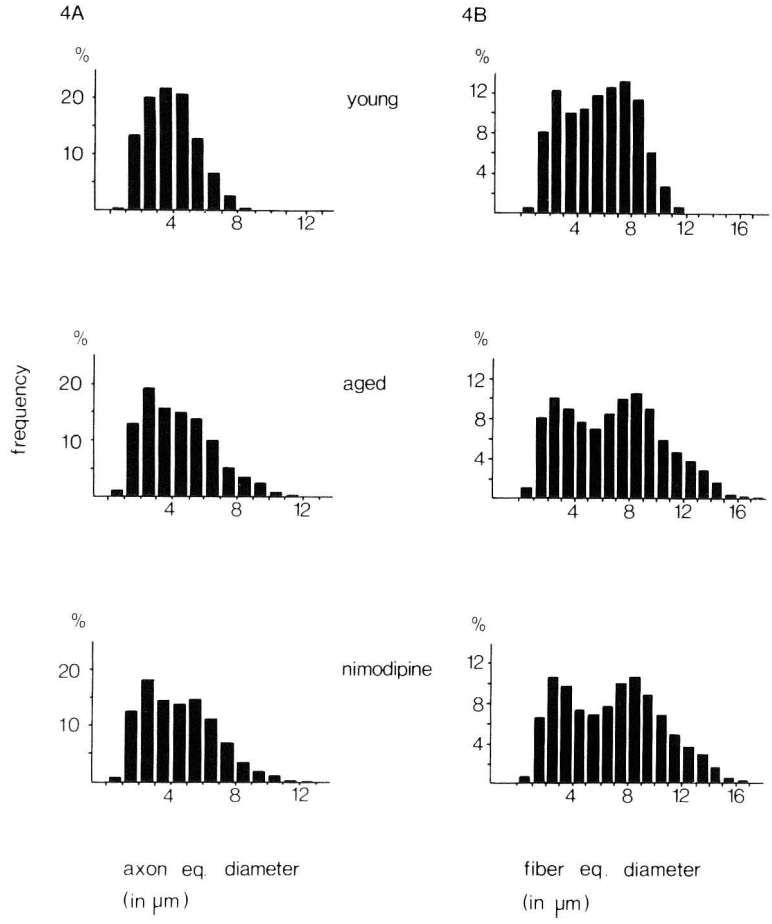

FIG. 4. Size frequency histograms of (A) axon and (B) fiber equivalent diameter (in μm) for young adult (3 months), aged (30 months) and aged, nimodipine-treated (16–30 months) animals (in percentages).

DISCUSSION

Cerebral Microvascular Integrity

The aging-related nature of the ultrastructural alterations of cerebral microvasculature has previously been described and was confirmed in the present study, since the incidence of all aberrations described above gradually increased with advancing age. In a preceding study we have shown that membranous inclusions, indicative for degenerating pericytes, were abundantly present in the microvascular wall of the aged rat motor cortex and hippocampus CA1. We also described that chronic treatment with the calcium entry blocker nimodipine from 24–30 months did not influence the amounts of microvessels with such membranous inclusions within the basement membrane (11). In the current investigation we found that treatment with nimodipine starting at the age of 16 months until 30 months of age did only slightly reduce the incidence of degenerative pericytes in layer 3 of the FRC. So it may be concluded that chronic application with the calcium antagonist nimodipine does not exert a prominent influence on the degeneration process of pericytes within the microvascular wall in senescence.

TABLE 2

MYELIN IRREGULARITIES IN YOUNG (3 MONTHS), AGED (30 MONTHS) AND AGED, NIMODIPINE-TREATED (16–30 MONTHS) RATS (IN PERCENTAGE OF THE TOTAL MYELINATED FIBER POPULATION ±S.E.M.)

	Young	Aged	Nimodipine
Infolding	0.29 (0.03)	3.47 (0.70)†	3.28 (0.32)†
Reduplication	0 (0)	0.61 (0.14)*	0.40 (0.08)†
Ballooning	0 (0)	0.66 (0.23)†	0.28 (0.13)†‡
Remyelination	0.12 (0.05)	1.51 (0.28)*	1.17 (0.16)†

Mann-Whitney U-test.
*Significantly from young controls with $p<0.05$.
†Significantly different from young controls with $p<0.01$.
‡Significantly different from aged controls with $p<0.05$.

Treatment with nimodipine from 24–30 months resulted in a significant reduction of the percentage microvessels showing deposits in layer 1 and layer 3 of the frontoparietal motor cortex (11). Such a reduction in the formation of these perivascular anomalies, however, was not significant in layer 5 of the FRC. In the present study we showed that treatment from 24–30 months prevented the development of microvascular deposits after the age of 24 months in layers 1 and 3 of the FRC. An earlier onset of the drug treatment yielded a significant reduction of the amount of microvessels with deposits in layers 1 and 3, as

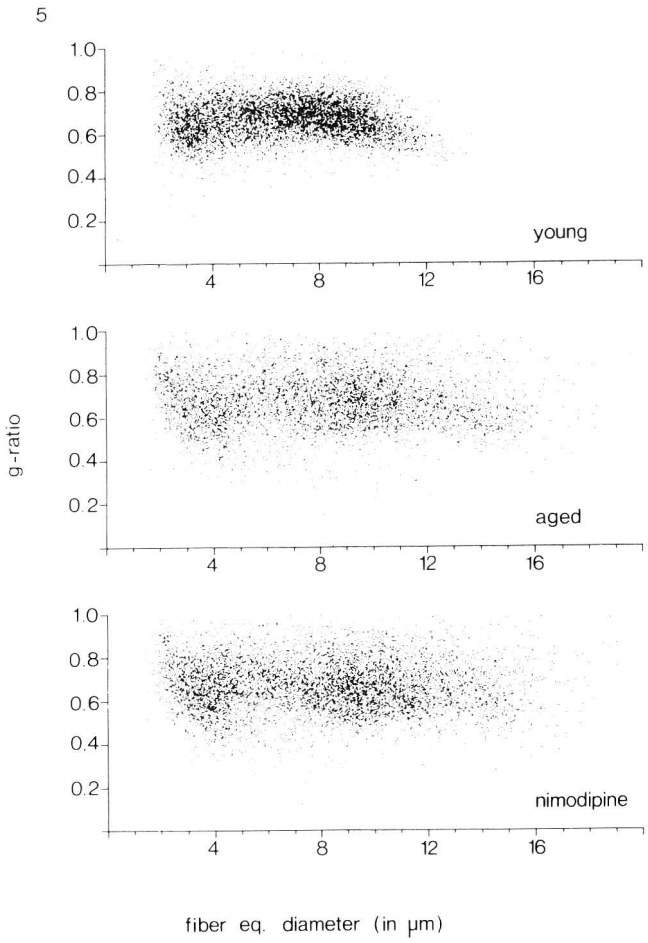

FIG. 5. Scatter diagrams of the g-ratio plotted against fiber diameter (in μm) for young adult (3 months), aged (30 months) and aged, nimodipine-treated animals (16–30 months).

well as in layer 5. This earlier started treatment could, however, not entirely prevent the aging-related deposition of, e.g., collagen fibrils and basement membrane material, since the percentages of cerebral microvessels with deposits was slightly by significantly higher than the percentages in the control group at the age of 16 months. Nevertheless, the chronic nimodipine treatment from 16–30 months revealed a very prominent reduction on aging-related microvascular alterations.

With respect to the interlaminar variation in the cortex a consistent pattern was observed in all groups. The highest percentage of microvessels with deposits was recorded in layer 5 of the motor cortex, while in FRC layer 3 of the motor cortex the amount of microvascular deposits was relatively small. Furthermore, the nonconsistent nimodipine effect in the different cortical layers, previously found after treatment from 24–30 months, was not any more present when the animals were treated from 16–30 months. The effect of nimodipine application is proportional to the incidence of deposits, and therefore can be considered to be consistent throughout the different cortical layers. A differential susceptibility to the aging process of layer 5 of the frontoparietal motor cortex may account for the variable effect of nimodipine, when administered from 24–30 months.

Microvascular aberrations that occur during aging have been proposed to underlie a disturbed nutrient transport over the blood-brain barrier and subsequent impairment of nutrient supply to the neuropil (19). Via these processes the reported nimodipine effects may partially add to an improved neuronal functioning of the frontoparietal motor cortex and other cortical areas during aging. This is substantiated by the behavioral observations that nimodipine treatment significantly ameliorated motor and cognitive functioning in aged rats (23). Research is underway including (immuno)histochemistry of several markers for neuronal activity and metabolism to establish aging-related differences in neuronal functioning and the effects thereupon of nimodipine.

A balanced calcium homeostasis is of crucial importance for the optimal performance of neuronal electrical and biochemical activities. An increased intracellular calcium concentration has been reported in ischemia (26), as well as in aging (16), and is assumed to play a key role in neuronal malfunction and cell damage. Nimodipine can counteract these aging-related alterations of neuronal functioning (16,17). Nimodipine acts on the L-type calcium channel (18) and binding sites for this drug have been localized in neuron rich areas, such as hippocampus, cerebellum and cerebral cortex (2). Not only neuronal (2,4), but also microvascular (4,20) binding sites have been identified, which display similar if not identical properties (4). Nimodipine binding on microvessels in the aged brain has previously been related to an increased cerebral blood flow (12). Our data suggest that, besides an effect on cerebral blood flow, and a direct neuronal action, nimodipine exerts an influence on the cortical microvascular integrity as well.

Sciatic Nerve Myelinated Fibers

The fascicular area of the proximal sciatic nerve was slightly increased in aged rats, which was also reported for the peroneal nerve of aged rats (15). Literature concerning aging-related loss of myelinated fibers (MF) in peripheral nerves has been contradictory. Some authors reported MF loss in hindlimb nerves of aged rodents (13,15) and humans (10), which is in agreement with the 30% MF loss reported in this study, whereas others did not find any such changes (25,27). The mean equivalent axon diameter was increased in aged animal, which was also described for the peroneal nerve of aged rats (15). Long-term administration of nimodipine did not affect fiber density, fascicle area, and axonal and fiber diameter.

The axonal size-frequency histogram was characterized by a unimodal distribution. This distribution pattern was previously described for rodents in several peripheral nerves (5,27). The fiber equivalent diameter increases with senescence, which was also shown by Stanmore et al. (27). The bimodality of the fiber diameter distribution has earlier been described for the, e.g., sural and sciatic nerves of rodents (6,27). The bimodal nature of the fiber size-frequency distribution became more pronounced during aging as was also reported by Stanmore et al. (27).

Two subpopulations can be derived from the scatter plots of the g-ratio (ratio axon diameter/fiber diameter) and fiber equivalent diameter (5). The increased scatter in these diagrams during aging has previously been observed by Jacobs and Love (10) in the sural nerve of aged humans. The mean g-ratio did not change in the different groups and approached the optimal theoretical value of 0.6 for nerve conduction velocity (22). Since the g-ratio is a relative measure for the thickness of the myelin sheath, the increased variation in the scatter plots indicate that with aging more myelinated fibers display either a relatively thin (high g-ratio) or a thick (low g-ratio) myelin sheath. A relatively thick sheath can be attributed to those fibers provided with infolded loops of myelin or reduplication, while a relatively thin sheath can be imputed to remyelinated fibers.



FIG. 6. A part of a transversely cut sciatic nerve of an aged rat (30 months), stained with toluidine blue. Besides normal myelinated fibers, infoldings (arrowhead), reduplication (large arrow), balloons (asterisk; ax: axon) and remyelinated fibers (small arrow) can be observed.

Kazui et al. (13) showed that in the sciatic nerve of aged rats 5–6% of the MF display myelin aberrations, which is in agreement with our data. The incidence of myelin irregularities is increased with aging and tended to be smaller in the nimodipine-treated animals. This reduction was significant only for the myelin balloon formation.

Using a different experimental design, van der Zee et al. (29) have shown that the decline of the nerve conduction velocity in the sciatic nerve of animals aged 29 months can be significantly reduced by chronic nimodipine administration starting at the age of 24 months. These authors administered nimodipine to animals, which were selected on poor motor functioning at the age of 24 months. In their nimodipine-treated animals the nerve conduction velocity was higher compared to aged matched controls, which coincided with a moderate but significant increase in MF density. In the current investigation nimodipine was given to randomly chose animals at the age of 16 months. The nimodipine-treated animals showed less individual variation for most parameters examined compared to the aged controls. The drug treatment yielded significant group effects only on the incidence of myelin ballooning in the sciatic nerve. The latter effect alone, however, cannot account for the increased nerve conduction velocity in aged nimodipine-treated rats. The present findings corroborate with previously reported assumptions (15), which suggest that the alterations in peripheral nerve morphology are not sufficient to explain the dramatic decrease in nerve conduction velocity during aging.

Within the same animals, however, a prominent effect of nimodipine treatment on aging-related cerebral microvascular deposits was established. These results indicate that nimodipine exerts a powerful influence aging-related changes in microvascular morphology in the central nervous system, while the effect on the peripheral sciatic nerve is limited and confined to some categories of myelin distortion.

ACKNOWLEDGEMENTS

The authors wish to thank H. de Weerd and the photographic service of the Department of Histology and Cell Biology. We are grateful for the advise of I. Stokroos on the morphometric image analyzing system. Furthermore, we appreciate the assistance of Hans Beldhuis with the preparation of this manuscript.

REFERENCES

1. Arbuthnott, E. R.; Ballard, K. J. Boyd, I. A.; Kalu, K. U. Quantitative study of the noncircularity of myelinated peripheral nerve fibres in the cat. J. Physiol. 308:99–123; 1980.
2. Belleman, P.; Schade, A.; Towart, R. Dihydropyridine receptor in rat brain labelled with [3-H]nimodipine. Proc. Natl. Acad. Sci. USA 80:2356–2360; 1983.
3. Casey, M. A.; Feldman, M. L. Aging in the rat medial nucleus of the trapezoid body. III. Alteration in capillaries. Neurobiol. Aging 6:39–46; 1985.
4. Dooley, D. J.; Mahlmann, H.; Brenner, O.; Osswald, H. Characterization of the dihydropyridine binding sites of rat neocortical synaptosomes and microvessels. J. Neurochem. 49:900–904; 1987.
5. Fraher, J. P.; O'Leary, D.; Moran, M. A.; Cole, M.; King, R. H. M.; Thomas, P. K. Relative growth and maturation of axon size and myelin thickness in the tibial nerve of the rat. I. Normal animals. Acta Neuropathol. (Berl.) 79:364–374; 1990.

6. Friede, R. L.; Beuche, W. Combined scatter diagrams of sheath thickness and fibre calibre in human sural nerves: changes with age and neuropathy. J. Neurol. Neurosurg. Psychiatry 48:749–756; 1985.
7. Goldman, H.; Berman, R. F.; Gershon, S.; Murphy, S. L.; Altman, H. J. Correlation of behavioral and cerebrovascular functions in the aging rat. Neurobiol. Aging 8:409–416; 1987.
8. Heinsen, H.; Heinsen, Y. L. Cerebellar capillaries. Qualitative and quantitative observations in young and senile rats. Anat. Embryol. (Berl.) 168:101–116; 1983.
9. Hinds, J. W.; McNelly, N. A. Capillaries in aging rat olfactory bulb: a quantitative light and electron microscopic analysis. Neurobiol. Aging 3:197–207; 1982.
10. Jacobs, J. M.; Love, S. Qualitative and quantitative morphology of human sural nerve at different ages. Brain 108:897–924; 1985.
11. Jong, G. I., de; de Weerd, H.; Schuurman, T.; Traber, J.; Luiten, P. G. M. Microvascular changes in aged rat forebrain. Effects of chronic nimodipine treatment. Neurobiol. Aging 11:381–389; 1990.
12. Kazda, S.; Towart, R. Nimodipine, a new calcium antagonist drug with a preferential cerebrovascular action. Acta Neurochir. (Wien) 63:259–265; 1982.
13. Kazui, H.; Fujisawa, H. Radiculoneuropathy of ageing rats: a quantitative study. Neuropathol. Appl. Neurobiol. 14:137–156; 1988.
14. Knox, C. A.; Yates, R. D.; Chen, L.; Klara, P. M. Effects of aging on the structural and permeability characteristics of cerebrovasculature in normotensive and hypertensive strains of rats. Acta Neuropathol. (Berl.) 51:1–13; 1980.
15. Knox, C. A.; Kokmen, E.; Dyck, P. J. Morphometric alteration of rat myelinated fibers with aging. Neuropathol. Appl. Neurobiol. 48: 119–139; 1989.
16. Landfield, P. W. Increased calcium currents in rat hippocampal neurones during aging. In: Morad, M.; Nayler, W.; Kazda, S.; Schramm, M., eds. The calcium channel: Structural, function and implications. Berlin: Springer-Verlag; 1988:465–477.
17. Landfield, P. W.; Pitler, T. A. Prolonged Ca2+-dependent afterhyperpolarizations in hippocampal neurons of aged rats. Science 226: 1089–1092; 1984.
18. Miller, R. J. Multiple calcium channels and neuronal function. Science 235:46–52; 1987.
19. Mooradian, A. D. Effect of aging on the blood-brain barrier. Neurobiol. Aging 9:31–39; 1988.
20. Morel, N.; Godfraind, T. Cerebrovascular effect of calcium antagonists. Eur. Neurol. 30(2):10–15; 1990.
21. Ravens, J. R. Vascular changes in human senile brain. In: Cervos-Navarro, J., ed. Pathology of the cerebral microcirculation, vol. 20. New York: Raven Press; 1978:487–501.
22. Rushton, W. A. H. A theory of the effects of fibre size in medullated nerve. J. Physiol. 115:101–122; 1951.
23. Schuurman, T.; Klein, H.; Beneke, M.; Traber, J. Nimodipine and motor deficits in the aged rat. Neurosci. Res. Commun. 1:9–15; 1987.
24. Sciabine, A.; Schuurman, T.; Traber, J. Pharmacological basis for the use of nimodipine in central nervous system disorders. FASEB J. 3:1799–1806; 1989.
25. Sharma, A. K.; Bajada, S.; Thomas, P. K. Age changes in the tibial and plantar nerves of the rat. J. Anat. 130(2):417–428; 1980.
26. Siesjo, B. K.; Wieloch, T. Brain ischemia and cellular homeostasis. In: Goodman, T., et al., eds. Calcium entry blockers and tissue protection. New York: Raven Press; 1985:139–149.
27. Stanmore, A.; Bradbury, S.; Weddell, A. G. M. A quantitative study of peripheral nerve fibres in the mouse following the administration of drugs. 1. Age changes in untreated CBA mice from 3 to 21 months of age. J. Anat. 127(1):101–115; 1978.
28. Topple, A.; Fifkova, E.; Cullen-Dockstader, K. Effect of age on blood vessels and neurovascular appositions in the rat dentate fascia. Neurobiol. Aging 11:371–380; 1990.
29. Zee, C. E. E. M., van der; Schuurman, T.; Gerritsen-Van der Hoop, R.; Traber, J.; Gispen, W. H. Beneficial effect of nimodipine on peripheral nerve function in aged rats. Neurobiol. Aging 11:451–456; 1990.