IJC
International Journal of Cancer

TRIM28 haploinsufficiency predisposes to Wilms tumor

Illja J. Diets[1,2†], Juliane Hoyer[3†], Arif B. Ekici[3], Bernt Popp[3], Nicoline Hoogerbrugge[1,2], Simon V. van Reijmersdal[1,4], Rajith Bhaskaran[4], Michel Hadjihannas[3], Georgia Vasileiou[3], Christian T. Thiel[3], Didem Seven[3,5], Steffen Uebe[3], Denisa Ilencikova[6], Esmé Waanders[4], Annelies M.C. Mavinkurve-Groothuis[4], Nel Roeleveld[7,8], Ronald R. de Krijger[4,9], Jenny Wegert[10], Norbert Graf[11], Christian Vokuhl[12], Abbas Agaimy[13], Manfred Gessler[10], André Reis[3], Roland P. Kuiper[4], Marjolijn C.J. Jongmans[1,2,4,14†] and Markus Metzler[15†]

[1]Department of Human Genetics, Radboud university medical center, Nijmegen, The Netherlands
[2]Radboud Institute for Molecular Life Sciences, Nijmegen, The Netherlands
[3]Friedrich-Alexander-Universität Erlangen-Nürnberg (FAU), Institute of Human Genetics, Erlangen, Germany
[4]Princess Máxima Center for Pediatric Oncology, Utrecht, The Netherlands
[5]Department of Medical Biology, Cerrahpasa Medical Faculty, Istanbul University, Istanbul, Turkey
[6]Department of Pediatrics, Children's University Hospital, Comenius University, Bratislava, Slovakia
[7]Department for Health Evidence, Radboud Institute for Health Sciences, Radboud university medical center, Nijmegen, The Netherlands
[8]Department of Pediatrics, Radboudumc Amalia's Children's Hospital, Nijmegen, The Netherlands
[9]Department of Pathology, University Medical Center Utrecht, Utrecht, The Netherlands
[10]Theodor-Boveri-Institute/Biocenter, Developmental Biochemistry, and Comprehensive Cancer Center Mainfranken, University of Würzburg, Würzburg, Germany
[11]Department of Pediatric Hematology and Oncology, Saarland University, Medical Center Homburg/Saar, Homburg, Germany
[12]Kiel Pediatric Tumor Registry, Section of Pediatric Pathology, Department of Pathology, Christian Albrechts University, Kiel, Germany
[13]Institute of Pathology, University Hospital Erlangen, Friedrich-Alexander University Erlangen-Nuremberg, Erlangen, Germany
[14]Department of Genetics, University Medical Center Utrecht, Utrecht, The Netherlands
[15]Department of Pediatrics and Adolescent Medicine, Friedrich-Alexander-Universität Erlangen-Nürnberg (FAU), Erlangen, Germany

Two percent of patients with Wilms tumors have a positive family history. In many of these cases the genetic cause remains unresolved. By applying germline exome sequencing in two families with two affected individuals with Wilms tumors, we identified truncating mutations in *TRIM28*. Subsequent mutational screening of germline and tumor DNA of 269 children affected by Wilms tumor was performed, and revealed seven additional individuals with germline truncating mutations, and one individual with a somatic truncating mutation in *TRIM28*. *TRIM28* encodes a complex scaffold protein involved in many different processes, including gene silencing, DNA repair and maintenance of genomic integrity. Expression studies on mRNA and protein level showed reduction of TRIM28, confirming a loss-of-function effect of the mutations identified. The tumors showed an epithelial-type histology that stained negative for TRIM28 by immunohistochemistry. The tumors were bilateral in six patients, and 10/11 tumors are accompanied by perilobar nephrogenic rests. Exome sequencing on eight tumor DNA samples from six individuals showed loss-of-heterozygosity (LOH) of the *TRIM28*-locus by mitotic recombination in seven tumors, suggesting that *TRIM28* functions as a tumor suppressor gene in Wilms tumor development. Additionally, the tumors showed very few mutations in known Wilms tumor driver genes, suggesting that loss of *TRIM28* is the main driver of tumorigenesis. In conclusion, we identified heterozygous germline truncating mutations in *TRIM28* in 11 children with mainly epithelial-type Wilms tumors, which become homozygous in tumor tissue. These data establish *TRIM28* as a novel Wilms tumor predisposition gene, acting as a tumor suppressor gene by LOH.

Key words: Wilms tumor, haploinsufficiency, TRIM28, genetic predisposition
Additional Supporting Information may be found in the online version of this article.
[†]I.J.D., J.H., M.C.J.J. and M.M. contributed equally to this work
Grant sponsor: Dutch Cancer Society; **Grant number:** KUN2012-5366; **Grant sponsor:** The KiKa Foundation (project 127)
DOI: 10.1002/ijc.32167
History: Received 8 Oct 2018; Accepted 15 Jan 2019; Online 29 Jan 2019
Correspondence to: Markus Metzler, Department of Pediatrics and Adolescent Medicine, Friedrich-Alexander-Universität Erlangen-Nürnberg (FAU), Erlangen, Germany, E-mail: markus.metzler@uk-erlangen.de

What's new?

About 2% of Wilms tumors run in families, and some of the mutations remain unknown. These authors identified a new Wilms tumor mutation, a truncation on the *TRIM28* gene. They started by performing exome sequencing on tumors in pairs of affected children from 2 families. In these 4 patients, they found mutations in *TRIM28*, which encodes a scaffold protein involved in DNA repair and genome stability. They then screened a cohort of 269 cases and found 8 more patients bearing *TRIM28* loss-of-function mutations. The gene appears to function as a tumor suppressor with loss of heterozygosity in the tumor cells.

Introduction

Wilms tumors or nephroblastomas are the most common renal tumors in the pediatric population, affecting approximately 1 in 10,000 children. These tumors are typically diagnosed in young children at an average age between 3 and 4 years. Wilms tumors are considered embryonal tumors, as their development is tightly linked to the development of the kidney, and they can be associated with the presence of nephrogenic rests or nephroblastomatosis.[1,2]

The currently known repertoire of oncogenic Wilms tumor driver mutations includes *WT1, CTNNB1*, *AMER1*, *MYCN*, *SIX1/2* and several miRNA processing genes.[3–5] In addition, epigenetic alterations on chromosome 11p15.5 play an important role, mainly through IGF2 overexpression.

In about 10–15% of individuals with a Wilms tumor, a germline mutation or epigenetic alteration occurring during early embryogenesis underlies the pathogenesis of the tumor.[6,7]

These aberrations most commonly involve the *WT1* gene [MIM:194070],[8] and the 11p15.5 locus.[9] Less common causes include, but are not limited to Bloom syndrome (*BLM*; MIM: 210900),[10] Fanconi anemia based on bi-allelic *BRCA2* or *PALB2* mutations (MIM: 605724, 610832),[11,12] Perlman syndrome (*DIS3L2*; MIM:267000),[13] and Simpson-Golabi-Behmel syndrome (*GPC3*; MIM: 312870).[14] In addition, novel Wilms tumor predisposition genes such as *REST* and *CTR9* have been identified by exome sequencing in individuals without additional recognizable features.[15,16]

Although most Wilms tumor diagnoses occur in sporadic patients, about 2% of cases have one or more relatives affected by Wilms tumor.[17] A proportion of these familial cases can be ascribed to the aforementioned syndromes and genes. Furthermore, two familial Wilms tumor loci have been identified by genome-wide linkage analysis, FWT1 on chromosome 17q12-q21[18] and FWT2 on chromosome 19q13.4.[19] Nevertheless, the underlying genetic cause of some familial cases remains unexplained, indicating the existence of other Wilms tumor predisposition genes.

Here, we report the identification of germline truncating mutations in *TRIM28* in two families affected by Wilms tumors by exome sequencing. A subsequent cohort screening of 269 individuals with Wilms tumors revealed seven additional cases with germline mutations in *TRIM28*. The tumors show a characteristic epithelial-predominant histology, are frequently bilateral and are accompanied by nephrogenic rests.

Methods

Inclusion of index families

Affected individuals 1 and 2 from FAM#1 were included and described before in a childhood cancer predisposition study (case #22),[20] whereas the affected individuals 3 and 4 from FAM#2 were counseled in a diagnostic setting. Written informed consent was obtained from all participants or their legal guardians. For FAM#1, whole exome target enrichment (SureSelect Human All Exon v4 technology; Agilent Technologies, Santa Clara, CA) and sequencing (Illumina HiSeq platform, BGI, Copenhagen, Denmark) of peripheral blood samples was performed as described previously.[21] For FAM#2, exome sequencing was performed on an Illumina HiSeq 2,500 system (Illumina, Inc., San Diego, CA), after enrichment with SureSelect Target Enrichment v6 technology (Agilent Technologies, Santa Clara, CA). Alignment, variant calling and annotation was performed as described previously.[22] Exome sequencing data analysis focused on shared variants between the siblings from each family separately (details in Supporting Information methods).

Screening of Wilms tumor validation cohorts

Patients and samples. Targeted *TRIM28* sequencing was performed in two validation cohorts (Table 1). The first cohort consisted of 84 unrelated patients affected by Wilms tumors. Lymphocyte-derived germline DNA was obtained from AGORA (Aetiologic research into Genetic and Occupational/environmental Risk factors for Anomalies in children), a large ongoing data- and biobank coordinated by the Radboud university medical center including children with childhood cancer or congenital malformations.[23] The data collection protocol and this study were approved by the Regional Committee on Research involving Human Subjects Arnhem-Nijmegen (No. 2012–271).

For the second cohort, tissue samples were obtained from the German SIOP93-01/GPOH and SIOP2001/GPOH pediatric kidney tumor studies. All subjects (or their parents) provided written consent for tumor banking and future research use according to national regulations including ethical approval (Ethikkommission der Ärztekammer des Saarlandes, Germany, No. 23.4.93/Ls and 136/01). This cohort was enriched for bilateral cases and consisted of 193 tumor samples from 185 individuals. From the cases that had bilateral tumors (N = 47), DNA samples from both tumors were

Table 1. Composition of validation cohorts

Validation cohort	Source of DNA	Method of analysis	Total number of cases analyzed	Number of bilateral tumors	Number of tumors with epithelial histology
Cohort 1	Lymphocyte-derived germline DNA	Molecular Inversion Probe sequencing	84	6 (7.1%)	10 (11.9%)
Cohort 2	Tumor DNA	Amplicon sequencing	185	47 (25.4%)	18 (9.7%)
Total	-	-	269	53 (19.7%)	28 (10.4%)

analyzed in eight cases. In total, we analyzed 269 cases, of whom 53 (20%) had bilateral tumors, and 28 (10%) had epithelial histology (Table 1).

Targeted sequencing of TRIM28. For mutational screening of the validation cohorts, we used two different methods. The first cohort was screened using Molecular Inversion Probe (MIP) technology as described previously (Supporting Information Tables S1-S3).[24,25] For mutational screening of the second cohort, an Illumina TruSeq Custom Amplicon design for low DNA input was used. Both designs covered all 17 coding exons and intron-exons boundaries (±20 bp) of *TRIM28* (NM_005762.2). Details on both designs and sequencing can be found in Supporting Information methods. The identified potentially pathogenic variants were validated by Sanger sequencing in germline samples.

Exome sequencing on tumor material of individuals with germline *TRIM28* mutations

Exome sequencing was performed on genomic DNA isolated from eight Wilms tumor samples from individuals 1–4 (one tumor), 7 and 8 (both tumors). Peripheral blood (individuals 1–4) or normal kidney samples (individuals 7 and 8) were included to facilitate the identification of somatic variants. Genomic DNA was extracted from fresh frozen tissue (individuals 3, 7 and 8) and Formalin-Fixed Paraffin-Embedded (FFPE) tumor sample (individuals 1, 2 and 4) respectively. For individuals 1 and 2 (FAM#1), the SureSelext XT HS Target Enrichment System was used (Agilent Technologies, Santa Clara, CA) and libraries were sequenced on a NextSeq 2x150 bp mid output run (Utrecht Sequencing Facility). Enrichment and library preparation for exome sequencing on individuals 3, 4, 7 and 8 was performed using the SureSelect Human All Exon V6 kit (Agilent Technologies, Santa Clara, CA), and sequencing was carried out with 125 bp paired-end reads on an Illumina Hiseq 2,500 system (Illumina, Inc., San Diego, CA). Concurrent somatic variant calling using freebayes v1.1.0[26] was performed as described previously on the final 8 tumor and 6 germline BAM files from the affected individuals, and 40 in-house control samples.[27] Details on variant calling are available in Supporting Information methods.

Copy number variation (CNV) calling from exome data was performed using CNVkit version 0.9.4a0, with standard parameters against the 40 controls. In addition, allele specific copy number analysis was performed from the exome sequencing data using the FACETS algorithm.[28] Briefly, FACETS simultaneously segments total and allele specific DNA copy number from the coverage and genotypes of preselected single nucleotide polymorphisms (SNPs). In this study, SNPs with population allele frequency (AF) of >20% were selected from the Genome Aggregation Database (gnomAD). Allele specific segmentation is based on the log odds ratio of allele fractions at SNPs identified as heterozygous in the normal sample, which are used for B-allele frequency (BAF) plotting.

RNA isolation and RT-PCR analysis of *TRIM28* variants

Total RNA from individuals 3 and 4 (FAM#2), as well as from their unaffected mother was extracted from blood lymphocytes with the PAXgene Blood System (Becton Dickinson, Franklin Lakes, NJ). Tumor RNA and RNA from healthy kidney tissue from individuals 7 and 8 was extracted from fresh-frozen 5 μm sections with the AllPrep DNA/RNA mini Kit (Qiagen). The Superscript II Reverse Transcriptase Kit (Invitrogen, Carlsbad, CA) was used to produce cDNA, according to the manufacturer's instructions.

Western blotting and immunohistochemistry

Western blotting was performed as previously reported.[29] Rabbit polyclonal antibodies against human TRIM28 (Anti-KAP1 antibody, ab10484) were purchased from Abcam (Cambridge, UK). Validity of this antibody was demonstrated by Western blotting, using siRNA-mediated knockdown in human embryonic kidney cells (Supporting Information Fig. S1). Western blots were visualized on a Chemidoc MP Imaging system from Bio-Rad (Hercules, CA). For quantification of Western blots the open source Image Lab package was used as recommended.

TRIM28 immunostaining was manually performed on 2-μm thick sections prepared from FFPE tumor blocks at a 1:5,000 dilution, according to the manufacturer's instructions (Supporting Information methods). For assessment of the staining results, only the nuclear staining was considered specific. As a control, the presence of a homogeneous strong nuclear staining of stromal fibroblasts, inflammatory cells, vascular endothelial cells or normal epithelial cells in the background was a prerequisite for assessable staining in the tumor.

Results

Clinical reports of two index families

The first family consisted of two sisters who both developed Wilms tumors.[20] One girl (individual 1) was diagnosed with

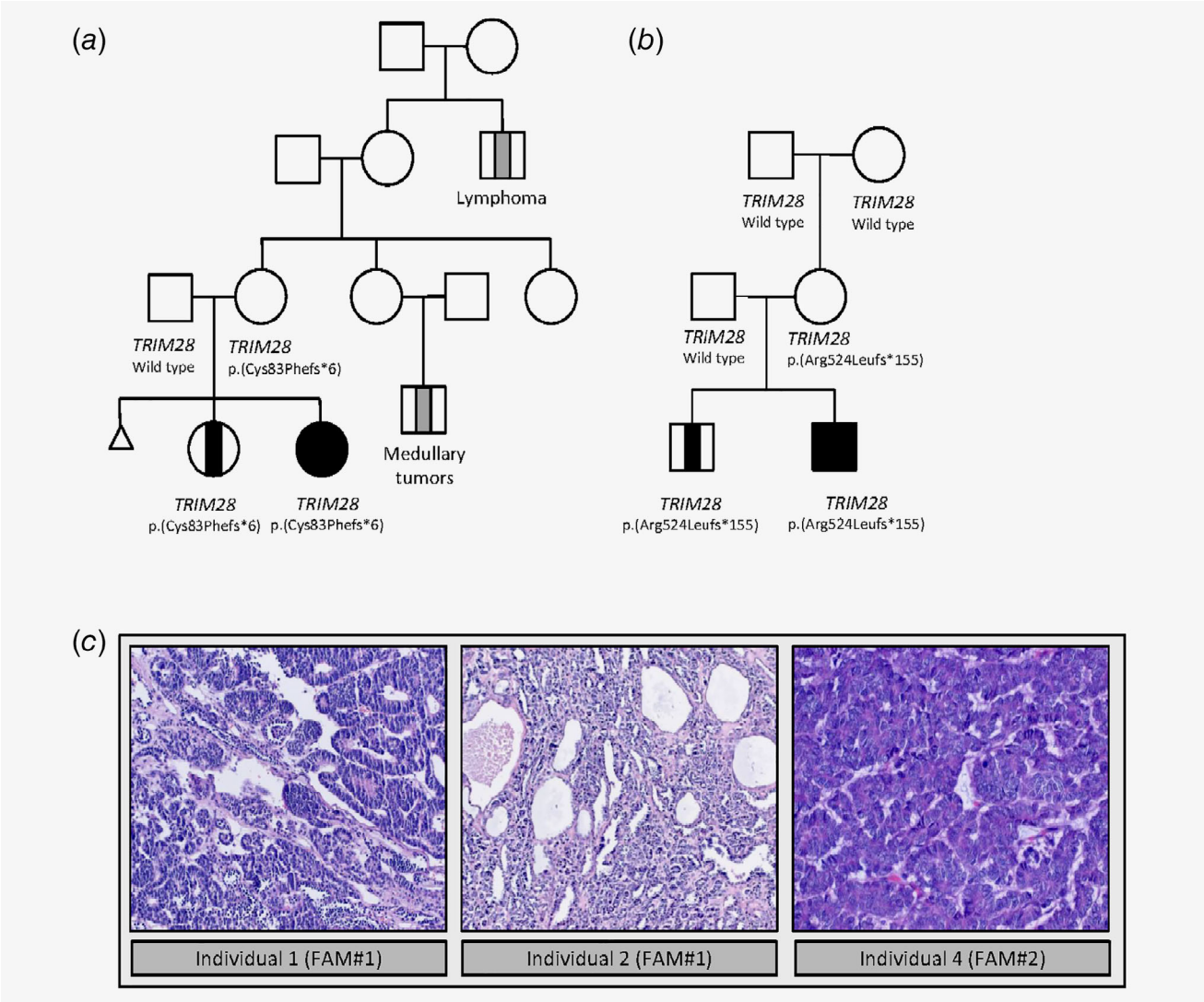

Figure 1. Family trees and clinical features of index families with *TRIM28* mutations. Symbol definitions: Black squares and circles: males and females affected by bilateral Wilms tumors; squares and circles with black bar: males and females affected by unilateral Wilms tumors; squares with gray bar: males affected by other tumors than Wilms tumor; triangle: miscarriage. (*a*) Family tree of FAM#1, consisting of two sisters affected by Wilms tumors, in whom a p.(Cys83Phefs*6) variant was detected. (*b*) Family tree of FAM#2, consisting of two brothers affected by Wilms tumors. Sanger sequencing showed that the p.(Arg524Leufs*155) mutation in *TRIM28* is maternally inherited, and that the maternal grandparents do not carry the mutation (ie the mutation is *de novo* in the mother). (*c*) Hematoxylin–eosin staining of the Wilms tumors of individuals 1, 2 and 4, showing a predominantly epithelial histology.

bilateral tumors at the age of 1.5 years and her sister (individual 2) had a unilateral tumor when she was 6 months old (Fig. 1*a* and Table 2). Individual 2 presented with additional congenital anomalies, including esophageal atresia with tracheo-esophageal fistula (Vogt classification Type 3B), coarctation of the aorta with a hypoplastic aortic arch, ventricular septal defect, patent ductus arteriosus and open foramen ovale, all of which were surgically corrected. After *WT1* sequencing revealed no mutation, exome sequencing on peripheral blood from both girls was performed. Data analysis focused on shared variants between the siblings and revealed a heterozygous c.246_247del variant in the *TRIM28* gene, predicted to cause a frameshift and premature stop codon after 6 amino acids p.(Cys83Phefs*6) (NM_005762.2). No other variants of interest were identified.[20]

In the second family (FAM#2), two brothers were diagnosed with unilateral and bilateral Wilms tumor (FAM#2: individual 3 and 4, Fig. 1*b*, Supporting Information Fig. S2 and Table 2), with presence of perilobar nephrogenic rests (PLNR) and nephroblastomatosis. No congenital anomalies were diagnosed in these siblings. After exclusion of germline mutations in *WT1,* exome sequencing on lymphocyte-derived DNA from both boys was performed. We identified a shared heterozygous frameshift aberration c.1562_1569dup in *TRIM28,* which was predicted to result in a premature termination codon after

Table 2. Clinical features of patients with germline and somatic mutations in *TRIM28*

	FAM#1		FAM#2									
	Individual 1	Individual 2	Individual 3	Individual 4	Individual 5	Individual 6	Individual 7	Individual 8	Individual 9	Individual 10	Individual 11	Individual 12
Germline mutation (NM_005762.2)												
Nucleotide change	c.246_247del		c.1562_1569dup		c.847C>T		c.1015C>T	c.586+2T>C	c.175del	c.1629del	c.520_523 del	c.1162_1162insGA
Protein effect	p.(Cys83Phefs*6)		p.(Arg524Leufs*155)		p.(Gln283*)		p.(Gln339*)	p.(Cys152Glyfs*50)	p.(Leu59Trpfs*34)	p.(Ala544Profs*132)	p.(Cys174Argfs*4)	p.(Met389Argfs*2)
Exon	1		12		6		7	Intron 3	1	12	3	
Inheritance	Maternal		Maternal		NT		NT	NT	NT	NT/*de novo*[1]	NT	NT
LOH in tumor	Yes	Yes	Unclear	Yes	Yes	Yes	Yes	Yes	Yes	Yes	Yes	NT
Origin	Germline		Germline		Germline		Germline	Germline	Germline	Germline	Germline	Somatic
Detection method	Exome sequencing		Exome sequencing		TS		TS	TS	TS	TS	TS	TS
Clinical- and tumor information												
Age at diagnosis	5 months	18 months	5 years, 9 months	7 months	6 months	7 months	6 months	1 year, 5 months	7 months	3 years, 4 months	6 years, 3 months	8 months
Gender	F	F	M	M	F	F	M	M	F	F	F	F
Localization	Bilateral	Left kidney	Left kidney	Bilateral	Left kidney	Bilateral	Bilateral	Bilateral	Right kidney	Left kidney	Bilateral	Left kidney
Pathology	*Both sides:* Epithelial-type WT	Epithelial-type WT	Mixed-type WT	*Left:* Epithelial-type WT *Right:* Blastemal-type WT	Epithelial-type WT	*Left:* Epithelial-type WT *Right:* NB	*Both sides:* Epithelial type WT	*Left:* Perilobar NB *Right:* Epithelial-type WT	Epithelial-type WT	Epithelial-type WT with diffuse anaplasia	*Left:* Perilobar NB *Right:* Epithelial-type WT	Epithelial-type WT
Nephrogenic rests	Yes, PLNR	Yes, perilobar NB	Yes, PLNR	Yes, bilateral perilobar NB	Yes, PLNR	Yes, perilobar NB	Yes, PLNR	Yes, NB	Yes, PLNR	No	Yes, PLNR	Unknown
Family	Siblings		Siblings		Identical twins		Mother bilateral WT 8mo. (NT)	Sporadic	Sporadic	Sporadic	Sporadic	Sporadic
Co-morbidities	Foramen ovale apertum	Esophageal atresia, complex CHD, retinopathy	No	No	No	No	No	No	No	No	No	No

Abbreviations: TS, Targeted Sequencing; F, female; M, male; LOH, loss of heterozygosity; WT, Wilms Tumor; NB, nephroblastomatosis; PLNR, perilobar nephrogenic rests; NT, not tested; CHD, congenital heart defect.
[1]Although the parents were not tested we can conclude based on the mosaic state of the mutation in the child, that this variant was not inherited from the parents.

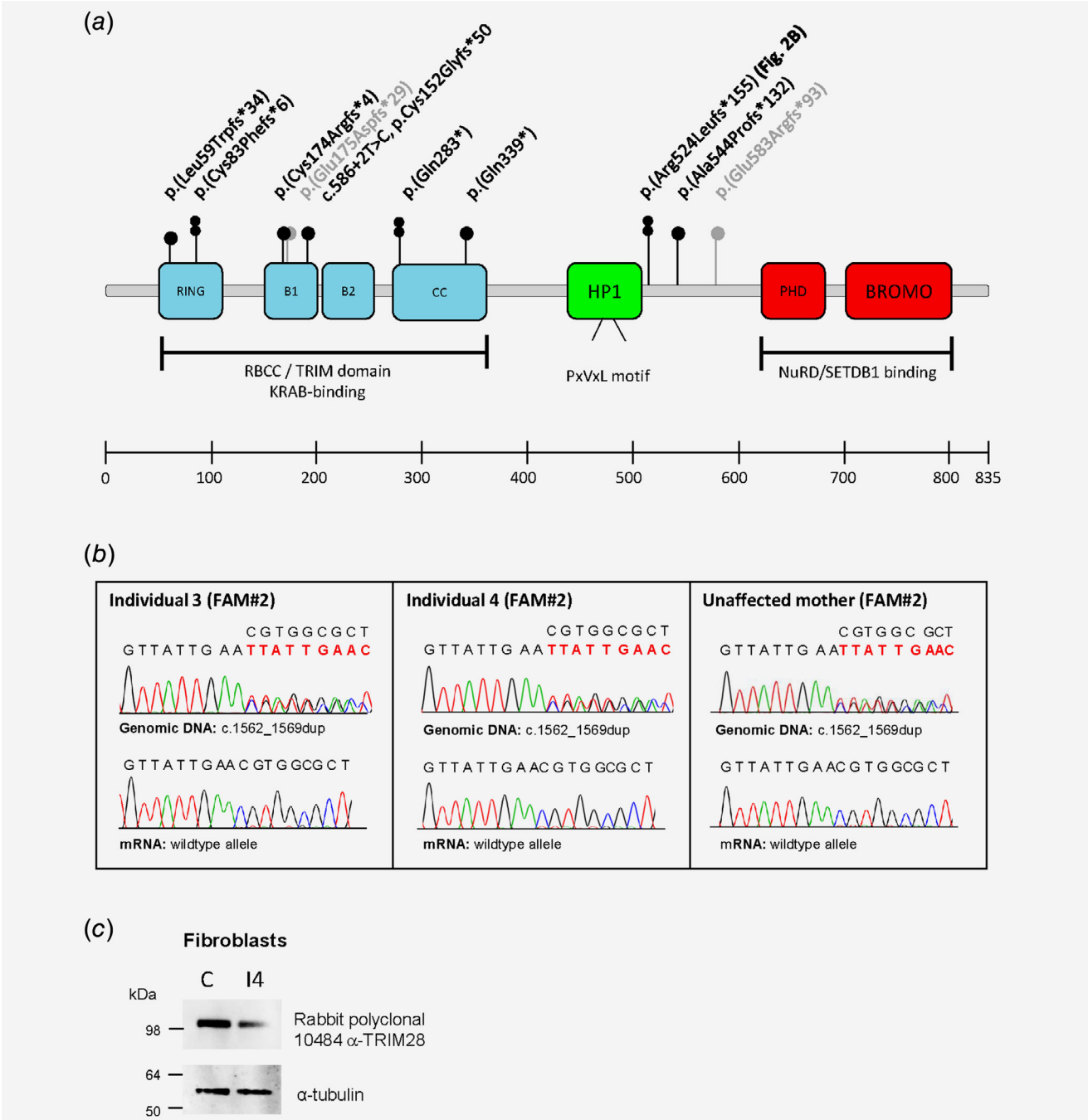

Figure 2. Distribution and translational impact of TRIM28 mutations. (*a*) Schematic representation of the TRIM28 protein and the localization of all identified germline *TRIM28* mutations. In black, variants found in this study, and in gray, variants identified by Halliday *et al.*[35] The TRIM28 protein consists of a RBCC domain (amino acids 65–376), consisting of a RING-type zinc finger (amino acids 65–121), two B-boxes (amino acids 148–195, 204–245) and a CC-domain amino acids (246–376), which is involved in the interaction with the KRAB domain of KRAB zinc finger proteins. The HP1 box (amino acids 476–513) with PxVxL motif (amino acids 481–494) is responsible for the binding to HP1. Last, the protein contains a BROMO domain (697–801) which, together with the PHD domain (amino acids 625–672) is responsible for NuRD/SETDB1 recruitment and binding (domains based on Uniprot Q13263). (*b*) Sanger sequencing validation of the c.1562_1569dup variant on peripheral blood-derived genomic DNA and cDNA of two affected siblings of FAM#2 and their unaffected carrier mother, showing nonsense mediated mRNA decay of the mutant allele. (*c*) Western blot analysis of human skin fibroblast lysates from a healthy control (c) and Individual 4 (I4) shows reduced expression of the TRIM28 protein. An antibody against α-tubulin was used as loading control.

155 amino acids p.(Arg524Leufs*155). The researchers involved in these two families came in contact by employing the web-based matching platform GeneMatcher.[30]

In both families, the *TRIM28* variants were maternally inherited (Figs. 1*a* and 1*b*). Both mothers were unaffected, indicating incomplete penetrance of germline *TRIM28* mutations for the development of Wilms tumor. No renal imaging was performed in these unaffected mothers. In FAM#2, the mutation was confirmed to be *de novo* in the mother. Both mutations were not present in the ExAC and gnomAD databases,[31] and loss-of-function

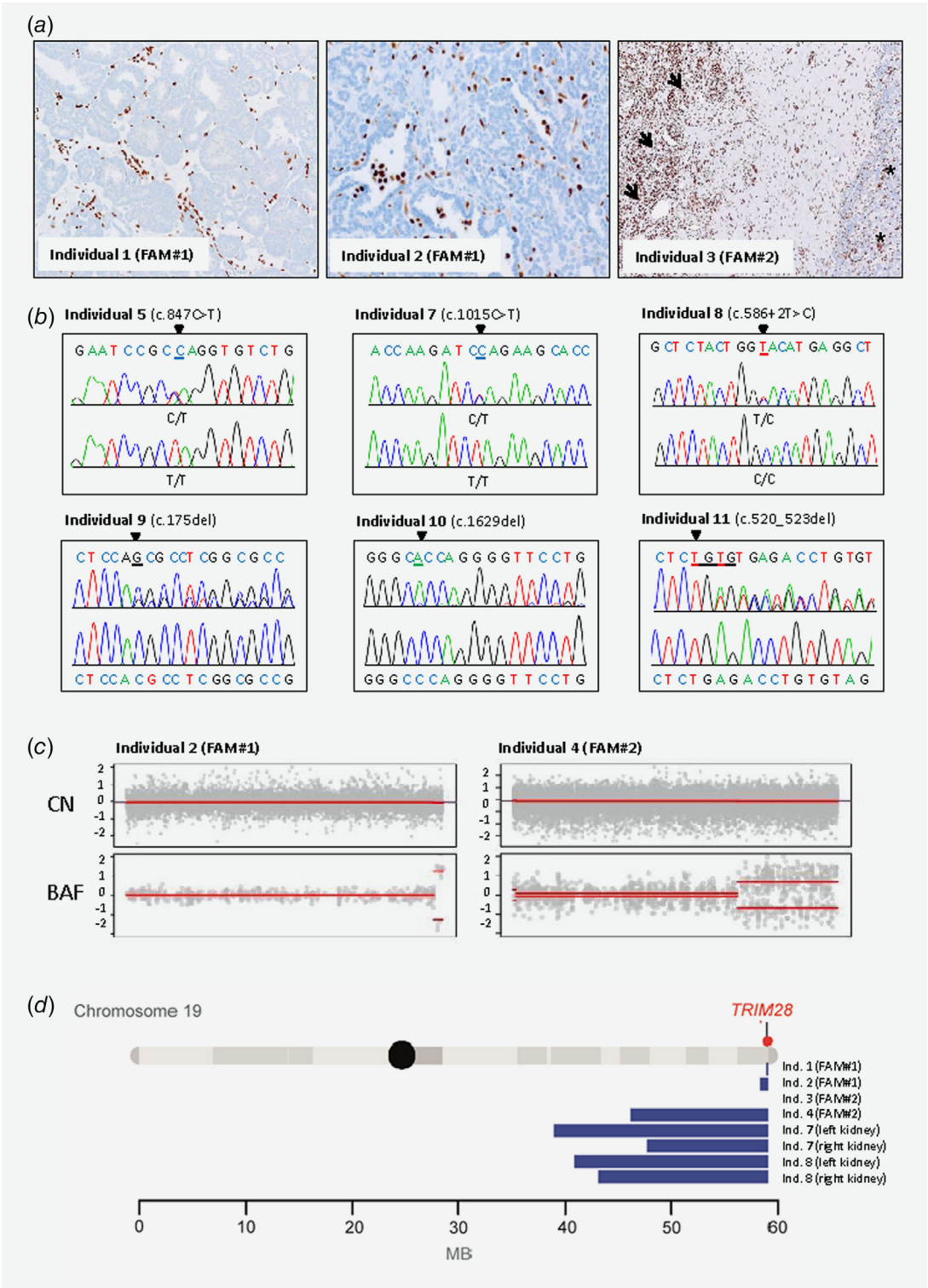

Figure 3. Legend on next page.

(LoF) variants in *TRIM28* are extremely rare. In fact, the high probability of LoF intolerance score (pLI of 1.00)[31] and high Z-score[32] of 3.16 in ExAC indicate that *TRIM28* is a gene that is very intolerant for normal variation.

Histological examination of the tumors (N = 6, including the two bilateral tumors) in individuals with germline *TRIM28* mutations showed a predominantly epithelial histology in four out of six tumors (Fig. 1*d*), and presence of nephroblastomatosis in all cases. In individual 4 with bilateral Wilms tumors, one tumor showed a predominantly blastemal histology, whereas the other tumor also had a predominantly epithelial histology, and in individual 3, the tumor had a mixed histology.

Identification of *TRIM28* variants in Wilms tumor validation cohorts

To establish the prevalence of germline *TRIM28* mutations in individuals with Wilms tumors, we performed targeted sequencing of 269 cases (Table 1). In total, we identified mutations in *TRIM28* in eight additional individuals, including three nonsense, one splice site and four frameshift mutations. As these mutations were identified in tumor DNA samples, validation on DNA derived from normal kidney tissue was performed, showing that seven out of eight mutations were present in a heterozygous state in the germline (individuals 5–11 in Table 2 and Fig. 2*a*). In individual 10, Sanger sequencing traces indicated that the variant was not present in a full heterozygous state in the germline sample, suggesting mosaicism in this patient. In one individual the mutation could not be detected in DNA derived from normal kidney tissue, indicating the somatic nature of this mutation (individual 12, c.1162_1162insGA, p.(Met389Argfs*2)).

Individuals 5 and 6 were twin sisters, both affected by Wilms tumor. DNA-based fingerprinting revealed monozygotic twinship. Additionally, the mother of individual 7 was diagnosed with a bilateral Wilms tumor at the age of eight months. Her germline DNA was not available for segregation analysis. Pathological examination of the tumors of individuals 5–12 (including the individual with a somatic *TRIM28* mutation) showed diffuse anaplasia in one case (individual 10) and a predominantly epithelial histology in all remaining cases. Four out of eight individuals had bilateral Wilms tumors, and all patients but one exhibited either PLNR, or nephroblastomatosis (Table 2). In these eight additional individuals, no congenital heart disease or other congenital anomalies were reported.

TRIM28 expression in normal tissue and tumor tissue

In total, we identified eight different heterozygous germline *TRIM28* mutations in eleven patients, all potentially leading to gene truncation (Fig. 2*a*). In individuals 3 and 4 (FAM#2), as well as their unaffected carrier mother, mRNA sequencing analysis from blood lymphocytes demonstrated a predominant expression of the wild type allele, indicating nonsense-mediated decay of mRNA containing the mutant allele (Fig. 2*b*). Western blotting analysis of cultured human skin fibroblasts of individual 4 (FAM#2), showed a decreased TRIM28 protein level compared to a control subject (Fig. 2*c*). Furthermore, mRNA analysis of individual 8 harboring the splice-donor variant c.586+2T>C, showed an aberrant transcript with skipping of exon 3 (r.454_586del), resulting in a frameshift and premature stop codon after 50 amino acids (p.Cys152Glyfs*50; Supporting Information Fig. S3).

Next, we investigated the expression of TRIM28 in the tumors. First, we performed immunohistochemical staining of the TRIM28 protein in tumors of six individuals (individuals 1–4, 7 and 8), to assess a loss of protein expression. All samples tested exhibit loss of TRIM28 expression (Fig. 3*a*), compared to retained TRIM28 expression in normal kidney tissue, strongly suggesting the presence of a somatic second hit mutation in *TRIM28*. This loss was complete for all samples, except in individual 4 where regions with retained TRIM28 expression were seen. Interestingly, Sanger sequencing of the mutation in the Wilms tumors of individuals 5–11 revealed loss of the wild-type allele and increased intensity of the mutant allele, which is indicative of acquired homozygosity (Fig. 3*b*).

To investigate this further, we performed exome sequencing of eight Wilms tumor samples from six individuals (individuals 1–4, 7 and 8). In none of these tumors, a second somatic mutation in *TRIM28* could be identified, nor did we observe deletion of the 19q telomeric region where the *TRIM28* locus is located (Fig. 3*c* and Supporting Information Fig. S4). However, B-allele frequency plots of chromosome 19 revealed that in seven out of eight tumors, variable regions of allelic imbalance or homozygosity of 19qter could be identified, in some cases involving only the tip of chromosome 19 (Fig. 3*d*). This is suggestive of copy-number neutral LOH, in which the wild type allele is replaced by the mutant allele by a mitotic recombination event (Fig. 3*c* and Supporting Information Fig. S4). No copy-number neutral LOH could be identified in the tumor of individual three, even though TRIM28 immunohistochemistry did show

Figure 3. Germline *TRIM28* mutations become homozygous in all tested tumors. (*a*) TRIM28 immunohistochemical staining of the tumors of individuals 1–3 shows complete loss of TRIM28 expression in the neoplastic cells. In the right panel, asterisks mark the locations with loss of TRIM28 expression in the tumor, as compared to normal tissue with retained TRIM28 expression (arrows). In the left and middle panel, the presence of normal cells between tumor cells serve as a internal positive control. The images are representative for all patients tested. (*b*) Sanger sequencing of the *TRIM28* mutation in six individuals showing homozygosity of the mutation in all tumors (bottom chromatograms), compared to normal tissue (top chromatograms). Mutated nucleotides are underlined in the reference sequence. (*c*) Copy number (CN) and B-allele frequency (BAF) plots of chromosome 19 (X-axis) from two tumors from individuals 2 (FAM#1) and 4 (FAM#2), showing normal copy number status (top plots), but variable copy-number neutral LOH of the 19qter region (bottom plot). (*d*) Schematic representation of the regions of LOH in all eight whole exome sequenced tumors from six individuals. The gene *TRIM28* is located at the end of the long arm of chromosome 19, ~200 kb from the telomere. B-allele frequency plots are provided in Supporting Information Figure S4.

Table 3. Overview of somatic mutations found by exome sequencing in 8 tumors

Tumor sample	# Somatic mutations	# Deleterious mutations	# Mutations in known driver genes[1]
WT individual 1	3	2	0
WT individual 2	6	2	0
WT individual 3	6	4	3 *DICER1* (NM_030621.4: c.5428G›C; p.(Asp1810His)) *DICER1* (NM_030621.4: c.1908-2A›G; splice) *AMER1* (NM_152424.3: c.1072C›T; p.(Arg358*))
WT individual 4	9	6	1 *NF1* (NM_001042492.2: c.2325+1G›A; splice)
WT individual 7, left kidney	1	0	0
WT individual 7, right kidney	2	1	0
WT individual 8, left kidney	0	0	0
WT individual 8, right kidney	1	0	0

[1]Driver genes in Wilms tumor are defined as the genes identified as recurrently mutated according to Refs. 6,35,47

loss of the protein in tumor tissue (Fig. 3*a*). Together, these findings indicate that in Wilms tumors from the individuals with germline *TRIM28* mutations, the wild type allele is lost by copy-number neutral LOH in the far majority of cases.

Somatic mutation profile of *TRIM28*-mutated tumors

Finally, we analyzed the spectrum of somatic mutations in the eight aforementioned tumors. Copy number analysis on the exome sequencing data revealed predominantly diploid genomes with no large segmental copy number aberrations. Analysis of the lists of high quality somatic variants in other genes besides *TRIM28* hardly revealed pathogenic mutations in the genes known to be mutated frequently in Wilms tumors (Table 3).[5,6] The only exceptions are the tumors of individuals 3 and 4. In individual 3 two somatic *DICER1* mutations (the splice site mutation c.1908-2A>G and the missense variant c.5428G>C, p.(Asp1810His) within the RNase III domain) and an *AMER1* nonsense variant (c.1072C>T, p.(Arg358*)) were found. Of note, the tumor of this individual showed a mixed histology, and we could not indicate LOH with certainty in this tumor. The tumor of individual 4 carried a heterozygous *NF1* splice site mutation (c.2325+1G>A). In the tumors of the other individuals, no high-quality somatic variants were found in known Wilms tumor genes.

Discussion

We have recently shown that clinical exome sequencing is an effective strategy for the diagnosis of known and novel genetic tumor predisposition syndromes.[20] Here, we report how application of exome sequencing in two centers independently resulted in the identification of pathogenic *TRIM28* frameshift mutations in two families with very similar clinical presentations of Wilms tumor. A subsequent screening of a validation cohort revealed seven additional individuals with germline mutations, and one individual with a somatic mutation in *TRIM28.* Two individuals with a germline mutations were monozygotic twins (individual 5 and 6). Tumors from 10 out of 11 individuals showed a predominantly epithelial histology, and six out of 11 individuals had bilateral Wilms tumors. Furthermore, 10 out of 11 patients had either PLNRs or nephroblastomatosis. The tumors showed loss of heterozygosity (LOH) of the *TRIM28* mutation, indicating that *TRIM28* is a classical tumor suppressor gene involved in Wilms tumor predisposition.

TRIM28, also known as KAP1 (Krüppel-Associated Box (KRAB)-Associated Protein 1) or TIF1-β (Transcriptional Intermediary Factor 1 β), is located on chromosome 19q13.43 and encodes a large multi-domain protein (Fig. 2*a*). At the N-terminus, TRIM28 contains four domains: a RING-finger, two B-boxes and a coiled-coil region. Together, these domains are responsible for interaction with the KRAB repression domain of many transcription factors. This highlights the function of TRIM28 as a significant transcriptional co-repressor.[33] TRIM28-associated transcription complexes have many different functions, including maintenance of genome stability, DNA repair and functions during early embryonic development.[34]

Recently, an association of germline and somatic mutations in *TRIM28* with Wilms tumor development was reported by Halliday and coworkers.[35] Their findings, namely a predominantly epithelial histology of the tumors, LOH of the *TRIM28* mutation in the tumor and a lack of somatic mutations in known Wilms tumor drivers in two tumors examined, are largely in agreement with ours. The predominant epithelial histology observed in the two studies appears to be an important hallmark with diagnostic potential. Therefore, *TRIM28*-associated Wilms tumor predisposition should be considered particularly when tumors fall into this category. We observed PLNRs or nephroblastomatosis in 10 out of 11 patients in our cohort, and 6 out of 11 individuals presented with bilateral Wilms tumors. This is higher compared to the Halliday study, in which no patients had nephrogenic rests and only 1 out of 5 tumors were bilateral. Nephrogenic rests are a result of maldevelopment of the embryonic kidney and are considered precursor lesions of Wilms tumors. It has been shown that *TRIM28* has an important role in the developing kidney, since silencing of *TRIM28* in cultured rat kidneys results in branching arrest.[36]

Immunohistochemistry showed loss of the TRIM28 protein in tumor material. The additional observation of *TRIM28* LOH in the tumors provides evidence that in Wilms tumor development, *TRIM28* functions as a classical tumor suppressor gene. Several cancer predisposing genes are known to interact with *TRIM28*, including *TP53*,[37–39] the recently identified Wilms tumor predisposition gene *REST*[40] and *AMER1,* a gene frequently mutated somatically in Wilms tumors.[41] In individual 3, a previously reported somatic nonsense mutation in *AMER1* was identified, in addition to two mutations in *DICER1*. The tumor of this patient is the only tumor with a mixed histology. Based on the exome data and immunohistochemical staining, we hypothesize that this tumor has different regions with different mutational profiles, i.e. *AMER1* and *DICER1* mutations in the part with retained TRIM28 expression, and LOH of TRIM28 in the other part. In other tumors that were examined (eight tumors from six individuals), no other somatic pathogenic variants in known Wilms tumor associated genes were identified. This suggests that in these tumors, *TRIM28* is the main and usually sufficient driver of tumorigenesis, but more samples need to be sequenced for further validation.

Interestingly, in all individuals and families with germline *TRIM28* mutations identified so far and in which testing of parental DNA was possible, the mutations are maternally inherited (N = 4).[35] It has been shown that loss of maternal *TRIM28* in mice leads to early lethality,[42] which is likely the result of misregulation of genomic imprinting. Thus, it might be that *TRIM28* mutations will only lead to tumor development if maternally inherited, perhaps due to a tissue-specific imprinting effect or *via* a haploinsufficient maternal allele during oogenesis and early zygotic cell divisions.

In individual 2 multiple congenital anomalies were observed, including esophageal atresia and a complex congenital heart defect. Although it is possible that this is attributable to other causes, we cannot exclude a possible effect of the *TRIM28* mutation. No other explanations were identified by exome sequencing. TRIM28 is ubiquitously expressed and shows high expression in oocytes and early embryos.[43,44] Knockout of *Trim28* in mice is embryonically lethal around implantation,[45] which shows the importance of the gene in early development. Thus, disruption of *TRIM28* might lead to congenital anomalies in humans as well. However, since only one individual was diagnosed with congenital anomalies, detailed clinical evaluation of additional individuals should elucidate this correlation.

The identification of germline *TRIM28* variants in individuals with Wilms tumors is of high clinical significance. Currently, germline genetic testing of individuals with Wilms tumors is performed mainly in individuals with high-risk histological subtypes, bilateral tumors, syndromic features, or a family history of cancer.[6,46] Our findings indicate that genetic screening should also be extended to individuals with tumors with epithelial predominant histology, since it is particularly this rare subgroup of patients representing 4.5% of the total group of patients with Wilms tumors, that appears to harbor germline *TRIM28* mutations. Another important finding is the loss of TRIM28 protein expression in tumor cells, which highlights the significance of the inclusion of TRIM28 immunohistochemical staining in the standard pathological analysis of Wilms tumors. If tumor epithelial cells lack staining, individuals should be referred for genetic testing. Taken together, we consider that immunohistochemistry in combination with histology analysis would strongly contribute to the recognition of most of these patients. In recent years, multiple novel Wilms tumor predisposition genes have been identified in nonsyndromic children and children with sporadic Wilms tumors,[15,16,35] including the gene identified in this study. Therefore, it could be beneficial to perform sequencing of a Wilms tumor predisposition gene panel including these genes on all children diagnosed with Wilms tumor, irrespective of their histological subtype or family history.

In conclusion, we identified truncating germline mutations in *TRIM28* in four children with Wilms tumor from two families and in seven out of 269 individuals. Additionally, one individual carried a somatic *TRIM28* mutation. Furthermore, analysis of tumor DNA showed loss of the TRIM28 wild-type allele, indicating that it functions as a classical tumor suppressor gene in Wilms tumor development. These results establish *TRIM28* as a novel Wilms tumor predisposition gene.

Acknowledgements

We thank the Genome Technology Center Nijmegen. We thank Sabrina Bausenwein, Heike Streitenberger and Barbara Ziegler for expert technical assistance in the Wilms tumor biobank, and Christa Winkelmann for support in preparation of IHC specimens. We thank Daniela Schweitzer and Olga Zwenger for their technical assistance.

Illja J. Diets is funded by The KiKa Foundation (project 127). Esmé Waanders was funded by the Dutch Cancer Society (KUN2012-5366). The funding agencies did not have influence on the generation and publication of the data.

Authors' contributions

Study design and conceptualization: I.D., J.H., N.H., R.K., M.J., M.M. Clinical analysis of patients: I.D., J.H., D.I., M.G., M.J., M.M. Composition of validation cohorts: A.M.C.M., N.R., M.G., A.E., J.W. Targeted sequencing design and interpretation of validation cohorts: I.D., Sv.R., A.E., S.U., R.K., D.S. Sanger validation of variants: A.E., G.V., D.S., E.W. Segregation analysis: B.P. Tumor exome sequencing: Sv.R., A.E., R.B., B.P., R.K. Establishment of antibodies: M.H. Pathological examination of tumors: R.R.dK, A.A., C.V. RT-PCR analysis: G.V. Western blot and siRNA experiments: M.H. Bio-informatic and technical assistance: R.B., C.T., E.W., S.U., B.P. Writing of the manuscript: I.D., J.H., R.B., B.P., R.K., M.J. and M.M. Critical review of the manuscript: All authors. Study supervision: A.R., R.K., M.J., M.M.

Data availability statement

The data that supports the findings of this study are available from the corresponding author upon reasonable request.

References

1. Hohenstein P, Pritchard-Jones K, Charlton J. The yin and yang of kidney development and Wilms' tumors. *Genes Dev* 2015;29:467–82.
2. Breslow N, Olshan A, Beckwith JB, et al. Epidemiology of Wilms tumor. *Med Pediatr Oncol* 1993; 21:172–81.
3. Gadd S, Huff V, Huang CC, et al. Clinically relevant subsets identified by gene expression patterns support a revised ontogenic model of Wilms tumor: a Children's Oncology Group Study. *Neoplasia (New York, NY)* 2012;14:742–56.
4. Walz AL, Ooms A, Gadd S, et al. Recurrent DGCR8, DROSHA, and SIX homeodomain mutations in favorable histology Wilms tumors. *Cancer Cell* 2015;27:286–97.
5. Wegert J, Ishaque N, Vardapour R, et al. Mutations in the SIX1/2 pathway and the DROSHA/-DGCR8 miRNA microprocessor complex underlie high-risk blastemal type Wilms tumors. *Cancer Cell* 2015;27:298–311.
6. Gadd S, Huff V, Walz AL, et al. A Children's oncology group and TARGET initiative exploring the genetic landscape of Wilms tumor. *Nat Genet* 2017;49:1487–94.
7. Dome JS, Huff V. *GeneReviews((R))*. In: Adam MP, Ardinger HH, Pagon RA, et al., eds *Wilms tumor predisposition*. Seattle (WA): University of Washington 2016.
8. Huff V, Miwa H, Haber DA, et al. Evidence for WT1 as a Wilms tumor (WT) gene: intragenic germinal deletion in bilateral WT. *Am J Hum Genet* 1991;48:997–1003.
9. Henry I, Bonaiti-Pellie C, Chehensse V, et al. Uniparental paternal disomy in a genetic cancer-predisposing syndrome. *Nature* 1991;351:665–7.
10. Ellis NA, Groden J, Ye TZ, et al. The Bloom's syndrome gene product is homologous to RecQ helicases. *Cell* 1995;83:655–66.
11. Reid S, Renwick A, Seal S, et al. Biallelic BRCA2 mutations are associated with multiple malignancies in childhood including familial Wilms tumour. *J Med Genet* 2005;42:147–51.
12. Reid S, Schindler D, Hanenberg H, et al. Biallelic mutations in PALB2 cause Fanconi anemia subtype FA-N and predispose to childhood cancer. *Nat Genet* 2007;39:162–4.
13. Astuti D, Morris MR, Cooper WN, et al. Germline mutations in DIS3L2 cause the Perlman syndrome of overgrowth and Wilms tumor susceptibility. *Nat Genet* 2012;44:277–84.
14. Pilia G, Hughes-Benzie RM, MacKenzie A, et al. Mutations in GPC3, a glypican gene, cause the Simpson-Golabi-Behmel overgrowth syndrome. *Nat Genet* 1996;12:241–7.
15. Hanks S, Perdeaux ER, Seal S, et al. Germline mutations in the PAF1 complex gene CTR9 predispose to Wilms tumour. *Nat Commun* 2014;5: 4398.
16. Mahamdallie SS, Hanks S, Karlin KL, et al. Mutations in the transcriptional repressor REST predispose to Wilms tumor. *Nat Genet* 2015;47:1471–4.
17. Breslow NE, Olson J, Moksness J, et al. Familial Wilms' tumor: a descriptive study. *Med Pediatr Oncol* 1996;27:398–403.
18. Rahman N, Arbour L, Tonin P, et al. Evidence for a familial Wilms' tumour gene (FWT1) on chromosome 17q12-q21. *Nat Genet* 1996;13: 461–3.
19. McDonald JM, Douglass EC, Fisher R, et al. Linkage of familial Wilms' tumor predisposition to chromosome 19 and a two-locus model for the etiology of familial tumors. *Cancer Res* 1998;58: 1387–90.
20. Diets IJ, Waanders E, Ligtenberg MJ, et al. High yield of pathogenic Germline mutations causative or likely causative of the cancer phenotype in selected children with cancer. *Clin Cancer Res* 2018;24:1594–603.
21. Vissers LE, de Ligt J, Gilissen C, et al. A de novo paradigm for mental retardation. *Nat Genet* 2010; 42:1109–12.
22. Hauer NN, Popp B, Schoeller E, et al. Clinical relevance of systematic phenotyping and exome sequencing in patients with short stature. *Genet Med* 2018;20:630–8.
23. van Rooij IA, van der Zanden LF, Bongers EM, et al. AGORA, a data- and biobank for birth defects and childhood cancer. *Birth Defects Res A Clin Mol Teratol* 2016;106:675–84.
24. Boyle EA, O'Roak BJ, Martin BK, et al. MIPgen: optimized modeling and design of molecular inversion probes for targeted resequencing. *Bioinformatics* 2014;30:2670–2.
25. Zhang J, Wang X, de Voer RM, et al. A molecular inversion probe-based next-generation sequencing panel to detect germline mutations in Chinese early-onset colorectal cancer patients. *Oncotarget* 2017;8:24533–47.
26. Garrison MG. Haplotype-based variant detection from short-read sequencing. *arXiv* 2012;1207: 3907.
27. Popp B, Krumbiegel M, Grosch J, et al. Need for high-resolution genetic analysis in iPSC: results and lessons from the ForIPS consortium. *bioRxiv* 2018;8:17201.
28. Shen R, Seshan VE. FACETS: allele-specific copy number and clonal heterogeneity analysis tool for high-throughput DNA sequencing. *Nucleic Acids Res* 2016;44:e131.
29. Hadjihannas MV, Bernkopf DB, Bruckner M, et al. Cell cycle control of Wnt/beta-catenin signalling by conductin/axin2 through CDC20. *EMBO Rep* 2012;13:347–54.
30. Sobreira N, Schiettecatte F, Valle D, et al. GeneMatcher: a matching tool for connecting investigators with an interest in the same gene. *Hum Mutat* 2015;36:928–30.
31. Lek M, Karczewski KJ, Minikel EV, et al. Analysis of protein-coding genetic variation in 60,706 humans. *Nature* 2016;536:285–91.
32. Samocha KE, Robinson EB, Sanders SJ, et al. A framework for the interpretation of de novo mutation in human disease. *Nat Genet* 2014;46: 944–50.
33. Friedman JR, Fredericks WJ, Jensen DE, et al. KAP-1, a novel corepressor for the highly conserved KRAB repression domain. *Genes Dev* 1996; 10:2067–78.
34. Iyengar S, Farnham PJ. KAP1 protein: an enigmatic master regulator of the genome. *J Biol Chem* 2011;286:26267–76.
35. Halliday BJ, Fukuzawa R, Markie DM, et al. Germline mutations and somatic inactivation of TRIM28 in Wilms tumour. *PLoS Genet* 2018;14: e1007399.
36. Dihazi GH, Jahn O, Tampe B, et al. Proteomic analysis of embryonic kidney development: heterochromatin proteins as epigenetic regulators of nephrogenesis. *Sci Rep* 2015;5:13951.
37. Okamoto K, Kitabayashi I, Taya Y. KAP1 dictates p53 response induced by chemotherapeutic agents via Mdm2 interaction. *Biochem Biophys Res Commun* 2006;351:216–22.
38. Tian C, Xing G, Xie P, et al. KRAB-type zinc-finger protein Apak specifically regulates p53-dependent apoptosis. *Nat Cell Biol* 2009;11: 580–91.
39. Wang C, Ivanov A, Chen L, et al. MDM2 interaction with nuclear corepressor KAP1 contributes to p53 inactivation. *EMBO J* 2005;24:3279–90.
40. Lee N, Park SJ, Haddad G, et al. Interactomic analysis of REST/NRSF and implications of its functional links with the transcription suppressor TRIM28 during neuronal differentiation. *Sci Rep* 2016;6:39049.
41. Kim WJ, Wittner BS, Amzallag A, et al. The WTX tumor suppressor interacts with the transcriptional Corepressor TRIM28. *J Biol Chem* 2015; 290:14381–90.
42. Messerschmidt DM, de Vries W, Ito M, et al. Trim28 is required for epigenetic stability during mouse oocyte to embryo transition. *Science (New York, NY)* 2012;335:1499–502.
43. Quenneville S, Turelli P, Bojkowska K, et al. The KRAB-ZFP/KAP1 system contributes to the early embryonic establishment of site-specific DNA methylation patterns maintained during development. *Cell Rep* 2012;2:766–73.
44. Quenneville S, Verde G, Corsinotti A, et al. In embryonic stem cells, ZFP57/KAP1 recognize a methylated hexanucleotide to affect chromatin and DNA methylation of imprinting control regions. *Mol Cell* 2011;44:361–72.
45. Cammas F, Mark M, Dolle P, et al. Mice lacking the transcriptional corepressor TIF1beta are defective in early postimplantation development. *Development (Cambridge, England)* 2000;127:2955–63.
46. Yost S, de Wolf B, Hanks S, et al. Biallelic TRIP13 mutations predispose to Wilms tumor and chromosome missegregation. *Nat Genet* 2017;49: 1148–51.
47. Huff V, Saunders GF. Wilms tumor genes. *Biochim Biophys Acta* 1993;1155:295–306.