The Bone Graft in the Alveolar Cleft

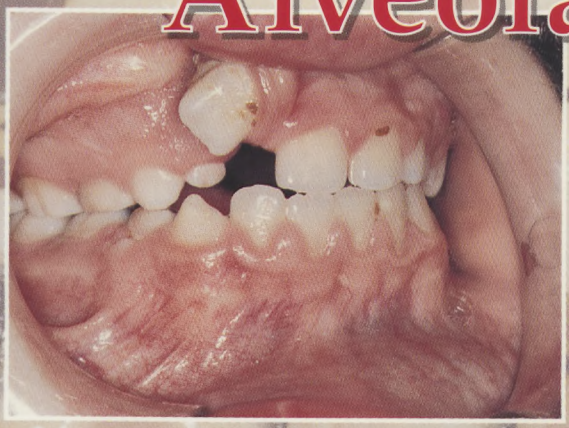

R. Koole

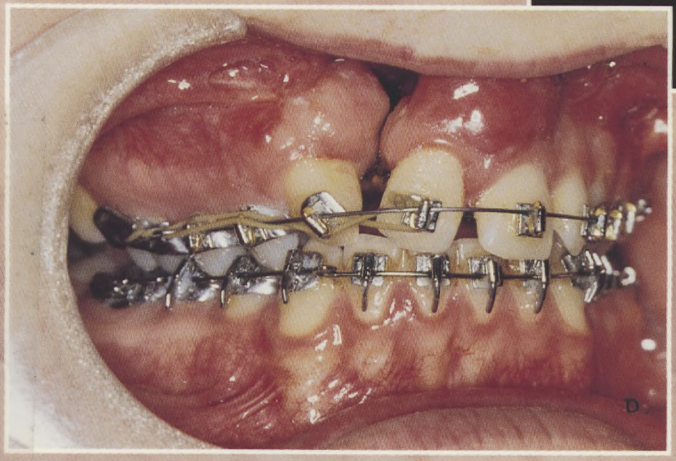

List of abbreviations used in the text

ABR	- alveolar bone resorption
mABR	- mean alveolar bone resorption
mABR-G	- mean alveolar bone resorption Groningen
mABR-U	- mean alveolar bone resorption Utrecht
ACR	- alveolar cleft repair
BCLP	- bilateral cleft lip and palate
BOP	- bleeding on probing
BRAR	- bone remodelling and alveolar repair
BV	- bone volume
CAC	- cleft associated canine
CACI	- cleft associated central incisor
CAI	- cleft associated incisor
CALI	- cleft associated lateral incisor
CAT	- cleft associated teeth
FFG	- finger flap group
FFG-U	- finger flap group Utrecht
MBB	- mandibular body bone
mPD	- mean probing depth
MPFG	- muco periosteal flap group
MPFG-G	- muco periosteal flap group Groningen
MPFG-U	- muco periosteal flap group Utrecht
OMF	- oro-maxillofacial
PD	- probing depth
PDL	- periodontal ligament
TACR	- tertiary alveolar cleft repair
TV	- total volume
UCLP	- unilateral cleft lip palate
X-OPT	- rontgen orthopantomogram

Stellingen

behorend bij het proefschrift

The Bone Graft in the Alveolar Cleft

R. Koole

Stellingen

1. Het bottransplantaat uit de mandibulaire symphysis is waardevol en betrouwbaar voor het herstel van de gnathoschisis. (dit proefschrift)

2. De primaire osteoplastiek voor herstel van de gnathoschisis leidt niet tot het beoogde resultaat.

3. De termen "primair" en "secundair" bij de osteoplastiek dienen te worden afgeschaft.

4. De term osteoplastiek met leeftijdsaanduiding voor de 1e bottransplantatie in de kaakspleet en de term osteocorrectie voor een daaropvolgende bottransplantatie(s) in de kaakspleet is te prefereren (Honigman en Prein).

5. De Le Fort I osteotomie zal bij een goede samenwerking tussen kaakchirurg en orthodontist én bij minder traumatiserende primaire ingrepen t.b.v. het palatum op de achtergrond raken.

6. Uitgebreide prothetische voorzieningen bij schisispatiënten zoals verricht vóór de 80-er jaren zullen niet meer noodzakelijk zijn, de tandheelkundige prothetische nazorg eenvoudiger geworden.

7. 3D-imaging van de gnathoschisis regio is een medisch technische verworvenheid die vooralsnog de resultaten van de bottransplantatie in de gnathoschisis niet fundamenteel zal wijzigen.

8. De epitheliale-ectomesenchymale interactie in het post-natale leven, verdient een nader uitvoerig onderzoek. (dit proefschrift)

9. Het ineenstorten van de neus van Michael Jackson is waarschijnlijk mede toe te schrijven aan het gebruik van een mesenchymaal bottransplantaat in een ectomesenchymale acceptorregio.

10. Het kaakchirurgische vakgebied breidt zich uit; in craniale richting van wortelvlies tot hersenvlies; de dubbele vooropleiding, arts en tandarts, ten behoeve van het specialisme Mondziekten en Kaakchirurgie is derhalve géén overdreven eis.

11. Het aanbieden van "gedifferentieerde" tandheelkundige professionele zorg is *min of meer* duidelijk voor de professie zelf, voor de patiënt is het *volstrekt* onduidelijk, voor de verzekeraar *niet goedkoper*.

12. Homeopathische (genees)middelen werken alleen bij gezonde mensen.

13. Dubbelzijdig fotocopiëren bespaart meer dan 50% papierverbruik.

14. Zeven wijzen kunnen meer vragen dan één dwaas kan beantwoorden.

R. Koole, september 1994

THE BONE GRAFT IN THE ALVEOLAR CLEFT

R. KOOLE

THE BONE GRAFT IN THE ALVEOLAR CLEFT

HET BOTTRANSPLANTAAT IN DE GNATHOSCHISIS

(with a summary in English)

PROEFSCHRIFT

ter verkrijging van de graad van doctor

aan de Universiteit Utrecht

op gezag van de Rector Magnificus,

Prof.dr. J.A. van Ginkel

ingevolge het besluit van het College van Decanen

in het openbaar te verdedigen op

dinsdag 13 september 1994

des namiddags te 12.45 uur

door

Ronald Koole

geboren 17 juni 1950

te Leiden

Promotor : Prof.dr. P. Egyedi
Faculteit Geneeskunde, Universiteit Utrecht

This thesis was prepared at the Department of Oral and Maxillofacial Surgery, Prosthodontics and Special Dental Care, Faculty of Medicine, University Utrecht. University Hospital Utrecht, Heidelberglaan 100,
3584 CX Utrecht, The Netherlands.

Beoordelingscommissie:
Prof.dr. S.A. Duursma
Prof.dr. H.P. Freihofer
Prof.dr. E.H. Huizing
Prof.dr. B.D. de Jong
Prof.dr. M. Kon
Prof.dr. C. de Putter

Paranymphen: A.R.M. Wittkampf
P. Koole-Kisman

Da steh' Ich nun, Ich armer Tor!
Und bin so klug als wie zuvor;
J.W. Goethe

CIP-data Koninklijke Bibliotheek, Den Haag
Koole, Ronald
The bone graft in the alveolar cleft / Ronald Koole. -
Utrecht: Universiteit Utrecht, Faculteit Geneeskunde
Thesis Universiteit Utrecht. - with summary in Dutch.
ISBN 90-393-0613-3
Subject headings: congenital alveolar clefts / bonegrafting / alveolar cleft repair.

Dit proefschrift kwam tot stand dankzij giften van:
- Stichting tot Bevordering van de Mondheelkunde te Utrecht

Drukwerk: Libertas Grafische Communicatie - Bunnik

Ondanks Petra

Dankwoord

Ter gelegenheid van het verschijnen van een proefschrift worden velen in vele toonaarden bedankt; mijn oprechte dankbetuigingen gaan naar:

- Hooggeleerde Egyedi, beste Peter, de voortvarende wijze waarop je de begeleiding van het bijna gestrande proefschrift ter hand hebt genomen, heeft resultaat opgeleverd, we kregen het weer vlot; dat je ook als promotor optreedt, stemt mij dankbaar.
- Zeer geleerde Bosker, jij hebt met je nimmer aflatend enthousiasme in onze discussies over dit onderwerp (en nog vele andere) laten zien wat kan komen uit een goede samenwerking tussen een universiteitskliniek en een "perifere" kaakchirurgische praktijk. Beste Hans, mijn dank voor jouw inbreng en inzet.
- Geleerde Van Dijk, Lucas, jouw rustige, voortvarende manier van denken en doen heb ik in Groningen in het Diakonessenhuis mogen ervaren. De gedachten aangaande dit promotie onderwerp komen zeker óók uit jouw brein voort. Trouwens, zonder de Groninger inbreng had het proefschrift nooit tot stand kunnen komen!
- Zeer geleerde Noorman van der Dussen, beste Frans, jij bent één van de eersten geweest, die mij enthousiast heeft gemaakt voor de "schisispatiënt". Jij hebt met jouw inzet voor nieuwe delen der kaakchirurgie, mij steeds enthousiast willen houden om dit proefschrift af te maken, daarvoor veel dank. In de beginjaren negentig hebben we voor hete vuren gestaan, vriendschap overwon echter.
- Geleerde Wittkampf, beste Albert, samen begonnen wij met een promotie project in de afdeling Kaakchirurgie binnen de vakgroep Mondziekten/Kaakchirurgie en Bijzondere Tandheelkunde. Je hebt gewerkt aan veel, voornamelijk klinische zaken in de afgelopen jaren; sinds kort echter "volledig" aan jouw wetenschappelijke opdracht. Wederzijds stimuleren was een groot goed. Een vriendschap ontwikkelde zich. Dank!
- Geleerde Ten Broek, beste Frans Willem, jij moest eveneens veel klinische werkzaamheden vervullen, de afgelopen jaren. Straks mag en moet jij de wetenschappelijke kant gaan ontwikkelen. Veel dank voor de steun in de achter ons liggende tijd.
- Veel dank ben ik verschuldigd aan de "jongere" collegae specialisten en assistenten in opleiding van onze afdeling. Jullie maakten het mogelijk "er een tijd uit" te zijn voor de afronding van dit proefschrift. Veel werkzaamheden zijn overgenomen. Toine, Kees, Ben, Dirk, Robert, Gert en Nicky, zeer veel dank hiervoor.
- Zeer geleerden Visser en Klein; Walter en Willem en Astrid Suiker, jullie dank ik voor de steun bij het dieronderzoek en de bewerkingen ten behoeve van het his-

tologische onderzoek.

- Geleerde Alsbach, Hans, jou dank ik voor het datamanagement en de statistische bewerking van het materiaal. Tevens dank ik dr. P. Westers voor zijn waardevolle adviezen met betrekking tot de biostatistiek.
- De hooggeleerde leden van de Beoordelingscommissie ben ik dank verschuldigd voor hun inzet.
- Lieve Iris, jouw bijdrage aan de totstandkoming van het boek is groot. Bandjes uittypen met strandgeluiden op de achtergrond en de correcties verwerken op de vele computeruitdraaien waren niet eenvoudig: oren, ogen en vooral puzzelkunsten werden op hoog niveau aangesproken. Héél véél dank hiervoor.
- Geleerde De Lange en Van den Braber, Jan en Willem, jullie inzet voor het corvé, dat aan een retrospectieve analyse vastzit was groot. Willem, jij was er tot het laatste toe bij en weet wat het daarna nog aan arbeid heeft gekost. Zéér bedankt!
- Dank is verschuldigd aan de secretaresses, röntgenlaboranten en studenten van het voormalige Tandheelkundig Instituut, die patiënten opriepen, röntgenfoto's maakten en gebitsafdrukken vervaardigden, in het zicht van de naderende Sluiting!
- Ook de administratieve en verpleegkundige medewerkers van de collegae Bosker en Van Dijk in het Martini Ziekenhuis is zeer veel dank verschuldigd voor hun bijdragen aan het patiëntenonderzoek.
- Niet in de laatste plaats is dank, veel dank zelfs, verschuldigd aan de patiënten behandeld te Utrecht en te Groningen, die zonder omhaal zich allen aan dit onderzoek onderwierpen, allen in de overtuiging dat de uitkomst van het onderzoek hun medepatiënten tot nut kon zijn.
- Natuurlijk is er ook dank aan mijn ouders, die het mogelijk hebben gemaakt om mij "te laten studeren aan de Universiteit". Helaas heeft mijn moeder de éérste afronding daarvan niet mee mogen maken. Het stemt mij tot grote vreugde dat mijn vader en Ciska in goede gezondheid dit alles kunnen meebeleven.
- Nieke, in jou, dank ik ook Dick, die niet alleen heeft bijgedragen aan mijn vorming tot kaakchirurg en aan de opzet van het proefschrift.
- Tot (bijna) slot wil ik iedereen danken, die bij het lezen van dit dankwoord denkt: "Hij is veel mensen vergeten!".
  Ook U, hartelijk dank voor uw inzet, bijdrage, steun of opvang.

Petra, Michiel en Evelien, het proefschrift is eindelijk klaar, tijd te over (?) voor andere dingen. Jullie zeggen niets te kort te zijn gekomen en wilden niet bedankt of gezoend worden, want het is in woorden ook niet uit te drukken!

Voorwoord

Dit proefschrift kent een lange voorgeschiedenis.
Sinds 1938 worden in de Utrechtse Kliniek voor Mondziekten en Kaakchirurgie patiënten met één of andere vorm van cheilo-gnatho-palato-schisis behandeld. Het aantal schisisbaby's behandeld door professor J.W.A. Tjebbes (tot 1973), professor dr. P. Egyedi (tot 1986), dr. H. Müller (tot 1990) en dr. M.F. Noorman van der Dussen (tot 1992), bedraagt naar schatting meer dan 2700.
Blijdorp (1984) heeft één facet van de Utrechtse schisisbehandeling beschreven. Hij onderzocht het effect van het op verschillende leeftijden (3 en 6 jaar) opereren van het palatum durum en palatum molle op kaakgroei, KNO-status, spraak en persoonlijkheidsontwikkeling. Het lag dan ook voor de hand dat meer wetenschappelijk naonderzoek m.b.t. de schisisbehandeling, in de vorm van een proefschrift, uit deze kliniek zou worden gepresenteerd.
Toen op de najaarsvergadering van de Nederlandse Vereniging voor Mondziekten en Kaakchirurgie in 1979 collega Bosker zijn resultaten bekend maakte van de bottransplantatie in de gnathoschisis, gebruik makend van een transplantaat uit de kinstreek, werd uit "Utrecht" vrij sceptisch gereageerd. Vervolgens publiceerden Bosker en Van Dijk hun resultaten in het Nederlands Tijdschrift voor Tandheelkunde (1980); dit veranderde onze ideeën nog niet. Daarna kregen in 1984 de contacten tussen de Utrechtse Kliniek voor Kaakchirurgie en het Diakonessenhuis in Groningen, door introductie van het transmandibulaire implantaat (Bosker, 1986) een intensief karakter.
Er volgde een gedachtenwisseling over het mandibulaire bottransplantaat bij de reconstructie van de gnathoschisis. Het toenmalig hoofd der kliniek, prof.dr. P. Egyedi, stimuleerde schrijver dezes om het patiëntenmateriaal in Groningen te gaan bestuderen. Zo ontstond een tweede samenwerkingsverband tussen de Utrechtse Kliniek en de praktijk van Bosker en Van Dijk.
Na de eerste voorbereidende besprekingen en het maken van plannen tot uitvoering van het patiëntenonderzoek, kwam het bericht dat de subfaculteit Tandheelkunde te Utrecht zou sluiten. In december 1985 vertrok mede daardoor het hoofd en voorzitter van de Vakgroep Mondziekten en Kaakchirurgie der Rijksuniversiteit Utrecht. Dr. H. Müller werd hoofd ad interim van vakgroep en afdeling Mondziekten en Kaakchirurgie, tevens begeleider van het prille onderzoek.
In 1986, 1987 en 1988 werden de patiënten, zowel in Utrecht als in Groningen, opgeroepen en klinisch en röntgenologisch onderzocht. De gegevens werden bewerkt in de vrijgekomen hoogleraarskamer in het Tandheelkundig Instituut aan de Sorbonnelaan. Het dierexperimentele deel werd in 1988 samen met dr. W.J. Visser,

dr. W.R. Klein en A.M.H. Suiker opgezet en uitgevoerd.
In september 1988 moest de hoogleraarskamer wegens de effectuering van de sluiting van het Tandheelkundig Instituut worden verlaten. In de kelder van gebouw IV van het Academisch Ziekenhuis aan de Catharijnesingel werd het werk voortgezet. Hetgeen gepaard ging met vele onderbrekingen, omdat werkzaamheden in de kliniek, voorbereidingen voor de verhuizing naar het nieuwe Academisch Ziekenhuis en het mee-ontwerpen aan de divisiestructuur de toegewezen wetenschappelijke werktijd als sluitstuk van de (tijd)begroting deed fungeren.
In juli 1989 volgde de tweede grote verhuizing, naar het nieuwe A.Z.U. complex in de Uithof. Hier werd in een kleine stafkamer het werk (voort)gezet. Tussen december 1989 en mei 1991 verschenen drie artikelen m.b.t. het onderwerp (Koole et al, 1989; Koole, 1990; Koole et al, 1991). De beschikbare 1/2 weektaak voor wetenschappelijk werk werd veelal geïnvesteerd in de "vervanging" van een deel van de werkzaamheden van dr. H. Müller.
Daar de komst van een nieuwe hoogleraar Mondziekten en Kaakchirurgie werd bemoeilijkt door facultaire financiële perikelen (1992) rond de vakgroep Mondziekten/Kaakchirurgie en Bijzondere Tandheelkunde, ontbrak directe begeleiding. De afdeling Mondziekten en Kaakchirurgie werd bijna volledig "ontmensd" en er kon nauwelijks meer aan de wetenschappelijke taak worden gewerkt.
Sinds de zomer van 1992 is op de afdeling Mondziekten en Kaakchirurgie voorzien in de vacature van de hoogleraar door Prof.dr. P. Egyedi. De vacatures van stafleden werden gedurende 1993 aangevuld. Mede daarom ligt er thans een resultaat voor u.
Het proefschrift dient in de eerste plaats als een klinisch na-onderzoek te worden beschouwd (Hoofdstuk V, VI, VII). De nadruk valt daarbij echter op de klinische relevantie van de theorie over de bijzondere geschiktheid van het uit ectomesenchymaal weefsel bestaande bottransplantaat bij de chirurgie van de gnathoschisis. Daaraan is ook een literatuur studie gewijd en een dierexperimenteel onderzoek (hoofdstuk II en IV).
In hoofdstuk VIII worden de resultaten van de klinische na-onderzoeken bij verschillen patiëntengroepen aan een vergelijking, analyse en beschouwing door middel van de vragen uit de probleemstelling onderworpen. De conclusies worden tenslotte in het laatste hoofdstuk geformuleerd.

Literatuur

Blijdorp, P.A.: De invloed van de leeftijd van sluiten van het palatum bij de schisispatiënt op kaakgroei, KNO-status, spraak en persoonlijkheidsontwikkeling. Proefschrift R.U. Utrecht, 1984

Bosker, H., L. van Dijk: Het bottransplantaat uit de mandibula voor het herstel van de gnathopalatoschisis. Ned. Tijdschr. Tandheelk. 87 (1980) 383-389

Bosker, H.: The transmandibular implant. Proefschrift R.U. Utrecht, 1986

Koole, R., H. Bosker, M.F. Noorman van der Dussen: Late secondary autogenous bone grafting in cleft patients comparing mandibular (ectomesenchymal) and iliac crest (mesenchymal) grafts. Suppl. J. Cranio-Max. Fac. Surg. 17 (1989) 28-30

Koole, R.: De Schisispatiënt. Ned. Tijdschr. Tandheelk. 97 (1990) 472-476

Koole, R., W.J. Visser, W.R. Klein, A.M.H. Suiker: A Comparative Investigation on Autologous Mandibular and Iliac Crest Bone Grafts - An experimental Study in Sheep. J. Cranio-Max.-Fac. Surg. 19 (1991) 133-143

Contents

Chapter I

General Introduction

Chapter I
General Introduction

I.1. Introduction

I.1.1. Problems caused by a persistent alveolar cleft

The interrupted dental arch in the (sometimes) retrognathic maxilla of the total cleft patient accentuates, if unilateral, the asymmetry of maxilla, nose and lip (fig. 1). Apart from the asymmetry, speech and aesthetics may be severely impaired.

In bilateral cases the asymmetry may be absent, but the other problems are usually very conspicuous. The upper incisors are often rotated and deformed, the lateral ones sometimes agenetic and supernumerary teeth may be present within the cleft (Bergland et al, 1986). Prosthetic rehabilitation, if necessary with an overdenture (fig. 2) was the standard way of treatment in the (near) adult cleft patient up to about the late fifties, but the results were often disappointing.

Developments in orthodontics led to a combined orthodontic/prosthetic management of adolescent cleft patients resulting in semi-fixed bridge constructions or removable partial dentures bridging the alveolar cleft area. These constructions (fig. 3) were considered more satisfactory (Ranta, 1989).

The drawbacks of the still existing alveolar clefts however were still present (Koberg, 1973; Witsenburg, 1985):

Figure 1. *The interrupted dental arch accentuates the asymmetry of maxilla, nose and lip.*

Figure 2. *Prosthetic appliance with obturator and compensated retrognathia in the anterior part (front teeth in overdenture).*

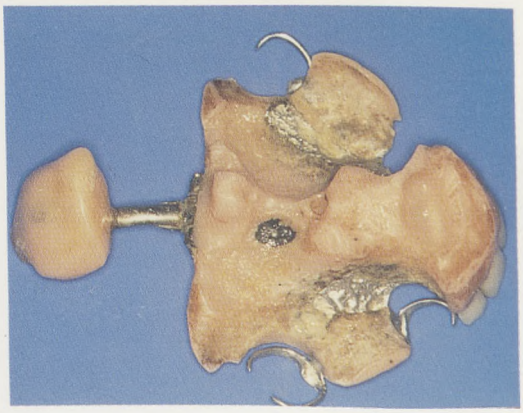

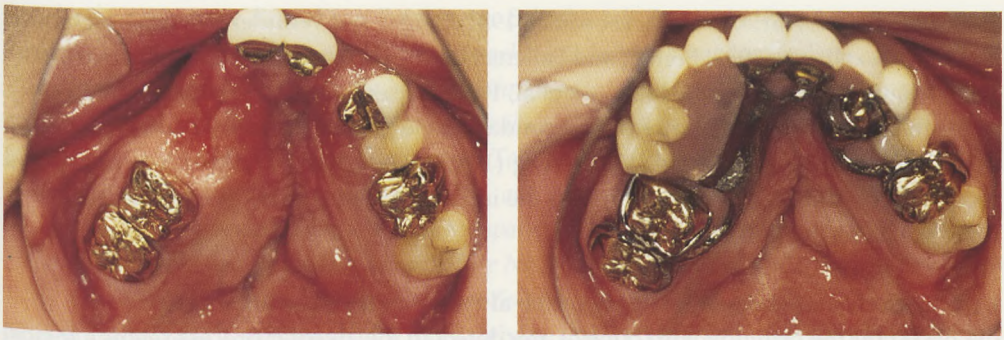

Figure 3. *Intra-oral view of a removable partial denture after prae-prosthetic orthodontic treatment.*

1. Alveolar crest defect, disturbed eruption of adjacent teeth (lateral incisors, canines).
2. Mobility of the maxillary segments with respect to each other, especially of the premaxilla in bilateral cases.
3. Periodontal disease around cleft-adjacent teeth in accordance with difficult access and thus impaired oral hygiene (locally).
4. Presence of an oronasal fistula with its sequelae (e.g. rhinitis, rhinolithiasis, escape of liquids to nose).
5. Impaired speech because of malposition of teeth and escape of air through palatal and vestibular fistulae.
6. Nasal asymmetry and asymmetry of the lip especially in unilateral clefts.

Clearly, persistence of the alveolar defect interferes with normal development in the area, hence the attempts by many authors to bridge the gap with bone at the earliest possible moment i.e. together with primary lip repair[1] (Schmid, 1955, 1960; Widmaier, 1966; Kriens, 1968; Monroe and Rosenstein, 1971; Friede and Johanson, 1974; Rosenstein, 1975; Chierici, 1977; Friede and Johanson, 1982; Koch, 1982; Nordin, 1982; Pfeiffer, 1982; Rosenstein et al, 1982; Johanson, 1984; Nylén et al, 1984; Pfeifer, 1984; Poupard et al, 1984; Schmid, 1984).

Since the primary bone grafting technique did not appeal to many workers in the field, secondary bone grafting - after 1st permanent molar eruption - was advocated by many others (Nordin and Johanson, 1955; Bäckdahl and Nordin, 1961; Stenström and Thilander, 1963; Brauer and Cronin, 1964; Flint, 1964; Baumgarten and Maeglin, 1966; Johanson, 1966; Muir, 1966; Perko, 1966; Cronin, 1968; Obwegeser and Perko, 1968; Perko, 1969; Härle, 1971; Koberg, 1971; Boyne and Sands, 1972; Jackson, 1972; Chausse, 1973; Freihofer and Obwegeser, 1973; Koberg, 1973; Stellmach, 1973; Boyne, 1974; Broude and Waite, 1974; Johanson et al, 1974; Boyne and Sands, 1976; Haag, 1977; Prahl-Andersen and Lekkas, 1977; Dorsch and Hochstein, 1979; Waite and Kersten, 1980; Abyholm et al,

[1] This is the so-called primary bone grafting procedure

1981; Bertz, 1981; Härle, 1981; Jackson et al, 1981; Geiger and Wunderlich, 1982; Jackson et al, 1982; Troxell et al, 1982; Freitag and Fallenstein, 1984; Turvey et al, 1984; Enemark et al, 1985; Krantz Simonsen, 1986; Enemark et al, 1987; Witsenburg and Freihofer, 1990).
In the following pages the expression secondary bone grafting is used as defined - among others - by Koberg (1973) and Witsenburg (1985). When using the words primary and secondary they refer to the age at which the initial grafting is done, not to the number of times it is done in a certain patient.

I.1.2. Evolution of surgical bridging of the alveolar cleft with a bone graft

On first sight the bridging with bone of any defect in the alveolar process seems a logical approach, were it not that any surgery in an area of rapid growth may in principle cause growth disturbances.
This is the reason that timing of this treatment modality and the possible influence of pre- and postoperative orthodontics are at present subject of scientific research in many centres (Shaw et al, 1992a; Molsted et al, 1992; Mars et al, 1992; Asher et al, 1992; Shaw et al, 1992b). Also a lot of attention is given to alveolar cleft repair (ACR) at international conferences on management of cleft patients (Monaco, 1985, 5th International Cleft Congress; Hamburg, 1987, 4th International Symposium on Cleft Palate; Jeruzalem, 1989, 6th International Congress on Cleft Palate; Broadbeach, 1993, 7th International Congress on Cleft Palate and Related Craniofacial Anomalies).
It all started at the beginning of this century when Von Eiselsberg (1901) bridged an alveolar cleft with a pedicled little finger graft. Lexer (1908) used a free bone graft and was probably the first surgeon to do so (Witsenburg, 1985). However, up to the second world war even great cleft surgeons like Veau (1931) and Axhausen (1936, 1941) made no serious attempts to close alveolar clefts. Possible reasons for this abstinence may have been the primitive state of general anaesthesia in continental Europe at that time, the absence of antibiotics and the lack of interest of orthodontics for the cleft patient. Of course there may also have been a major financial problem.
This is the reason that prosthodontic rehabilitation was the standard way of treatment of the problems caused by the persistent alveolar clefts.
The orthodontic-prosthetic era (already mentioned) was a step forward in the treatment of the alveolar cleft, but the decisive advance was made after world war II, when endotracheal intubation became routine in general anaesthesia and antibiotics became available. Also the vast experience with maxillofacial bone grafting accumulated during world war II (Mowlem, 1945, 1963) and the modern health care system which came into being in many countries in east and west may have been responsible for the development of the orthodontic/surgical treatment concept, which is now the standard in the developed countries (Bergland et al, 1986).
This concept is aptly expressed by Axhausen (1952) who wrote: *"Alle Versuche, durch Exzision der Schleimhaut im Bereich des engen Spaltes und durch Anfrischung der gegenüberliegenden Knochenflächen die knöcherne Verbindung zu erzwingen, sind ergebnislos geblieben. Der*

übliche Ausweg ist die Brücke von Eckzahn zu Eckzahn mit Ersatz der Frontzähne. Aber es ist doch nur ein Ausweg. Gäbe es ein Mittel, die nachträgliche knöcherne Verbindung zwischen dem Zwischenkiefer und den Seitenteilen herbeizuführen, so wäre dieser Weg unbedingt vorzuziehen; er würde es ermöglichen, wohlgebildete Frontzähne zu erhalten. Ein solches Mittel zu finden, scheint mir gegenwärtig das letzte Problem der Totalplastiken zu sein.
Vom allgemein-chirurgischen Gesichtspunkt aus wäre die Aufgabe am besten durch die Auflagerung eines periostgedeckten Knochenspans auf den Spalt zu lösen. Aber die schwere Zugänglichkeit des Spaltes und die unmittelbare Nachbarschaft der Mundhöhle erschweren diesen Weg. Am ehesten könnte es gangbar sein unter Zuhilfenahme der Knochenvorpflanzung".[2]
This opinion, which was shared by many others, induced the German maxillo-facial surgeon Schmid and the Swedish plastic surgeon Johanson to renew the attempt of bridging the alveolar cleft with a free bone graft (Schmid, 1955; Nordin and Johanson, 1955). The age at which these authors performed the grafting differed widely however: Schmid wanted to prevent the collapse of the alveolar segments and grafted at a very early age, i.e. together with lip closure when he implanted iliac crest bone into the alveolar cleft (primary grafting).
Nordin and Johanson grafted after completion of initial orthodontic treatment during the mixed dentition stage, also iliac crest bone. Thus the secondary grafting approach came into being, but also the controversy about which of the two should be preferred. In the end it seems that retarded growth of the maxilla as seen after primary grafting has all but decided this issue in favour of secondary grafting (Bardach, 1991). In the meantime, according to Witsenburg (1985) and Freihofer and Witsenburg (1990) more than 500 publications have appeared on the surgical technique, timing and donor site in these bone grafting procedures. We want to highlight publications by Schrudde and Stellmach, 1958; Ritter, 1959; Schrudde and Stellmach, 1959; Derichsweiler, 1964; Pruzanski, 1964; Perko, 1966; Widmaier, 1966; Pickrell and Quinn, 1967; Kriens, 1968; Obwegeser and Perko, 1968; Pickrell et al, 1968; Perko, 1969; Rehrmann et al, 1970; Rehrmann, 1971; Boyne and Sands, 1972; Jolleys and Robertson, 1972; Koberg, 1973; Robertson, 1973; Schilli et al, 1973; Stellmach, 1973; Friede and Johanson, 1974; Nylén et al, 1974; Rosenstein, 1975; Friede and Johanson, 1982; Koch, 1982; Nordin, 1982; Rosenstein et al, 1982; Schmid, 1982; Robertson and Jolleys, 1983; Grabowski, 1991; Hasund et al, 1991;

[2] "All attempts to obtain bony bridging of the alveolar gap by excision of the mucosa inside the narrow cleft and roughening the adjacent alveolar stumps have resulted in failure. The usual escape out of this problem is construction of a bridge from canine to canine with dummy replacement of the incisors. But it is an escape only. If it were possible to obtain a bony bridge between premaxilla and lateral alveolar processes, this approach should definitely be preferred; it would enable us to retain well developed incisors. To develop such a procedure appears to me nowadays to be the last problem in total rehabilitation. From the general surgical viewpoint realization of this challenge might best be obtained by insertion of a periosteum covered bone graft into the cleft. But the difficult access to the cleft and the immediate proximity of the oral cavity render this approach rather difficult. Maybe a staged grafting procedure could best be applied."

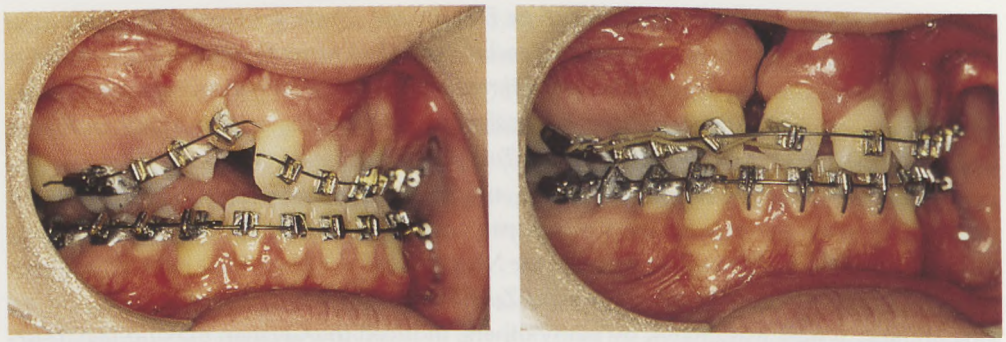

Figure 4. *Prae- and postoperative photograph of a Le Fort I osteotomy, advancement and transversal widening of the maxilla. The reopening of the cleft is evident.*

Johanson et al, 1991; Rosenstein and Kernahan, 1991; Scheer and Pfeifer, 1991; Schwenzer et al, 1991; Steinhäuser and Gottsauner, 1991; Stoll et al, 1991.

Tertiary bone grafting refers to the bridging of an alveolar cleft after a maxillary osteotomy (Witsenburg, 1985). The first major osteotomies of the maxilla in cleft patients in cases where gross deformity was present were done in the early sixties (Obwegeser, 1965). In the Netherlands this type of surgery was introduced in the early seventies (Egyedi, 1973; Stoelinga and Wentges, 1973).

The surgical advancement of a retrognathic maxilla requires sometimes a (re-)opening of the alveolar cleft in order to obtain a proper occlusion (fig. 4). In some cases the cleft can be bridged with a bone graft in the same session, but in major deformities or/and in cases of severe scarring, the grafting of the cleft is better deferred until at least 6 months after the osteotomy (Koole, 1990). When properly managed the majority of cleft patients will never need an osteotomy, but in a significant minority impairment of growth is such, that proper rehabilitation of occlusion and aesthetics cannot do without it. In these cases, as a rule a prosthetic dental solution for final dental rehabilitation is required (fig. 5).

I.1.3. Aim of the operation

ACR with bone grafting, performed between an age of 9 and 12 years has the following aims (Waite and Kersten, 1980):

1. to promote eruption of the canine(s) into the alveolar defect;
2. to stabilize the alveolar segments and improve periodontal support of cleft-adjacent teeth;
3. to render orthodontic alignment of teeth in the cleft area possible;
4. to aid in the closure of oro-nasal fistulae;
5. to provide the necessary stability for bridgework in cases of hypodontia or where a residual gap in the dental arch remains;
6. to improve speech by the proper alignment of the anterior teeth and by the closure of the fistulae;

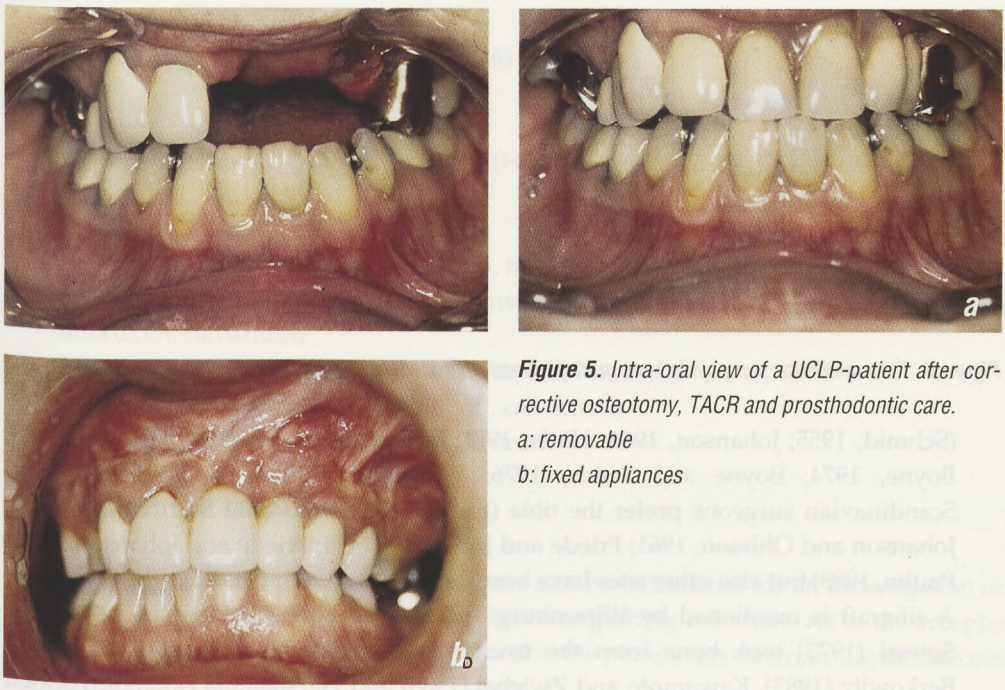

Figure 5. *Intra-oral view of a UCLP-patient after corrective osteotomy, TACR and prosthodontic care.*
a: removable
b: fixed appliances

7. to provide bony support for the ala(e) of the nose, thus improving aesthetics.

I.1.4. Problems in ACR and bone grafting

Incorporation of a bone graft and maintenance of its volume are dependent on a number of factors, like its physiological quality and the quantity and load of the bone after grafting (Frost, 1963). This raises the question about the most suitable donor site for a specific grafting procedure, a problem (often) referred to in publications in the preprosthetic literature on alveolar reconstruction, where the long-term results are significantly impaired by graft resorption (e.g. Obwegeser, 1967; Fazili et al, 1978; Stoelinga et al, 1978; Härle, 1979; Stoelinga et al, 1983; Swart, 1984).

The final choice of a donor site however is also dependent on complications during harvesting, the amount of bone available and surgical-technical aspects.

As to bone grafting and ACR the following can be said.

1. Loading of the graft.
   Schmid (1955), Schrudde and Stellmach (1959) and Boyne en Sands (1972, 1976) emphasized the importance of functional loading of the grafted bone by orthodontically moving adjacent teeth into it. By this procedure maintenance of the grafted bone according to these authors would be ensured.
2. Choice of the donor site.
   According to the literature several bones can be used as a donor site. The iliac crest is preferred by most authors because of it's presumed excellent osteogenetic qualities

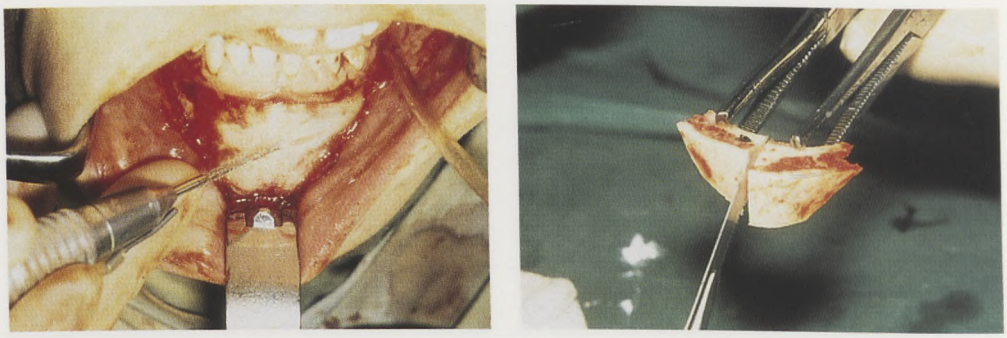

Figure 6. *The mandibular symphysis bone graft. Harvesting procedure and the bicortical graft.*

(Schmid, 1955; Johanson, 1966; Härle, 1971; Boyne and Sands, 1972; Koberg, 1973; Boyne, 1974; Boyne and Sands, 1976; Witsenburg, 1985). Some French and Scandinavian surgeons prefer the tibia (Freidel, 1957; Bäckdahl and Nordin, 1961; Johanson and Ohlsson, 1961; Friede and Johanson, 1974; Friede and Johanson, 1982; Paulin, 1988) but also other sites have been used.

A ribgraft is mentioned by Witsenburg and Freihofer (1990); Engdahl (1972) and Spiessl (1973) took bone from the trochanter major. Jackson (1983), Wolfe and Berkowitz (1983), Kawamoto and Zwiebel (1985) and Harsha et al (1986) advocated use of the calvarial graft.

Bosker and Van Dijk (1980) introduced the mandibular symphysis bone grafts for ACR (fig. 6). They stated that the embryological similarity between the bony tissue of chin and maxilla - both are considered to be of ectomesenchymal origin - might have a positive influence on the final result as compared to purely mesenchymal bone grafts. This hypothesis will extensively be dealt with in chapter II.

3. The donor site.

Harvesting a bone graft may give rise to complications like seroma, hemorrhage, wound infection, scarring, but also to specific complications linked to the donor site:

- iliac crest grafts
  * gait disturbances
  * deviation in form
  * meralgia paresthetica (neuropraxia N. cut. fem. lat.)
  * herniation of intestine (Mrasik et al, 1980)
- rib grafts
  * pneumothorax
  * respiratory problems (Cullum et al, 1984)
- tibial grafts
  * gait disturbances
  * impaired growth (Friede and Johanson, 1974, 1982)
- calvarial grafts

  * subdural hematoma
  * dural tears (Jackson et al, 1983, 1986)
- chin grafts
  * mental nerve disturbances
  * devitalization lower anterior teeth (Hoppenreys et al, 1992)

Advantages of the different donor sites:
- saving of time by 2 team approach (rib, tibia, iliac crest)
- no time lag between harvesting and insertion of graft if harvesting is done in same area (chin, calvarium)
- little postoperative pain (chin, rib, calvarium)
- reduced hospitalization time (chin, rib, calvarium)
- ample supply of cancellous bone (iliac crest)

I.2. Statement of problems

In view of the above a number of parameters can be formulated for an investigation on the success of the ACR and merits of the different grafting materials. As to the acceptor region the following differences may be found in the parameters determining the success.

1. Eruption of canines.
   Is there a difference in spontaneous canine eruption into the graft?
2. Periodontium.
   Is there a difference in the periodontal condition of the teeth in the former cleft area?
3. Morphology alveolar process.
   Is there a difference in the morphology of the alveolar process in the former cleft area?
4. Orthodontic results in former cleft region.
   Is there a difference in the percentage of uninterrupted dental arches resulting from orthodontic treatment?
5. Oronasal fistulae.
   Is there a difference in success rate as to closure of fistulae?
6. Alveolar bone resorption (ABR) at the interdental alveolar crest.
   Is it possible to judge the quality of the grafted bone by looking at the degree of the interdental ABR in the former cleft region
   a. in case of a continuous dental arch being present (usually after orthodontic treatment)
   b. in case of an interrupted gap in the dental arch (less functional load as compared to a.)

In comparing groups of patients there are several differences in their composition which should be considered and which might influence the results, e.g.:

- width of the cleft (at birth and) before grafting
- surgical technique during primary surgery
- number of surgical interventions in the cleft region prior to (secondary) ACR
- age of the patient/dental age at the time of bone grafting
- pre-surgical orthodontics
- method of oral covering of the graft
- post-surgical orthodontics

With respect to the donor area the following questions are relevant:

1. Are there significant differences in local morbidity?
2. Are there significant differences in duration of surgery?

The subject of this thesis is a retrospective study in which two groups of patients were investigated, in one of which chin bone had been used, whilst the other group had been treated with bone from the iliac crest.
The drawbacks of a retrospective study are known - missing data, incomplete data, Berkson fallacy, confounding bias - but a prospective randomized study can only be attempted *after* an exploratory investigation as described has been done.
Besides, on the basis of what already has been published on this topic it is hardly acceptable from a medico-legal point of view to randomize (Witsenburg and Freihofer, 1990; Freihofer et al, 1993).
A group of patients in whom a tertiary bone grafting procedure (after completion of the dentition (>17.5y) or after a Le Fort I osteotomy) had been done has also been investigated in order to render some perspective to the findings in the other two groups.

I.3. Aim of the study (research objectives)

This follows from the questions formulated in I.2.

1. To determine the value (quality) of a chin bone graft as compared with the "golden standard", the bone graft from the iliac crest.
2. To investigate whether the theoretical superiority of ectomesenchymal bone can be substantiated clinically.

References

Abyholm, F.E., O. Bergland, G. Semb: Secondary bone grafting of alveolar clefts. A surgical/orthodontic treatment enabling a non-prosthetic rehabilitation in cleft lip and palate patients. Scand. J. Plast. Reconstr. Surg. 15 (1981) 127

Asher-McDade, C., V. Brattström, E. Dahl, J. McWilliam, K. Molsted, D.A. Plint, B. Prahl-Andersen, G. Semb, W.C. Shaw, R.P.S The. A six-center international study of treatment outcome in patients with clefts of the lip and palate. Part 4. Assessment of nasolabial appearance. Cleft Palate-Craniofac. Surg. 29 (1992) 409

Axhausen, G.: Technik und Ergebnisse der Gaumenplastiek. Thieme, Leipzig, 1936. (Cited by: Luhr, H.-G., W.-J. Höltje, U. Hammer: Über den Verschluss von Restlöchern im Gaumenbereich. In: K. Schuchardt: Fortschr. der Kiefer-Gesichtschir. 16/17, Thieme, Stuttgart 1973, 293)

Axhausen, G.: Technik und Ergebnisse der Lippenplastiken. Thieme Verlag, Leipzig 1941

Axhausen, G.: Technik und Ergebnisse der Spaltplastiken. Hanser, München 1952

Bäckdahl, M., K.E. Nordin: Replacement of the maxillary bone defect in cleft palate. A new procedure. Acta. Chir. Scand. 122 (1961) 131

Bardach, J., K.E. Salyer, eds.: Surgical Techniques in Cleft Lip and Palate. Mosby Year Book (1991) 305-306 335-350

Baumgartner, P., B. Maeglin: Die primäre und sekundäre Osteoplastik in der Chirurgie der Gaumenspalte. Schweiz. Med. Wschr. 96 (1966) 883

Bergland, O., G. Semb, F.E. Abyholm: Elimination of the residual alveolar cleft by secondary bone grafting and subsequent orthodontic treatment. Cleft Palate J. 23 (1986) 175

Bertz, J.E.: Bone grafting of alveolar clefts. J. Oral. Surg. 39 (1981) 874

Bosker, H., L. van Dijk: Het bottransplantaat uit de mandibula voor herstel van de gnathoschisis. Ned. Tijdschr. Tandheelk. 87 (1980) 383

Boyne, P.J., N.R. Sands: Secondary bone grafting of residual alveolar and palatal clefts. J. Oral. Surg. 30 (1972) 87

Boyne, P.J.: Use of marrow-cancellous bone grafts in maxillary alveolar and palatal clefts. J. Dent. Res. 53 (1974) 821

Boyne, P.J., N.R. Sands: Combined orthodontic-surgical management of residual palato-alveolar cleft defects. Am. J. Orthod. 70 (1976) 20

Brauer, R.O., T.D. Cronin: Maxillary orthopedics and anterior palate repair with bone grafting. Cleft Palate J. 1 (1964) 31

Broude, D.J., D.E. Waite: Secondary closure of alveolar defects. Oral Surg. 37 (1974) 829

Chausse, J.-M.: Ergebnisse des Verschlusses von Restspalten. In: K. Schuchardt: Fortschr. der Kiefer-Gesichtschir. vol. 16/17, Thieme, Stuttgart (1973) 314

Chierici, G.: Experiments on the influence of oriented stress on bone formation replacing bone grafts. Cleft Palate J. 14 (1977) 114

Cullum, P.E., D.E. Frost, T.B. Newland, T.M. Keane, M.J. Ehler: Evaluation of hydroxylapatite particles in

repair of alveolar clefts in dogs. J. Oral Max.-Fac. Surg. 46 (1988) 290

Cronin, T.D.: Some results and thoughts on bone grafting of cleft palates. In: J.J. Longacre: Craniofacial anomalies: pathogenesis and repair. Lippincott, Philadelphia (1968) 77

Derichsweiler, H.: Early orthodontic treatment of cleft palate patients as related to the prevention of jaw anomalies. In: R. Hotz: Early treatment of cleft lip and palate. Huber, Bern (1964) 132

Dorsch, C., H.J. Hochstein: Vergleichende Untersuchungen zum Einfluss der Osteoplastik auf das Oberkieferwachstum. Zahn-, Mund- und Kieferheilkd. 67 (1979) 706

Egyedi, P.: Chirurgische correctie van de gedeformeerde maxilla bij volwassen patiënten met cheilognathopalatoschisis. Ned. T. Geneesk. 117 (1973) 25

von Eiselsberg, F.W.: Zur Technik der Uranoplastik. Arch. Klin. Chir. 64 (1901) 509

Enemark, H., E. Krantz-Simonsen, J.E. Schramm: Secondary bone grafting in unilateral cleft lip patients: indications and procedure. Int. J. Oral. Surg. 14 (1985) 2

Enemark, H., S. Sindet-Pedersen, M. Bundgaard: Long-term results after secondary bone grafting of alveolar clefts. J. Oral Max.-Fac. Surg. 45 (1987) 913

Engdahl, E.: Bone regeneration in maxillary defects. Scand. J. Plast. Reconstr. Surg. suppl. 8 (1972)

Fazili, M., G.R. van Overvest, A.M. Vernooy, W.J. Visser, M.A.J. van Waas: Follow-up investigation of reconstrucion of the alveolar process in the atrophic mandible. J. Oral Surg. 7 (1978) 400

Flint, M.: Chip bone grafting of the mandible. Br. J. Plast. Surg. 17 (1964) 184

Freidel, Ch.: Greffes osseuses. In: Greffes Implantations inclusions. Ed.: Duclos, Freidel, Dumas, De Mourques, Merle-Béral. Masson Paris 1937, 8

Freihofer, H.P.M., H. Obwegeser: Verschluss grosser Gaumendefekte durch Weichteil- und Knochenplastik. In: K. Schuchardt: Fortschr. Kiefer-Gesichtschir. vol. 16/17, Thieme, Stuttgart (1973) 311

Freihofer, H.P.M., W.A. Borstlap, A.M. Kuipers-Jagtman, R.A.C.A. Voorsmit, P.A. van Damme, K.L.W.M. Heidbüchel, V.M.F. Borstlap-Engels: Timing and transplant materials for closure of alveolar clefts. A. Clinical comparison of 296 cases. J. Cranio-Max.-Fac. Surg. 21 (1993) 143

Freitag, V., G. Fallenstein: Über die sekundäre Osteoplastik im Wechselgebiss bei Lippen-Kiefer-Gaumen-Spalten. Dtsch. Z. Mund-Kiefer-Gesichts-Chir. 8 (1984) 343

Friede, H., B. Johanson: A follow-up study of cleft children treated with primary bone grafting I. Orthodontic aspects. Scand. J. Plast. Reconstr. Surg. 8 (1974) 88

Friede, H., B. Johanson: Adolescent facial morphology of early bone grafted cleft, lip and palate patients. Scand. J. Plast. Reconstr. Surg. 16 (1982) 41

Frost, H.M.: Bone remodelling dynamics. Springfield Illinois USA. Charles C. Thomas, publisher. (1963) 52

Geiger, S.A., E. Wunderlich: Die Position des Eckzahnes bei Spaltpatienten nach früher sekundärer Plastik. 6th Congress E.A.M.F.S. Hamburg 1982

Grabowski, R.: Is the facial growth pattern of cleft palate patients inherited or aquired. In: G. Pfeifer: Craniofacial abnormalities and clefts of lip, alveolus and palate. Thieme, Stuttgart, New York (1991) 378

Haag, R.: Das Verhalten des Knochentransplantates bei jugendlichen Lippen-Kiefer-Gaumen-Spaltpatienten

nach Überbrückung der Alveolarspalte. Thesis, University of Zürich, Ströbele, Romanshorn 1977

Härle, F.: Die Zeitwahl der Osteoplastik bei Lippen-Kiefer-Gaumen-Spalten. Thesis, University of Freiburg, Quintessenz, Berlin 1971

Härle, F.: Follow-up investigation of surgical correction of the atrophic alveolar ridge by Visor-osteotomy. J. Max.-Fac. Surg. 7 (1979) 283

Härle, F.: Transplantatbett und Transplantat bei der sekundären Kieferspaltosteoplastik. In: H. Cotta and A.K. Martini: Implantate und Transplantate in der Plastischen und Wiederherstellungschirurgie. Springer, Berlin (1981) 201

Harsha, B.C., T.A. Turvey, S.K. Powers: Use of bone grafts in maxillofacial surgery. A preliminary report. J. Oral Max.-Fac. Surg. 44 (1986) 11

Hasund, A., G. Pfeifer, R. Wolf: Cephalometric comparison of the growth of patients with early and late osteoplasty in bilateral complete clefts of lip, alveolus, and palate. In: G. Pfeifer: Craniofacial abnormalities and clefts of the lip, alveolus and palate. Thieme, Stuttgart, New York (1991) 345

Hoppenreijs, T.J.M., E.S. Nijdam, H.P.M. Freihofer: The chin as a donor site in early secondary osteoplasty: a retrospective clinical and radiological evaluation. J. Cranio-Max.-Fac. Surg. 20 (1992) 119

Jackson, I.T.: Closure of secondary palatal fistuale with intra-oral tissue and bone grafting. Br. J. Plast. Surg. 25 (1972) 537

Jackson, I.T., L.R. Scheker, J.G. Vandervord, J.G. McLennan: Bone marrow grafting in the secondary closure of alveolarpalatal defects in children. Br. J. Plast. Surg. 34 (1981) 422

Jackson, I.T., J.G. Vandervord, J.G. McLennan, F.B. Christie, J.C. McGregor: Bone grafting of the secondary cleft lip and palate deformity. Br. J. Plast. Surg. 35 (1982) 345

Jackson, I.T., C. Pellet, J.M. Smith: The skull as a bone graft donor site. Am. Plast. Surg. 11 (1983) 527

Jackson, I.T., G. Helden, R. Marx: Skull bone grafts in maxillofacial and craniofacial surgery. J. Oral Max.-Fac. Surg. 44 (1986) 949

Johanson, B., A. Ohlsson: Bone grafting and dental orthopaedics in primary and secondary cases of cleft lip and palate. Acta Chir. Scand. 122 (1961) 112

Johanson, B.: Secondary osteoplastic completion of maxilla and palate. In: K. Schuchardt: Treatment of patients with clefts of lip, alveolus and palate. Thieme, Stuttgart (1966) 128

Johanson, B., A. Ohlsonn, H. Friede, J. Ahlgren: A follow-up study of cleft lip and palate patients treated with orthodontics secondary bone grafting and prosthetic rehabilitation. Scand. J. Plast. Reconstr. Surg. 8 (1974) 121

Johanson, B.: Primary and intermediate bone grafting and related procedures. Pannel session. In: M. Hotz, W. Gnoinski, M. Perko, H. Nussbaumer, E. Hof, R. Haubensak: Early treatment of cleft lip and palate. Hans Huber Publishers. Toronto, Lewiston N.Y., Bern, Stuttgart (1984) 221

Johanson, B., J. Lilja, H. Friede: Long-term results following treatment of clefts of the lip, alveolus and palate. In: G. Pfeifer: craniofacial abnormalities and clefts of the lip, alveolus and palate. Thieme, Stuttgart, New York (1991) 371

Jolleys, A., N.R.E. Robertson: A study of the effects of early bone grafting in complete clefts of the lip and palate. Br. J. Plast. Surg. 25 (1972) 229

Kawamoto, H.K., P.C. Zwiebel: Cranial bone grafts and alveolar clefts. In: Caronni, E.P. (ed.) Craniofacial Surgery. Little, Brown, Boston-Toronto (1985) 449

Koberg, W.R.: System der Rehabilitation von Patienten mit Lippen-Kiefer-Gaumen-Spalten. Thesis, University of Düsseldorf, Westdeutscher Verlag, Opladen 1971

Koberg, W.R.: Present view on bone grafting in cleft palate (a review of literature). J. Max.-Fac. Surg. 1 (1973) 185

Koch, J.: 15jährige Erfahrungen mit der primären Knochentransplantation beim Verschluss der Kiefer- und Gaumenspalten im 4. Lebensjahr. In: G. Pfeifer: Lippen-Kiefer-Gaumen-Spalten. Thieme, Stuttgart (1982) 112

Koole, R.: Behandeling van de schisispatiënt. Overzicht en achtergronden. Ned. Tijdschr. Tandheelk. 97 (1990) 472

Krantz Simonsen, E.: Secondary bone-grafting for repair of residual cleft defects in the alveolar process and hard palate (a new surgical technique). Int. J. Oral Max.-Fac. Surg. 15 (1986) 1

Kriens, O.: Primary osteoplasty in patients with clefts of lip, alveolus and palate. Acta Oto-rhino-laryng. Belg. 22 (1968) 687

Lexer, E.: Die Verwendung der freien Knochenplastik nebst Versuchen über Gelenkversteifung und Gelenktransplantation. Arch. Klin. Chir. 86 (1908) 942

Mars, M., C. Asher-McDade, V. Brattström, E. Dahl, J. McWilliam, K. Molsted, D.A. Plint, B. Prahl-Andersen, G. Semb, W.C. Shaw, R.P.S. The: A six-center international study of treatment outcome in patients with clefts of the lip and palate. Part 3. Dental arch relationships. Cleft Palate-Craniofac. J. 29 (1992) 405

Molsted, K., C. Asher-McDade, V. Brattström, E. Dahl, M. Mars, J. McWilliam, K. Molsted, D.A. Plint, B. Prahl-Andersen, G. Semb, W.C. Shaw, R.P.S. The: A six-center international study of treatment outcome in patients with clefts of the lip and palate. Part 2. Craniofacial form and soft tissue profile. Cleft Palate-Craniofac. J. 29 (1992) 398

Monroe, C.W., S.W. Rosenstein: Maxillary orthopedics and bone grafting in cleft lip and palate. In: Grabb, W.C, S.W. Rosenstein, K.R. Bzoch (Eds.): Cleft Lip and Palate. Little, Brown & Co., Boston (1971) 573

Mowlem, R.: Cancellous chip bone-grafts. The Lancet 2 (1945) 746

Mowlem, R.: Bone Grafting. Br. J. Plast. Surg. 16 (1963) 293

Mrazik, J., C. Amato, S. Leban, A. Mashberg: The ilium as a source of autogenous bone for grafting: clinical considerations. J. Oral Surg. 38 (1980) 29.

Muir, I.F.K.: Repair of the cleft alveolus. Br. J. Plast. Surg. 19 (1966) 30

Nordin, K.E.: Prä-operative kieferorthopädische Behandlung und frühe primäre Osteoplastik bei Patienten mit einseitigen totalen Lippen-, Kiefer-, Gaummen-Spalten. In: G. Pfeifer: Lippen-Kiefer-Gaumen-Spalten. Thieme, Stuttgart (1982) 75

Nordin, K.E., B. Johanson: Freihe Knochentransplantationen bei Defekten im Alveolarkamm nach kieferorthopädischer Einstellung der Maxilla bei Lippen-Kiefer-Gaumen-Spalten. Fortschr. Kiefer-Gesichtschir. vol. 1, Thieme, Stuttgart (1955) 168

Nordin, K.-E., O. Larson, B. Nylén, G. Eklund: Early bone grafting in complete cleft lip and palate cases following maxillofacial orthodpedics. I. The method and the skeletal development form seven to thirteen years of age. Scand. J. Plast. Reconstr. Surg. 17 (1983) 33

Nylén, B., N. Körlof, C. Arnander, R. Leanderson, B. Karr, K.E. Nording: Primary, early bone grafting in complete clefts of the lip and palate. A follow-up study of 53 cases. Scand. J. Plast. Reconstr. Surg. 8 (1974) 79

Nylén, B., O. Larson, K.-E. Nordin, M. Ideberg, J. Karling, G. Henningson, B. Fritzell: Early treatment in Stockholm, including presurgical orthopedics and bone grafting. In: M. Hotz, W. Gnoinski, M. Perko, H. Nussbaumer, E. Hof, R. Haubensak (Eds.): Early treatment of cleft lip and palate. Hans Huber Publishers. Toronto, Lewiston N.Y., Bern, Stuttgart (1984) 76

Obwegeser, H.: Eingriffe am Oberkiefer zur Korrektur des Progenen Zustandsbildes. Schweiz. Mschr. Zahnheilk. 75 (1962) 365

Obwegeser, H.: Weitere Erfahrungen mit der Aufbauenden Kammplastik. Schweiz. Mschr. Zahnheilk. 77 (1967) 1002

Obwegeser, H., M. Perko: Die Rekonstruktionen des Knochendefektes bei Lippen-Kiefer-Gaumen-Spaltenpatienten. Dtsch. Zahn, Mund- und Kieferhlk. 50 (1968) 203

Paulin, G., P. Åstrand, J.B. Rosenquist, L. Barholdson: Intermediate bone grafting of alveolar clefts. J. Cranio-Max.-Fac. Surg. 16 (1988) 2

Perko, M.: Gleichzeitige Osteotomie des Zwischenkiefers, Restspaltenverschluss und Zwischenkieferversteifung durch sekundäre Osteoplastik bei Spätfällen von beidseitigen Lippen-Kiefer-Gaumen-Spalten. Dtsch. Zahn-Mund-Kieferheilk. 47 (1966) 1

Perko, M.: Die chirurgische Spätkorrektur von Zahn und Kieferstellungsanomalien bei Spaltpatienten. Schweiz. Mschr. Zahnheilk. 79 (1969) 19

Pfeifer, G.: Der Einfluss der primären osteoplastik bei Lippen-, Kiefer-, Gaumenspalten auf das Oberkieferwachstum. In: G. Pfeifer: Lippen-Kiefer-Gaumen-Spalten. Thieme, Stuttgart (1982) 97

Pfeifer, G.: Primary bone grafting discontinued - evolution of the Hamburg approach. In: M. Hotz, W. Gnoinski, M. Perko, H. Nussbaumer, E. Hof, R. Haubensak: Early treatment of cleft lip and palate. Hans Huber Publishers. Toronto, Lewiston N.Y., Bern, Stuttgart (1984) 90

Pickrell, K., G. Quinn: Primary, secondary and tertiary bone grafts in clefts of the lip and palate. Panminerva Med. 9 (1967) 402

Pickrell, K., G. Quinn, R. Massengill: Primary bone grafting of the maxilla in cleft of the lip and palate. A four year study. Plast. Reconstr. Surg. 41 (1968) 438

Poupard, B., H. Coornaert, H. Ribière, P.A. Debaere, A.M. Tréanton: Early bone grafting versus delay of procedures interfering with maxillary bone - twenty years' experience. In: M. Hotz, W. Gnoinski, M. Perko, H. Nussbaumer, E. Hof, R. Haubensak: Early treatment of cleft lip and palate. Hans Huber Publishers. Toronto, Lewiston N.Y., Bern, Stuttgart (1984) 103

Prahl-Andersen, B., C. Lekkas: Het vrije bottransplantaat bij schisispatiënten ten behoeve van orthodontische behandeling. Ned. Tijdschr. Tandheelk. 84 (1977) 435

Pruzanski, S.: Pre-surgical orthodopedics and bone grafting for infants with cleft lip and palate: a dissent. Cleft Palate J. 1 (1964) 164

Ranta, R.: Orthodontic treatment in adults with cleft lip and palate. J. Cranio Max.-Fac. Surg. 17 (1989) 42

Rehrmann, A.: The effect of early bone grafting on the growth of upper jaw in cleft lip and palate children. Computer evaluation. Min. Chirurgica 26 (1971) 874

Rehrmann, A., W.R. Koberg, H. Koch: Long term postoperative results of primary and secondary bone grafting in complete clefts of lip and palate. Cleft Palate J. 7 (1970) 206

Ritter, R.: Beurteilung des Zwischenkiefers bei Spaltkindern von seiten des Kieferchirurgen, des Orthopäden und des Prothetikers. Fortschr. Kiefer-, Gesichtschir. Bd. 5. Thieme, Stuttgart 1959

Robertson, N.R.E.: Early treatment - a critique. Trans. Europ. Orthod. Soc. (1973) 547

Robertson, N.R.E., A. Jolleys: An 11-year follow-up of the effects of early bone grafting in infants born with complete clefts of the lip and palate. Br. J. Plast. Surg. 36 (1983) 438

Rosenstein, S.W.: Orthodontic and bone grafting procedures in a cleft lip and palate series: An interim cephalometric evaluation. Angle Orthod. 45 (1975) 227

Rosenstein, S.W., C.W. Monroe, D.A. Kernahan, B.N. Jacobson, B.H. Griffith, B.S. Bauer: The case for early bone grafting in cleft lip and cleft palate. Plast. Reconstr. Surg. 70 (1982) 297

Rosenstein, S.W., D.A. Kernahan: Bilateral clefts of the lip, alveolus, and palate: treatment modalities and long-term follow-up. In: G. Pfeifer: Craniofacial abnormalities and clefts of the lip, alveolus and palate. Thieme, Stuttgart, New York (1991) 341

Scheer, P., G. Pfeifer: Long-term results following orthodontic treatment and osteoplasty in the permanent dentition in unilateral complete clefts. In: G. Pfeifer: Craniofacial abnormalities and clefts of the lip, alveolus and palate. Thieme, Stuttgart, New York (1991) 302

Schilli, W., F. Härle, C. Holm: Die Kieferentwicklung nach Operation einseitiger Kiefer-Gaumenspalten mit Campbell-Vomerlappen und Widmaier-Velumplastik. In: K. Schuchardt: Fortschr. Kiefer-, Gesichtschir., vol. 16/17, Thieme, Stuttgart (1973) 131

Schmid, E.: Die Annäherung der Kieferstümpfe bei Lippen-Kiefer-Gaumen-Spalten; ihre schädlichen Folgen und Vermeidung. In: K. Schuchardt: Fortschr. Kiefer-, Gesichtschir. vol. 1. Thieme, Stuttgart (1955) 37

Schmid, E.: Die Osteoplastik bei Lippen-Kiefer-Gaumenspalten. Arch. Klin. Chir. 295 (1960) 868

Schmid, E.: Spätergebnisse nach primärer Osteoplastik. In: G. Pfeifer: Lippen-Kiefer-Gaumen-Spalten. Thieme, Stuttgart (1982) 93

Schmid, E.: Experience gathered and results obtained with primary osteoplasty. In: M. Hotz, W. Gnoinski, M. Perko, H. Nussbaumer, E. Hof, R. Haubensak: Early treatment of cleft lip and palate. Hans Huber Publishers. Toronto, Lewiston N.Y., Bern, Stuttgart (1984) 80

Schrudde, J., R. Stellmach: Die primäre Osteoplastik der Defekte des Kieferbogens bei Lippen-, Kiefer-, Gaumenspalten am Säugling. Zbl. Chir. 83 (1958) 849

Schrudde, J., R. Stellmach: Primäre Osteoplastik und Kieferbogenformung bei Lippen-Kiefer-Gaumenspalten. In: K. Schuchardt: Fortschr. Kiefer-Gesichtschir. vol. 5. Thieme, Stuttgart (1959) 247

Schwenzer, N., D. Dausch-Neumann, R. Bublitz, H. Feifel: Surgical-orthodontic long-term results of bilateral primary bone grafting in clefts of lip, alveolus and palate. In: G. Pfeifer: Craniofacial abnormalities and clefts of the lip, alveolus and palate. Thieme, Stuttgart, New York (1991) 367

Shaw, W.C., C. Asher-McDade, V. Brattström, E. Dahl, J. McWilliam, K. Molsted, D.A. Plint, B. Prahl-Andersen, G. Semb, R.P.S. The: A six-center international study of treatment outcome in patients with clefts of the lip and palate. Part 1. Principles and study design. Cleft Palate-Craniofac. J. 29 (1992) 393

Shaw, W.C., E. Dahl, C. Asher-McDade, V. Brattström, M. Mars, J. McWilliam, K. Molsted, D.A. Plint, B. Prahl-

Andersen, C. Robert, G. Semb, R.P.S. The: A six-center international study of treatment outcome in patients with clefts of the lip and palate. Part 5. General discussion and conclusions. Cleft Palate-Craniofac. J. 29 (1992) 413

Spiessl, B.: Verschiebeosteotomie und Spongiosatransplantation bei extremer Deformierung des Kieferbogens bei Spaltpatienten. In: K. Schuchardt: Fortschr. Kiefer-, Gesichtschir. vol. 16/17, Thieme Stuttgart (1973) 332

Steinhäuser, E.W., A. Gottsauner: Long-term results following primary osteoplasty in cleft lip and palate patients. In: G. Pfeifer: Craniofacial abnormalities and clefts of the lip, alveolus and palate. Thieme, Stuttgart, New York (1991) 374

Stellmach, R.: Von der Idee der primären Osteoplastik bei Lippen-Kiefer-Gaumenspalten zur Realität nach Ablauf eines Jahrzehnts. In: K. Schuchardt: Fortschr. Kiefer-, Gesichtschir. vol. 16/17, Thieme, Stuttgart (1973) 83

Stenström, S.J., B.L. Thilander: Bone grafting in secondary cases of cleft lip and palate. Plast. Reconstr. Surg. 32 (1963) 353

Stoelinga, P.J.W., R.T. Wentgens: Gecombineerde bovenkaak en neuscorrectie bij schisispatiënten. Ned. Tijdschr. Geneesk. 117 (1973) 1604

Stoelinga, P.J.W., H. Tideman, J.S. Berger, H.A. de Koomen: Interpositional bone graft augmentation of the atrophic mandible: a preliminary report. J. Oral Surg. 36 (1978) 30

Stoelinga, P.J.W., H.A. de Koomen, H. Tideman, A.J.M. Huijbers: A reappraisal of the interposed bone graft augmentation of the atrophic mandible. J. Max.-Fac. Surg. 11 (1983) 107

Stoll, P., W. Schilli, U. Joos, I. Jonas, W. Mann: Growth of the facial skeleton in adult patients with unilateral cleft lip and palate following either early or late secondary osteoplasty of the alveolus. In: G. Pfeifer: Craniofacial abnormalities and clefts of the lip, alveolus and palate. Thieme, Stuttgart, New York (1991) 289

Swart: Academisch Proefschrift. Vrije Universiteit Amsterdam, 1984

Troxell, J.B., R.J. Fonseca, D.B. Osbon: A retrospective study of alveolar cleft grafting. J. Oral Maxillofac. Surg. 40 (1982) 721

Turvey, T.A., K. Vig, J. Moriarty, J. Hoke: Delayed bone grafting in the cleft maxilla and palate: A retrospective multidisciplinary analysis. Am. J. Orthod. 86 (1984) 244

Veau, V.: Division palatine; anatomie, chirurgie, phonetique. Masson, Paris 1931

Waite, D.E., R.B. Kersten: Residual alveolar and palate clefts. In: W.H. Bell, W.R. Proffit, R.P. White: Surgical Correction of Dentofacial Deformities, vol. II, Saunders, Philadelphia (1980) 1329

Widmaier, W.: A surgical technique for primary osteoplasty in maxilla and palatal cleft to be applied simultaneously with the closure of the cleft lip. In: K. Schuchardt: Treatment of patients with clefts of lip, alveolus and palate. Thieme, Stuttgart (1966) 59

Witsenburg, B.: The reconstruction of anterior residual bone defects in patients with cleft lip, alveolus and palate. A review. J. Max.-Fac. Surg. 13 (1985) 197

Witsenburg, B., H.P.M. Freihofer: Autogenous rib graft for reconstruction of alveolar bone defects in cleft patients. J. Cranio Max.-Fac. Surg. 18 (1990) 55

Wolfe, S.A., S. Berkowitz: The use of cranial bone grafts in the closure of alveolar and anterior palatal clefts. J. Plast. Reconstr. Surg. 72 (1983) 659

Chapter II

The ectomesenchymal mandibular symphysis bone graft An improvement in alveolar cleft grafting? - a hypothesis -

This chapter is an edited form of an article that has been published in The Cleft Palate Craniofacial Journal 31 (1994) 217-223

Chapter II

The ectomesenchymal mandibular symphysis bone graft
An improvement in alveolar cleft grafting?
- a hypothesis -

II.1. Introduction

Bridging an alveolar defect with a bone graft is essential in the rehabilitation of cleft patients. The advantages of the autologous bone graft in ACR are as follows:

1. After incorporation and maturation the cleft area is filled with vital bone tissue facilitating the development of the maxillary arch.
2. Eruption of adjacent teeth in the former cleft region is made possible.
3. The vital bony tissue reacts to orthodontic forces.
4. The adjacent teeth around the former cleft have sufficient bony support.
5. The adequate closing of oronasal fistulae is facilitated.
6. Reliable support to the nasal framework.

Excellent published review articles by Witsenburg (1985) and Witsenburg and Freihofer (1990) contain almost all relevant references about bone grafting in ACR.
The donor region of primary choice mentioned by many authors is the anterior iliac crest, but some authors use autologous rib grafts for secondary ACR (Witsenburg and Freihofer, 1990).
Other donor sites, like the tibia, cranium or use of homologous and allogenous grafts have been tried, but did not show satisfactory results. The advantages and disadvantages of several donor sites can be seen in table 1.
In the last decade, several reports on the good results of mandibular bone (chinbone in ACR) were published (Bosker and Van Dijk, 1980; Sindet-Pedersen and Enemark, 1988, 1990; Freihofer and Kuijpers-Jagtman, 1989; Koole et al, 1989; Borstlap et al, 1990; Freihofer et al, 1993). Hoppenreijs et al (1992) reported their favorable data on the mandibular donor site in ACR.
Theoretical arguments for using mandibular bone in ACR, apart from such other variables as timing of the procedure, orthodontic procedures, and other technical pre-requisites, are based on relevant data concerning the following fields of study:

1. In embryology, the development of facial bones and origin of the ectomesenchym.
2. In bone graft physiology, comparison of membranous bone and endochondral bone grafts.
3. In the clinical practice of mandibular bone grafting (other than in ACR) in oral and maxillofacial surgery.

graft origin	*iliac crest bone*	*rib bone*	*tibia bone*	*calvarium bone*	*homologous bone*	*allogenic material (HA)*	*mandibular symphysis bone*
delay in ambulation	*7 days*	*1 day*	*14 days*	*3 days*	*0 days*	*0 days*	*0 days*
operation areas	*2*	*2*	*2*	*2*	*1*	*1*	*1*
specific morbidity and complications	*gait disturbances meralgia bowel hernia*	*disturbed respiration pneumothorax*	*gait disturbances shortening of the leg*	*meningitis subdural haematoma dura tear*	*–*	*–*	*apical trauma endodontic alterations*
amount of bone	*considerable*	*ample*	*ample*	*ample*	*unlimited*	*unlimited*	*limited*
scar donor defect	*visible palpable*	*visible*	*visible palpable*	*visible when hairloss*	*–*	*–*	*invisible*
miscellanea	*sometimes considerable bloodloss, need transfusion*	*–*	*obsolete (?)*	*psychological reluctance*	*virus transmission*	*corpus alienum reaction (giant cells)*	*haematoma in floor of the mouth*
tooth-eruption	*sometimes enlarged dental follicle*	*sometimes enlarged dental follicle*	*no special reports on dental follicle*	*possible*	*delayed*	*impossible*	*sometimes enlarged dental follicle*
commencement orthodontic treatment	*>12 weeks*	*>26 weeks*	*>12 weeks*	*>12 weeks*	*delayed*	*impossible*	*12 weeks*

This table is a compilation of our own clinical experience, plus data found in the literature reviewed for this article.

Table 1: *some advantages and disadvantages of different donor sites.*

II.2. Embryology

In craniofacial embryology, it is accepted that the neural crest cells play a major role in the development of the dental germs (Kollar and Baird, 1970[a,b]; Ten Cate, 1975[a,b]; Slavkin et al, 1988) and craniofacial skeleton *including* the mandible and maxilla, but also in the development of the muscles and the soft tissues of the face (Le Lièvre and Le Douarin, 1975; Hall, 1980, 1987, 1990; Noden, 1980; Been, 1987; Slavkin, 1990). Neural crest cells produce the embryological precursors of chondroblasts, fibroblasts, osteoblasts, and odontoblasts (Hall, 1984, 1987).

The neural crest is a population of embryologic cells referred to as neurectoderm which can be identified in the period when the neural crest closes to form the neural tube (in amphibians and fowl), or just prior to this stage in mammals (higher verte-brates). The precursors of the neural crest cells are identified in the embryonic chicken at an age of 12 hours when it is merely visible as a blastodisc (Hall, 1981). These precursors are moving in a medial direction, where they maintain a position between the lateral neural and epi-

dermal ectoderm (Noden, 1978; Le Douarin, 1982; Hall, 1987). When the neural tube develops, the neural crest cells migrate to the cranium (and the vertebral column). As this migration of the neural crest cells takes place along the basal lamina of the epithelium and along extracellular spaces created by enzymes (Hall, 1981; Slavkin et al, 1988), the folding of the embryo takes place in two different directions. In this way, the more familiar human embryo develops (Vermey-Keers, 1990; Sperber, 1992). Further cell migrations do not take place after this stage. In the craniofacial region, these neural crest cells differentiate to mesenchym. This mesenchym with its peculiar origin is called ectomesenchym, the 4th germlayer (Ten Cate, 1982), or, alternatively, mesectoderm (Van de Velde, 1987). The differentiation of this ectomesenchym into osteoblasts takes place after exposure to an embryonic epithelium (epithelial-ectomesenchymal interaction). Studies on this interaction of epithelium and ectomesenchym leading to the formation of the membranous bone of mandible and maxilla are by Le Lièvre and Le Douarin, 1975; Hall, 1980, 1984; Noden, 1980; Tyler and McCobb, 1980; Ten Cate, 1982; Hall and Van Exan, 1982; Tsuzuki and Kitamura, 1985).

In conclusion, mandibular epithelium induces ectomesenchymal bone formation by action of its basal lamina and in a stricter sense of its extracellular matrix (Hall, 1987; Slavkin, 1990).

Boyne and Scheer (1991) investigated the possibility of obtaining bone induction by the use of epithelium of a developing tooth. This experiment shows the epithelial-ectomesenchym interaction in postnatal life. An artificial cleft in a growing baboon (Papio anubis) was grafted on one side, with a diced tooth bud of the 2nd and the 3rd molar, (mainly soft tissue). Contralaterally, the oronasal fistula was closed by local soft tissue only. After 6 months the grafted osseous defects had completely closed by bone formation. The contralateral control side was filled in with fibrous tissue. The epithelial-ectomesenchym interaction in this experiment may thus have been demonstrated. Boyne has his doubts, he states however: "that it is the epithelial elements which have been responsible for the results demonstrated". On the other hand, it must be said that the epithelial-ectomesenchym interaction, leading to the formation of bone, matches with the embryologic research on craniofacial bone formation.

II.3. Bone graft physiology

It is beyond the scope of this chapter to go through all details of bone graft physiology. Much research deals with the remodelling dynamics in bone transplantation (Urist, 1953; Axhausen, 1956; Obwegeser, 1958, 1967; Frost, 1963; Burwell, 1966; Burchardt and Enneking, 1978; Marx et al, 1984; Ermis and Poole, 1992). The major points of interest are as follows:

1. Survival of the bonegraft.
2. Revascularization of the graft.

When the initial phase of the bone graft physiology is completed, other major points of

interest are extensively investigated:

3. Maintenance of transplanted volume.
4. Functional loading of the graft.

The following two points, are part of this investigation:

5. Quality of the bone graft.
6. Origin of the bone graft.

The debate in craniofacial literature, on endochondral bone versus membranous bone grafts, is interesting with respect to the first four topics in bonegrafting research (Smith and Abramson, 1974; Zins and Whitaker, 1983; Kusiak et al, 1985; Wilkes et al, 1985; Dado and Izquierdo, 1989; Hardesty and Marsh, 1990).
Some remarks concerning the mandibular symphysis bone graft can be made.

II.3.1. Survival of the bone graft

The largest number of surviving cells is located near the surface of the graft (survival by diffusion) (Axhausen, 1956; Adams, 1976; Marx, 1984).
Bartlett and Whitaker (1989) made the same observation in an experimental study on the storage of a bone graft and concluded that the duration of the extracorporeal time should be minimized. In using ectomesenchym (chin bone) grafts, the extracorporeal time is short, and the survival of the superficial bone graft cells optimal. This can also be realized in *distant* grafting procedures, but organization is complicated because of sterility problems.

II.3.2. Revascularization and volume maintenance

Since the mandible is mainly formed by intramembranous ossification, the problem of endochondral versus membranous bone grafts applies for the mandibular graft (symphysial or lateral). A short review of the data is presented for a clearer understanding of the issue.
Smith and Abramson (1974) showed, in grafting membranous bone (cranium) as an onlay on the nasal dorsum of a rabbit, that no significant resorption took place after one year. The control iliac crest graft resorbed in one year up to over 75% of its original total volume. The explanation for this phenomenon was thought to be the morphology of the cranial bone, that is, two layers of cortex and diploë, giving rise to delayed revascularization. Incorporation and remodelling, therefore, occurred in a much slower way than with the iliac crest graft. Zins and Whitaker (1983) and Kusiak et al (1985) took an opposite view. They showed that after 3 hours, there were more vessel buds in the membranous bone graft than in the endochondral iliac crest graft and, within 3 days, more vessels penetrated membranous bone grafts than iliac crest grafts. Even after 14 and 21 days, no vascularization was visible centrally in the endochondral bone graft. In the membranous bone graft, there was central revascularization after 7 days. They, therefore, concluded that graft resorption is inversely proportional to vascularization. It seems that the iliac

crest graft in both experiments was resorbed to a greater extent than the membranous bone graft.

Fasano et al (1989) made an interesting observation in the growing rabbit facial skeleton: membranous onlay bone grafts on the depositing bone surfaces (nasal snout) maintained volume and morphology significantly better than an onlay graft on a resorptive field (vestibular surface of the mandibular ramus). Alberius and Johnell (1991) and Isaksson and Alberius (1992) showed, in their experimental study in rats, that in artificial defects and experimental fractures in membranous bone, the re-establishment of the vascular supply represents the initial stage of repair and was seen as early as three days, postoperatively. The osteogenesis is critically dependent on the revascularization of the grafted area. The other phenomena in the initial stage, resorption of necrotic tissue, differentiation, and proliferation of the osteogenic cells are highly dependant on the revascularization. Alberius and Johnell (1991) noticed: rapid regenerative response, leading to direct formation of membranous bone with early revascularization.

From the literature the following conclusions are drawn:

1. The rapid revascularization of the bone graft determines the maintenance of the transplant (Zins and Whitaker, 1979, 1983; Kusiak et al, 1985; Fasano et al, 1989).
2. The revascularization proceeds faster in cortical membranous bone than in endochondral cortical bone (Kusiak et al, 1985; Alberius and Johnell, 1991).

The observed phenomenon, that is, the rapid angiogenesis in the membranous bone, could be explained by a variety of factors: the presence of humoral factors as shown by Eppley et al (1988), the differences in diffusion in the particular region, the more traditional peripheral mechanisms like O_2-gradient, pH-changes and metabolic products. The architecture of the grafted bone was mentioned as a possible factor of influence on the vascular ingrowth. Several authors (Glowacki, 1985, 1990; Hardesty and Marsh, 1990; Ermis and Poole, 1992) agree on the following statements:

1. The different types of bone must be considered in a histomorphometrical way to explain the revascularization differences (the difference in the ratio of trabecular/cortical bone).
2. The explanation of the observed phenomena, must also be studied in respect to histochemic and biochemic differences between the two types of bone (endochondral-membranous). Glowacki (1985) stated also in accordance with Glimsher et al (1980), that osteoblasts in long bones can be different from osteoblasts in membranous bone, because hydroxylating products of collagen lysil residue in membranous bone differ significantly from those in endochondral bone.
3. Further studies must be carried out to observe bone graft resorption in relation to embryonic origin, standardizing the experimental conditions.

II.3.3. Functional loading

As long as the load remains qualitatively similar throughout a certain period, the remodeling or reconstitution of the bone that occurs during that period maintains the internal and external shape and orientation of the bone elements. A change in load is followed in time by a change in the internal and external architecture of the bone (graft) of such form and degree that maximum resistance to the new physical load results. This is Wolff's law and cannot differ essentially for ectomesenchymal bone. After incorporation, the bone graft maintains volume due to functional stress and absence of movement. There will be no great difference between grafts of different origin (Phillips and Rahn, 1988; La Trenta et al, 1989).

In the maxillo mandibular skeleton, however, the effects of non-loading are well-known, e.g., in case of anodontia there will be no alveolar process (Vermeiden, 1987). The atrophy of the alveolar process in the edentulous mandible or maxilla is familiar to every dentist (Thoma, 1966). The presence of teeth clearly acts as a functional stimulus and functional loading is remarkably effective in the treatment of secondary retention of molars: after removal of a secondary retained molar, the adjacent molar, after orthodontic treatment, reconstitutes a normal alveolar process (Rhagoebar, 1991). This is of relevance for the results of ACR and the final objectives of the treatment to obtain an uninterrupted dental arch.

The difference in the architecture of the grafted bone of different origins and the effect in remodelling after incorporation of the graft must be considered. The mandibular graft, in its less ectopic ectomesenchym acceptor region, may respond in another way and degree to the new mechanical forces, such that the architecture adapts more to the environment than do the various mesenchym grafts in their ectopic ectomesenchymal acceptor region. This, as yet, is our working hypothesis with respect to the points of interest 5. and 6. mentioned above.

II.4. Mandibular bone grafts in oral and maxillofacial surgery

In oro-maxillofacial (OMF) surgery, the mandibular bone graft has been used in the following fields for reconstruction of defects:

1. Traumatology
2. Preprosthetic surgery
3. Orthognathic surgery and reconstructive maxillofacial surgery.

Although not related to ACR, the results of these different bone graft procedures were encouraging and therefore, contribute to the choice of mandibular bone for ACR.

II.4.1. Traumatology

In the case reports published on traumatology, the region of the mandibular symphysis is

	number of treated patients	*type of fractures*	*result(s)*	*graft from the mandible*
Peters 1969	*6*	*nonunion mandible midline/corpus*	*good*	*inferior ramus sliding symphysis*
Szmyd et al 1969	*1*	*nonunion mandible corpus*	*good*	*anterior ramus*
Kline et al 1970	*1*	*delayed union of the mandible corpus*	*good*	*symphysis*
Aslanian et al 1971	*1*	*malunion of the maxilla*	*good*	*symphysis*
Merkx 1975	*14*	*nonunion mandible corpus*	*good*	*inferior sliding ramus*
Laskin et al 1977	*1*	*orbital floor*	*good*	*symphysis*
Bagatin et al 1987	*6* *1* *3*	*orbital floor* *upper orbital rim* *depressed zygomatic bone*	*good*	*symphysis*
Girdler and Hosseini 1992	*12*	*orbital floor*	*good*	*symphysis and mandibular lingual cortex*

Table 2: *Use of mandibular bone graft in oromaxillofacial traumatology case reports*

a favourite donor site.

Peters (1969) used a sliding cortical mandibular graft for reconstruction of malunited fractures. Szmyd and Morgan (1969) used the anterior ramus as a graft for a mandibular defect fracture. Kline et al (1970) used mandibular symphysis bone for the treatment of a delayed union of a mandibular fracture. Aslanian et al (1971) reported on a mandibular bone graft for revision of a malunion of the maxilla. Later in 1977, Laskin and Edwards reported on a mandibular bone graft obtained from the buccal side of the third molar region in reconstructing an orbital floor defect. More recently, Bagatin (1987) reported on mandibular symphysis bone grafts in the reconstruction of orbit defects. Girdler and Hosseini (1992) reported on orbit floor reconstruction with autologous bone harvested from the mandibular lingual cortex. Roche and Schwartz (1993) reported good results of the mandibular body bone (MBB) graft. The results, by different authors, are summarized in table 2.

II.4.2. Preprosthetic surgery

Iliac crest grafts and ribgrafts are widely used for preprosthetic surgery. One of the first reports on the use of mandibular symphysis bone in this field was by Hofer and Mehnert in 1964. They suggested more indications for the use of this graft e.g. in traumatology, oncology, and cleft surgery.

II.4.3. Orthognathic and reconstructive surgery

Köle (1959) used the lower anterior mandibular border as a bone graft for bridging the defect after cranialization of the lower segment in anterior open bite surgery. Meyer (1972), reported on mandibular symphysis as a donor site in bonegrafting for a different surgical correction of an anterior open bite. In a review article on cleft lip and palate surgery, Neuner (1965), stated that in case of missing anterior teeth, the cleft alveolus and palate can be bone grafted with mandibular symphysis bone for the augmentation of the atrophic maxilla and closing of the oronasal fistulae. Braun and Sotereanos (1984) demonstrated the use of autogenous regional bone and advocated the use of regional bone that is anatomically, functionally and developmentally similar. Bosker and Van Dijk (1980), for the first time in Dutch literature, mentioned the use of mandibular symphysis bone for ACR. They started mandibular bone grafting for ACR in 1976. The results of these authors, and others, will be discussed in chapter V.

II.5. Discussion

Some remarks, must be made on the interacting aspects of embryology and osteogenesis. During the development of the mandible in embryonic life, Meckel's cartilage resorbs and is replaced by membranous ectomesenchym bone. The anterior lower border of the mandible, however, is formed by endochondral ectomesenchym ossification. The mandibular symphysis graft is, therefore, not intended to be extended to the lower border of the mandible and is chosen in the part that is developed by membranous ossification.

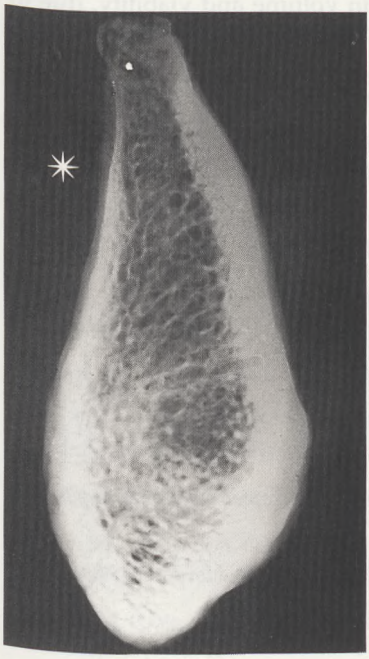

Kloosterman (1985) showed, in a follow-up study of 44 patients, that the chin prominence (lower border part), bridging the defect in the majority of segmental (Köle) osteotomies, incorporated very well. This latter study concludes that ectomesenchym mandibular bone of the endochondral lower border, from a clinical and radiologic point of view, is a reliable graft and, therefore, its membranous formation should not be overemphasized.

Most authors remark on the mainly cortic composition of the mandibular bone graft. Nevertheless, it appears to be clinically and radiographically favorable. The explanation may be the embryologic similarity and because the density of this cortic bone is definitely reduced in comparison to other parts of the mandible. This is demonstrated by the excellent penetration of locally injected anesthetic solutions (fig. 7).

Figure 7. *Relatively porous architecture of labial bone in donor area. * Vestibular side.*

During the eruption of the lateral incisor or cuspid into the ectomesenchym-bone-grafted cleft, the epithelial Malassezs' remnants in the periodontal ligament, interact with the ectomesenchym bonegraft, leading to a firm alveolar process (Sperber, 1973; Ten Cate, 1975[b]; Van de Velde, 1987). The establishment of a functional periodont ligament and the formation of a healthy sulcus is highly dependent of this epithelial remnant. The tooth, primarily an ectodermal derivate, can in grafted ectomesenchymal bone make use of this usual interaction.
Other bone grafts, e.g., calvarial or from endochondral bones, also can make use of these Malassez's remnants, but this interaction has not yet been described. Furthermore, if we review the anatomical relationships seen throughout the body, nowhere else epithelium is in direct contact with bone. Mostly, a buffer zone of fibrous connective tissue is between them.

II.6. Conclusion

Obviously, in maxillofacial surgery it is not new to use mandibular bone grafts. However, the use for ACR is, up till now, limited. The ectomesenchym bone graft from the mandibular symphysis has theoretic, but also practical, advantages as a grafting material, especially for ACR. Clinical studies, as well as animal experiments, so far seem to support this view based on the following features:

- the similarity in embryological origin (first branchial arch)
- the indication that membranous bone grafts maintain volume and viability, due to early vascularization
- good results obtained in other areas of maxillofacial surgery, with mandibular (symphysis) bone grafts.

References

Adams, C.: Outline of Orthopedics. London and New York: Churchill Livingstone Ed. (1976) 29

Alberius, P., O. Johnell: Repair of intra-membranous bone fractures and defects in rats. Immunolocalization of bone and cartilage proteins and proteoglycans. J. Cranio-Max.-Fac. Surg 19 (1991) 15

Aslanian, R.A., J.A. Wright, W.P. Marco, M.H. Goldberg: Use of mandibular bone for revision of malunion of the maxilla: report of case. J. Oral Surg. 29 (1971) 825

Axhausen, W.: The osteogenetic phases of regeneration of bone. A histological and experimental study. J. Bone Joint Surg. 38A (1956) 593

Bagatin, M.: Reconstruction of orbital defects with autogenous bone from mandibular symphysis. J. Cranio-Max.-Fac. Surg. 15 (1987) 103

Bartlett, S.P., L.A. Whitaker: Growth and survival of vascularized and nonvascularized membranous bone: An experimental study. Plast. Reconstr. Surg. 85 (1989) 783

Been, W.: Mediane facio-cerebrale misvormingen. Thesis University of Amsterdam. Amsterdam: Rodopi 1987

Borstlap, W.A., K.L.W.M. Heidbuchel, H.P.M. Freihofer, A.M. Kuijpers-Jagtman: Early secondary bone grafting of alveolar cleft defects. A comparison between chin and rib grafts. J. Cranio-Max.-Fac. Surg. 18 (1990) 201

Bosker, H., L. van Dijk : Het bottransplantaat uit de mandibula voor herstel van de gnatho-palatoschisis. Ned. Tijdschr. Tandheelk. 87 (1980) 383

Boyne, P.J., P.M. Scheer: Stimulation of bone induction by odontogenic epithelium in the treatment of alveolar clefts. In: Pfeifer, G.: Craniofacial abnormalities and clefts of the lip, alveolus and palate. 4th Hamburg International Symposium. (1991) 171

Braun, T.W., G.C. Sotereanos: Autogenous regional bone grafting as an adjunct in orthognathic surgery. J. Oral Max.-Fac. Surg. 42 (1984) 43

Burchardt, H., W. Enneking: Transplantation of bone. Surg. Clin. North Am. 58 (1978) 403

Burwell, R.G.: Studies in the transplantation of bone. VIII. Treated composite homograft-autografts of cancellous bone: an analysis of inductive mechanisms in bone transplantation. J. Bone Joint Surg. 48B (1966) 532

Ten Cate, A.R.: Development of the periodontal membrane and collagen turn over. In: The eruption and occlusion of teeth editered by Poole DFG and Stack MV Buttersworths, London: Colston papers 27 (1975[a]) 182

Ten Cate, A.R.: Formation of supporting bone in association with periodontal ligament organization in the mouse. Arch. Oral Biol. 20 (1975[b]) 137

Ten Cate, A.R.: Development of the dentofacial complex. Dent. Clin. North Am. 3 (1982) 445

Dado, D.V., R. Izquierdo: Absorption of onlay bone grafts in immature rabbits: Membranous versus endochondral bone and bone struts versus paste. Ann. Plast. Surg. 23 (1989) 39

Le Douarin, N.M.: The neural crest. London: Cambridge University Press 1982

Eppley, B.L., M. Doucet, D.T. Connolly, J. Feder: Enhancement of angiogenesis by bFGF in mandibular bone graft healing in the rabbit. J. Oral Max.-fac. Surg. 46 (1988) 391

Ermis, I., M. Poole: The effects of soft tissue coverage on bone graft resorption in the craniofacial region. Br. J. Plast. Surg. 45 (1992) 26

Fasano, D., G. Gasparini, V. Menoni, F. Bertoni, P. Bacchini: The fate of onlay membranous bone grafts in different facial recipient sites. Europ. J. Plast. Surg. 12 (1989) 160

Freihofer, H.P.M., A.M. Kuijpers-Jagtman: Early secondary osteoplastic closure of the residual alveolar cleft in combination with orthodontic treatment. Suppl. J. Cranio-Max.-Fac. Surg. 17 (1989) 26

Freihofer, H.P.M., W.A. Borstlap, A.M. Kuijpers-Jagtman, R.A.C.A. Voorsmit, P.A. van Damme, L.W.M. Heidbüchel, V.M.F. Borstlap-Engels: Timing and transplant materials for closure of alveolar clefts. A clinical comparison of 296 cases. J. Cranio-Max.-Fac. Surg. 21 (1993) 143

Frost, H.M.: Bone remodelling dynamics. Springfield, Illinois, USA: Charles C. Thomas publisher 1963

Girdler, N.M., M. Hosseini: Orbital floor reconstruction with autogenous bone harvested from the mandibular lingual cortex. Br. J. Oral Max.-Fac. Surg. 30 (1992) 36

Glimcher, M.J., F. Shapiro, R.D. Ellis, R. Eyre: Changes in tissue morphology and collagen composition during the repair of cortical bone in an adult chicken. J. Bone Joint Surg. 62A (1980) 964

Glowacki, J.: Discussion. In: Kusiak, J.F., J.E. Zins, L.A. Whitaker (eds). The early revascularization of membranous bone. Plast. Reconstr. Surg. 76 (1985) 515

Glowacki, J.: Discussion: Hardesty R.A., J.L. Marsh: Craniofacial onlay bone grafting: a prospective evaluation of graft morphology, orientation, and embryonic origin. Plast. Reconstr. Surg. 85 (1990) 15

Hall, B.K.: Tissue interactions and the initiation of osteogenesis and chondrogenesis in the neural crest derived mandibular skeleton of the embryonic mouse as seen in isolated murine tissues and in recombinations of murine and avian tissues. J. Embryol. Exp. Morphol. 58 (1980) 251

Hall, B.K.: The induction of neural crest-derived cartilage and bone by embryonic epithelia: an analysis of the mode of action of an epithelial-mesenchymal interaction. J. Embryol. Exp. Morphol. 64 (1981) 305

Hall, B.K.: Genetic and epigenetic control of connective tissues in the craniofacial structures. Birth Defects: Original Article Series 20 (1984) 1

Hall, B.K.: Earliest evidence of cartilage and bone development in embryonic life. Clin. Orthop. Rel. Res. 225 (1987) 255

Hall, B.K.: Evolutionary issues in craniofacial biology. Cleft. Palate J. 27 (1990) 95

Hall, B.K., R.J. van Exan: Induction of bone by epithelial cell products. J. Embryol. Exp. Morphol. 69 (1982) 37

Hardesty, R.A., J.L. Marsh: Craniofacial onlay bone grafting: A prospective evaluation of graft morphology, orientation, and embryonic origin. Plast. Reconstr. Surg. 85 (1990) 5

Hofer, O., H. Mehnert: Eine neue Methode zur Rekonstruktion des Alveolarkammes. Dtsch. Zahn- Mund- und Kieferheilk. 41 (1964) 353

Hoppenreijs, T.J.M., E.S. Nijdam, H.P.M. Freihofer: The chin as a donor site in early secondary osteoplasty: a retrospective clinical and radiological evaluation. J. Cranio-Max.-Fac. Surg. 20 (1992) 119

Isaksson, S., P. Alberius. Comparison of regenerative capacity elicited by demineralized bone matrix of different embryonic origins. J. Cranio-Max.-Fac. Surg. 20 (1992) 73

Kline, S.N., D.R. Shensa, M.R. Kahn: Use of autogenous bone fom the symphysis for treatment of delayed union of the mandible: report of case. J. Oral Surg. 28 (1970) 540

Kloosterman, J.: Köle's osteotomy, a follow-up study. J. Max.- Fac. Surg. 13 (1985) 59

Köle, H.: Formen des Offenen Bisses und ihre chirurgische Behandlung. Dtsch. Stomat. 9 (1959) 753

Kollar, E.J., G.R. Baird: Tissue interactions in embryonic mouse tooth germs. I. Reorganization of the dental epithelium during tooth-germ reconstruction. J. Embryol. Exp. Morphol. 24 (1970a) 159

Kollar, E.J., G.R. Baird: Tissue interactions in embryonic mouse tooth germs. II. The inductive role of the dental papilla. J. Embryol. Exp. Morphol. 24 (1970b) 173

Koole, R., H. Bosker, F. Noorman van der Dussen: Late secondary autogenous bone grafting in cleft patients comparing mandibular (ectomesenchymal) and iliac crest (mesenchymal) grafts. Suppl. J. Cranio-Max.-Fac. Surg. 17 (1989) 28

Koole, R., W.J. Visser, W.R. Klein, A.M.H. Suiker: A Comparative investigation on autologous mandibular and iliac crest bone grafts. An experimental study in sheep. J. Cranio-Max.Fac. Surg. 19 (1991) 133

Kusiak, J.F., J.E. Zins, L.A. Whitaker: The early revascularization of membranous bone. Plast. Reconstr. Surg. 76 (1985) 510

Laskin, J.L., D.M. Edwards: Immediate reconstruction of an orbital complex fracture with autogenous mandibular bone. J. Oral Surg. 35 (1977) 749

Le Lièvre, C.S., N.M. Le Douarin: Mesenchymal derivates of the neural crest: Analysis of chimeric quail and chick embryos. J. Embryol. Exp. Morphol. 34 (1975) 125

Marx, R.E., R.I. Miller, W.J. Ehler, G. Hubbard, T.I. Malini: A comparison of particulate allogeneic and particulate autogenous bone grafts into maxillary alveolar clefts in dogs. J. Oral Max.-Fac. Surg. 42 (1984) 3

Merkx, C.A.: Verschiebeosteoplastik bei Pseudarthrose des Corpus Mandibulae. In: Fortschritte der Kiefer- und Gesichts-Chirurgie. Band XIX. Die operatieve Behandlung der Verletzungen des Gesichtsschädels. Georg Thieme Verlag, Stuttgart (1975) 125

Meyer, R.A.: Mandibular symphysis as donor site in bone grafting for surgical correction of open bite: report of case. J. Oral Surg. 30 (1972) 125

Neuner, O.: Sekundäre Korrekturmöglichkeiten bei Lippen-Kiefer-Gaumenspalt-Patienten. Öst. Z. Stomat. 62 (1965) 268

Noden, D.M.: The control of avian cephalic neural crest cyto differentiation. I. Skeletal and connective tissue. Dev. Biol. 67 (1978) 296

Noden, D.M.: The migration and cytodifferentiation of cranial neural crest cells. In: Pratt RM, Christiansen RL (eds.) Current research trends in prenatal craniofacial development. New York: Elsevier North Holland (1980) 3

Obwegeser, H.: Co-report: surgical preparation of the mouth for full dentures. Int. Dent. J. 8 (1958) 252

Obwegeser, H.: Weitere Erfahrungen mit der aufbauenden Kammplastik. Schweiz. Monatsschr. Zahnheilk. 77 (1967) 1002

Peters, P.B.: Sliding cortical mandibular grafts. J. Oral Surg. 27 (1969) 565

Phillips, J.H., B. Rahn: Fixation effects on membranous and endo-chondral onlay bone graft resorption. Plast. Reconstr. Surg. 82 (1988) 872

Rhagoebar, G.M.: Secondary retention of molars. Thesis, University of Groningen, Groningen: Van Denderen 1991

Roche, Y.A., H.C. Schwartz: The mandibular body bone (MBB) graft: an alternative source of membranous bone. J. Cranio-Max.-Fac. Surg. 21 (1993) 199

Sindet-Pedersen, S., H. Enemark: Mandibular bone grafts for reconstruction of alveolar clefts. J. Oral Max.-Fac. Surg. 46 (1988) 533

Sindet-Pedersen, S., H. Enemark: Reconstruction of alveolar clefts with mandibular or iliac crest bone grafts. A comparative study. J. Oral Max.-Fac. Surg. 48 (1990) 554

Slavkin, H.C.: Regulatory issues during early craniofacial development: A summary. Cleft Palate J. 27 (1990) 101

Slavkin, H.C., M. MacDougall, M. Zeichner-David, P. Oliver, M. Nakamura, M.L. Snead: Molecular determinants of cranial neural crest-derived odontogenic ectomesenchyme during dentinogenesis. Am. J. Med. Gen. 4 (1988) 7

Smith, J.D., M. Abramson: Membranous vs endochondral bone autografts. Arch. Otolaryng. 99 (1974) 203

Sperber, G.H.: Craniofacial embryology. Dental Practitioner Handbook No. 15. Bristol: John Wright & Sons Limited 1973

Sperber G.H.: First year of life: prenatal craniofacial development. Cleft Palate-Craniofac. J. 29 (1992) 109

Szmyd, L., H.H. Morgan: Anterior ramus graft of the mandible: report of case. J. Oral Surg. 27 (1969) 132

Thoma, K.H.: Oral Surgery. Volume two. Saint Louis: The C.V. Mosby Company, 1966

La Trenta, G.S., J.G. McCarthy, A.S. Breitbart, M. May, H.A. Sissons: The role of rigid skeletal fixation in bone graft augmentation of the craniofacial skeleton. Plast. Reconstr. Surg. 84 (1989) 578

Tsuzuki, H., H. Kitamura: Epithelial-Mesenchymal Interface in the Rat Mandibular Process Observed by Electron Microscopy. Arch. Histol. Jap. 48 (1985) 223

Tyler, M.S., D.P. McCobb: The genesis of membrane bone in the embryonic chick maxilla: epithelial-mesenchymal tissue recombination studies. J. Embryol. Exp. Morphol. 56 (1980) 269

Urist, M.R.: Physiologic basis of bone graft surgery with special reference to the theory of induction. Clin. Orthop. 1 (1953) 207

Van de Velde, J.P.: De ontwikkeling van het tand-kaakstelsel ontogenie en fylogenie. Tandheelkundige Scholing en Nascholing deel II. Alphen a/d Rijn: Samsom Stafleu 1987

Vermeiden, J.P.W.: In: Van de Velde JP. De ontwikkeling van het tand-kaakstelsel: ontogenie en fylogenie. Alphen a/d Rijn: Samsom Stafleu 1987

Vermey-Keers, C.: Craniofacial embryology and morphogenesis: normal and abnormal. In Craniofacial Malformations ed.: M. Stricker, J. vd Meulen, B. Raphael, R. Mazzoka. Churchill Livingstone. Edinburg 3 (1990) 27

Wilkes, G.H., D.A. Kernahan, M. Christenson: The long-term survival of onlay bone grafts - A comparative study in mature and immature animals. Ann. Plast. Surg. 15 (1985) 374

Witsenburg, B.: The reconstruction of anterior residual bone defects in patients with cleft lip, alveolus and palate. A review. J. Max.-Fac. Surg. 13 (1985) 197

Witsenburg, B., H.P.M. Freihofer: Autogenous rib graft for reconstruction of alveolar bone defects in cleft patients. J. Cranio-Max.-Fac. Surg. 18 (1990) 55

Zins, J.E., L.A. Whitaker: Membranous versus endochondral bone: Implications for craniofacial reconstruction. Plast. Reconstr. Surg. 72 (1983) 778

Chapter III

Material and Methods

Chapter III
Material and Methods

III.1. Introduction

The hypothesis formulated in chapter II, was investigated in an animal experiment and in a retrospective clinical and radiological investigation of three groups of patients.
The latter is described in the chapters V, VI and VII the former in chapter IV.
In chapter VIII a statistical analysis of the results of the investigation reported in chapters V and VI is presented.

III.2. Material

III.2.1. Patients

The follow-up investigation comprises 3 groups of patients from the following sources.
In the Utrecht University clinic for maxillofacial surgery the ACR with the secondary bone grafting technique with iliac crest grafts was introduced in 1972. Age of the patients: about 9 to 17.5 years. Part of these patients are described in chapter VI.
At the same time, the Le Fort I osteotomy for adolescent and adult cleft patients was introduced and thus also the reopening of the cleft in severe cases of malformation. In order to obtain a dental arch in the maxilla more or less congruent to the mandibular one, besides ventralization also considerable expansion was often necessary, requiring closure of the wide gap and bone grafting (always done with iliac crest grafts and at a later date), i.e. tertiary alveolar cleft repair (TACR) by bone grafting (Koole, 1990). After this second operation the gap in the dental arch was usually bridged prosthetically (fig. 5). Nowadays also orthodontics is possible (fig. 4). This group of patients is described in chapter VII.
The third group of patients was operated in Groningen by Drs Bosker and Van Dijk, who started doing ACR using bone grafts from the chin region in 1976 also in patients between about 9-17.5 years. This group of patients is described in chapter V.
The two ACR groups from Utrecht and Groningen can be matched as far as age and orthodontics is concerned, but differ as to the source of the grafted bone.
The TACR group differed as to age as well as to pre- and postoperative treatment.
Summarizing, there are three groups of patients described in this thesis:

a. cleft patients from Groningen, ACR, chin bone;
b. cleft patients from Utrecht, ACR, iliac crest bone;
c. cleft patients from Utrecht, TACR, iliac crest bone.

III.2.2. Animal experiment

An animal experiment, conducted in sheep, in which mandibular bone and iliac crest bone were compared by insertion in artificial clefts. The particulars can be found in chapter IV to which the reader is referred.

III.3. Methods

In this chapter the methods are described which were used to analyze the results in the three groups of patients. Apart from the clinical and radiological investigation of cleft area and donor site, also the files were scrutinized for data which might be relevant for the end result.

All patients in the three groups were subjected to the same investigation by one and the same examiner.

III.3.1. Clinical examination

After explaining the aim of the investigation to the patient and obtaining her/his permission for processing the data the following parameters were examined.

1. Eruption of the cuspids in the bone grafted former cleft area.
2. Periodontal condition of
   a. teeth around the former cleft - cleft adjacent teeth (CAT)
   b. a number of non cleft-related teeth in the upper jaw.
   I.e. the teeth 14 to 24 were all examined on
   - probing depth (PD), mesiofacial and distofacial aspect;
   - bleeding on probing (BOP), here the classification was 0, +, ++
   - tooth mobility;
     This was expressed on a scale from 1 to 4:
     1= physiological mobility
     2= mobility slightly increased - 1 to 2mm in a bucco-lingual direction
     3= increased mobility - more than 2mm bucco-lingually
     4= vertical mobility
   - width attached gingiva;
   - colour of gingiva;
   - possible cervical resorption of CAT
3. The morphology of the alveolar process in the former cleft region was examined by palpation and classified as concave or normal. Special attention was given to scar tissue perpendicular to the alveolar process. The status of the vestibular sulcus was registered as physiological, reduced (shallow) or scarred.
4. The orthodontic condition was studied with emphasis on the situation around the uninterrupted dental arch in the reconstructed alveolar process.
   Dental casts were made of all Utrecht patients; in the Groningen group of patients this was also done in most patients, except in those where no orthodontic anomalies were seen. The treatment objectives registered were:
   - the sagittal relation of front teeth
   - the vertical relation of front teeth
   - the presence of a cross-bite
   - the angulation (paralleling) of the CAT was observed on the dental casts and on the

semi-standardized occlusal X-ray. A division in three groups was made: angulation over 45°, beween 30°-45° and less than 30° (Turvey et al, 1984). It was examined to see whether a relation existed with the ABR.

- molar relation

In case of prosthetic correction the presence of a removable or fixed appliance was noted.

5. Presence of an oro-nasal fistula was established by inspection, asking the patient to blow up his cheeks and listening for escape of air. Of course the patient was asked whether there was leakage of liquids and/or air escape.
6. Examination of the donor region. In the Groningen group vitality of the lower front teeth was tested faradically, with hot and cold stimuli and percussion. The scar in the vestibular sulcus was judged and its possible sequelae.

   In the two Utrecht groups the scar and skin sensitivity were examined and the iliac crest was palpated for irregularities.

III.3.2. Radiographic examination of the cleft site

In all patients an orthopantomogram (X-OPT) and a semi-standardized occlusal X-ray (Van Hoeken, 1983) was taken.

The latter was made as follows:

The AGFA 6x8cm X-ray film was inserted into the patient's mouth such that the short side was parallel to an imaginary tangent to the cleft.

Then the head of the patient was rotated until this short side of the film was parallel to an imaginary perpendicular onto the patient's axis c.q. the axis of the dental chair.

The X-ray tube was then placed in such a way infra-orbitally that exposure according the bissector rule became possible.

The X-ray apparatus used always was a Philips Dens-o-mat ZD46 (65 KV-7.5mA) which produces high quality photographs if due attention is paid to proper selection of the variables on the switch board. Since film, apparatus and exposure direction were reasonably well defined, we thought the term "semi-standardized" appropriate. These X-rays were used to detect root resorption and for measurements described in III 3.2.1.

They were also used to designate the width of the alveolar cleft with the distances of the alveolar process parts, projecting furthest into the cleft, as measuring points.

Classification: narrow - distance < 4 mm
normal - distance 4-6 mm
wide - distance > 6 mm

This method was described by Lilja et al (1987).

On the X-OPT especially the caudal part of the piriform aperture was traced and the donor region in the symphyseal are examined for signs of

- pulp obliteration
- peri-apical pathology of the relevant teeth
- degree of re-ossification of the donor site (Groningen patients)

III.3.2.1. Mathematical method to calculate ABR at the interdental alveolar crest

The height of the interdental alveolar crest was measured on the tracing of the semi-standardized occlusal X-ray (fig. 8) by selecting a number of fixed reproducible points and performing a number of calculations as described below.

R: on the distal cemento-enamel junction of the cleft adjacent tooth medially to the cleft region

S: corresponding to R on the opposite side of the cleft i.e. the mesial cemento-enamel junction lateral to the cleft region

A: centre point of the *inter*cervical line RS

B: "deepest" point of the bony contour between R and S

P: centre point of the *intra*cervical line of the tooth medially to the cleft region

Q: the apex of the tooth medially to the former cleft

Orthodontic tracing paper (writing PVC, 100 micron, A4) was fixed over this X-ray and the points described above were marked. The contours of the relevant teeth and the alveolar limbus were drawn with a hard pencil (Bruynzeel 3H 0,5mm). On the tracing (fig. 9) a line was drawn from point A to point B. The distances AB and PQ were measured with a ruler (Zimmer Orthopaedia Ltd). The ABR was then expressed by $\frac{AB}{PQ} \times 100\%$ (Koole et al, 1989).

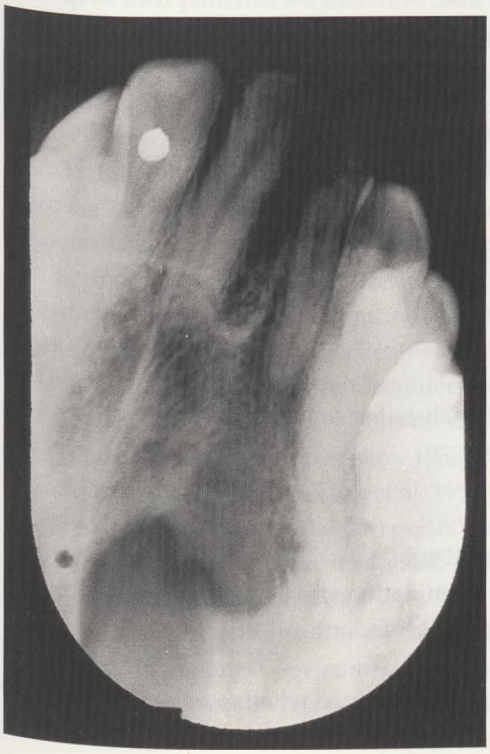

Figure 8. *The semi-standardized occlusal X-ray. If the area of interest was underexposed a Heliocontraster was used to make the tracing.*

Figure 9. *The tracing used for the measurement of the ABR.*

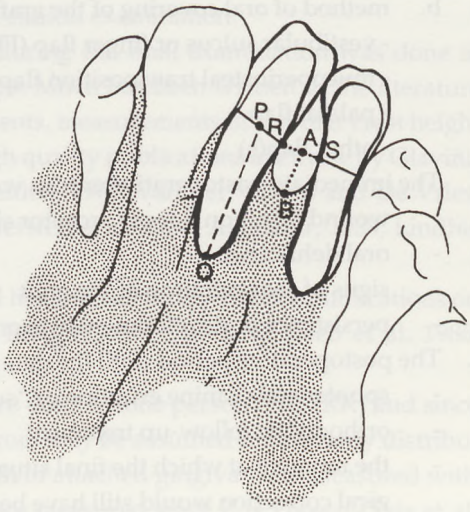

This percentage was regarded as an indicator for the functional loading of the transplanted bone and also as a parameter for the quality of the graft.

III.3.3. File analysis

In the medical files a number of data were searched for.

1. Diagnosis i.e. classification of the cleft (unilateral cleft lip palate (UCLP), bilateral cleft lip palate (BCLP)
2. During the age period 0-18 months:
   a. width of the cleft at birth (broad, average, narrow)
   b. age of lip closure and whether the anterior palate was closed at the same time
   c. age of closure of soft and hard palate
3. In the period from 18 months until ACR, information was sought with respect to:
   a. residual fistulae and possible attempts at their surgical closure
   b. pre-surgical orthodontics
   c. number of cleft related teeth
      - hypodontia
      - hyperdontia
      - hypoplasia
   d. width of the alveolar cleft just before bone grafting: wide, normal (4-6mm), narrow
   e. Other surgery
      - nose/lip correction
      - pharyngoplasty
4. As to the peri-operative period information was sought on:
   a. Calendar age of the patient at surgery; length of the developing root of the cuspid
   b. method of oral covering of the graft:
      - vestibular sulcus or finger flap (FF)
      - mucoperiosteal transposition flap (MPF)
      - palatal flap
      - other flap(s)
5. The immediate postoperative entries were analyzed as to
   - wound infection donor/acceptor site
   - oral dehiscence
   - signs of sequestration of the graft
   - persistence or development of oronasal fistula
6. The postoperative period until the date of examination was evaluated for:
   - spontaneous canine eruption or "surgical/orthodontical" eruption
   - orthodontic follow-up treatment
   - the moment at which the final situation was obtained whether or not further surgical correction would still have been desirable.

7. Miscellaneous items.
Registered were items like
- cystformation around the cuspid
- failures as to surgical or orthodontic treatment
- reoperation
- successive maxillary and/or mandibular osteotomy
- presence of permanent fixation of upper anterior teeth and of root resorption.

III.3.4. Statistical method

All data obtained were entered on a special form (viz. addendum 1) and computerized. The analysis was performed with the Superior Performing Software System (Inc. Chicago - U.S.A.) programme. The graphical figures in this thesis were obtained through Harvard Graphics (Inc.).

III.4. Discussion

III.4.1. Methods

Judging the results of ACR with ensuing orthodontics by using the six parameters described earlier has its limitations. Clinicians use clinical and radiological methods for follow-up of their patients; we therefore used the regular clinical and radiographic methods available in every day (oro-maxillo-facial (OMF))-practice. The various methods of investigation all may have errors and these are discussed in the following paragraph. Arguments in favour of the methods' usefulness are presented.

III.4.2. Clinical examination

As to canine eruption little controversy can arise. This process was followed by comparing successive occlusal X-rays and by the final clinical examination.
The periodontal condition, performed once during the final examination was done in accordance with periodontal routine check-ups. Much has been written in the literature about the reproducibility of pocket measurements, measurements of alveolar crest height and about differences between examiners. High quality publications are those by Glavind and Löe, 1967; Hassell et al, 1973; Van der Velden, 1979; Van der Velden and De Vries, 1980; Caton et al, 1981; Abbas et al, 1982; Badersten et al, 1984; Albandar, 1989; Lindhe, 1989; Marks et al, 1991; Axelsson et al, 1991).
On the whole little is published on periodontal health in cleft patients. Six publications on this topic were found (Hinrichs et al, 1984; Brägger, 1985, 1992; El Deeb et al, 1986; Ramstad, 1989; Teja et al, 1992).
The investigations presented in this thesis were done by one person only (RK) and since two groups of patients were compared any errors may be assumed to be evenly distributed among both groups. The pockets and width of attached gingiva were measured with a Hu Friedy probe. Loss of attachment was not measured since it is known (Teja et al,

1992) that this is always present anyway in cleft related teeth.
From the Utrecht group several patients had been examined on their general periodontal condition for evaluation of possible differences between upper and lower jaw in order to test our method.
In accordance with Ramfjord (1959) who introduced the system of 12 test teeth and Brägger et al (1985) no differences were found between the 12 test teeth in the mandible and those in the maxilla (the CAT excepted) in 30 UCLP patients. The sensitivity and specifity of this way of testing on PD and BOP also in cleft patients has been extensively investigated by Brägger et al (1992).
Absence of BOP is an indicator for periodontal stability (Lang et al, 1990) as is physiological tooth mobility.
The gingival colour was appraised since Haag (1977) assumed a bluish-red hue to be indicative for accelerated bone resorption.
Cervical root resorption is supposed by Gerner et al (1986) to be more prevalent in patients where bone was transplanted adjacent to teeth *after* their eruption. This is the reason it was looked for (on the semi-standardized occlusal X-ray and by probing). The vestibular sulcus seems important since Quarta and Koch (1985, 1989) are of the opinion, that presence of scar tissue perpendicular to the former cleft area causes more ABR, then if there is a proper vestibular sulcus plus attached gingiva on the graft and adjacent teeth.
The other clinical parameters investigated do not in our view require an intensive discussion, since they are part of the routine dental/oral surgical examinations and the possibility of major errors seems minimal. Of course a minor fistula might have been overlooked now and then, but it is assumed that this type of error is evenly distributed over all three groups of patients.
If required, these examinations will be further discussed in the following chapters. Whereas e.g. in evaluation of X-rays more than one examiner is usually seen to be advantageous for the avoidance of bias; in simple routine examinations especially if they are classified by yes or no, we think a true bias is very unlikely.

III.4.3. X-ray examination

CT-scanning or repeated examinations were not deemed necessary for this investigation since enough information could in our view be obtained by conventional methods (X-OPT, occlusal X-ray). The value and limitations of the X-OPT for an investigation as described here are well established and we considered the quality of the pictures obtained sufficient for a rough comparison of the three groups. They also allowed a gross evaluation of the donor site (viz. Kloosterman, 1985) in the Groningen group.
Of course there is a draw back here in the circumstance, that the Groningen patients have been X-rayed with a different apparatus, but this problem could not be overcome.
As to the donor site in Groningen, the 1-9 year follow-up period was considered long enough to judge what had happened to symphysis and teeth. Peri-apical pathology and pulp obliteration can generally be seen, but nevertheless the usual clinical vitality test

seemed essential and in case of doubt a more detailed examination is necessary. Madritsch (1968) and Pepersack (1973) were especially confronted with this problem during the first postoperative year in cases of segmental osteotomies.

III.4.3.1. The occlusal maxillary X-ray and the measurements of bone resorption

As to the literature on ABR within clefts after bone grafting one usually finds pictures of schematic drawings projected over intra-oral radiographs.

The lines of reference are usually connecting the apices of CAT and also their cemento-enamel junctions (Hall and Posnick, 1983; Bergland et al, 1986; Enemark et al, 1987; Sindet Pedersen, 1988, 1990).

A disadvantage of this method is, that percentages of resorption are always given with wide margins (0-25%, 25-50%, 50-75%, 75-100%). The first category (0-25%) is often classified as "normal or near normal". The semi-standardized occlusal X-ray of the maxilla plus the method of measuring as described in this paper allow a more precise calculation.

The reproducibility had been tested by duplo-measurements at different moments of 10 X-rays by two investigators (Van den Braber and De Lange, 1989). The error of the method was calculated with the formula

$$\sqrt{\frac{\Sigma d^2/2n}{\overline{X}}} \times 100\ \%$$

d= difference between duplomeasurements

n= number of duplomeasurements

$\bar{x}$= the mean of all measurements

The intra- and interobserver bias was negligible < 1.25%.

Akesson et al (1992) compare the data in the literature with the results of their own measurements (on panoramic and intra-oral x-rays) of marginal bone loss at the limbus alveolaris in patients with complex parodontitis.

Measurements on peri-apical intra-oral X-rays were the most accurate although the actual bone loss as measured during "surgical rootplaning" was underestimated (± 5%).

In this group of patients however, a progressive periodontal infection was present. The method of measurement was thought to be a good one, the intra-observer error being 0.5% for peri-apical X-rays only.

The reproducibility of our points of reference is almost 100% except for the apex of the medial cleft adjacent tooth, which may have changed position by root resorption as a result from orthodontic displacement. The measurements being made on the final X-rays can however be corrected by analysis of preceding X-rays from the patient before resorption took place. Recalculation of the "true" position of the apex and the original length of such a root can thus be done.

The choice of the line RS seems to us to be a correct one since

1. the cemento-enamel junction can simply be found on the occlusal X-ray;
2. R and S can be reproduced on serial X-rays;

3. Apart from rarely occurring external root resorption at this site, these points are stable.

One should realize though, that with this method more ABR is measured, than actually has occurred. The alveolar bone height next to the CAT reaches only rarely up to the cemento-enamel junction of those teeth (Brägger et al, 1992). This holds for untreated as well as for teeth which have been moved orthodontically. To eliminate this variable factor, the line RS was chosen taking the error in the measurements into account. The pre-existent height of the alveolar limbus determines the maximum obtainable bone height of the alveolar cleft (El Deeb et al, 1986; Stoelinga, 1988).

This difference in height between the cemento-enamel junction and the alveolar limbus expressed as a percentage of the medial tooth's root length was found to be 7.9%. This was determined by measurements on an aselect sample of 20 different X-rays from our material (range: 0.0%-17.0%).

Sjödin et al (1993) found in 7-9 year-old children an average distance of about 1mm between alveolar limbus and cemento-enamel junction. Albandar (1989) and Löst et al (1989) had similar results in in vitro studies.

Distances of more than 2mm were alleged to be pathological.

The periodontal condition of CAT has been extensively studied in 18 UCLP patients by Teja et al (1992) who found, that the difference in height on the distal aspect of the cleft adjacent incisors (CAI) was 2 mm (1.1-3.4mm); in the cleft associated canine (CAC) region the difference was about 1mm, not significantly different from the non-cleft side.

Our results are in agreement with those from the literature. The limbus height as measured at the "cleft sided" centrals or laterals was on average 1.1mm below the cemento-enamel junction (0-2.3mm). The variables co-responsible for this distance are: anatomy of the alveolar defect, pattern of eruption, pre-surgical orthodontics and possible dental restorations.

The percentages of "absolute" ABR could therefore be corrected (i.e. reduced) with the above mentioned percentage in order to arrive at the "real" resorption. We refrained from doing this however, firstly because in a comparison between groups the "real" number is no more valuable, than the measured one and secondly, because we thought the measured ABR fully apropriate as an indicator for functional loading. In other words, when comparing bone quality of different donor sites independently from the influence of post-operative orthodontic treatment, all information necessary is contained in this indicator.

III.4.4. Examination of files

All problems in retrospective file analysis were encountered:

- incomplete data like missing X-rays, photos, dental casts
- incomplete entries of relevant medical data
- no standardization

Since the treatment of the Utrecht group of patients had been done by experienced clinicians (e.g. Tjebbes, Egyedi) and according to a more or less standard protocol (Blijdorp,

1984), we may assume, that the data in the files as far as present are reliable.
The check-list data could be completed in almost all cases.
In the Groningen group a brief summary of the medical history of the infants (0-18 months) and an extensive documentation of the oral surgical history could be obtained. Most patients in this group were from the University cleft centre, where treatment according to protocol is the rule (Huffstadt, 1987).
Differences between the groups as to closure of lip and anterior palate, age and method of palatal closure (hard and soft) are therefore known.
Also the data of experienced clinicians as Bosker and Van Dijk are, were considered very reliable, and thus the pre-graft period of the Groningen patients seems well documented.

III.4.5. Statistics

In the chapter VIII the results of a comparison between the Groningen and Utrecht patients are analyzed. The statistical methods used in biomedical research have been extensively discussed by Kowalski (1993) in The Cleft Palate Craniofacial Journal. We would like to quote the following:

"... and it is suggested that at least some space in the Materials and Methods section of most papers could be profitably devoted to describing the rationale behind the size of the sample employed." and *"would go a long way in clarifying what the study was designed to accomplish and aid in the interpretation of the results. It may be less obvious but, in my opinion, the inclusion of this material would also help authors. It would allow them to distinguish between "exploratory" and "confirmatory" studies. Here an exploratory study is taken to mean any study that is undertaken in order to aid in the design and/or the execution of a future, more definitive, confirmatory one. Both have their place in the literature. It needs to be realized that confirmatory studies are not possible until considerable preliminary evidence is in hand. The admission that a given study is exploratory in nature would allow editors to accept valuable contributions to knowledge without the burden of considering its "statistical significance"."* and further *"... Among the few texts that explicity address the analysis of individual patient data the authors' intent is not to encourage the use of "statistics for the sake of statistics," but to show how many standard, familiar statistical techniques can aid understanding and patient management. It should be emphasized how such familiar procedures as t-tests, ANOVA, and the normal approximation to the binomial and Poisson distributions find valid and revealing application in the single-subject situation. They also cover the subject of "clinical decision analysis," which is perhaps more readily accepted in this context. In this section, I consider several techniques whose application to the management of individual patients with craniofacial anomalies is immediately evident and whose value extends beyond research endeavors into the very heart of the clinical decision making process itself. Physicians involved in the management of patients with dentofacial deformities make dozens of decisions daily. Most involve choosing one from among a number of possible alternative "treatments." This is done in spite of a certain measure of uncertainty in that treatment are prescribed even though diagnoses are not certain and therapy is not universally effective. In order to ensure that "good"*

decisions are being made we need methods for assessing the performance of diagnostic tests and how the outcomes of such tests should be incorporated into treatment planning." and finally *"... The reader will no doubt join the reviewers in noting that the current versions of these programs are of limited value in that they do not allow missing data nor do they accommodate the situation in which individuals are measured at different times. I cannot quarrel with this position, but suggest nevertheless that they will be of considerable value to those investigators who do have complete data sets."*

This is why it was decided to make use of the SSPS PC+ program and felt justified in the choice of the statistical analysis (ANOVA) and also to have reduced the patient samples from the original of 57 and 113 cleft patients respectively to 20, 30 and 18 UCLP-patients samples.

III.5. Conclusions

Since there are differences in the pre-grafting ways of treatment between the Groningen and the Utrecht patients, the value of any comparison will have its limitations. The groups however are well-matched as to the original condition at birth (all being total unilateral cleft patients) and also as to the time of ACR (< 17.5 years). Clear differences in pre-grafting treatment modalities were identified as good as possible and interpreted accordingly (see discussion of results).

Finally, the duration of the follow-up investigation in a single patient after some routine was acquired is presented.

Introductory conversation and history	10 minutes
Clinical examination (incl. impression taking and waxbite)	30 minutes
X-ray examination	15 minutes
OPT analysis	5 minutes
Measuring of ABR on occlusal X-ray	10 minutes
Medical file analysis + completion of checklist	40 minutes

The statistical analysis cannot, of course, be quantified with respect to a single patient.

References

Abbas, F., A.A.M. Hart, J. Oosting, U. van der Velden: Effect of training and probing force on the reproducibility of pocket depth measurements. J. Periodontal Research 17 (1982) 226

Åkesson, L., J. Håkansson, M. Rohlin: Comparison of panoramic and intra-oral radiography and pocket probing for the measurement of the marginal bone level. J. Clin. Periodontol. 19 (1992) 326

Albandar, J.M.: Validity and reliability of alveolar bone level measurements mad on dry skulls. J. Clin. periodontol. 16 (1989) 575

Axelsson, P., J. Lindhe, B. Nyström: On the prevention of caries and periodontal disease. Results of a 15-year longitudinal study in adults. J. Clin. Periodontol. 18 (1991) 182

Badersten, A., R. Nilveus, J. Egelberg: Reproducibility of probing attachment level measurements. J. Clin. Periodont. 11 (1984) 475

Bergland, O., G. Semb, F.E. Abyholm: Elimination of the residual alveolar cleft by secondary bone grafting and subsequent orthodontic treatment. Cleft Palate J. 23 (1986) 175

Blijdorp, P.A.: De invloed van de leeftijd van sluiten van het palatum bij de schisispatiënt opkaakgroei, KNO-status, spraak en persoonlijkheidsontwikkeling. Proefschrift R.U. Utrecht, 1984

Braber, W. van den, J. de Lange: Resultaten van de meetmethode op de tracing van de maxillaire opbeetfoto; een kritische beschouwing. Interne mededelingen (1989)

Brägger, U., Jr. E. Schurch, F. Gusberti, N. Land: Periodontal conditions in adolescents with cleft lip, alveolus and palate following treatment in a co-ordinated team approach. J. Clin. Periodontol. 12 (1985) 494

Brägger, U., E. Schurch, S. Gianai, T. von Wyttenbach, N.P. Lang: Periodontal conditions in adult patients with cleft lip, alveolus and palate. Cleft Palate Cranio-Fac. J. 29 (1992) 179

Caton, J., G. Greenstein, A.M. Polson: Depth of periodontal probe penetration related to clinical and histologic signs of gingiva inflammation. J. Periodont. 52 (1981) 626

Egyedi, P.: Chirurgische correctie van de gedeformeerde maxilla bij volwassen patiënten met cheilognathopalatoschisis. Ned. Tijdschr. Geneesk. 25 (1973) 117

El Deeb, M.E., J.E. Hinrichs, D.E. Waite, C.L. Bandt, R. Bevis: Repair of alveolar cleft defects with autogenous bone grafting: periodontal evaluation. Cleft Palate J. 23 (1986) 126

Friede, H., B. Johanson: A follow-up study of cleft children treated with primary bone grafting. I. Orthodontic aspects. Scand. J. Plast. Reconstr. Surg. 8 (1974) 88

Gerner, N.W., B. Hurlen, O. Bergland, G. Semb, E.M.S. Beyer-Olsen: External root resorption in patients with secondary bonegrafting of alveolar clefts. Endod. Dent. Traumatol. 2 (1986) 263

Glavind, L., H. Loë: Errors in the clinical assesment of periodontal destruction. J. Clin. Periodont. 15 (1967) 180

Haag, R.: Das Verhalten des Knochentransplantates bei jugendlichen Lippen-, Kiefer-, Gaumen-Spaltpatienten nach Überbrückung der Alveolarspalte. Thesis, University of Zürich, Ströbele, Romanshorn 1977

Hall, H.D., J.C. Posnick: Early results of secondary bone grafts in 106 alveolar clefts. J. Oral Max.-Fac. Surg. 41 (1983) 289

Hassell, T.M., M.A. Germann, V.P. Saxer: Periodontal probing: Interinvestigator discrepancies and correlations between probing force and recorded depth. Helvetica Odontol. Acta 15 (1973) 114

Hinrichs, J.E., M.E. El Deeb, D.E. Waite, R.R. Bevis, C.C. Bandt: Periodontal evaluation of canines erupted through grafted alveolar cleft defects. J. Oral Max.-Fac. Surg. 42 (1984) 717

Van Hoeken, F. van: Occlusale röntgenfoto's bij schisispatiënten. Ned. Tijdschr. Tandheelk. 90 (1983) 215

Huffstadt, A.J.C, P.H.M. Spauwen, J. Boersma, G.S. Havinga, J. Bergstra: Schisis; Multidisciplinaire benadering. De Nederlandse Bibliotheek der Geneeskunde. Samsom Stafleu, Alphen aan den Rijn/Brussel 1987

Kloosterman, J.: Köle's osteotomy, a follow-up study. J. Max. Fac. Surg. 13 (1985) 59

Koole, R.: Behandeling van de schisispatiënt. Overzicht en achtergronden. Ned. Tijdschr. Tandheelk. 97 (1990) 472

Koole, R., H. Bosker, F. Noorman van der Dussen: Late secondary autogenous bone grafting in cleft patients comparing mandibular (ectomesenchymal) and iliac crest (mesenchymal) grafts. J. Cranio Max.-Fac. Surg. 17 (1989) 28

Kowalski, C.J.K.: Data analysis in craniofacial biology with special emphasis on longitudinal studies. Cleft Palate Craniofac. J. 30 (1993) 111-120

Lang, N.P., R. Adler, A. Joss, S. Nyman: Absence of bleeding on probing. An indicator of periodontal stability. J. Clin. Periodontol. 17 (1990) 714

Lilja, J., M. Möller, H. Friede, C. Lauritzen, L.E. Petterson, B. Johanson: Bone grafting at the stage of mixed dentition in cleft lip and palate patients. Scand. J. Plast. Reconstr. Surg. 21 (1987) 73-79

Lindhe, J.: Textbook of clinical periodontology. Copenhagen, Munksgaard 1989

Löst, G., K. Mirn, W. Nüssle: Determination of the facial/oral alveolar crest using RF-echograms. An in vitro study on the periodontium of pigs. J. Clin. Periodontol. 16 (1989) 539-544

Madritsch, E.: Spätergebnisse nach Korrektur von Dysgnathien und Zahnstellungsanomalien durch Alveolarforsatzbewegungen und Kortikotomie. Thesis, University of Zürich, Juris, Zürich 1968

Marks, E.G., S.B. Low, M. Taylor, R. Baggs, I. Magnusson, W.B. Clark: Reproducibility of attachment level measurements with two models of the Florida Probe. J. Clin. Periodontol. 18 (1991) 780

Pepersack, W.J.: Tooth vitality after alveolar segmental osteotomy. J. Max.-Fac. Surg. 1 (1973) 85

Quarta M., J. Koch: Mundvorhofplastik beim LKGS-Spaltträger unter Verwendung von Polyglactin-Netz. Zahnärztl Prax 35 (1985) 344

Quarta M., J. Koch: Metric results of vestibuloplasty in unilateral cleft patients. J. Cranio Max.-Fac. Surg. 17 (1989) 175

Ramfjord, S.: Indices for prevalence and incidence of periodontal disease. J. Periodontol. 30 (1959) 51

Ramstad, T.: Periodontal condition in adult patients with unilateral complete cleft palate. Cleft Palate J. 26 (1989) 14

Sindet-Pederson, S., H. Enemark: Mandibular bone grafts for reconstruction of alveolar clefts. J. Oral Max.-Fac. Surg. 46 (1988) 533

Sindet-Pederson, S., H. Enemark: Reconstruction of alveolar clefts with mandibular or iliac crest bone grafts. A comparative study. J. Oral Max.-Fac. Surg. 48 (1990) 554

Sjödin, B., L. Matsson, L. Unell, J. Egelberg: Marginal bone loss in the primary dentition of patients with juvenile periodontitis. J. Clin. Periodontol. 20 (1993) 32

Stoelinga, P.: Persoonlijke mededeling. 32e Najaarscongres Nederlandse Vereniging voor Mondziekten en Kaakchirurgie. Alkmaar, november 1988

Teja, Z., R. Persson, M.L. Ommell: Periodontal status of teeth adjacent tot non-grafted unilateral alveolar clefts. Cleft Palate Cranio-Fac. J. 29 (1992) 357

Turvey, T.A., K. Vig, J.M. Moriarty, J. Hoke: Delayed bone grafting in the cleft maxilla and palate; A retrospective multidisciplinary analysis. Am. J. Orthod. 86 (1984) 244

Van der Velden, U.: Probing force and the relationship of the probe tip to the periodontal tissues. J. Clin. Periodont. 6 (1979) 106

Van der Velden, U., J.H. de Vries: The influence of probing force on the reproducibility of pocket depth measurements. J. Clin. Periodont. 7 (1980) 414

Chapter IV

A comparative investigation on autologous mandibular and iliac crest bone grafts.
- An experimental study in sheep -

This chapter is an edited form of an article that has been published in the J. Cranio-Max.-Fac. Surg. 19 (1991) 133-143

Chapter IV

A comparative investigation on autologous mandibular and iliac crest bone grafts. - An experimental study in sheep -

VI.1. Introduction

In patients with a cleft lip, alveolus and palate, iliac crest autografts are traditionally widely used for the closure of the alveolar cleft (Koberg, 1973; Jackson et al, 1982; Witsenburg, 1985; Bergland et al, 1986; Demas and Sotereanus, 1988; Paulin et al, 1988; Stoelinga et al, 1990). Witsenburg and Freihofer (1990) reported on rib grafts; the good results of cranial bone grafts in ACR were reported by Wolfe and Berkowitz (1983), Harsha et al (1986), and Jackson et al (1983).
In order to eliminate a second surgical procedure, thus reducing the overall morbidity and operation time, Allard et al (1987), Nique et al (1987) and Maxson et al (1990) advocated the use of homologous bone for secondary cleft repair.
Hydroxylapatite particles were evaluated for repair of alveolar clefts in dogs (Cullum et al; 1988) and Horsewell and El Deeb (1989) reported their results in a primate model. In both studies the artificial residual alveolar clefts were closed satisfactorily. However, the long-term effects on the *growing* maxilla, the *erupting* teeth or the *orthodontic* movement of teeth in these cases *in humans* were questionable. Therefore, one may conclude that in tertiary alveoloplasty the use of hydroxylapatite is possible (Horsewell and El Deeb, 1989).
Bosker and Van Dijk (1980) however prefer the use of autografts obtained from the mandible and claim to obtain good results with this type of graft. Koole et al (1987, 1989) showed similar good results. Simultaneously Freihofer and Kuijpers-Jagtman (1987, 1989) and later Sindet-Pedersen and Enemark (1988, 1990) and Borstlap et al (1990) mentioned good results with mandibular bone grafting in reconstruction of the alveolar cleft.
The advantages and disadvantages of these different procedures are summarized in table 3.
We have tried to obtain an answer to the question whether one of these two types of autograft might be superior to the other, with respect to the quality of alveolar reconstruction. To eliminate other factors which might influence the bone remodelling and alveolar reconstruction, we compared the two types of graft simultaneously in an animal experiment.

IV.2. Material and Methods

For this study, nine healthy Friesian sheep (age 1.5-2 years) were used. In these sheep, the two types of graft were implanted in artificially-produced bilateral maxillary defects, localized symmetrically with respect to the midline.
Serial intra-oral dental radiographs were taken under general anaesthesia.
Six months after implantation, the grafted areas were submitted to radiological, histologi-

categories	iliac crest graft (anterior)	mandibular graft (symphysial)	homologous graft (bank bone)	allogeneic graft (HA)
morbidity complications donor site	gait disturbances neurosensory disturbances scar	almost none in case of apical trauma, endodontic treatment	none transmitting virus (?)	none
size of the donor defect	visible and palpable	none	none	none
number of operation fields	2	1	1	1
hospitalization time	7-10 days	± 5 days	± 5 days	± 5 days
tooth eruption in former cleft region	sometimes altered (enlarged dental follicle)	sometimes altered (enlarged dental follicle)	often disturbed, delayed	impossible
postgrafting orthodontic treatment	not influenced starting after 12 weeks	not influenced starting within 12 weeks	delayed	impossible

Table 3: *Clinical features; advantages and disadvantages of several alveolar cleft grafting procedures*

cal and histomorphometric investigations.

IV.2.1. Surgical procedure

Pre-operatively, the healthy sheep were starved for 48 hours to prevent possible occurrence of regurgitation pneumonia. Surgery was performed under general anaesthesia. After induction with Nesdonal (thiopental), an oro-endotracheal tube was inserted and anaesthesia was continued by a N_2O/O_2 mixture and Halothane. For prophylactic reasons, before obtaining the graft, 2 g. of ampicillin and 500 mg. of metronidazole were administered intravenously. On both sides of the maxilla, alveolar defects were created in the following way (El Deeb et al, 1985):

1. Extraction of the first upper deciduous molar and removal of the premolar tooth germ.
2. Resection of the buccal cortex.
3. Perforation of the nasal floor over an area of ± 1 cm^2.
4. Additional removal of bone in a mesial and palatal direction.

The bone was removed using rotating instruments and rongeurs. Remnants of the nasal mucosal lining were removed. Bone grafts were obtained from the iliac crest and from the mandibular pre-angle region. They were shaped to 25x15x10 mm in size. Then they were wedged into the alveolar defects (fig. 10).

After implantation of the grafts, the defects were covered with a transpositioned, scari-

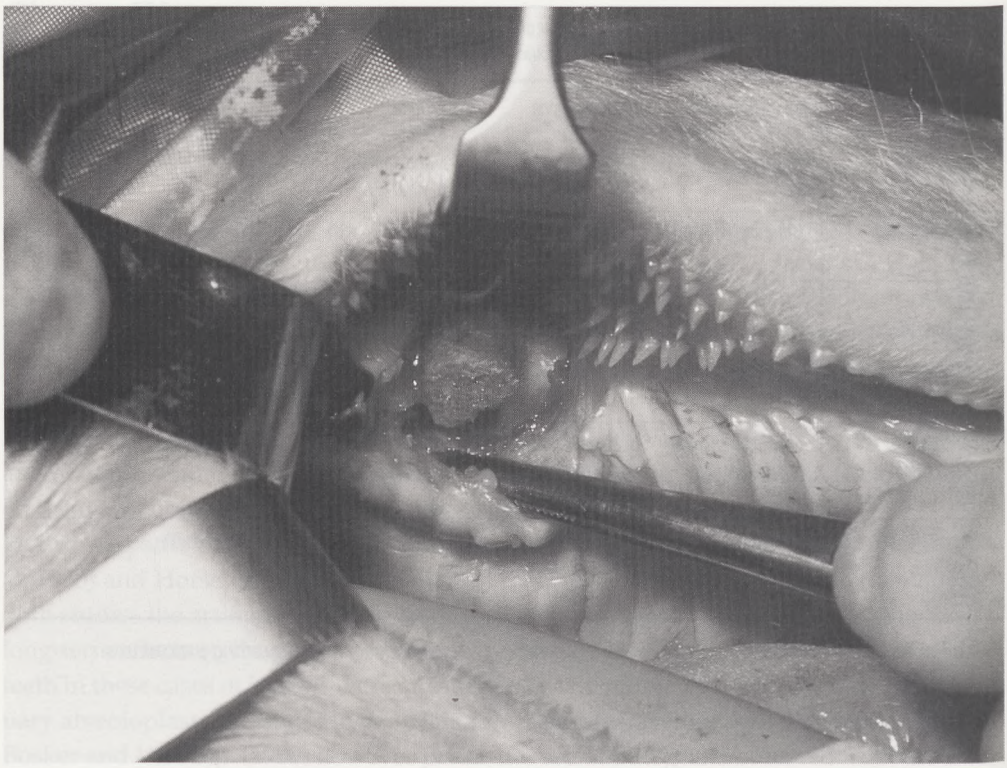

Figure 10. *Intra-operative view of the recipient site with the iliac crest bone graft in situ.*

fied mucoperiosteal flap both on the buccal and palatal side. The buccal transposition flap had to be scarified because of the size of the defect which had to be covered. No attempt was made to close the nasal mucosa or the mucosa of the maxillary sinus which was sometimes perforated.

Prior to the implantation, a sample of each graft was taken for histological investigation. In the mandibular graft, cortical bone dominated, whereas in the iliac crest graft trabecular bone was predominant (fig. 11).

After 6 hours a liquid diet was commenced, consisting of pre-moistened nutritious food, to prevent dehiscence due to mechanical trauma. Postoperatively, each animal received 5 ml Leotrox (Trimethoprim and Sulphatroxazole) intravenously twice daily for 5 days. After one week, the animals were allowed to eat hay and grass. The sheep were visited daily in the first week, including inspection and palpation of the donor sites and intraoral inspection. They were examined once in the second, sixth and twelfth week after surgery.

In one case (sheep no. 6), a defect was prepared without the insertion of a graft, this is indicated as a sham operation. One unoperated sheep (no. 9) served as a control.

Figure 11.
Microradiograph of the mineralized part of the mandibular (A) and iliac crest graft (B). The difference in architecture; cortical and trabecular bone is evident.

IV.2.2. Radiographic procedure

Immediately after surgery semi-standardized maxillary radiographs of the recipient region were taken (Philips, Diagnost Maximus M150). The semi-standardized maxillary X-ray technique was as follows:

1. Lateral positioning of the head of the sheep on the X-table.
2. The 6x8 cm dental occlusal X-ray film was placed intra-orally and
3. exposed according to the bisector rule.
4. Fixed 110 cm focus/film distance.
5. 40 m.a.s. exposure time and 55 kilo-voltage.

All this ensured the constant quality of the X-ray technique used. The immediate post-operative radiograph showed the preparation of the defect and the graft, so it was decided not to prolong the surgery for supplementary intra-operative radiographs. Serial radiography in the sixth, twelfth and twenty-sixth weeks was performed under general anaesthesia.

IV.2.3. Histological procedure

After 26 weeks, the animals were sacrificed using multiple doses of Euthanon intravenously. However, before death, under spontaneous ventilation and whilst circulation was still intact, the arteria carotis communis was dissected bilaterally in order to obtain intravital fixation of the tissues. For fixation fluid, a buffered methanol and formol-containing solution according to Burkhardt (Burkhardt, 1966) was used. The maxilla was excised over a distance of 2 cm; 5 mm thick maxillary segments were cut with a diamond band saw, in a transversal direction, starting at the deciduous molar distal from the grafted area.

After fixation for one week in Burkhardt's (1966) solution, the slices were prepared for

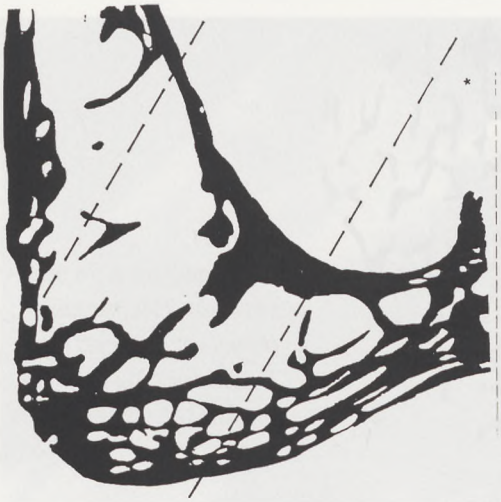

Figure 12. *For legend see text.*

embedding in methyl-methacrylate. Serial undecalcified 5 µm sections as well as 100 µm groundsections 1.0-1.5 mm apart were prepared in such a way that the area of the former defect and its direct environment was included within the serial sections.
The 5 µm sections were cut with the use of a Jung K microtome and stained according to Goldner. This staining method is suitable for discriminating clearly between mineralized bone and osteoid. These sections were used for histomorphometric and histological investigation.
Ground sections, 100 µm thick, were used for microradiography. The area of interest (as indicated in fig. 12) is confined between two parallel lines enclosing the top of the alveolar

Table 4: *No significant difference in volumetric density in grafted area 26 weeks after implantation (Wilcoxon test)*

sheep No	*origin graft*	*BV/TV %*	*origin graft*	*BV/TV %*
1	*crista*	*38.36 ± 6.81* (n=7)*	*mandible*	*45.66 ± 7.85* (n=7)*
2	*crista*	*54.00 ± 11.64* (n=7)*	*mandible*	*57.29 ± 8.77* (n=6)*
3	*(crista)*	*–*	*(mandible)*	*–*
4	*crista*	*51.42 ± 12.39* (n=6)*	*mandible*	*54.92 ± 3.47* (n=7)*
5	*crista*	*58.21 ± 9.91* (n=6)*	*mandible*	*57.43 ± 8.00* (n=7)*
6	*sham*	*55.62 ± 4.47 (n=7)*	*mandible*	*52.87 ± 6.27* (n=8)*
7	*crista*	*44.47 ± 5.67* (n=8)*	*mandible*	*50.39 ± 6.08* (n=7)*
8	*crista*	*47.32 ± 7.47* (n=6)*	*mandible*	*51.31 ± 6.84* (n=6)*
9	*control (L)*	*37.19 ± 6.18 (n=6)*	*control (R)*	*39.01 ± 4.47 (n=7)*
mean values (*)		*48.96 ± 7.10*		*52.83 ± 4.18*
number of sheeps		*6*		*7*

** = values used for the Wilcoxon test*
n = number of microradiographs used for the measurement of BV/TV% of the grafted area with the IBAS

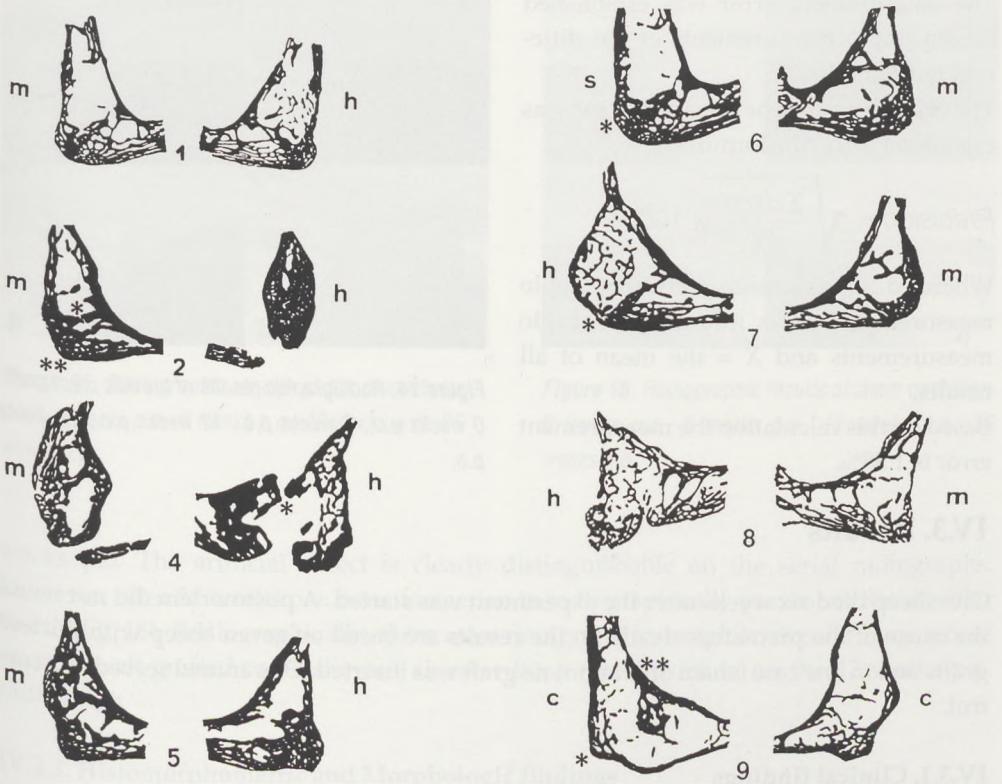

Figure 13. *Overview of the areas of interest grouped in pairs of eight sheep. m= mandibular graft; h= iliac crest graft; s= sham, c= control.*

process in the centre. The actual distance between these lines is 5 mm. The angle between the midline of the maxilla and the medial of the parallel lines is 33°. The area of interest is furthermore limited by the periosteum of the upper jaw and the nasal mucosa. The area indicated above, enclosed the most reactive bone portion (fig. 13). Bone density in the grafted area was measured with an Image Analyzing Computer (IBAS).

The volumetric density of cortical and trabecular bone, Bone Volume (BV), is expressed as a fraction of the Total Bone Volume (TV = tela ossea + marrow) and indicated as BV/TV%. In fact the measurements were carried out in the plane of the section by means of point counting, six to eight measurements were made per maxillary defect.

IV.2.4. Statistical procedures

Six to eight measurements are made per area of interest. The mean values + 2xSD per area are presented in table 4. Comparing bone densities in areas with mandibular grafts and densities in areas with iliac crest grafts, all measured values of the two categories are compared using the Wilcoxon test.

The measurement error was established by ten duplo measurements of ten different radiographs.
The reproducibility or precision error was calculated using the formula:

$$Precision = \sqrt{\frac{\Sigma d^2/n}{\overline{X}}} \times 100\ \%$$

Where d = difference between duplo measurements, n = number of duplo measurements and $\overline{X}$ = the mean of all results.
Based on this calculation the measurement error is 1.58%.

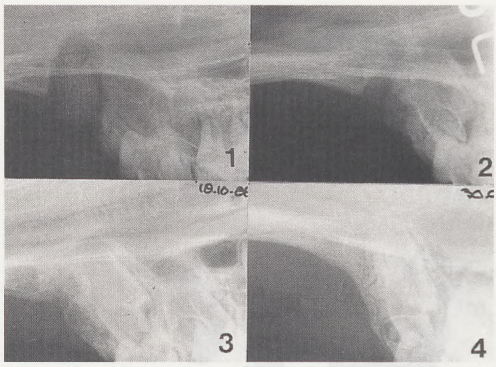

Figure 14. *Radiographic results of the iliac crest graft. 0 weeks p.o., 6 weeks p.o., 12 weeks p.o., 26 weeks p.o.*

IV.3. Results

One sheep died six weeks after the experiment was started. A postmortem did not reveal the cause of the premature death. So the results are based on seven sheep with thirteen grafts and in one case (sham operation) no graft was inserted. One animal served as a control.

IV.3.1. Clinical findings

In the first week, two sheep showed small wound dehiscences on the mandibular bone graft side (left-hand side) (sheep 1-5). In one sheep this resulted in partial bone loss up to 1/3 of the original mandibular graft; in the other sheep, no mandibular bone loss was noticed. Postoperative wound infection did not occur, either in the donor areas or in the recipient areas.

IV.3.2. Radiographic findings

Immediately postoperatively, the corticocancellous iliac crest grafts appeared less radio-opaque than the surrounding alveolar bone. At six weeks p.o. the grafted bone was still less radio-opaque, but there was close contact with the adjacent alveolar bone. At twelve weeks p.o. the alveolar cortex was almost reconstituted and at the 26th weeks p.o. the grafts were almost indistinguishable from the host bone (fig. 14).
Immediately postoperatively the autologous mandibular grafts were as radio-opaque as the surrounding alveolar host bone but clearly recognizable because of the different direction of the trabeculae. At six weeks p.o. there was close contact between the grafts and the surrounding bone. From the twelfth week p.o. the normal maxillary radiographic pattern was again present (fig. 15).
In contrast to the grafted defects, no bone formation is seen in the sham operation up to 12

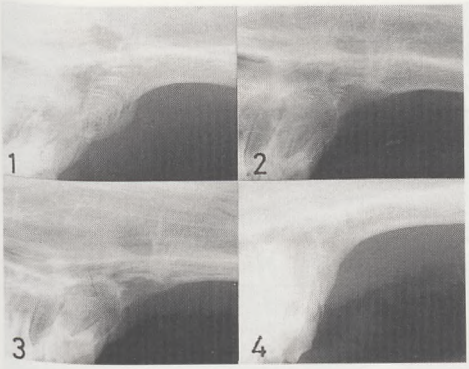

Figure 15. *Radiographic results of the mandibular graft. 0 weeks p.o., 6 weeks p.o., 12 weeks p.o., 26 weeks p.o.*

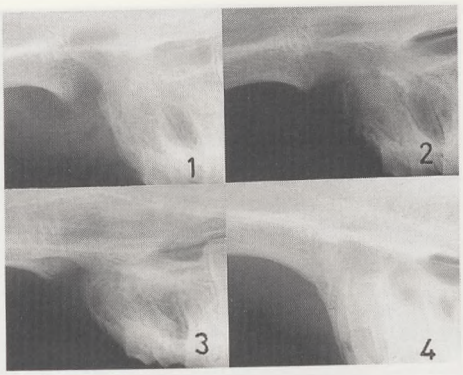

Figure 16. *Radiographic results of sham operation. 0 weeks p.o., 6 weeks p.o., 12 weeks p.o., 26 weeks p.o.*

weeks p.o. The artificial defect is clearly distinguishable on the serial radiographs. However, after 26 weeks p.o. bone formation is radiographically present in the alveolar defect (fig. 16). Radiographically, there were no signs of incomplete alveolar bone reconstruction, all grafted cases showed alveolar bone reconstruction on the 12 weeks p.o. radiograph.

IV.3.3. Histomorphometric and Morphologic findings

In table 4, the results are presented of the histomorphometric measurements of the former defects and the origin of the grafts. It appears that there is no significant difference in the volumetric density (BV/TV%) between the two types of bone after 26 weeks p.o. To qualify to a certain extent, bone remodelling and alveolar reconstruction (BRAR), 4 types of bony architecture in the former artificial cleft can be distinguished at 26 weeks p.o., with respect to the origin of the graft:

1. Mandibular architecture
2. Iliac crest architecture
3. Mixed architecture i.e. a combination of the grafted bone and the host bone architecture
4. The normal maxillary architecture

In table 5 the data are presented which we found representative for the quality of BRAR in relation to the origin of the grafts.

IV.3.4. Histological findings

During histological observations of the serial sections of 13 grafted maxillary areas of interest, it was observed that three grafted areas were not fully bridged by bony tissue (2

origin graft *architecture*	*iliac crest autograft (n = 6) (sheep number)*	*mandibular autograft (n = 7) (sheep number)*
mandibular architecture in the grafted area		*4 (2R; 4R; 5R; 7L)*
iliac crest architecture in the grafted area	*3 (4L; 7R; 8R)*	
mixed architecture in the grafted area	*2 (2L; 5L)*	*2 (1R; 6L)*
normal architecture	*1 (1L; 9 control)*	*1 (8L;9 control)*
partial sequestration graft during experiment	*0*	*1*
incomplete bony closure of the defect	*2*	*1*
cases with clear signs of inflammation	*0*	*0*

Mixed architecture: original graft "mixed" with host bone.
R = right maxilla L = left maxilla.

Table 5: *Quality of bone repair; see also figure 13*

Figure 17-21. *In these photomicrographs the areas indicated with * in Fig. 13 are shown. The number in the lower right corresponds to the sheep number.*

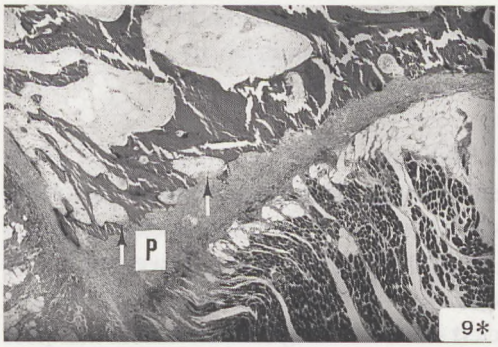

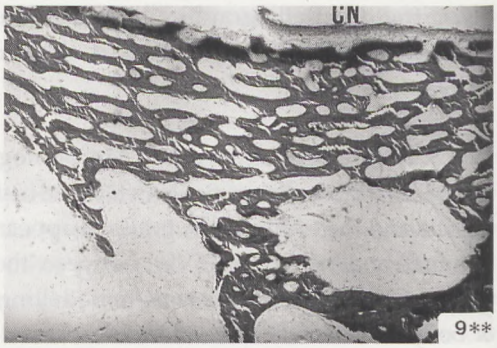

Figure 17. *Sheep No. 9, control without operation.*

Figure 17a. *Cortical bone with Haversian canals in close contact with the periosteum (P). Goldner x12.*

Figure 17b. *Cortical bone at the side of the cavum nasi (CN). Note the phenomenon of trabecularization of the cortex. Goldner x12.*

iliac crest, 1 mandibular grafted artificial defect). Dense hypocellular fibrous tissue and occasionally glandular tissue were found. In fig. 13 the most unfavourable serial section is depicted.

In figure 17 the normal histology of the unoperated maxilla is shown (sheep no. 9). Cortical and trabecular bone can be distinguished, the cortical bone shows signs of trabecularisation, mainly fatty tissue is present in the marrow cavities. Especially in the cortical region, areas of active bone resorption (osteoclasts) can be seen.

In figure 18, the area of interest 26 weeks after the sham operation is depicted. Increased

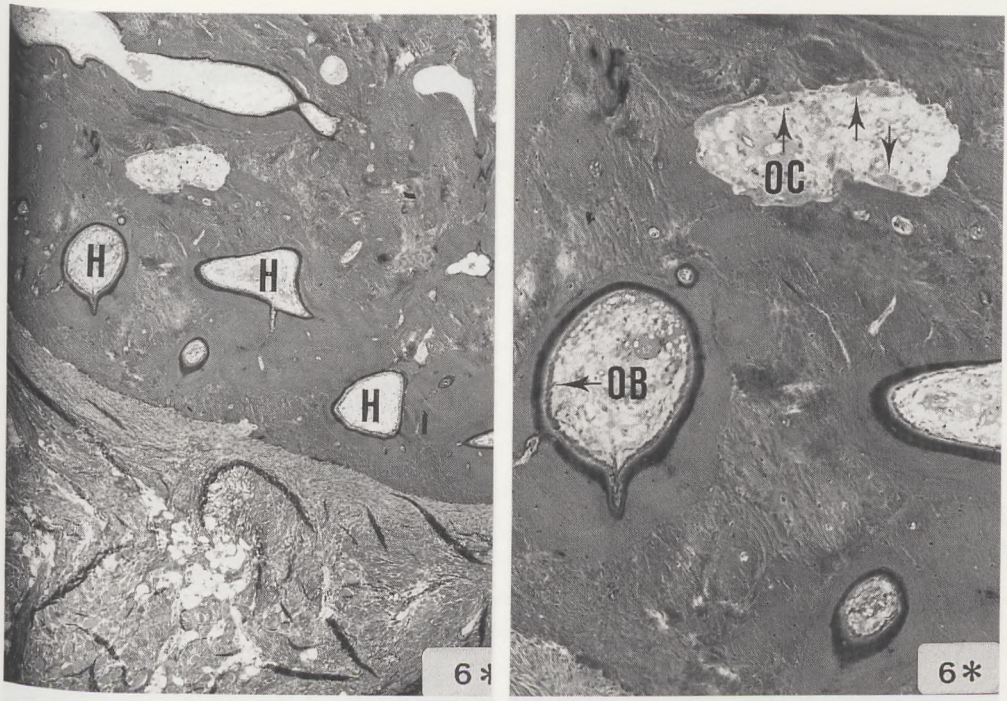

Figure 18. *Sheep 6, sham operation.*

Figure 18a. *Part of the alveolar bone with Haversian canals (H). Goldner x15.*

Figure 18b. *Detail of Haversian Canal. OC= osteoclasts, OB= osteoblasts. Goldner x15.*

density of the cortical bone of the alveolar ridge can be observed. The bone turnover in the area is increased. Multiple Haversian canals are present, some with active bone formation (cuboidal osteoblasts and osteoid) others with active bone resorption (osteoclasts) (fig. 18b).

Figure 19 shows the area of interest 26 weeks after implantation of the mandibular graft (sheep 2). The histologic view shows increase in bone density at the alveolar and nasal side. The bone turnover is increased. Areas of active bone formation are easily found. Cuboidal osteoblasts and osteoid in Haversian canals is abudantly present.

The histological findings of an iliac graft after 26 weeks were shown in figure 20. The bone turnover in the grafted area is increased at the side of the alveolar ridge. The alveolar ridge is covered with dense connective tissue. The surface of the alveolar ridge is rather irregular, depending on bone resorption and bone formation. Nearly all of the surface of the underlying trabecular bone is covered with osteoid. Active i.e. cuboidal osteoblasts are almost absent in this area. In this case the marrow spaces contain mainly fatty tissue.

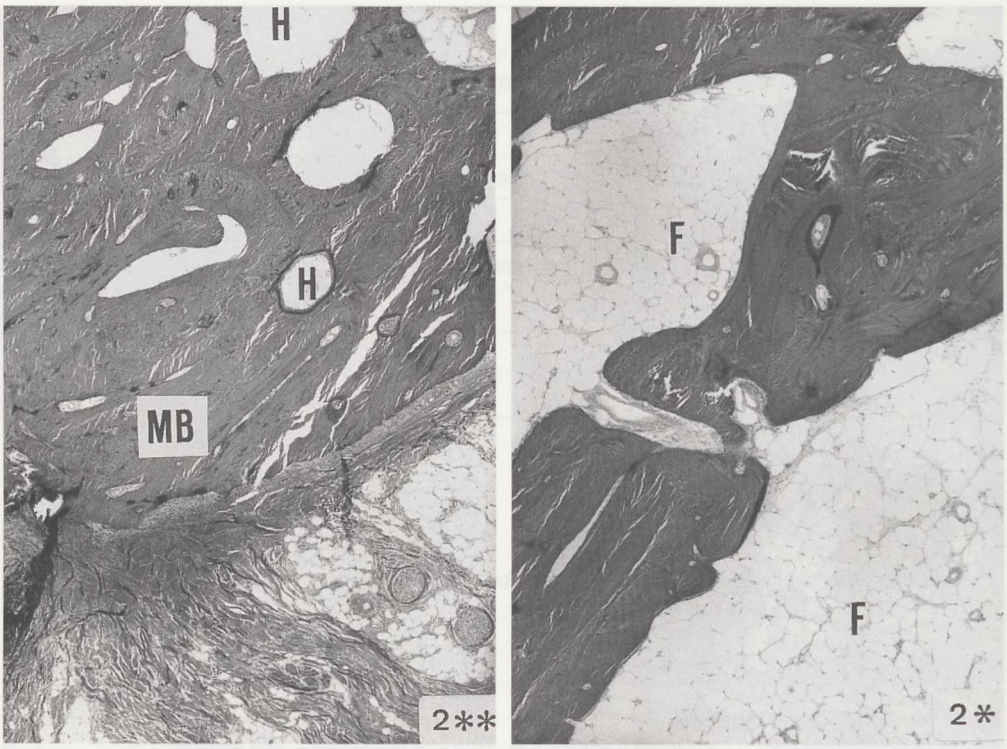

Figure 19. *Sheep No. 2, mandibular graft.*

Figure 19a. *Part of the alveolar ridge. The mineralized bone (MB) is rather dense. Note the Haversian canals (H) of different activity. Goldner 5 µm undecalcified section. x20.*

Figure 19b. *A bone trabeculum surrounded by fatty tissue (F). The bone activity is not increased in this area. Goldner x30.*

IV.4. Discussion

Several methods are available for the correction of alveolar clefts. These are described extensively by many others (Boyne and Sands, 1972; Troxell et al, 1982; Hall and Posnick, 1983; Turvey et al, 1984; El Deeb et al, 1986; Enemark et al, 1987). We have compared these two types of graft because our department has a good collaboration with the maxillofacial department of the Diaconess Hospital of Groningen where mandibular symphysial grafts have been used routinely since 1976 (Bosker and Van Dijk, 1980; Koole et al 1989).

The choice of the mandible as a graft donor site is based on the fact that both mandibular and maxillary bone are derived from neuroectodermal cells (Le Lievre and le Douarin, 1975; Freeman et al, 1975; Le Lievre, 1978; Hall, 1980; Noden, 1980; Been et al, 1984; Been, 1987; Hall, 1987, 1990; Slavkin, 1990; Bronner-Fraser, 1990) whereas iliac crest bone is of

Figure 20. *Cortical and trabecular bone, Haversian canals (H), blood vessels (V), and fatty tissue (F). Goldner x35. Sheep No. 7, iliac crest graft.*

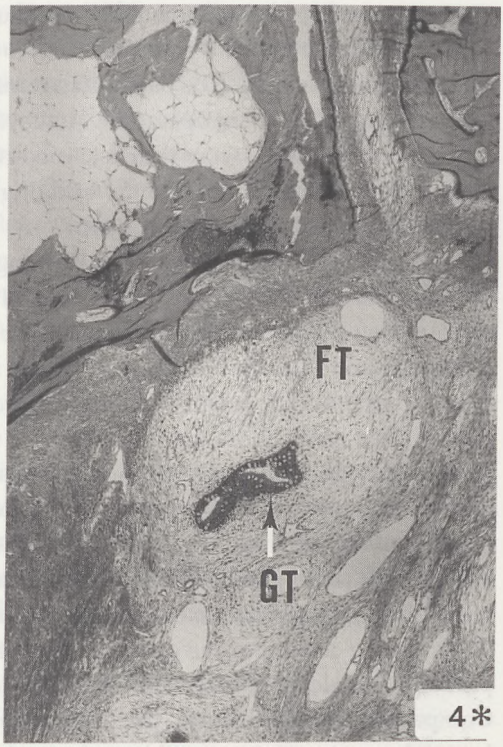

Figure 21. *Sheep No. 4, iliac crest graft. Fibrous (FT) tissue is present in the intra-bony defect. There is an island of glandular tissue (GT) probably translocated during the operation. Goldner x30.*

mesodermal origin. It was postulated, therefore, that acceptance of mandibular grafts might be better than grafts of other embryological origin. Merely based on our radiological, histomorphometrical and histological findings we cannot discriminate between autologous grafts obtained from the iliac crest and those obtained from the mandibular angle, in relation to the quality of BRAR. Nevertheless, other factors in daily clinical practice as presented in tables 1 and 3, may play a role in the choice of the graft. Our experimental findings are not in contradiction to the ideas of Bosker and Van Dijk (1980), Sindet-Pedersen and Enemark (1988), Koole et al (1987, 1989), Freihofer and Kuijpers-Jagtman (1987, 1989), Kuijpers-Jagtman et al (1989), Witsenburg and Freihofer (1990), Sindet-Pedersen and Enemark (1990) and Borstlap et al (1990) that mandibular grafts or chin bone are superior to iliac crest grafts, provided a sufficient amount of bone can be harvested to bridge the gap in the alveolar process.

The partial sequestration of one mandibular graft did not effect the outcome after 26

weeks. The serial radiographs show osseous bridging of the defect before the twelfth week. The remnants of the graft were able to repair the artificial defect.
The above results should be balanced against the fact that after 26 weeks p.o. there was also bridging in the sham operation. However the dynamics of bone remodelling (viz the radiographic findings) were the basic subject of this investigation and, therefore, we considered the fact that in the end the bridging observed in the sham operation was irrelevant in the context of this experiment.
Marx et al (1984), compared particulate allogenic bone with particulate autogenous bone from the iliac crest in dogs; Cullum et al (1988), evaluated hydroxylapatite particles in alveolar cleft repair compared to particulate cancellous bone from the iliac crest in dogs. Horsewell and El Deeb (1989), in a primate model, compared the use of non-porous hydroxylapatite in cleft repair to iliac crest graft. They all found fibrous tissue in the iliac crest grafted areas in several instances. We found in our sheep experiment two cases of incomplete bone repair, i.e. fibrous and glandular tissue in the defect in the iliac crest grafted group. In the group which was grafted with mandibular pre-angle bone, one case of incomplete bone repair was noted. In none of these cases had sequestration of the autologous graft taken place. In one particular case of the iliac-crest-grafted, incomplete bony repair, it might be possible that the presence of glandular tissue in the former defect had impeded the closure of the defect by bone formation (fig. 21). The glandular tissue was probably translocated to the area of interest during the preparation of the defect.
Comparing the architecture, the histomorphometric findings and the histological findings, it has not yet been possible to determine the superiority of either the mandibular or iliac crest graft. The bone turnover is still increased in the area of interest six months after operation in the mandibular and iliac crest grafted defect. It may be presumed that the process of bone healing was not yet complete.
The old controversy in bone transplantion surgery, transplanting cancellous bone chips as opposed to a mainly corticocancellous bone block, is revised. The good results of membranous mesenchymal calvarian bone in alveolar cleft repair, advocated by Wolfe and Berkowitz (1983), Kawamoto and Zwiebel (1985) and Harsha et al (1986), combined with the experimental work of Smith and Abramson (1974), Zins and Whitaker (1979, 1983) and Kusiak et al (1985) indicating the faster revascularization of membranous bone which results in a greater viability and better maintenance of bone volume may be, mutatis mutandis, also applicable to the corticocancellous membranous ectomesenchymal mandibular bone graft.
Jackson et al, however, in 1986, no longer use cranial mesenchymal bone grafts in secondary reconstruction of alveolar clefts, because the quality of bone derived from the skull graft is not satisfactory for grafting the alveolar area. He reported the difficulty of achieving sufficient density with cranial bone. The ingrowth of fibrous tissue was not inhibited by the lack of density and periodontal defects could form around the adjacent teeth. Our study, however, proves no difference in bone quality after grafting iliac crest or mandibular bone in the artificial bone defect (table 5).

The theory of osteoinduction repostulated by Urist (1953), confirmed by Burwell (1966) and quoted by Marx et al (1984) and the introduction of a protein BMP (Bone Morphogenetic Protein) by Urist in 1981 and the reference of B.K. Hall in 1987 concerning the role BMP plays in the initiation of bone formation in the embryonic mandible, and the finding that BMP is mainly found in cortical bone, can also play a major role in the good results of mandibular bone as a graft material. In this animal experiment, where we used membranous ectomesenchymal corticocancellous (mandibular) bone and compared this with the "golden standard" endochondral mesenchymal corticocancellous (iliac crest) bone, more questions are raised than answered. Further investigations in collaboration with craniofacial embryologists/biologist is mandatory (Glowachi, 1985).

IV.5. Conclusion

It appears that transplantation of mainly cortical ectomesenchymal bone, at least in this experiment, was not inferior to the transplantation of mainly trabecular bone of the iliac crest in relation to the repair of an artificially created maxillary defect. Nevertheless, from the clinical point of view we support the views expressed by Bosker and Van Dijk (1980) and others that mandibular bone grafts should be prefered to iliac crest grafts in this type of surgery, whenever possible.

References

Allard R.H.B., C. Lekkas, J.G.N. Swart: Autologous versus homologous bone grafting in osteotomies, secondary cleft repairs and ridge augmentations; A clinical study. Oral Surg. Oral Med. Oral Pathol. 64 (1987) 269

Been, W.: Mediane facio-cerebrale misvormingen. Thesis. University of Amsterdam. With a summary in English. Rodopi (1987)

Been, W., S.H. Lieuw Kie Song, J. van Limborgh: Developmental anomalies of the lower face and the hyoid cartilage due to partial elimination of the posterior mesencephalic and anterior rhombencephalic neural crest in chick embryos. Acta Morphol. Neerl. Scand. 22 (1984) 265

Bergland, O., G. Semb, F.E. Abyholm: Elimination of the residual alveolar cleft by secondary bone grafting and subsequent orthodontic treatment. Cleft Palate J. 23 (1986) 175

Borstlap, W.A., K.L.W.M. Heidbuchel, H.P.M. Freihofer, A.M. Kuijpers-Jagtman: Early secondary bone grafting of alveolar cleft defects. A comparison between chin and rib grafts. J Cranio-Max.-Fac. Surg. 18 (1990) 201

Bosker, H., L. v. Dijk: Het bottransplantaat uit de mandibula voor herstel van de gnathopalatoschisis. Ned. Tijdschr. Tandheelk. 87 (1980) 383

Boyne, P.J., N.R. Sands: Secondary bone grafting of residual alveolar and palatal clefts. J. Oral Surg. 30 (1972) 87

Bronner-Fraser, M.: Experimental analyses of the migration and cell lineage of avian neural crest cells. Cleft Palate J. 27 (1990) 110

Burkhardt, R.: Präparative Voraussetzungen zum klinischen Histologie des menschlichen Knocchenmarkes. Blut 14 (1966) 30

Burwell, R.G.: Studies in the transplantation of bone treated composite homograft-autograft of cancellous bone; An analysis of inductive mechanisms in bone transplantation. J. Bone Joint Surg. 48B (1966) 532

Cullum, P.E., D.E. Frost, T.B. Newland, T.M. Keane, M.J. Ehler: Evaluation of hydroxylapatite particles in repair of alveolar clefts in dogs. J. Oral Max.-Fac. Surg. 46 (1988) 290

Demas, P.N. G.C. Sotereanos: Closure of alveolar clefts with corticocancellous block grafts and marrow; A retrospective study. J. Oral Max.-Fac. Surg. 46 (1988) 682

El Deeb, M.E., J.E. Hinrichs, D.E. Waite, C.L. Bandt, R. Bevis: Repair of alveolar cleft defects with autogenous bone grafting: periodontal evaluation. Cleft Palate J. 23 (1986) 126

El Deeb, M.E., B.B. Horswell, D.E. Waite: A primate model for producing experimental alveolar cleft defects. J. Oral Max.-Fac. Surg. 43 (1985) 523

Enemark, H., S. Sindet-Pedersen, M. Bundgaard: Long-term results after secondary bone grafting of alveolar clefts. J. Oral Max.-Fac. Surg. 45 (1987) 913

Freeman, E., A.R. Ten Cate, J. Dickinson: Development of a gomphosis by tooth germ implants in the parietal bone of the mouse. Arch. Oral Biol. 20 (1975) 139

Freihofer H.P.M., A.M. Kuijpers-Jagtman: Osteoplasty in the mixed-dentition combined with pre- and/or post-surgical orthodontic treatment. Presentation 4th Hamburg Int. Symp. Craniofacial Anomalies and Clefts of the Lip, Alveolus and Palate. Sept. 1987

Freihofer H.P.M., A.M. Kuijpers-Jagtman: Early secondary osteoplastic closure of the residual alveolar cleft in combination with orthodontic treatment. Suppl. J. Cranio-Max.-Fac. Surg. 17 (1989) 26

Glowacki, J.: Discussion. In: Kusiak, J.F., J.E. Zins, L.A. Whitaker (eds.) The early revascularization of membranous bone. Plast. Reconstr. Surg. 76 (1985) 515

Hall, B.K.: Tissue interactions and the initiation of osteogenesis and chondrogenesis in the neural crest-derived mandibular skeleton of the embryonic mouse as seen in isolated murine tissues and in recombinations of murine and avian tissues. J. Embryol. Exp. Morphol. 58 (1980) 251

Hall, B.K.: Earliest evidence of cartilage and bone development in embryonic life. Clin. Orthop. and Related Research 225 (1987) 255

Hall, B.K.: Evolutionary issues in craniofacial biology. Cleft Palate J. 27 (1990) 95

Hall, H.D., J.C. Posnick: Early results of secondary bone grafts in 106 alveolar clefts. J. Oral Max.-Fac. Surg. 41 (1983) 289

Harsha, B.C., T.A. Turvey, S.K. Powers: Use of autogenous cranial bone grafts in maxillofacial surgery; A preliminary report. J. Oral Max.-Fac. Surg. 44 (1986) 11

Horswell, B.B., M. El Deeb: Nonporous hydroxylapatite in the repair of alveolar clefts in a primate model; Clinical and histologic findings. J. Oral Max.-Fac. Surg. 47 (1989) 946

Jackson, I.T., G. Helden, R. Marx. Skull bone grafts in maxillofacial and craniofacial surgery. J. Oral Max.-Fac. Surg. 44 (1986) 949

Jackson, I.T., C. Pellet, J.M. Smith: The skull as a bone graft donor site. Am. Plast. Surg. 11 (1983) 527

Jackson, I.T., J.G. Vandervord, J.G. McLennan, F.B. Christie, J.C. McGregor: Bone grafting of the secondary cleft lip and palate deformity. Brit. J. of Plast. Surg. 35 (1982) 345

Kawamoto, H.K., P.C. Zwiebel: Cranial bone grafts and alveolar clefts. In: E.P. Caronni (ed): Craniofacial surgery. Little, Brown. Boston, Toronto (1985) 449

Koberg, W.R.: Present view on bone grafting in cleft palate (a review of the literature). J. Max.-Fac. Surg. 1 (1973) 185

Koole, R., H. Bosker, F. Noorman van der Dussen: Late secondary autogenous bone grafting in cleft patients comparing mandibular (ectomesenchymal) and iliac crest (mesenchymal) grafts. Presentation, 4th Hamburg Int. Symp. Craniofacial Anomalies and Clefts of Lip, Alveolus and Palate Sept. 1987

Koole, R., H. Bosker, F. Noorman van der Dussen: Late secondary autogenous bone grafting in cleft patients comparing mandibular (ectomesenchymal) and iliac crest (mesenchymal) grafts. Suppl. J. Cranio-Max.-Fac. Surg. 17 (1989) 28

Kuijpers-Jagtman, A.W., W.A. Borstlap, H.P.M. Freihofer, K. Heidbruchel: Early secondary bone grafting with chin grafts and rib grafts. Abstr. Sixth International Congress on Cleft Palate and Related Anomalies, Jerusalem 1989

Kusiak, J.F., J.E. Zins, L.A. Whitaker: The early revascularization of membranous bone. Plast. Reconstr. Surg. 76 (1985) 510

Le Lièvre, C.S.: Participation of neural crest-derived cells in the genesis of the skull in birds. J. Embryol. Exp. Morphol. 47 (1978) 17

Le Lièvre, C.S., N.M. Le Douarin: Mesenchymal derivates of the neural crest; analysis of chimaeric quail and chick embryos. J. Embryol. Exp. Morphol. 34 (1975) 125

Marx, R.E., R.I. Miller, W.J. Ehler, G. Hubbard, T.I. Malinin: A comparison of particulate allogeneic and particulate autogenous bone grafts into maxillary alveolar clefts in dogs. J. Oral Max.-Fac. Surg. 42 (1984) 3

Maxson, B.B., S.D. Baxter, K.W.L. Vig, R.J. Fonseca: Allogeneic bone for secondary alveolar cleft osteoplasty. J. Oral Max.-Fac. Surg. 48 (1990) 933

Nique, T., R.J. Fonseca, L.G. Upton, R. Scott: Particulate allogeneic bone grafts into maxillary alveolar clefts in humans; A preliminary report. J. Oral Max.-Fac. Surg. 45 (1987) 366

Noden, D.M.: The migration and cytodifferentiation of cranial neural crest cells. In: R.M. Pratt, R.L. Christiansen (eds): Current research trends in prenatal craniofacial development. Elsevier North Holland, New York (1980) 3

Paulin, G., P. Astrand, J.B. Rosenquist, L. Bartholdson: Intermediate bone grafting of alveolar clefts. J. Cranio-Max.-Fac. Surg. 16 (1988) 2

Sindet-Pederson, S., H. Enemark: Mandibular bone grafts for reconstruction of alveolar clefts. J. Oral Max.-Fac. Surg. 46 (1988) 533

Sindet-Pedersen, S., H. Enemark: Reconstruction of alveolar clefts with mandibular or iliac crest bone grafts; A comparative study. J. Oral Max.-Fac. Surg. 48 (1990) 554

Slavkin, H.C.: Regulatory issues during early craniofacial development: A summary. Cleft Palate J. 27 (1990) 101

Smith, J.D., M. Abramson: Membranous vs endochondral bone autografts. Arch. Otolaryngol. 99 (1974) 203

Stoelinga P.J.W., P.E.J.J. Haers, R.J. Leenen, R.J. Soubry, P.A. Blijdorp, J.H.A. Schoenaers: Late management of secondarily grafted clefts. Int. J. Oral Max.-Fac. Surg. 19 (1990) 97

Troxell, J.B., R.J. Fonseca, D.B. Osborn: A retrospective study of alveolar cleft grafting. J. Oral Max.-Fac. Surg. 40 (1982) 721

Turvey, T.A., K. Vig, J.M. Moriarty, J. Hoke: Delayed bone grafting in the cleft maxilla and palate; A retrospective multidisciplinary analysis. Am. J. Orthod. 86 (1984) 244

Urist, M.R.: Physiologic basis of bone graft surgery with special reference to the theory of induction. Clin. Orthop. 1 (1953) 207

Urist, M.R.: Isolation and characterization of bone morphogenetic protein in bone grafting; Biology and application. Plast. Surg. and Research Foundation of San Diego and The Bone and Joint Disease Foundation Course, (Dec. 4-6 1981)

Witsenburg, B.: The reconstruction of anterior residual bone defects in patients with cleft lip, alveolus and palate. A review. J. Max.-Fac. Surg. 13 (1985) 197

Witsenburg, B., H.P. Freihofer: Autogenous rib graft for reconstruction of alveolar bone defects in cleft patients. Long term follow-up results. J. Cranio-Max.-Fac. Surg. 18 (1990) 55

Wolfe, S.A., S. Berkowitz: The use of cranial bone grafts in the closure of alveolar and anterior palatal clefts. J. Plast. Reconstr. Surg. 72 (1983) 659

Zins, J.E., L.A. Whitaker: Membranous versus endochondral bone autografts: implications for craniofacial reconstruction. Surg. Forum Plast. Surg. (1976) 521

Zins, J.E.; L.A. Whitaker: Membranous versus endochondral bone: implications for craniofacial reconstruction. Plast. Reconstr. Surg. 72 (1983) 778

Chapter V

Ectomesenchymal bone grafting (mandibular symphysis) for alveolar cleft repair; Late results - a clinical and radiological follow-up study -

This chapter is an extended and edited form of an article which has been submitted for publication (Cleft Palate Craniofacial J.).

Chapter V

Ectomesenchymal bone grafting (mandibular symphysis) for alveolar cleft repair; Late results
- a clinical and radiological follow-up study -

V.1. Introduction

In ACR the anterior iliac crest is the traditional bone graft site (Rehrmann et al, 1970; Boyne and Sands, 1972, 1976; Koberg, 1973; Boyne, 1974; Witsenburg, 1985; Bergland et al, 1986; Witsenburg and Freihofer, 1990; Breier et al, 1992). In bone grafting history the pioneer of ACR (Von Eiselsberg, 1901) used a bizarre donor site, the distal phalanx of the little finger (Witsenburg, 1985).
Mowlem (1941, 1944, 1963) advocated the use of iliac crest bone for bone transplanting surgery. Schmid (1955) used it in baby clefts for alveolar cleft reconstruction.
The membranous calvarian bone in alveolar cleft surgery was introduced by Wolfe and Berkowitz (1983). Jackson (1983), Kawamoto and Zwiebel (1985) and Harsha et al (1986) favour its use, because of good maintenance of the volume and contour due to its architecture; the maintenance of volume by the faster revascularization was mentioned by Zins and Whitaker (1976, 1983) and Kusiak et al (1985). Also the reduction of operation time was pointed out (Wolfe and Berkowitz, 1983; Jackson et al, 1983; Harsha et al, 1986). The disadvantages - dural tears, severe haemorrhage, subdural haematoma, skull contour abnormalities - were reported by Jackson (1986) and Frodel et al (1993). Kortebein et al (1991) in accordance with Sadove et al (1990) registered a lower successrate (63%) of calvarian bone against 89.9% with iliac crest in ACR. Jackson et al (1986) stated that the quality and density of cranial bone were not optimal for ACR, thus contradicting their original favourable impression.
Bosker and Van Dijk (1980), advocated the use of mandibular symphysis bone for grafting the alveolar cleft because of embryological similarity. Later, Koole et al (1989), Freihofer and Kuypers-Jagtman (1989), Sindet-Pedersen and Enemark (1988, 1990), Borstlap et al (1990), Hoppenreys et al (1992), Witsenburg and Remmelink (1993) report-

Table 6: *clinical data of 57 cleft patients*

variables N=57	*gender distribution male:female*	*UCLP left-right*	*cleft palate vs non-cleft palate*	*mean and median age at ACR*	*pre-surgical orthodontics*	*previous bone grafts elsewhere*	*re-operation after mandibular graft*	*range follow-up in years*
UCLP 43	*32:11*	*33:10*	*25:18*	*mean: 13.95 median: 13.44*	*11*	*2*	*1*	*1.01-9.54 y mean: 4.18 y*
BCLP 14	*9:5*	*–*	*13:1*	*mean: 14.24 median: 14.21*	*8*	*–*	*3*	*1.65-8.66 y mean: 5.08 y*

variables N=20	gender distribution male:female	left-right	mean and median age at ACR range: 11.16-17.36	pre-surgical orthodontics		follow-up
				front alignment	front + expansion	
UCLP	15:5	16:4	mean 13.58 median 13.34	2	4	1.01-9.54 y mean: 5.54 y median: 5.85 y

Table 7: *clinical data of 20 UCLP-patients selected for ACR ≤17.5 years*

ed in favour of mandibular bone as grafting material in ACR.
The aim of this study is to present the results of the first group of Dutch cleft patients grafted with a mandibular symphysis graft by doctors Bosker and Van Dijk, oromaxillofacial (OMF) surgery department, "Martini Hospital", Groningen, the Netherlands.

V.2. Material and methods

V.2.1. Patients

The original patient sample investigated consisted of 57 consecutive cleft patients grafted between 1976 and 1987. All forms of alveolar cleft (N_{ac}=71) were reconstructed with mandibular symphysis bone. The genderdistribution, cleft type, age at bone grafting, presurgical orthodontic treatment and mean follow-up period are summarized in table 6.
Out of these 57 cleft patients 20 UCLP-patients with an unilateral complete cleft of lip, alveolus and palate were selected for a final evaluation of the *recipient* site. Additional criteria were: ACR before 17.5 years of age, no maxillary osteotomy in combination with ACR, no previous ACR (table 7). For the evaluation of the *donor* site however, all 57 patients were used.

V.2.2. Previous surgery

Previous treatment according to the Groningen University Hospital protocol: lipclosure at the age of 3 months (Le Mesurier or Millard) without closure of the anterior palate; palatal closure (Von Langenbeck) at the age of 10 months; in case of a small or average cleft, surgery in one stage, in wide clefts a two stage procedure: at 10 months the soft palate was closed and 6 months later the hard palate (Huffstadt et al, 1987).

V.2.3. Orthodontic procedures

An interceptive orthodontic treatment during pre-school-age was optional. Pre-school-age interceptive orthodontic treatment took place in 4 patients.
The pre-surgical orthodontic treatment and the indication for ACR were established by one of ten regional orthodontists (each for his own patients) who cooperated with the OMF surgery department. The postoperative orthodontic treatment was executed by the

same orthodontist. The applied orthodontic technique in the pre- or postsurgical situation was not studied.
Due to the later reported, but already existing controversy on preoperative expanding procedures (Boyne and Scheer, 1991) only a minority of the patients (n=6, 30%) had received pre-surgical orthodontic treatment. Pre-operatively a severe malposition of the anterior teeth had been corrected in 2/20 patients (10%). Simultaneously with anterior teeth alignment expansion of the lesser segment had been performed in 4/20 patients (20%). In 14 cases no orthodontic treatment had been started pre-operatively.

V.2.4. Pre-operative dental status

The dental age in respect to cuspid status can be summarized as follows: In 11 patients the cuspids were impacted at the time of ACR; 2/3 of the root formation was completed in 2 patients, in 9 patients the cuspids were fully formed, but at the time of surgery they were still covered by an intact mucoperiosteal layer. In 9 cases the canine tooth had already erupted at the time of ACR. In 13 patients a normal number of teeth were present in the cleft area, one patient showed hyperdontia, six showed agenesis of the lateral incisors.
The width of the cleft was classified pre-operatively as small in 7 patients, one patient showed a wide alveolar cleft, 12 clefts were judged as normal.

V.2.5. Surgical procedure

Approximately 8 weeks pre-operatively deciduous or hypoplastic teeth (n=6) adjacent to the cleft were removed in order to establish a sufficient amount of mucoperiosteal tissue in the cleft region. Hypoplastic permanent teeth (n=2) were removed during surgery.
ACR with mandibular bone was performed in general anaesthesia with endotracheal intubation. Antibiotic prophylaxis was given for 5 days, during surgery intra-venously, postoperatively orally.

Figure 22. *The size of the mandibular graft can vary considerably because of impacted canines, amount of bone needed and intrinsic shape of the chin region.*

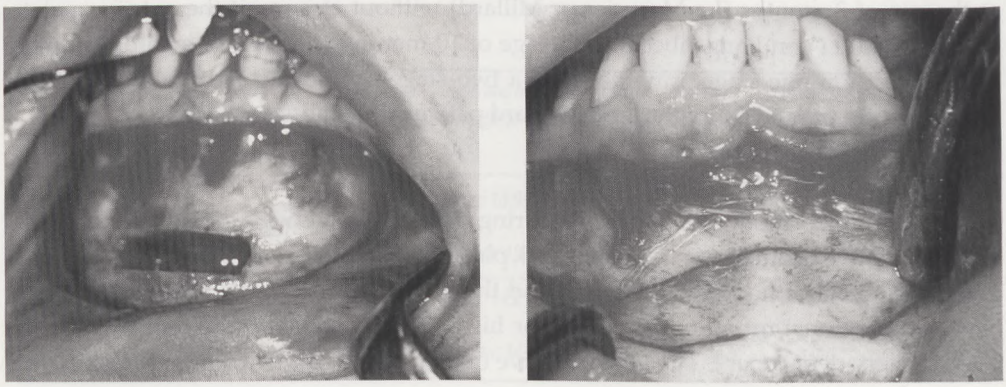

The alveolar cleft region was exposed in the usual manner: marginal incision and releasing incision in the buccal sulcus. Oral covering was created by elevating tissue out of the cleft. The nasal lining could not always be closed watertight. A single situation suture appeared sufficient in many cases. The maxillary alveolar process was roughened with an osteotome. By opening the outer cortex angioneogenesis is facilitated. Care was taken, not to damage impacted teeth nor the dental roots.
The symphysial bone graft was harvested 5 mm below the apices of the lower incisor teeth. The mandibular impacted canine tooth germ and/or the size of the alveolar cleft dictated the shape of the bone graft: rectangular or trapezoid (fig. 22). If needed, an additional amount of cancellous bone was harvested from the inside of the inferior lower border of the chin.
The corticocancellous bone graft was wedged into the alveolar cleft and the vestibular mucoperiosteal layer was constructed with transpositioned mucoperiosteal flaps or locally undermined mucoperiosteal flaps were raised. The use of these mucoperiosteal flaps was decribed later by Hall and Posnick (1983). Postoperative orthodontic treatment was started after about 3 months, i.e. after the bone graft was radiographically incorporated.

V.2.6. Methods of examination

The examination of the results of this group of 20 UCLP patients was done according to the methods described in chapter III. For convenience of the reader they are summarized once more.

1. Eruption and migration of teeth into the grafted area
2. Periodontal status
3. Morphology of the alveolar process and vestibular sulcus
4. Orthodontic status
5. Presence of oronasal fistulae
6. Examination of donor region
7. Radiological examination of ABR
   a. The interdental alveolar crest height (former cleft area)
   b. The status of the piriform aperture

Ad 1. Spontaneous and aided eruption of impacted teeth was evaluated by retrospective analysis of the patients' files and successive maxillary radiographs.

Ad 2. The periodontal status was examined on a routine clinical basis (by the same investigator: RK). The area of interest comprised the upper maxillary teeth from the first premolar on the cleft side to the first contralateral premolar.
The non-cleft maxillary teeth served as a control.
The PD was investigated with a periodontal probe (Hu Friedy).
BOP and the mobility of the involved teeth were investigated. According to Lindhe (1983)

and Lang et al (1990) they are valid indicators for periodontal health.
The attached gingiva was measured from the mucogingival junction to the free gingival margin with the Williams markings.
The colour of the gingiva was observed, because Haag (1977) thought a bluish-red discoloration of the mucosa to be indicative for increased bone resorption.
The cervical areas of the teeth adjacent to the former cleft were screened on external resorption, because bone grafting after eruption of the CAT may show more cervical resorption (Gerner et al, 1986).
So the following periodontal aspects of the maxillary teeth from 14 to 24 (if present) were monitored:

a. PD at the mesiofacial and distofacial surface
b. BOP
c. Mobility of the involved teeth
d. Width of attached gingiva
e. Colour of the gingiva
f. Cervical resorption of CAT

Ad 3. The morphology of the alveolar process and vestibular sulcus in the former cleft region was investigated as follows: the presence of scar tissue perpendicular to the alveolus and in the vestibular sulcus was noted.
The buccal sulcus was classified as physiological, shallow or scarred. The appearance of the alveolar process e.g. the buccal contour (concave or normal) was registered by palpation.

Ad 4. The results of the orthodontic treatment were registered with respect to the sagittal and vertical anterior tooth relation and the transversal molar relation. A palatal position of the premolars was noted. In addition the presence of permanent fixation wires of the anterior upper teeth was surveyed.
Special interest was paid to the relation of anterior permanent fixation and (root)resorption (Koole and Egyedi, 1990).
The angulation of all cleft adjacent teeth was determined.
In the majority of the cases study models were made for the orthodontic evaluation.
When the interrupted dental arch was reconstructed with a bridge or removable appliance it was noted and the intermaxillary relation was classified as if they were natural teeth, unless obvious compensations of a malocclusion had been obtained. Further investigations of the prosthetic reconstruction was not undertaken.

Ad 5. Patients were asked if there were functional (passive-active) oronasal fistulae for air and/or liquids. Then inspection and blowing test were done.

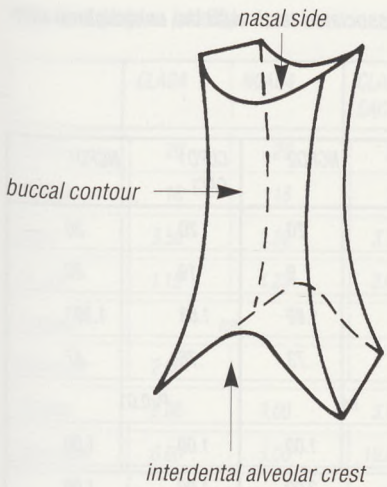

Figure 23.
Schematic drawing of three relevant bone graft resorption sites. Excavation at the nasal surface, lowering of the interdental alveolar crest and resorption at the buccal contour. The palatal side is not relevant in respect of resorption of the graft.

Ad 6. The condition of the bone donor site was checked in 57 patients on the following items:

a. Paraesthesia of the mental nerve.
b. Gingival clefts or adhesions in the anterior vestibulum.
c. Tooth vitality in the donor region.
d. Radiographical bone regeneration (evaluated on a X-OPT, sometimes ceph. X-ray).
e. The periapical region was screened on radiolucencies, the teeth on obliterations of the root canal.

Ad 7. Radiological examination ABR. The amount of ABR in the former cleft area was related to the length of the distal surface of the cleft-adjacent root (viz. fig. 8 and 9). This method of calculating the percentage of ABR is executed on a tracing of the semi-standardized occlusal X-ray (Van Hoeken, 1983; Koole et al, 1989). The mABR percentage, in respect of ACR and orthodontic treatment of the grafted alveolus, is used as an indicator for the relation: functional loading - bone resorption; at the same time it is an indicator for the quality of the graft.
On the OPT the caudal side of the piriform aperture at the cleft side was qualified as normal, slightly excavated or deepened.
In combination with the results of ad 3, three relevant possible bone graft resorption sites are evaluated radiographically and mathematically (fig. 23).

V.3. Results

Twenty UCLP-patients were reviewed on the before-mentioned seven topics to determine success of ACR.

Table 8: *periodontal findings in 20 UCLP-patients comparing cleft associated teeth with the contralateral non-cleft side*

Probing depth distofacial

	CLPD4	NCPD4	CLPD3 CAC	NCPD3	CLPD2 CALI	NCPD2	CLPD1 CACI	NCPD1
Count	20	20	20	20	20	20	20	20
Valid N	18	18	18	20	6	9	19	20
Mean	1.44	1.56	1.50	1.45	1.67	1.89	1.63	1.30*
St. dev.	.51	.51	.62	.51	.82	.73	.76	.47
P values	ns		ns		ns		P<0.01	
Minimum	1.00	1.00	1.00	1.00	1.00	1.00	1.00	1.00
Median	1.00	1.00	1.00	1.00	1.50	2.00	1.00	1.00
Maximum	2.00	2.00	3.00	2.00	3.00	3.00	3.00	2.00

CLPD= cleft side probing depth distofacial aspect
NCPD= non cleft side probing depth distofacial aspect
1, 2, 3, 4= central, lateral incisor, cuspid, bicuspid
ns= not significant
CAC= cleft associated canine
CALI= cleft associated lateral incisor
CACI= cleft associated central incisor

Probing depth mesiofacial

	CLPM4	NCPM4	CLPM3 CAC	NCPM3	CLPM2 CALI	NCPM2	CLPM1 CACI	NCPM1
Count	20	20	20	20	20	20	20	20
Valid N	18	18	18	20	6	9	19	20
Mean	1.56	1.56	1.83	1.65	1.33	1.56	1.37	1.40
St. dev.	.62	.62	1.15	.97	.52	.73	.50	.60
P values	ns		ns		ns		ns	
Minimum	1.00	1.00	1.00	1.00	1.00	1.00	1.00	1.00
Median	1.50	1.50	1.00	1.00	1.00	1.00	1.00	1.00
Maximum	3.00	3.00	5.00	5.00	2.00	3.00	2.00	3.00

CLPM= cleft side probing depth mesiofacial aspect
NCPM= non cleft side probing depth mesiofacial aspect
1, 2, 3, 4= central, lateral incisor, cuspid, bicuspid
ns= not significant
CAC= cleft associated canine
CALI= cleft associated lateral incisor
CACI= cleft associated central incisor

Attached gingiva (width)

	CLAG4	NCAG4	CLAG3 CAC	NCAG3	CLAG2 CALI	NCAG2	CLAG1 CACI	NCAG1
Count	20	20	20	20	20	20	20	20
Valid N	18	18	18	20	6	9	19	20
Mean	3.56	3.28	3.72	4.10	3.67	5.22	3.37	3.82
St. dev.	1.15	1.23	2.65	1.59	3.50	1.64	2.01	1.31
P values	ns		ns		ns		ns	
Minimum	2.00					2.00		1.00
Median	3.00	3.00	3.00	4.50	2.50	5.00	3.00	4.00
Maximum	6.00	5.00	10.00	7.00	10.00	7.00	7.00	6.00

CLAG= cleft side attached gingiva
NCAG= non cleft side attached gingiva
1, 2, 3, 4= central, lateral incisor, cuspid, bicuspid
ns= not significant
CAC= cleft associated canine
CALI= cleft associated lateral incisor
CACI= cleft associated central incisor

V.3.1. Examinations

Ad 1. Cuspid eruption.
In all 11 UCLP-patients the relevant information on the eruption of the cuspid could be obtained from the patient's files and successive maxillary X-rays. One impacted cuspid was transplanted during ACR, six cuspids had erupted spontaneously into the bone grafted area.
Due to delayed eruption surgical exposure and/or orthodontic traction was performed for 4 cuspids. One enlarged dental follicle was observed.

At the time of evaluation 18 cuspids were present, the transplanted cuspid was lost six month after surgery, another cuspid was extracted during follow-up period because of dental decay.

Ad 2. Periodontal status.
First we will deal with the localization of the cleft with respect to the lateral incisors. Preoperatively in 8/20 patients the lateral incisors were present. The cleft was situated mesially of the lateral incisor in 7/8 patients and in 1/8 patients the cleft was at the distal aspect of the cleft associated lateral incisor (CALI). During surgery 2 hypoplastic CALI had to be removed. The grafted cleft was situated mesially of the lateral incisor in 5 patients and in one patient the right-sided cleft was distally of the lateral incisor.
The periodontal results at follow-up are listed in table 8.
Severe pathological conditions were not encountered.

results	UCLP-patients N=20	
closure oral layer	physiological	shallow
local mucoperiosteal flaps n=11 (55%)	6 54.5%	5 45.5%
	mABR: 6.9%	
transpositional mucoperiost. flaps n=9 (45%)	4 44.4%	5 55.6%
	mABR: 15.8%	
finger flaps n=0	–	–
total	10 mABR: 13.0%	10 mABR: 8.8%

Table 9: *Influence of flap design on vestibular sulcus depth in 20 UCLP-patients*

Not much difference in appearance of the vestibular sulcus using local periosteal flaps or transpositional flaps (mABR= mean alveolar bone resorption).

Generally speaking the periodontal status of the cleft adjacent teeth as compared with the contralateral sites was very satisfactory. Paired sampled t-tests of the different probing sites showed only one significant difference: in 18 cleft associated central incisors (CACI) the mPD at the distofacial aspect (1.63mm) was significantly deeper than at the same incisor on the non-cleft side (n=20, 1.30mm, P<0.01) (maximum PD on the cleft side was 3mm versus 2mm on the non-cleft side).

Also the width of the attached gingiva, even though the smallest measurement found was only 1 mm, did not differ significantly from the non-cleft side. It must be said however that the differences noted between the two sides were always in favour of the non-cleft one.

BOP around the cleft associated teeth (CAT), was present in 36% of the patients. The bleeding incidence was not different from the non-cleft related teeth (1:3.4). One patient with pockets (3-5mm) showed moderate BOP in all tested maxillary teeth.

The mobility of the CAT was not different from non-cleft related teeth.

The bluish-red colour of the gingiva, as a sign of bone resorbing inflammation (Haag, 1977) was not observed. Cervical external root resorption was not seen either. Apical resorption, however was registered in 4 patients, it was not seen bilaterally. It did not occur at the canine teeth.

Summarizing, the investigated periodontal aspects, concerning the CAT - PD mesiofacial, distofacial, - BOP, - mobility, - width of the attached gingiva, - colour and cervical root resorption were not different from the non-cleft contralateral teeth. The only exception were the PD on the distofacial aspect of the central incisors, the cleft sided distofacial pocket being deeper. The periodontal variables concerning the other teeth showed no significant cleft - non-cleft difference.

diverging teeth adjancent to cleft / cleft	≤30° alveolar process		30-45° alveolar process		≥45° alveolar process	
	concave	normal	concave	normal	concave	normal
left (N=16)	2	10	0	4	0	0
right (N=4)	0	2	0	2	0	0
total (N=20)	2	12	0	6	0	0

Table 10: *Divergency of cleft adjacent teeth and morphology of the alveolar proces*

There is no manifest relation in this sample, between shape of the alveolar process and root parallelling

N=20	C	I_2 (N=6)	I_1	molar cleft side
normal or acceptable anterior relation	7	4	10	14
end to end relation	8	–	5	–
anterior open bite	–	–	3	–
vertical overbite	–	–	1	–
reversed relation	5	2	5	–
reversed relation in molar region	–	–	–	6

Table 11: *Orthodontic relation of cleft associated teeth and molar relation in 20 UCLP patients*

In cases with prosthodontic reconstructions (n=4) the orthodontic evaluation was done as with natural teeth, unless severe compensations had taken place.

Ad 3. Morphology of the alveolar process and vestibular sulcus.

Local (n=11) and transpositional mucoperiosteal flaps (n=9) were used for vestibular closure.

Extremely scarred vestibular sulci were never encountered.

The buccal sulcus of the former alveolar cleft region was registered as physiological in 10/20 patients. Minor scars, perpendicular to the alveolar process in the cleft area in combination with a slightly shallow sulcus were noticed in the remaining 10 patients.

The relation between the local flap design and buccal sulcus depth is summarized in table 9. There is however no strong correlation between ABR or buccal contour of the alveolar process and method of oral closure; mABR 8.8% in the shallow sulcus group (range 0-25%); in the physiological vestibulum group mABR is 13,0% (range 0-42.3%).

As can be inferred from table 9 the effects of local flap design as to a shallow or normal sulcus seem to show a haphazard pattern.

The angulation of the CAT and its effect on the buccal contour of the alveolar process can be inferred from table 10.

The shape of the alveolar process in cases with an angulation below 30° was normal or convex except in two patients, in one of whom the dental arch had been reconstructed with a fixed bridge.

Figure 24. Uninterrupted dental arch with an acceptable crossbite in the former alveolar cleft region.

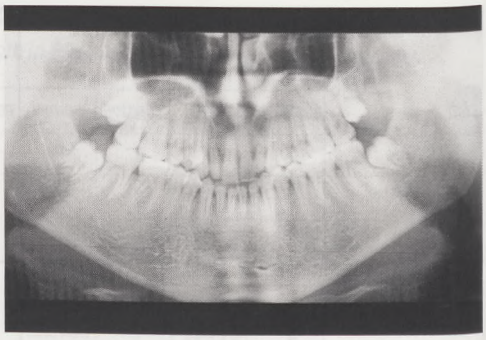

Figure 25. Minor radiographic scar in the donor area.

Ad 4. Orthodontic status.

At the time of the evaluation 3 patients were in the final stage of orthodontic treatment. The patient material however was not divided according to Amanat and Langdon (1991) into a group where the canine was in its final position and a group where the orthodontic treatment was still in progress. We do not expect a different outcome of the orthodontic parameter by the orthodontic finalizing treatment.

The orthodontic results of the anterior teeth including the first molar positions are depicted in table 11.

Severe palatal malpositions of the bicuspids were not seen.

The post-surgical orthodontic treatment had been performed by the patients' own regional orthodontist in 19 cases.

One person desired no orthodontic treatment after ACR and showed a minor anterior open bite with slight retrusion and a minor irregularity of the front teeth.

Ten of 20 patients developed a normal anterior tooth relationship due to orthodontic treatment after ACR.

A class II front tooth relation was seen in 1/20. Further orthodontic evaluation however showed 3/10 acceptable crossbites in the former cleft regions (fig. 24).

Maxillary retrognathia was seen in 5/20 patients.

A combination with an anterior open bite was present in 3/20. Summarizing, in most cases (16/20 - 80%) the dental arch could be closed by the orthodontic treatment after ACR, although limitations in the results had to be accepted (cross bites, end to end anterior tooth relations).

Ad 5. Oronasal fistulae.

Pre-operatively 7 patients complained of their oronasal fistulae. At the time of evaluation two oronasal fistulae were present. The only complaints were about "active" air leakage (by pressure). In one of these 2 patients there was a shift with no fistula pre-operatively to an oronasal fistula postoperatively. The successrate of fistula closure is then 6/7 (=85.7%)

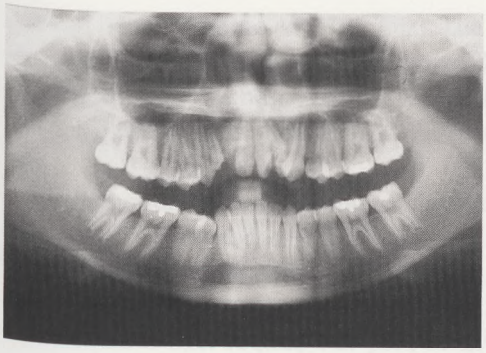

Figure 26. *X-OPT showing an apical trauma to the 43 after a bicortical graft for ACR in a BCLP-patient.*

and the complication rate (as to fistula "production") 1 out of 13 = 7.7%.

Ad 6. Findings in the donor area.
The findings of the selected 20 UCLP-patients at the donor site are favourable. There were no patients with complaints, however one showed some adhesions in the vestibulum, 2 teeth (two patients) showed avitality and a periapical granuloma (Ø 2 and 5 mm). Endodontic treatment had to be arranged.
Bone regeneration of the donor site was seen in 95-100% of 18 patients. Two patients showed a radiographic scar in the symphyseal area (fig. 25). Radiographic pulpobliterations were seen in two teeth.
In the total patient sample (n=57), bone grafts (n=61, including 4 reoperations) taken from the chin region, produced one mental nerve injury (bilateral cleft) and three damaged apices (fig. 26). However this was not noted during surgery. The endodontic treatment was postponed, the mental nerve injury resulted in a persistent paraesthesia.
At the follow-up investigation 12 teeth showed avitality, a peri-apical granuloma (Ø 2-12mm) was seen in 4 patients. Fourteen (4,1%) pulpobliterations were noticed on the X-OPT. All lower cuspids had erupted, no damage to- nor eruption disturbances of impacted lower anterior teeth (due to bone graft harvesting) were noted.
The periodontal status of the anterior lower teeth at the follow-up investigation showed no gingival clefts, but in the anterior vestibulum of six patients some small adhesions could be noted, they were of no clinical importance.
In 30.4% of all patients the bone regeneration in the donor area was incomplete. A radiolucency of 1-3mm in the chin region could be seen on the X-OPT. In 9 of these 17 cases the mandibular bone graft was harvested for bilateral ACR.
Growth disturbances of the chin, as a possible late complication could not be established.

Ad 7. Measurement of ABR.
The results are presented in figure 27; the ABR at the interdental alveolar crest height ranged from 0% to 25% with one exception. In 16 patients with a closed dental arch, seven

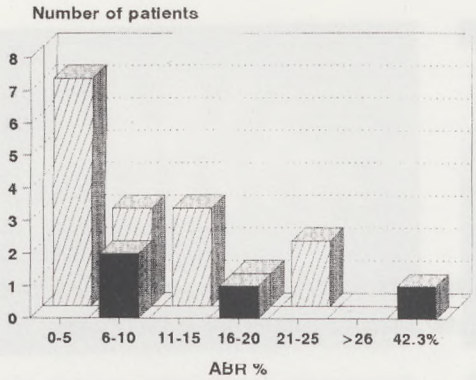

Figure 27. *Alveolar Bone Resorption (ABR%) in 20 UCLP-patients grafted with chin bone. First row: interrupted dental arch n=4; Second row: uninterrupted dental arch n=16.*

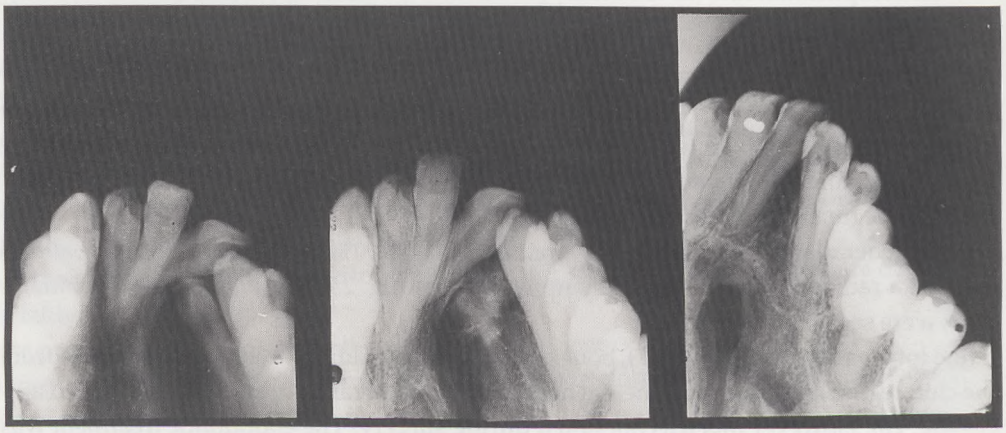

Figure 28a. *Successive maxillary X-ray's. No measurable ABR after completion of the orthodontic treatment. CALI removed during surgery. Tracing made with the use of a magnifier Heliocontraster.*

Figure 28b. *Interrupted dental arch with maximum ABR (42.3%).*

showed no measurable ABR (fig. 28a). The mean ABR (mABR) in the uninterrupted dental arch (n=16) is 8.7%, in the interrupted dental arch (n=4) mABR= 19.9%. The maximal ABR (42.3%) was seen in a patient reconstructed with a Maryland bridge, 4.5 years after ACR (fig. 28b). In the 3 remaining interrupted dental arch cases the ABR rate was below 20%.

The prosthodontic closure of the residual gap in the dental arch did not represent a failure of surgery or of orthodontic treatment, but was mainly the expression of congenital (n=6) or acquired hypodontia (n=8).

Hyperdontia pre-operatively was seen in 1/20 patients, initially 13/20 showed normodontia in the cleft region, but pre- or intra-operatively hypoplastic malformed teeth adjacent to the cleft were removed.

Radiographic analysis of the morphology of the grafted area at the piriform aperture. On the X-OPT the caudal part of the piriform aperture at the cleft side was examined. A normal symmetrical aspect was present in 8 patients. A slight depression was noticed at the cleft side in comparison with the normal side in 5/20 (fig. 29). In 7/20 cases a moderate excavation in the aperture was seen. In 4/20 former cleft regions teeth were absent.

The presence of a three-dimensional resorption (at the interdental-, buccal- and nasal-side) can result in a diabolo shaped alveolar process. This (moderate) diabolo phenomenon was observed in one patient. An example of a diabolo shaped "demodelled" alveolar process is presented in figure 30, this patient however was not part of the investigated 20 UCLP patients.

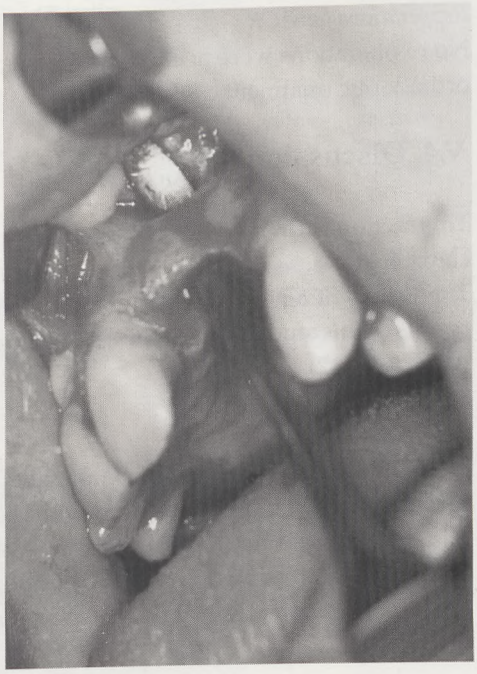

Figure 30. *Intra-operative view of a diabolo-shaped remodelled bone graft due to cervical-, buccal- and nasal-side resorption. The exposure was performed to improve morphology of the alveolar process prior to construction of a bridge.*

Figure 29. *X-OPT on the left side a slight depression is seen in the piriform aperture (former cleft area).*

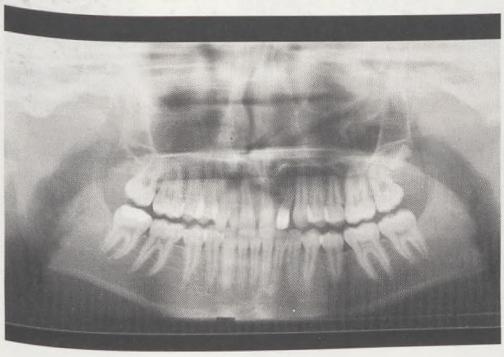

V.3.2. File analysis

Complications

A major haematoma in the *donor* region with glottic edema was seen in one patient, observation in the intensive care unit was required. In the *grafted* area no major complications were encountered. Immediate postoperatively in one case a haematoma and later, a minor postoperative dehiscence was seen.

Postoperatively in another 3 patients minor wound dehiscences were seen. Secondary wound healing under an iodoformvaseline gauze followed rapidly. Major bone loss was never observed and in these 4 cases only minimal bone loss was present. Cervical root resorption after bone grafting is a rare complication. The incidence is higher if the grafting takes place after eruption of the cuspids (Gerner et al, 1986; Enemark et al, 1987). In fact, in 9/20 cases the ACR took place after the eruption of the CAC. In addition 6 CALI were also present in the surgical area, nevertheless no cervical root resorption was seen.

A major complication in orthodontic treatment is apical root resorption (Kaplan, 1989) the incidence in cleft patients can be higher because of the complexity of the treatment. In this cleft patient sample, treated by regional orthodontists the canine showed no apical resorption. The root of the central/lateral incisor was reduced in length by apical resorption due to orthodontic treatment in 4/20 patients (20.0%). Permanent fixation was present in 3 of them.

One patient showed apical resorption without permanent fixation.

Reoperations for ACR

No re-operations were needed, the bone grafts did not resorb to a subcritical mass so the orthodontic treatment could continue without interruption.

V.4. Discussion

This section is divided in the same paragraphs as presented in the "results", for reading convenience.

The results of ten studies on ACR and iliac crest bone grafts will be compared with the results of this study and with the results reported in the literature on chin bone grafts and ACR (table 12).

Preliminary remark

The status quo of some clinical parameters at the follow-up investigation (e.g. periodontal condition) could not be compared with the one at the time of surgery. For the purpose of this study we did not consider this to be of major importance; with respect to the further investigations (chapter VI and VII) on iliac crest bone grafts this should be taken into account. In chapter III more has been said about this problem.

Table 12. *Comparison of relevant data obtained from the literature*

cleft region author(s)	donor site	cuspid status	periodontal status	orthodontic status	height alveolar crest grafted area	alveolar process morphology	oronasal fistula	other remarks
Troxell et al (1982); N=30; UCLP 26 (r-9 l-17) mean age: 13.2 y follow-up: 2-26 mth m:f= 14:16	iliac crest	impacted: 19-63% erupted: 18/19 95% eruption	mean probing depth: 3mm width attached gingiva: 4mm	pre-op: 73% orthod. post-op: 3/30 interrupted arch no details on dental arch relation	29/30 bony bridge no % mentioned	no data presented	pre-op: 28 (93%) post-op: 2 fistula remained	short term follow-up
Hall and Posnick (1983); N=83; UCLP 60 (r-40 l-20) mean age: 12.4 y follow-up: ? m:f= 61:39	iliac crest	pre-op UCLP: 60% impacted pre-op BCLP: 65% impacted post-op no info about eruption	no data on probing depth	pre-op: orthod. expansion no further details	"firm bony alveolus" no details	no data: mucoperiosteal flaps used	98% closure	pre-teen pat. do better, short post-op follow-up
Turvey et al (1984); N=24 UCLP 15 (r-5 l-10) mean age: 11.6 y follow-up: 19 y m:f= 13:11	iliac crest	17/24 impacted 16/17 erupted surg. exp. 1/17 11 cuspids moved in the graft orthodontically	no periodontal problems reported no cervical root resorption	50% closed dental arch	31/33 normal aspect height: equal to the limbus alveolaris of the adjacent teeth	normal 33/33 12/24 – normal pontics in prosthetic closure	100% closure buccally 4/24 palatal fistula	every pat. is candidate for alveolar cleft repair
Semb et al (1986); N=417; UCLP 249 (r-? l-?) mean age: 11.5 y follow-up: > 1 y m:f= 268:149	iliac crest	± 50% impacted ± 35% spont. eruption 15% surgical exposure	no periodontal data in detail 3% cervical root resorption	closed dental arch in 90%	≥90% alveolar crest height in 90% of the cleft 10% low or no bony bridge	mucoperiosteal flaps no further details	no reports on fistula closure	maxillary growth not influenced by bone grafting
Bergland et al (1986); N=378; UCLP 294 (r-? l-?) mean age: 11.6 y follow-up: ≥ 1 y m:f= 218:122	iliac crest	15% surgical exposure	no thorough periodontal investigation 3% cervical root resorption	90% closed dental arch; no details on relationship	90% had normal bone height level, 7% low level, 3% failure	normal alveolar proces mucoperiosteal flaps used	no reports on fistula closure	after eruption of the canine the results are less favourable
Enemark et al (1987); N=224; UIC 29; UCLP 151 A:94-10y; B:72-13.1 y; C:58-16y follow-up: ≥ 4 y m:f= 153:71	iliac crest	cuspid retention 36% in UCLP, 15% in BCLP	no periodontal remarks; width attached gingiva favourable; cervical root resorption in B+C 17/130	A: 87%, B:75%, C: 50% closed dental arch vertical growth disturbed?	without attached gingiva more bone resorption ($p < 0.0005$)	mucoperiosteal flaps no data	no reports on fistula closure	A: grafting before eruption c. B: after eruption c. C: tertiary bone grafting
Paulin et al (1988) NA=37; NB=30 UCLP 55 mean age: ≤ 13 y A=8-13 y; B=10-20 y follow-up: ? m:f ?	75% iliac crest 25% tibia	pre-op A: 93% impacted,B:29,4% impacted; post-op: spont. erupted A: 93%; surg. exp. 10%; 5x foll. cysts	no periodontal data root resorption not reported	pre: most in orthodontic expansion. post: A: 93% B: 47% closed dental arch	investigated on 48 clefts – closed dental arch A: height >90%: 63%; 90-75%:37% B: height 90-75%:66%. Interrupted arch height <75%:39%	normal contour; mucoperiosteal-flaps used	pre-op: 58 (72.5%) 100% closure	A: intermediate grafting (after I2 before C eruption). B: grafting after eruption of cuspid

cleft region author(s)	donor site	cuspid status	periodontal status	orthodontic status	height alveolar crest grafted area	alveolar process morphology	oronasal fistula	other remarks
Stoelinga et al (1990); N=34 UIC 8; UCLP 20 mean age: 10.24 y follow-up: 6.6 y m:f= 22:12	iliac crest	impacted laterals and cuspids erupted except one 1 surgically exposed (2.1%)	probing depth 2-3mm in 33/40 cleft teeth one cervical root resorption	pre-op: none orthodontic expansion. Post-op: 41% closed arch + norm. relation 38% interrupted arch; 25% maxil. retrognathia	u-shaped disuse atrophy in alveolar crest 7/40 normal: 26/40; 12/40:20%; 2/40: 40% alv. bone resorption	no data on contour; mucoperiosteal flaps used	all closed after surgery	long term follow up; 38% interrupted arches corrected by uni lateral osteotomy; 25% retrognathia needed LeFort I advanc.
Amanat and Langdon (1991); N=34 (A=< 144:28, B=14-16:2, C=>16:4) mean age: 11.6 y follow-up: 22 mth m:f=23:11	iliac crest	22 impacted at time of surgery spontaneous eruption: 21 1 surgical exp. (2.1%)	no special data on p.d. normal width of attached gingiva one cervical (3.3%) root resorption	pre-op: front region; sometimes: expansion post-op: closed dental arch 80% interruped arch 20%	normal/near normal: 83% low level III: 6.6% failure: 10%	normal buccal contour; mucoperiosteal flaps used	no reports on fistula closure	
Breier et al (1992) N=90; UIC 11; UCLP 40 mean age: 11.6 y follow-up: > 1 y m:f= 48:42	iliac crest	32% spontaneous eruption; 46% surgical exposure and guidance	62%≥ 3mm attached gingiva no periodontal problems reported	53/90 norm. dental arch relation uninterrupted (crossbite incl) 23/90 interrupted arch, 14/90 surg. correction dent. arch rel.	66-100% height: 84%; 33-66% height: 15%; failure: 1%	normal contour, 61% normal vestibular sulcus; 39% shallow sulcus mucoperiosteal flaps used	no reports on fistula closure	no growth disturbances in the maxilla; mimic muscle activity better, when cleft is closed
Koole (1994) N=20 UCLP 20 (r-4 l-16) mean age: 13.4 y follow-up: 1-9 y m:f= 15:5	mandibular symphysis graft	9 present at surgery; 11 impacted; post-op: 6/10 (60%) spontaneous eruption 4 (40%) surgical exposure; 1 fol. cyst formation	probing depth (1-2mm) no periodontal problems (one pat. 4mm); normal width of attached gingiva	33% pre-op. orthod.; post-op: closed dental arch: 16/20; 12/20 norm. dent. arch; 3/20 ant. open bite; 5/20 max. retrognath.	16/20 uninterrupted arches: normal (20%) interrupted arches 4/20: 3: normal (<20%) one case: 42.3% resorption	normal contour, except two; parallelling cleft adjacent teeth; all mucoperiost. flaps; buccal sulcus: 50% normal - 50% shallow	present 7 preop. closure: 6 87.5% production: one 1/13= 7.7% postop.: 2 fistula present (10%)	25% retrognathia Le Fort I procedure. 1 (5%) non-cleft related dysgnathia. findings in donor site (n=57) 1 hypaesthesia 12 endodontic treatment
Sindet-Pederson and Enemark (1990) N=20 UCLP 20 mean age: 9.1 y follow-up: 19 mth m:f= ?	mandibular symphysis compared with iliac crest	15% cuspid retained after surgery at follow-up	no pathological pockets, but 25% had insufficient width of attached gingiva; no cervical root resorption	pre-surgical expansion is not completed. Still in progress.	normal in all cases, but still in orthodontic treatment	normal morphology of the alveolar process; mucoperiosteal flaps used	no reports on fistula closure	no pain donor site; good alternative to iliac crest
Borstlap et al (1990); N=22; UCLP: 22 mean age: 9.5 y follow-up: > 1 y m:f= 7:3	mandibular symphysis compared with rib	all impacted at surgery post-op: 5% surgical exp. follicular widening (40.0%)	no periodontal "problems" reported; width attached gingiva normal	still in progress at evaluation	bone resorption 0-25%: 68.4% pat. 25-50%: 31.6% pat.	normal, mucoperiosteal flaps used	100% closure	mandibular bone graft do better than rib grafts!

cleft region author(s)	donor site	cuspid status	periodontal status	orthodontic status	height alveolar crest grafted area	alveolar process morphology	oronasal fistula	other remarks
Sindet-Pedersen and Enemark (1988) N=28 UIC 25; UCLP 3 mean age: 10 y follow-up: 8 mth m:f= 14:14	mandibular symphysis	20 impacted c. 100% eruption	no pocket depth ≥ 3mm; 4/28 insufficient width of attached gingiva, no cervic. root resorption	still in progress, no information on outcome	normal/near normal; 100%	normal contour no scars in vestibulum	no reports on fistula closure UIC- no fistula?	no donor site complications increase of use in future
Bosker and Van Dijk (1980); N=26; UCLP 18 (r-4 l-14) mean age: 11.3 y follow-up: ≥ 6 mth m:f= ?	mandibular symphysis	100% eruption	no pathological effect on periodontium cleft adjacent teeth	no data reported	normal/near normal height in alveolar crest in all cases	normal contour	no reports on fistula closure	symmetry piriform aperture one hypaesthesia mental nerve
Freihofer et al; (1993); N=296 UCLP=165; BCLP=131 (clefts) mean age: follow-up: >1y m:f=	mandibular symphysis n=59, rib n=72; illiac crest n=123; during osteotomy n=42 other n=80	early SACR: n=93 cuspid impacted late SACR: n=42 cuspid erupted TACR: n=51 no reports on % C eruption	no reports on periodontal status	no data reported expectation that prae-/post-operative orthodontics have no influence on ACR	chin bone: >90% alveolar crest height over 50% rib=83% alv. crest: >50% iliac crest: 46% alv. crest: >50%	no data reported	20% oro-nasal fistula persisted	failure classified as oronasal fistula open and >50% ABR; 17 different surgeons TACR extremely difficult; chin graft do better
Witsenburg and Remmelink (1993) N=40; UCLP= mean age: 13.9y follow-up: 5.0y 1.0y-10.6y m:f=30:10	iliac crest n=26 mandibular symphysis n=14	no reports on cuspid status and eruption	no reports on periodontal status	no details on orthodontic outcome	28/40 normal or near normal alv. crest (≥2/3 alv. crest height) 3/40 failure eg ≤ 1/3 alv. crest height	no details on contour and scars; only mucoperiosteal flaps were used	3/31 fistula persisted after ACR. Fistula closure 90.3%	grafting <12 y (23/40) best results. Radiographic results of mandibular graft slightly better

UIC= unilateral incomplete cleft (hard palate intact); BCLP can be calculated: N – (UCLP+UIC) = BCLP

V.4.1. Methods

The methods used in this follow-up investigation are routine clinical and radiological methods, reproducible and valid.
The mathematical measurements on the semistandardized X-rays were performed by an uninvolved dentally qualified medical student.

V.4.2. Clinical and radiological examinations

V.4.2.1. Cuspid eruption and dental status

Comparing the results of the eruption of the impacted cuspid at the previous cleft region, the eruption incidence (table 7) seems average (6/10) (60.0%). Troxell et al (1982) reported 95% spontaneous eruption of the cuspid, Enemark et al (1985) reported 21% retention of

canines, later Enemark et al (1987) noted a retention of canines in 36%. Hinrichs et al (1984) reported 56% surgical exposure whereas 10% were reported by Paulin et al (1988). El Deeb et al (1982) mentioned 56% surgical uncovering in UCLP and 63% surgical uncovering in BCLP-patients. Bergland et al (1986) reported 15% surgical uncovering and orthodontic guidance. Breier et al (1992) mentioned 32% spontaneous eruption of the cuspid. Surgical exposure of the retained canine in the Groningen patients was needed in 4/10 (40%).
There does not seem to be a significant difference between the ectomesenchymal graft and traditional grafts as far as cuspid eruption is concerned.
We found one cyst (10.0%) around the impacted cuspid, the incidence however, of follicle pathology differs widely and may not be related to the origin of the graft. Borstlap et al (1990) reported 40.9% widened follicles in their UCLP-group transplanted with chin bone.

With respect to the CALI it is known from the literature that 52% is congenitally missing and 24% is hypoplastic (Vd Wal, 1993). In the Groningen patients in 30% the CALI was missing. Supernumerary teeth in the cleft region are rare. The situation of the cleft varies between cuspid - lateral incisor and lateral incisor - central incisor. In our patients the cleft was situated mainly mesially of the CALI. Although the number is small, it is a remarkable fact.

V.4.2.2. The periodontal status

The intra-individual comparison of the periodontal status of the CAT, showed one statistically significant difference (distofacial mPD of the CACI 1,63 vs 1,30 mm ($P<0.01$). Mesiofacial mPD of the CAC in our group was 1.80mm. Hinrichs et al (1984) and El Deeb et al (1986) reported a 2.0mm mesiofacial mPD of the CAC. Ramstad (1989) found a mesial mpd of 2.41 mm of the CAC, but prosthetic appliances were used in this group of patients. Brägger et al (1985, 1992) found similar data. The periodontal results therefore are comparable to the figures in periodontal follow-up reports emerging from other cleft palate centres (Hinrichs et al, 1984; Brägger et al, 1985, 1992; El Deeb et al, 1986; Ramstad, 1989).
The use of mucoperiosteal transposition flaps as advocated by Hall and Posnick (1983), Quarta and Koch (1985, 1989), Enemark et al (1985, 1987), Bergland et al (1986), Krantz Simonsen (1986) gives satisfactory periodontal results.
The width of attached gingiva in this group of cleft patients is favourable and in accordance with others who use local mucoperiosteal flaps. The difference between the attached gingiva around the CACI (3,37 vs 3,80 mm) is of minor importance and probably due to the releasing incisions in that area when raising the mucoperiosteal flaps. BOP and mobility of the CAT did not reveal differences. The periodontal health state of the cleft side in this patient sample was not significantly different from the contralateral side, this is in accordance with Brägger et al (1985, 1992) and El Deeb et al (1986). Again, no advan-

tage or disadvantage of the donor site as far as periodontics is concerned.
In this patient sample there was no correlation between bluish-red colour of the gingiva and amount of ABR of the interdental alveolar crest of the grafted cleft alveolus as suggested by Haag (1977). Cervical external rootresorption of teeth in ACR procedures with mesenchymal bone is due to osteoclastic activity (Andreasen, 1985, 1989). It reduces the prognosis of the preserved teeth in the former alveolar cleft, especially when grafting is performed after the eruption of the canine tooth (Gerner et al, 1986; Enemark et al, 1987). In this group of patients we did not see this complication neither in the CALI nor in the CAC, notwithstanding 45% of the CAT had already erupted at the time of grafting. Is there a connection with the ectomesenchymal nature of the grafts?
It is beyond the scope of this chapter to discuss this interesting subject extensively as Hillerup et al (1987) and (Gold and Hasselgren, 1992) did, but according to the periodontal literature the incidence of root resorption and ankylosis is reduced if cancellous tuberosity bone is placed adjacent to the root surface (Dragoo and Sullivan, 1973; Ellegaard et al, 1973, 1976; Karring et al, 1984).

V.4.2.3. Morphology of the alveolar process and vestibular sulcus

No massive scar tissue perpendicular to the cleft area was noted and resorption due to soft tissue pressure was not present. This is in accordance with Enemark et al (1985), Quarta and Koch (1985, 1989), Breier et al (1992) and many others. The use of transpositioned or local mucoperiosteal flaps obviated use of free mucosa grafts from the palate, which need to be transplanted in an other surgical procedure.

Furthermore we could determine on the X-OPT's that the caudal part of the piriform aperture on the cleft side was only moderately depressed in the edentulous former cleft area cases. So three dimensional resorption to a significant degree producing a diabolo shaped morphology occurred in one case only. No reports on this phenomenon are found in the literature.

V.4.2.4. Orthodontic status

The orthodontic results can be judged as "in accordance" with the reviewed literature (viz. table 9 and 10, 11 and 12) with respect to the closed dental arch. On the other hand a six-center international study on the results of dental arch relationship shows the need in 3 centers for surgical correction of the dental arch relation in 32%, 37%, 49% respectively. In the other 3 centers surgical correction was indicated in 6%, 9% and 10%. Mars et al (1992) concluded that the outcome of the orthodontic treatment could be influenced by poor palatal closure. In our 20 UCLP-patients five developed a maxillary retro-gnathia and one patient showed a mild cleft related dental arch relation disturbance (anterior open bite). The malocclusion was comparable with the Goslon 4 and 5 Yardstick groups[1]

[1] This is a scale (1-5) developped for multi-centre evaluation of malocclusion in cleft patients.

(Mars et al, 1992). Thus in 6/20 (30%) a moderate to severe cleft-related malocclusion was found. The malocclusions were concluded to be so severe that they were beyond orthodontic correction and required surgical intervention.
Orthodontic treatment after ACR corrected the malocclusion satisfactorily in 14/20 UCLP-patients (70%).
This percentage (70%) may point to a relatively poor concept of primary treatment as compared to what Mars et al described.
The UCLP-patients (6/20) who underwent pre- and post-surgical orthodontic treatment did not do (statistically) better in any respect than those of the group with only post-surgical orthodontic treatment.
One must consider that the postoperative orthodontic treatment was executed by different regional orthodontists. Most of the orthodontists were to a different degree experienced people, the entire cleft population of the OMF department was treated by them. One of them had treated 19 patients and the other orthodontist's number of cleft patients ranged from 1-9. The median orthodontic treatment time was 3.23 years (2.04-5.54 years). This open team approach, in our opinion, worked out fairly well.

V.4.2.5. Oronasal fistulae

Whenever a direct oro-nasal communication was present during surgery, it was closed with tissue from the cleft area. The use of mandibular bone in the grafting procedure had no negative influence on the results of oronasal fistula closure. The results are in accordance with Perko (1966) and many others. Production of fistulae was noted in 7.7%. We cannot compare this number with others since nobody reports this complication. It is about the same as reported in chapter VI.

V.4.2.6. The findings at the harvesting site

The procedure does not lead to visible or palpable scars. There seem to be three ways to avoid unfavourable vestibular scars:

1. When the incision is made in the buccal sulcus a sufficient rim of soft tissue should be left in the cervical area of the lower anterior teeth (Jauw, 1983; Kloosterman, 1985).
2. One could perform a marginal incision into the gingival sulcus along the lower incisors with two relieving incisions (Borstlap et al, 1990).
3. The intra-mucous membrane approach can be used.

If any of these incisions is made, no periodontal damage to the lower anterior teeth is likely to occur.
As known from the literature 5mm distance from the apices of the lower incisors ensures tooth-vitality (Kloosterman, 1985). Three apices in two patients were damaged during surgery due to overenthusiastic harvesting. So endodontic treatment is a complication of the harvesting procedure.
Pulpobliteration is not of clinical importance, it is in accordance with the experiment of Banks (1977) who noticed pulp changes after subapical mandibular osteotomy.

An estimation of the amount of donor bone needed should of course be carefully made. In general, careful examination of the recipient site during surgery and good observation of the pre-operative radiographs (X-OPT and maxillary occlusal x-ray) should prevent unnecessary damage in the donor region. (Even in the 14 BCLP-patients (mean age: 14.2y) of the total group, the amount of chin bone obtained was usually sufficient, although incomplete regeneration of the donor site was seen (63,6%; 9/14), probably due to bicortical bone harvesting). For wide unilateral clefts the amount of available chin bone harvested bicortically is sufficient. Incomplete donor site regeneration in the UCLP was seen in 2/20, with no clinical implications. Hoppenreys et al (1992) showed similar figures in their series of 26 mandibular grafts in complete UCLP-patients. We consider the complications in the donor area acceptable, because the sequelae are not a burden for the patient. Furthermore the complication rate will diminish after experience with the harvesting procedure is gained.

V.4.2.7. Radiographic examination

The alveolar crest height in active orthodontic treatment cases and after completion of the orthodontic treatment is good as compared with what is reported by authors who used iliac crest grafts (table 12). The ABR in our patients ranges from 0-20%. ABR rates below 15% were scored in 14/16 patients (uninterrupted dental arch). Functional stimulation by the presence of teeth in the bone grafted former cleft area was incontrovertible. The low degree of ABR must be considered as an indicator for it's quality and also for the good suitability of the graft for accepting orthodontic forces.

It is well known that interdental ABR occurs in cases where the roots are missing and/or diverging. This classic phenomenon was mentioned in review articles on ACR and resorption of graft material (Koberg, 1973; Witsenburg, 1985). We found no buccal bone resorption in the alveolar process due to diverging teeth.

Freitag and Fallenstein (1984) reported unfavourable results in the prosthetically reconstructed dental arches. They found considerable resorption of the interdental alveolar crest bone if there was no functional loading of the bone. The maximum bone resorption in the interrupted dental arch occurred in the patient with a Maryland bridge (42.3%). In all other prosthetically closed arches ABR was below 20%. (viz. fig. 27).

Additional factors which can probably contribute to alveolar bone graft resorption are:

1. (Extensive) scarring in the cleft area prior to bone grafting. This contributes to bone resorption because the blood supply is diminished and the bone is not covered by periosteum.
2. Infection from the nasal cavity (Johanson et al, 1974; Hall and Posnick, 1983).

In our patients excessive surgery had (probably) not taken place prior to ACR as we could establish from the medical histories. However, in 5/20 a previous attempt at fistula closure had been undertaken. A possible connection of the bone grafts with the nasal cavity because of formation of a nasal covering with a few interrupted situation stitches only did not affect the outcome. The more depressed piriform apertures (n=7) were not likely to be

caused by infection, because notes about purulent nasal discharge were not found in the medical histories.

V.5. Conclusion

By careful consideration of the presented data on periodontics, orthodontic results, morphology of the alveolar process, oronasal fistulae closure and ABR one can conclude that mandibular bone grafts in ACR, gives rise to encouraging results in comparison with iliac crest bone grafts as they are reported in the literature. Even the higher mean age of our patients did not affect the healing potential of the mandibular grafts.
The complications in the donor region are limited. The overall success rate, with respect to the six parameters that were investigated is far above the 80% which Witsenburg (1985) advocated to be a minimum requirement. MABR (8.7%) was low in a closed dental arch and ABR over 20% we did not see. In interrupted dental arches with prosthetic appliances there was slightly more mABR (19.9%).
From several points of view, clinical and theoretical, there are many arguments to recommend the use of mandibular symphysis bone as grafting material. Traditional donor sites, when in doubt, are still available.
The final verdict however on ectomesenchymal mandibular symphysis bone for ACR cannot be established yet on the basis of this investigation of 20 UCLP-patients. Analyses of variances with the results of mesenchymal iliac crest grafts in ACR must be performed.

References

Amanat, N., J.D. Langdon: Secondary alveolar bone grafting in clefts of the lip and palate. J. Cranio-Max.-Fac. Surg. 19 (1991) 7

Andreasen, J.O.: External root resorption: its implication in dental traumatology, paedodontics, periodontics, orthodontics and endodontics. Int. J. Endodont. 8 (1985) 109

Andreasen, J.O.: Review of root resorption systems and models. Etiology of root resorption and the homeostatic mechanisms of the periodontal ligament. In: Davidovitch, ed. The biological mechanisms of tooth eruption and resorption. Birmingham: EBSCO Media, 1989

Banks, P.: Pulpchanges after anterior mandibular subapical osteotomy in a primate model. J. Max.-Fac. Surg. 5 (1977) 39

Bergland, O., G. Semb, F.E. Abyholm: Elimination of the residual alveolar cleft by secondary bone grafting and subsequent orthodontic treatment. Cleft Palate J. 23 (1986) 175

Borstlap, W.A., K.L.W.M. Heidbruchel, H.P.M. Freihofer, A.M. Kuijpers-Jagtman: Early secondary bone grafting of alveolar cleft defects. A comparison between chin and rib grafts. J. Cranio-Max.-Fac. Surg. 18 (1990) 201

Bosker, H., L. van Dijk: Het bottransplantaat uit de mandibula voor herstel van de gnathopalatoschisis. Ned. Tijdschr. Tandheelk. 87 (1980) 383

Boyne, P.J.: Use of marrow-cancellous bone grafts in maxillary alveolar and palatal clefts. J. Dent. Res. 53 (1974) 821

Boyne, P.J., N.R. Sands: Secondary bone grafting of residual alveolar and palatal clefts. J. Oral Surg. 30 (1972) 87

Boyne, P.J., N.R. Sands: Combined orthodontic-surgical management of residual palato-alveolar cleft defects. Am. J. Orthod. 70 (1976) 20

Boyne, P.J., P.M. Scheer: Stimulation of bone induction by odontogenic epithelium in the treatment of alveolar clefts. In: Pfeifer G. Craniofacial abnormalities and clefts of the lip, alveolus and palate. 4th Hamburg International Symposium. (1991) 171

Boyne, P.J., P.M. Scheer: A long-term study of unilateral alveolar cleft grafting comparing pre-graft arch expansion to post-graft arch expansion. In: Pfeifer G. Craniofacial abnormalities and clefts of the lip, alveolus and palate. 4th Hamburg International Symposium. (1991) 292

Brägger, U., E. Schurch Jr, F. Gusberti, N. Land: Periodontal conditions in adolescents with cleft lip, alveolus and palate following treatment in a co-ordinated team approach. J. Clin. Periodontol. 12 (1985) 494

Brägger, U., S. Nyman, N. Land, T.H. von Wyttenbach, E. Schurch Jr: The significance of alveolar bone in periodontal disease. J. Clin. Periodontol. 17 (1990) 379

Brägger, U., E. Schurch, S. Giani, T. von Wyttenbach, N.P. Lang: Periodontal conditions in adult patients with cleft lip, alveolus and palate. Cleft Palate Cranio-Fac. J. 29 (1992) 179

Breier, Th., A. Hemprich, E. Immenkamp, R. Becher: Die Spätprimäre Kieferspaltosteoplastiek, Langzeiterfahrungen mit 90 Patienten. Dtsch. Z. Mund-Kiefer-Gesichts-Chir. 16 (1992) 232

Dragoo, R.M., H.C. Sullivan: A clinical and histological evaluation of autogenous iliac bone grafts in humans. II. External tooth resorptions. J. Periodontol. 44 (1973) 615

von Eiselsberg, F.W.: Zur Technik der Uranoplastik. Arch. Klin. Chir. 64 (1901) 509

El Deeb, M., L.B. Messer, M.W. Lehnert, T.W. Hebda, D.E. Waite: Canine eruption into grafted bone in maxillary alveolar cleft defects. Cleft Palate J. 19 (1982) 9

El Deeb, M.E., J.E. Hinrichs, D.E. Waite, C.L. Bandt, R. Bevis: Repair of alveolar cleft defects with autogenous bone grafting: periodontal evaluation. Cleft Palate J. 23 (1986) 126

Ellegaard, B., T. Karring, M. Listgarten, L. Herald: New attachment after treatment of interradicular lesions. J. Periodont. 44 (1973) 209

Ellegaard, B., I.M. Neilson, T. Karring: Composite jaw and iliac cancellous bone grafts in intrabony defects in monkey. J. Periodont. Res. 11 (1976) 299

Enemark, H., E. Krantz-Simonsen, J.E. Schramm: Secondary bone grafting in unilateral cleft lip palate patients: indications and procedure. Int. J. Oral Surg. 14 (1985) 2

Enemark, H., S. Sindet-Pedersen, M. Bundgaard: Long-term results after secondary bone grafting of alveolar clefts. J. Oral Max.-Fac. Surg. 45 (1987) 913

Freihofer, H.P.M., A.M. Kuijpers-Jagtman: Early secondary osteoplastic closure of the residual alveolar cleft in combination with orthodontic treatment. Suppl. J. Cranio-Max.-Fac. Surg. 17 (1989) 26

Freihofer, H.P.M., W.A. Borstlap, A.M. Kuijpers-Jagtman, R.A.C.A. Voorsmit, P.A. van Damme, L.W.M. Heidbüchel, V.M.F. Borstlap-Engels: Timing and transplant materials for closure of alveolar clefts. A clinical comparison of 296 cases. J. Cranio-Max.-Fac. Surg. 21 (1993) 143

Freitag, V., G. Fallenstein: Über die sekundäre Osteoplastik im Wechselgebiss bei Lippen-Kiefer-Gaumen-Spalten. Dtsch. Z. Mund-Kiefer-Gesichts-Chir. 8 (1984) 343

Frodel, J.L., L.J. Marentette, V.C. Quartela, G.S. Weinstein: Calvarian bone graft harvest: techniques, considerations and morbidity. Arch. Otolaryngol. Head Neck Surg. 119 (1993) 17

Gerner, N.W., B. Hurlen, O. Bergland, G. Semb, E.M.S. Beyer-Olsen: External root resorption in patients with secondary bone-grafting of alveolar clefts. Endod. Dent. Traumatol. 2 (1986) 263

Gold, S.I., G. Hasselgren: Peripheral inflammatory root resorption. A review of the literature with case reports. J. Clin. Periodontol. 19 (1992) 523

Haag, R.: Das Verhalten des Knochentransplantates bei jugendlichen Lippen-Kiefer-Gaumen-Spaltenpatienten nach Überbrückung der Alveolarspalte. Thesis, University of Zürich, Ströbele, Romanshorn, 1977

Hall, H.D., J.C. Posnick: Early results of secondary bone grafts in 106 alveolar clefts. J. Oral Max.-Fac. Surg. 41 (1983) 289

Harsha, B.C., T.A. Turvey, S.K. Powers: Use of autogenous cranial bone grafts in maxillo-facial surgery. A preliminary report. J. Oral Max.-Fac. Surg. 44 (1986) 11

Hillerup, S., E. Dahl, O. Schwartz, E. Hjorting-Hansen: Toothtransplantation to bone graft in cleft alveolus. Cleft Palate J. 24 (1987) 137

Hinrichs, J.E., M.E.N. El Deeb, D.E. Wait, R.R. Bevis, C.L. Bandt: Periodontal evaluation of canines erupted through grafted alveolar cleft defects. J. Oral Max.-Fac. Surg. 42 (1984) 717

van Hoeken, F.: Occlusale röntgenfoto's bij schisispatiënten. Ned. Tijdschr. Tandheelk. 90 (1983) 215

Hoppenreijs, T.J.M., E.S. Nijdam, H.P.M. Freihofer: The chin as a donor site in early secondary osteoplasty: a retrospective clinical and radiological evaluation. J. Cranio-Max.-Fac. Surg. 20 (1992) 119

Huffstadt, A.J.C., P.H.M. Spauwen, J. Boersma, G.S. Havinga, J. Bergstra: Schisis; Multidisciplinaire benadering. De Nederlandse Bibliotheek der Geneeskunde. Samsom Stafleu, Alphen aan den Rijn/Brussel 1987

Jackson, I.T., C. Pellet, J.M. Smith: The skull as a bone graft donor site. Am. Plast. Surg. 11 (1983) 527

Jackson, I.T., G. Helden, R. Marx: Skull bone grafts in maxillofacial and craniofacial surgery. J. Oral Max.-Fac. Surg. 44 (1986) 949

Jauw, S.L.: The use of homologous lyophilized bone graft in Hofer's osteotomy. J. Max.-Fac. Surg. 11 (1983) 113

Johanson, B., A. Ohlsson, H. Friede, J. Ahlgren: A follow-up study of cleft lip and palate patients treated with orthodontics secondary bone grafting and prosthetic rehabilitation. Scand. J. Plast. Reconstr. Surg. 8 (1974) 121

Kaplan, H.: The logic of modern retention procedures. Am. J. Orthod. Dentofac. Orthop. 93 (1989) 325

Karring, T., S. Nyman, J. Lindhe, M. Sirirat: Potentials for root resorption during periodontal wound healing. J. Clin. Periodontol. 11 (1984) 41

Kawamoto, H.K., P.C. Zwiebel: Cranial bone grafts and alveolar clefts. In: Caronni EP, ed. Craniofacial surgery. Boston-Toronto: Little & Brown (1985) 449

Kloosterman, J.: Köle's osteotomy, a follow-up study. J. Max.-Fac. Surg. 13 (1985) 59

Koberg, W.R.: Present view on bone grafting in cleft palate (a review of literature). J. Max.-Fac. Surg. 1 (1973) 185

Koole, R., H. Bosker, F. Noorman van der Dussen: Late secondary autogenous bone grafting in cleft patients comparing mandibular (ectomesenchymal) and iliac crest (mesenchymal) grafts. Suppl. J. Cranio-Max.-Fac. Surg. 17 (1989) 28

Koole, R., P. Egyedi: The case for postoperative orthodontics in orthognathic surgery. J. Cranio-Max.-Fac. Surg. 18 (1990) 293

Kortebein, M.J., C.L. Nelson, A.M. Sadove: Retrospective analysis of 135 secondary alveolar cleft grafts using iliac or calvarial bone. J. Oral Max.-Fac. Surg. 49 (1991) 493

Krantz Simonsen, E.: Secondary bone-grafting for repair of residual cleft defects in the alveolar process and hard palate (a new surgical technique). Int. J. Oral Max.-Fac. Surg. 15 (1986) 1

Kusiak, J.F., J.E. Zins, L.A. Whitaker: The early revascularization of membranous bone. Plast. Reconstr. Surg. 76 (1985) 510

Lang, N.P., R. Adler, A. Joss, S. Nyman: Absence of bleeding on probing. An indicator of periodontal stability. J. Clin. Periodontol. 17 (1990) 714

Lindhe, J.: Textbook of clinical periodontology. Copenhagen: Munksgaard, 1983

Mars, M., C. Asher-McDade, V. Brattström, E. Dahl, J. McWilliam, K. Molsted, D.A. Plint, B. Prahl-Andersen, G. Semb, W.C. Shaw, R.P.S. The: A six-center international study of treatment outcome in patients with clefts of the lip and palate: part 3. Dental arch relationships. Cleft Palate-Craniofac. J. 29 (1992) 405

Mowlem, R.: Bone and cartilage transplants. Their use and behaviour. Br. J. Surg. 29 (1941) 182

Mowlem, R.: Cancellous chip bone-grafts. The Lancet 2 (1944) 746

Mowlem, R.: Bone grafting. Br. J. Plast. Surg. 16 (1963) 293

Paulin, G., P. Astrand, J.B. Rosenquist, L. Bartholdson: Intermediate bone grafting of alveolar clefts. J. Cranio-Max.-Fac. Surg. 16 (1988) 2

Perko, M.: Gleichzeitige Osteotomie der Zwischenkiefers, Rest-spaltenverschluss und Zwischenkieferversteifung durch sekundäre Osteoplastik bei Spätfällen von beidseitigen Lippen-Kiefer-Gaumen-Spalten. Dtsch. Zahn-Mund-Kieferheilk. 47 (1966) 1

Quarta, M., J. Koch: Mundvorhofplastik beim LKGS-Spaltträger unter Verwendung von Polyglactin-Netz. Zahnärztl. Prax. 35 (1985) 344

Quarta, M., J. Koch: Metric results of vestibuloplasty in unilateral cleft patients. J. Cranio-Max.-Fac. Surg. 17 (1989) 175

Ramstad, T.: Periodontal condition in adult patients with unilateral complete cleft lip and palate. Cleft Palate J. 26 (1989) 14

Rehrmann, A., W.R. Koberg, H. Koch: Long term postoperative results of primary and secondary bone grafting in complete clefts of lip and palate. Cleft Palate J. 7 (1970) 206

Sadove, A.M., C.L. Nelson, B.L. Eppley, B.N. Guyen: An evaluation of calvarian and iliac donor sites in alveolar cleft grafting. Cleft Palate J. 27 (1990) 225

Semb, G., O. Bergland, F. Abyholm: Die Bedeutung der sekundären Osteoplastik für die kieferorthopädische Behandlung von Spaltpatienten. Fortschr. Kieferorthop. 47 (1986) 519

Schmid, E.: Die Annäherung der Kieferstümpfe bei Lippen-Kiefer-Gaumen-Spalten; ihre schädlichen Folgen und Vermeidung. In: Schuchardt K. Fortschr. Kiefer-, Gesichtschir. vol. 1. Stuttgart: Thieme (1955) 37

Sindet-Pedersen, S., H. Enemark: Mandibular bone grafts for reconstruction of alveolar clefts. J. Oral Max.-Fac. Surg. 46 (1988) 533

Sindet-Pedersen, S., H. Enemark: Reconstruction of alveolar clefts with mandibular or iliac crest bone grafts. A comparative study. J. Oral Max.-Fac. Surg. 48 (1990) 554

Stoelinga, P.J.W., P.E.J.J. Haers, R.J. Leenen, R.J. Soubry, P.A. Blijdorp, J.H.A. Schoenaers: Late management of secondarily grafted clefts. Int. J. Oral Max.-Fac. Surg. 19 (1990) 97

Troxell, J.B., R.J. Fonseca, D.B. Osborn: A retrospective study of alveolar cleft grafting. J. Oral Max.-Fac. Surg. 40 (1982) 721

Turvey, T.A., K. Vig, J.M. Moriarty, J. Hoke: Delayed bone grafting in the cleft maxilla and palate; A retrospective multidisciplinary analysis. Am. J. Orthod. 86 (1984) 244

Van de Wal, K.: Gnathoschisis en de laterale incisief. Ned. Tijdschr. v. Tandheelk. 100 (1993) 442

Witsenburg, B.: The reconstruction of anterior residual bone defects in patients with cleft lip, alveolus and palate. A review. J. Max.-Fac. Surg. 13 (1985) 197

Witsenburg, B., H.P. Freihofer: Autogenous rib graft for reconstruction of alveolar bone defects in cleft patients. Long term follow-up results. J. Cranio-Max.-Fac. Surg. 18 (1990) 55

Witsenburg, B., H.J. Remmelink: Reconstruction of residual alveolo-palatal bone defects in cleft patients. A retrospective study. J. Cranio-Max.-Fac. Surg. 21 (1993) 239

Wolfe, S.A., S. Berkowitz: The use of cranial bone grafts in the closure of alveolar and anterior palatal clefts. J. Plast. Reconstr. Surg. 72 (1983) 659

Zins, J.E., L.A. Whitaker: Membranous versus endochondral bone autografts: implications for craniofacial reconstruction. Surg. Forum Plast. Surg. (1976) 521

Zins, J.E., L.A. Whitaker: Membranous versus endochondral bone: implications for craniofacial reconstruction. Plast. Reconstr. Surg. 72 (1983) 778

Chapter VI

Mesenchymal bone grafting (anterior iliac crest) for alveolar cleft repair; Late results - a clinical and radiological follow-up -

This chapter is an extended form of an article that will be submitted for publication.

Chapter VI

Mesenchymal bone grafting (anterior iliac crest) for alveolar cleft repair; Late results - a clinical and radiological follow-up -

VI.1. Introduction

Bone grafting in cleft lip and palate patients for ACR is a well established surgical procedure, it was reported in the 1950's in German literature (Schmid, 1955; Nordin and Johanson, 1955). Many European cleft palate centres followed this procedure, because the ratio, not only to unite the soft components around the cleft, but also to prevent collapse of the maxillary segment by filling the bony defect with an autologous bone graft (Axhausen, 1952) was accepted by many surgeons.

However, in the 1960's, after surgery in young children, growth disturbances of the maxillary complex were reported from many European cleft centres (Koberg, 1973). The early bone grafting procedure (primary osteoplasty) in complete cleft lip and palate cases was abandoned, because intrinsic and extrinsic growth disturbances of the maxillary complex, resulted in retrognathia, marked vertical growth deficiency in the cleft region, retention of permanent teeth in the cleft region and subsequent resorption of the bone graft (Pruzanski, 1964; Ross, 1987).

In the 1970's Boyne (1974) and Boyne and Sands (1972, 1976), established the optimal time for (secondary) ACR: around 9 to 12 years of age. Many cleft lip and palate centres in Europe and the U.S.A. reported on their good results of (secondary) ACR in the late 1970's and 1980's (Witsenburg and Freihofer, 1990; Bardach and Morris, 1990) without the before mentioned shortcomings of the primairy osteoplasty. Some centres however, still claim good results and continued the primairy bone grafting (Rosenstein et al, 1982). The controversy between the two procedures continues and the performers of the primary bone graft state that the reported unfavourable results were due to excessive surgery in the cleft region before or during the ACR.

Thus Larson et al (1991) and Schwenzer (1991) mentioned severe growth disturbances, Rosenstein and Kernahan (1991) on the contrary claim (after a follow-up of 23 years) good results. Krüger et al (1991) and Stoll et al (1991) mentioned growth retardation but this was not significantly different from the "secondary" grafted cleft lip patients and they stated that there is more than the bone graft surgery interfering with anterior and vertical growth. The orthodontic treatment after primary osteoplasty must be considered as a major growth stimulus in that patient group.

In an extensive growth studie Ross (1987) concluded that the facial and maxillary (retarded) growth in the sagittal, vertical and transversal dimension is almost completed by 10-11 years of age. Surgery performed after or during that time can not harm facial growth anymore to a great extent. The general (intrinsic) growth disturbance he states, whenever existing in a cleft patient, can be corrected by the orthodontist after grafting the cleft and eruption of the CAT.

In our treatment approach we accepted in 1972 the "secondary" grafting procedure for ACR. As in most of the above-mentioned reports iliac crest bone was used.
This chapter will report on the results of ACR in 30 UCLP patients. The surgical procedure was performed by experienced OMF-surgeons in the Department of OMF Surgery of the University Hospital of Utrecht, orthodontic treatment was done by regional orthodontists and specialists of the Department of Orthodontics. The prosthodontic rehabilitation was carried out in the department for Maxillo-Facial-Prosthetics. All departments were part of the former Dental School of the University of Utrecht.

VI.2. Material and methods

VI.2.1. Patients

From the files of the Department of OMF Surgery over 220 cleft patients were found who underwent some form of ACR on a routine basis during 1976-1987. After screening the patients' files, for sufficient data, 166 patients were invited to cooperate in a long-term follow-up investigation.
Twenty-one (12.6%) did not react to the mailing.
Thirty-two further patients (19,3%) did not qualify (eight had moved abroad, nineteen patients refused or were not able to come, five patients with extensive maxillary overdentures were excluded). In the end (table 13) 113 patients (67.6%) entered the study.
The total cleft patient sample however was quite diverse:

- unilateral (complete) cleft patients (N=81)
- bilateral (complete) cleft patients (N=32)
- bone grafting between 9 - 17.5 years (N=75)
- bone grafting after ≥ 17.5 years (N=38)

Table 13.

variables N=113	gender distribution male:female	left-right
UCLP 81	51:30	60:21
BCLP 32	20:12	–

Table 14.

variables N=30	gender distribution male:female	left-right	mean and median age at ACR range: 9.59-17.44	pre-surgical orthodontics			follow-up range: 1.53-9.5 y
				front	expansion	front + expansion	
UCLP	18:12	23:7	mean 13.53 median 13.54	10	5	2	mean 4.95 y median 4.36 y

- bone grafting with endochondral mesenchymal bone (1976-1986) (crista N=80, rib N=5, other N=2)
- bone grafting with ectomesenchymal mandibular symphysis bone (1986, 1987) (N=26)

Therefore it was decided to restrict this report to the results of ACR performed between 9-17.5 years in unilateral complete cleft patients grafted with iliac crest bone (N=30). No reoperations for ACR, previous bone grafting procedures or combination with an osteotomy had been done in these patients. In table 14 the gender distribution, cleft side, pre-surgical orthodontic treatment and mean age at ACR and mean follow-up period is depicted.

VI.2.2. Previous surgery

Previous treatment; most patients had been operated on at an age of 3 months for lipclosure according to Veau or Tennison-Randall. The anterior part of the palate was closed at the same time with a Vomer flap (single layer closure of alveolar cleft). The hard and soft palate were closed in the majority of the cases by the age of 18 months according to Wardill Kilner. Interceptive orthodontic treatment during pre-school-age was optional.

VI.2.3. Orthodontic procedures

Within the cleft palate team orthodontic treatment in those days was not standardized or according to a protocol; further more the pre-operative orthodontic treatment was executed by the patients' local orthodontists.

The orthodontic treatment (n=17/30, 56.66%) can be divided in: religning anterior teeth (10/30=33.33%), expansion of the lesser segment (5/30=16.67%) or a combination (2/30=6.66%). The postoperative orthodontic treatment, was started after 3 months, assuming the mesenchymal bone graft was incorporated. It was executed by regional orthodontists or in the Department of Orthodontics of the former Utrecht Dental School.

VI.2.4. Pre-operative dental status

The dental age in respect to the cuspid status can be described as follows: three patients showed an impacted normally developed cuspid at the time of surgery, however they were still covered by intact mucoperiosteum; 2/3 root formation was completed in 10 cuspids. Two patients had cuspid roots developed for 1/3 of their estimated (final) length. In 15 UCLP-patients the cuspids were erupted at the time of surgery. Five patients showed a normal number of teeth in the cleft area, absence of the lateral incisor was registered in 25 children.

Pre-operatively the cleft was classified as small in one, wide in 4 and normal in 25 UCLP-patients.

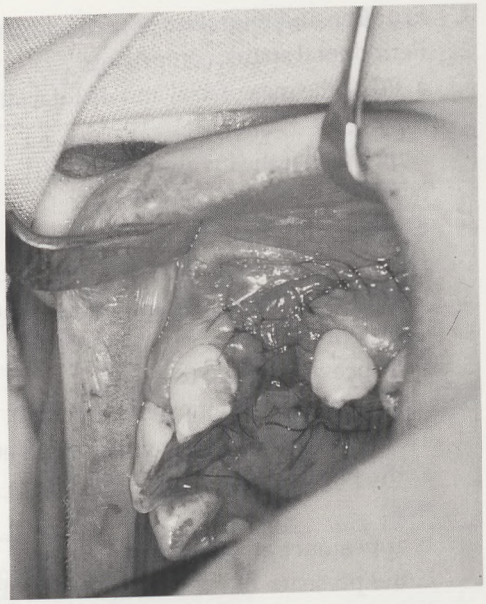

Figure 31. *Oral closure by a finger flap and retaining a rim of attached gingiva in the cleft area.*

a. Design of the flap - note the alveolar defect and oro-nasal fistula.

b. Post-operative view.

VI.2.5. Surgical procedure

The ACR by iliac crest bone grafting was performed in general anaesthesia with endotracheal intubation. Antibiotic (Flucloxacilline) profylaxis was given for 7 days intravenously, starting half an hour before the bone harvesting procedure.

The bone graft was taken from the iliac crest in the usual manner (Mrasik et al, 1980). The bone graft was (at that time) stored in a blood-soaked gauze. The recipient side was prepared in the early cases by leaving a rim of attached gingiva around the cervical area of the teeth adjacent to the cleft (fig. 31). The nasal floor was restored, the edges of the alveolar defect were freshened by an osteotome (by opening the outer cortex the angioneogenesis is facilitated). Care was taken not to damage impacted teeth or dental roots. Then cancellous bone was grafted into the alveolar cleft at the palatal side, a corticocancellous bone block was wedged into the alveolar cleft and an amount of cancellous bone was grafted at the buccal side and in the region of the piriform aperture.

A vestibular finger flap[1] (n=10), local undermining of the adjacent mucogingival tissue and transpositional mucoperiosteal flaps (n=20) were used to close the vestibular oral layer.

VI.2.6. Methods of examination

The results of the grafting procedures were evaluated on basis of the clinical and radiological parameters, in the same way as described earlier.

For a good understanding it is summarized here:

[1] In our clinic, out of respect to the great Czech cleft surgeon Burian, we call it the Burian-flap.

1. Eruption and migration of teeth into the grafted area.
2. Periodontal status, comprising:
   a. PD at the mesiofacial and distofacial surface of the maxillary teeth (14-24)
   b. BOP,
   c. mobility of the involved teeth,
   d. width of attached gingiva,
   e. color of the gingiva,
   f. cervical root resorption of CAT.
3. Morphology of the alveolar process and vestibular sulcus.
4. Orthodontic status.
5. Presence of oronasal fistulae.
6. Examination of donor site (iliac crest).
   The status of the bone donor site was evaluated considering:
   a. direct postoperative complications (prolonged gait disturbances, seroma, infection)
   b. appearance and length of the scar
   c. the presence of meralgia paraesthetica (neuropraxia of the N. cutaneous femoris lateralis)
   d. the presence of a dip of the iliac crest
   e. the persistence of gait disturbances on the long term.
7. Radiologic examination of ABR
   a. The interdental alveolar crest height (former cleft area)
   b. The status of the piriform aperture.

For some more details of the evaluations the reader is referred to chapters III and V.

VI.3. Results

Thirty UCLP-patients were examined on the seven topics to determine succes of ACR.

VI.3.1. Examinations

Ad 1. Cuspid eruption.
In all 15 UCLP patients the information on eruption was found. Ten cuspid teeth had erupted spontaneously in the grafted area, as could be assessed from the patients' file or successive maxillary X-rays. Orthodontic traction after surgical exposure was performed in 5 cases of delayed eruption.
Enlarged dental follicles were observed in the grafted area around two impacted cuspids. With respect to the delayed eruption of impacted teeth in the finger flap group (FFG) one tooth had to be surgically exposed and in the mucoperiosteal flap group (MPFG) four patients needed surgical exposure of the canine tooth.

Table 15: *Periodontal findings in 30 UCLP patients comparing cleft associated teeth with the contra-lateral non cleft side*

Probing depth distofacial

	CLPD4	NCPD4	CLPD3 CAC	NCPD3	CLPD2 CALI	NCPD2	CLPD1 CACI	NCPD1
Count	30	30	30	30	30	30	30	30
Valid N	29	28	26	29	3	19	23	30
Mean	2.17	1.96	2.08	1.90	1.33	1.95	1.91	1.87
St. dev.	.85	.69	.69	.82	.058	.078	.051	.078
P values	ns		ns		no variance		ns	
Minimum	1.00	1.00	1.00	1.00	1.00	1.00	1.00	1.00
Median	2.00	2.00	2.00	3.00	1.00	2.00	2.00	2.00
Maximum	5.00	3.00	3.00	4.00	2.00	4.00	3.00	5.00

CLPD= cleft side probing depth distofacial aspect
NCPD= non cleft side probing depth distofacial aspect
1, 2, 3, 4= central, lateral incisor, cuspid, bicuspid
ns= not significant

CAC= cleft associated canine
CALI= cleft associated lateral incisor
CACI= cleft associated central incisor

Probing depth mesiofacial

	CLPM4	NCPM4	CLPM3 CAC	NCPM3	CLPM2 CALI	NCPM2	CLPM1 CACI	NCPM1
Count	30	30	30	30	30	30	30	30
Valid N	29	28	26	29	3	19	23	30
Mean	2.17	1.96	2.08	1.90	1.33	1.95	1.91	.187
St. dev.	.85	.69	.69	.82	.058	.078	.051	.078
P values	ns		ns		no variance		ns	
Minimum	1.00	1.00	1.00	1.00	1.00	1.00	1.00	1.00
Median	2.00	2.00	2.00	3.00	1.00	2.00	2.00	2.00
Maximum	5.00	3.00	3.00	4.00	2.00	4.00	3.00	5.00

CLPM= cleft side probing depth mesiofacial aspect
NCPM= non cleft side probing depth mesiofacial aspect
1, 2, 3, 4= central, lateral incisor, cuspid, bicuspid
ns= not significant

CAC= cleft associated canine
CALI= cleft associated lateral incisor
CACI= cleft associated central incisor

Attached gingiva (width), mean values (FFG+MPFG)

	CLAG4	NCAG4	CLAG3 CAC	NCAG3	CLAG2 CALI	NCAG2	CLAG1 CACI	NCAG1
Count	30	30	30	30	30	30	30	30
Valid N	29	28	26	29	3	19	23	30
Mean	3.25	3.52	1.96	1.82	1.67	3.89	1.87	2.48
St. dev.	1.84	1.31	1.40	1.33	1.15	1.32	1.06	1.27
P values	ns		ns		no variance		ns	
Minimum	2.00	1.00	0.00	0.00	1.00	2.00	1.00	1.00
Median	3.00	3.00	2.00	2.00	1.00	4.00	1.00	2.00
Maximum	8.00	5.00	5.00	5.00	3.00	7.00	4.00	5.00

CLAG= cleft side attached gingiva
NCAG= non cleft side attached gingiva
1, 2, 3, 4= central, lateral incisor, cuspid, bicuspid
ns= not significant
CAC= cleft associated canine
CALI= cleft associated lateral incisor
CACI= cleft associated central incisor

During the follow-up period four cuspids were lost for various dental reasons (periodontal, dental decay, position unsuitable for crown/bridge reconstruction).

Ad 2. Periodontal status.
The results are shown in table 15. A few items which were considered important are highlighted in addition. Pre-operatively in five patients the lateral incisor was present (5/30), the cleft was situated distally. During surgery two CALI were removed, so three UCLP patients showed a distally of the CALI located cleft at follow-up. In 27 patients the grafted cleft was between the cuspid and central incisor.

PD at the CAT was compared with the contralateral side
In both groups together the mPD at the distofacial aspect of the CACI (1.91mm) showed no significant difference with the contralateral side (mPD: 1.87mm). The mesiofacial mPD (2.00mm) of the CAC compared with the non-cleft canines (1.90mm) showed no significant difference either. However, a PD of 3 mm was measured once in the CAC. This patient showed an overall moderate to severe pathological periodontal status and was responsible for all maximum probing depths. The mPD of the CALI (n=3) measured distofacially 1.33mm vs 1.95mm compared with the contralateral side. However, they were paired in one case only (2.00mm vs 2.00mm).
Summarizing, PD > 3 mm were not measured in CAT.
BOP around the CAT was present in 23% of the patients. The incidence of BOP in non-cleft related teeth was 1:5.2. The mobility of the teeth in the former cleft area was not dif-

Table 16. *Difference in width of attached gingiva in 30 UCLP patients, oral closure with finger flaps or mucoperiosteal transposition flaps*

Attached gingiva (width); labial sulcus flaps (FFG)(n=10)

	CLAG4	NCAG4	CLAG3 CAC	NCAG3	CLAG2 CALI	NCAG2	CLAG1 CACI	NCAG1
Count	10	10	10	10	10	10	10	10
Valid N	10	10	10	9	0	7	7	10
Mean	3.40	3.80	2.30	2.11	–	3.43	1.86	2.40
St. dev.	1.17	1.23	1.06	0.93	–	1.27	0.90	0.97
P values	ns		ns		ns		ns	
Minimum	1.00	2.00	0.00	1.00	–	2.00	1.00	1.00
Median	3.00	4.00	3.00	2.00	–	3.00	2.00	2.50
Maximum	5.00	5.00	3.00	3.00	–	5.00	3.00	4.00

CLAG= cleft side attached gingiva
NCAG= non cleft side attached gingiva
1, 2, 3, 4= central, lateral incisor, cuspid, bicuspid
ns= not significant

CAC= cleft associated canine
CALI= cleft associated lateral incisor
CACI= cleft associated central incisor

Attached gingiva (width); mucoperiosteal flaps (MPFG)(n=20)

	CLAG4	NCAG4	CLAG3 CAC	NCAG3	CLAG2 CALI	NCAG2	CLAG1 CACI	NCAG1
Count	20	20	20	20	20	20	20	20
Valid N	19	18	16	20	3	12	16	20
Mean	3.17	3.35	1.75	1.68	1.67	4.18	1.88	2.53
St. dev.	2.15	1.37	1.57	1.49	1.15	1.33	1.15	1.43
P values	ns		ns		ns		ns	
Minimum	1.00	1.00	1.00	0.00	1.00	2.00	1.00	1.00
Median	3.00	3.00	1.50	1.00	1.00	4.00	1.00	2.00
Maximum	8.00	5.00	5.00	5.00	3.00	7.00	4.00	5.00

CLAG= cleft side attached gingiva
NCAG= non cleft side attached gingiva
1, 2, 3, 4= central, lateral incisor, cuspid, bicuspid
ns= not significant

CAC= cleft associated canine
CALI= cleft associated lateral incisor
CACI= cleft associated central incisor

ferent from the non-cleft related teeth.
The periodontal health with respect to mPD, BOP, and mobility using the two tailed probability in paired samples t-test was not different between CAT and non-CAT.
The width of attached gingiva in the former cleft region must be considered in separate groups, because the closing method is essentially different (table 16). In the FFG (n=10) at the cleft area, there is minimal attached gingiva at the CACI (1.86mm). The pedicle of the Burian flap flattens the vestibular sulcus. The (transpositional) MPFG showed, however, no difference in width of attached gingiva between the cleft and non-cleft area (paired samples t-test).
The colour of the gingiva at the CAT showed no clear difference with the non-cleft related teeth.
Cervical external root resorption of the CAT was not observed at follow-up, even when the ACR took place after the eruption of the canine (n=15).
Summarizing the periodontal findings, there were no statistical differences between CAT and non-cleft related teeth.

Ad 3. Morphology of the alveolar process and vestibular sulcus.
In fact three methods of closing were performed in the ACR-procedure, the influence of flap design on the vestibular sulcus is depicted in table 17.

Table 17: *Influence of flap design on resulting vestibular sulcus depth in 30 UCLP-patients treated by ACR < 17.5 years*

results	*UCLP Patients N=30*				
				buccal contour alveolar process	
closure oral layer	*physiological*	*shallow*	*scarred*	*concave*	*normal*
local mucoperi-osteal flaps n=15	*9*	*6*	*0*	*6/15*	*9/15*
	mABR: 19.4%				
transpositional mucoperiosteal flaps n=5	*2*	*3*	*0*	*2/5*	*3/5*
	mABR: 26.5%				
finger flaps n=10	*5*	*4*	*1*	*8/10*	*2/10*
	mABR: 46.1%				
total n=30	*16*	*13*	*1*	*16/30*	*14/30*
	mABR: 24.9%	*mABR: 34.7%*			

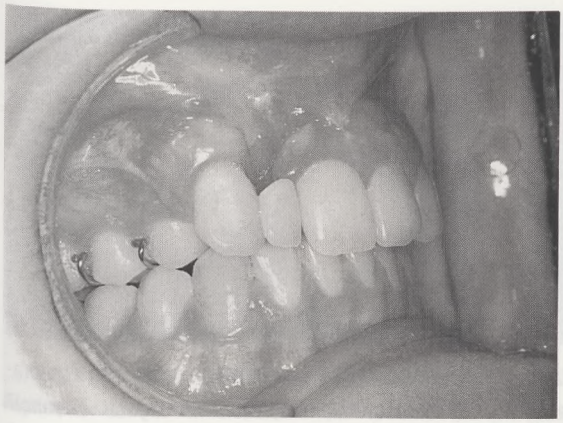

Figure 32. *Scar of the finger flap in the shallow vestibular sulcus, concave buccal contour, cervical resorption of the graft, non-functional loading.*

The use of finger flaps from the buccal sulcus may cause a depressed vestibulum due to scars perpendicular to the alveolar process. These scars (fig. 32) were actually present in 5 out of 10 patients.

The contour of the alveolar process in the FFG was registered as concave by palpation in most cases (8/10). In the MPFG 8/20 concave contours were registered. In two directions (buccal and interdental) oral closure seems to have influenced the amount of ABR.

Summarizing in 16/30 the buccal contour of the alveolar process showed substantial bone resorption of the graft.

If we analyze the influence of the angulation of the teeth we find the following (viz. table 18).

When the angulation of the teeth adjacent to the previous cleft was ≤ 30% (23/30) the contour of the alveolar process was classified as concave in 12/23. When the roots were diverging between 30-45% (7/30) the contour of the alveolar process was classified as concave in 4/7. However, in only 70% of the cases the dental arch was closed, therefore the concavity of the buccal aspect of the alveolar process is also determined by the absence of teeth in the former cleft area.

Nine patients had been reconstructed with extensive prosthetic appliances.

Ad 4. Orthodontic status.

26 of the 30 patients had postsurgical orthodontic treatment, four were treated prostho-

Table 18.

diverging teeth adjancent to cleft / *cleft*	*≤30° alveolar process*		*30-45° alveolar process*		*≥45° alveolar process*	
	concave	*normal*	*concave*	*normal*	*concave*	*normal*
left (N=23)	*9*	*8*	*3*	*3*	*0*	*0*
right (N=7)	*3*	*3*	*1*	*0*	*0*	*0*
total (N=30)	*12*	*11*	*4*	*3*	*0*	*0*

Figure 33. *UCLP-patient after ACR and in finalizing state of orthodontic treatment. The cuspid is considered to be in its final position.*

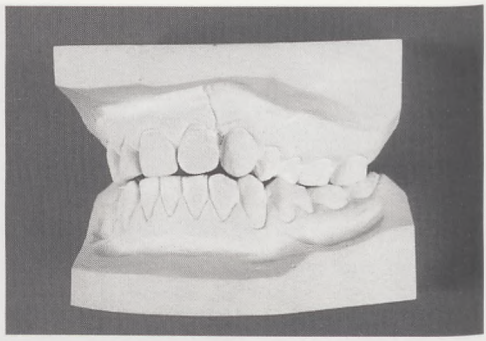

Figure 34. *Dental cast of UCLP-patient. An acceptable anterior teeth relation in sagittal direction. However an slight vertical open bite is present.*

dontically after ACR. At the time of the evaluation in 14/26 patients the orthodontic treatment was in a finalizing stage, however the canine tooth was already in its final position (fig. 33).

The prosthodontically rehabilitated dental arches (n=9) were, as far as the intermaxillary relation is concerned, dealt with as if natural teeth were present, unless prosthetic compensations of a class III relation were performed (n=5/9). The combined surgical-orthodontic treatment resulted in 21/30 uninterrupted dental arches. A normal sagittal front or maxillary relation was seen in 14/30 and 3/30 acceptable crossbites were seen in the cleft region. In 13/30 a retrognathia of the maxilla had occurred. A combination with an anterior open bite was present in eleven patients (fig. 34).

N=30	C1	I2 (N=3)	I1	molar cleft side
normal sagittal and acceptable cross bite relation	11	2	14	15
end to end relation	4	–	3	–
anterior open bite	11	1	11	–
in combination with deep overbite			2	
reversed frontal sagittal relation (prosthetics included)	13	–	13	–
reversed molar relation	–	–	–	15

Table 19: *orthodontic relation of cleft associated teeth and molar relation in 30 UCLP patients*

If there were prosthodontic reconstructions (n=9) the intermaxillary relation was registered as if they were natural teeth unless severe compensations were executed (n=5).

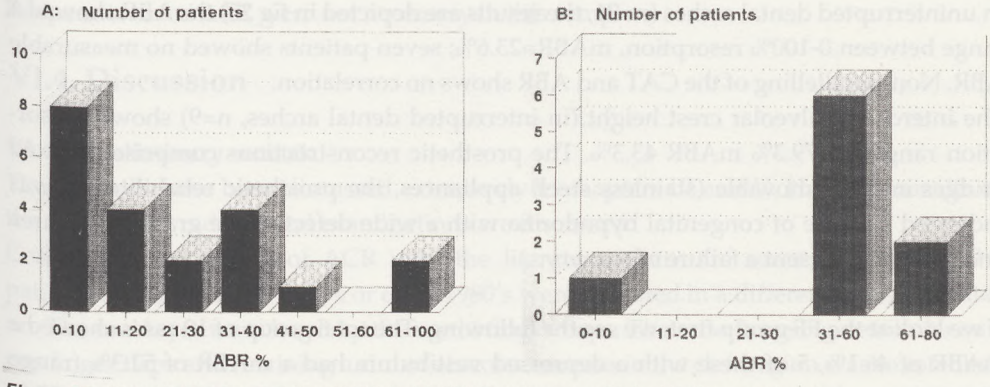

Figure 35. *Alveolar bone resorption (ABR) in 30 UCLP-patients grafted with iliac crest bone.*
A. 21 uninterrupted dental arch
B. 9 interrupted dental arch

A vertical deep overbite was seen in two patients. The orthodontic results are shown in table 19.
Summarizing, in 21/30 (70%) a closed dental arch could be established by orthodontic treatment, although limitations in the orthodontic result had to be accepted (end to end position, cross bite, retrognathic relation).

Ad 5. Oronasal fistulae.
Pre-operatively 11 oronasal fistulae were present and gave complaints about air or liquid leakage to the nose. At the time of follow-up evaluation 10/11 fistulae were closed by the ACR procedure. In one case a fistula was produced or became manifest. Successrate of fistula closure 90.9%, fistula production as a complication 1/19= 5.2%.

Ad 6. Findings in the donor area.
The harvesting procedure for obtaining the bone graft from the iliac crest is a well-known surgical procedure. Apart from the general postoperative complaints as swelling, haematoma, seroma and formation of a scar, special attention was paid to the incidence of specific complications like meralgia paraesthetica, herniation of small intestine and prolonged gait disturbances.
Direct postoperative complications were very few, only one seroma was encountered. In the long term 7 patients showed a broad and hypertrophic skin scar. The length of the scar varied considerably (3.5-7.2cm) the mean length was 4.3cm. In 4 patients a palpable dip in the anterior iliac crest was present. One patient showed a meralgia paraesthetica and two patients (6.7%) had prolonged gait disturbances. Herniation of intestine and serious complications as infection or osteomyelitis of the pelvic bone was never observed.

Ad 7. Radiographic examination. Measurement of ABR. Interdental alveolar crest height.

In uninterrupted dental arches (n=21, the results are depicted in fig 35) the ABR showed a range between 0-100% resorption, mABR=23.6%; seven patients showed no measurable ABR. Non-parallelling of the CAT and ABR shows no correlation.
The interdental alveolar crest height (in interrupted dental arches, n=9) showed resorption ranging 0-79.3% mABR 43.3%. The prosthetic reconstructions comprised 4 fixed bridges and 5 removable (stainless steel) appliances, the prosthetic rehabilitation was indicated because of congenital hypodontia with a wide defect in the grafted cleft area and did not represent a failure of surgery.

If we look at the FF group first, we see the following. The total group of 10 cases showed a mABR of 46.1%, 5 of these with a depressed vestibulum had a mABR of 52.3% (range 37.2-79.3%), whilst those with a physiological sulcus had a mABR of 39.9% (range 25.0-80.8%) (difference: 12.4%).
In the MPF-group (n=20) scar tissue perpendicular to the alveolar process could be determined in 9/20 of the cases. The correlation ABR - scar tissue was again clear, it gives rise to a resorption of the alveolar crest of 25.5% up to 45.5% (mABR: 24.8%). In the other eleven patients with no scars in the vestibulum the ABR, although ranging from 0-100%, showed a mABR of 18.2%. The mABR in the total MPF-group is 21.5% (difference: 6.6%). So there seems to be a correlation between ABR and a shallow vestibular sulcus, most likely to be produced by scar tissue in both (FF-MPF) groups.

Radiographical analysis of the morphology of the grafted area at the piriform aperture
On the X-OPT the caudal part of the piriform aperture was observed, it was noticed that a slight depression at the cleft side in comparison with the normal side was present in 11/30. In 9/30 cases a moderate excavation in the aperture was seen. In 10/30 no difference was seen between cleft and non-cleft piriform aperture. Whenever teeth in the former cleft region were absent (n=9) these findings combined resulted in a diabolo shaped alveolar process (n=9) (due to interdental-, buccal- and nasal side bone resorption).

VI.3.2. File analysis

Complications
In the ACR with iliac crest bone, some complications were encountered. Direct postoperative complications such as extreme swelling of the face, haematoma or postoperative infection, were not seen. Wound dehiscensies were not seen in this patient sample. Major bone loss or minimal bone sequestration were not observed. Cervical root resorption was not found, however 4 cuspids were missing at follow-up. Apical resorption, mostly due to orthodontic traction was seen twice in the canine roots. Apical resorption of the central/lateral incisors was observed in 4/30= 13.3% of the patients. After orthodontic treatment in one patient (3.3%) the upper anterior teeth were permanently fixed by a palatal bar. In this case the patient showed obvious apical root resorption.

Reoperations for ACR were not necessary in this sample.

VI.4. Discussion

VI.4.1. Preliminary remark

The methods have been discussed extensively in chapters III and V. Here, the results of the clinical and radiological examinations are discussed.

Comparing our results of ACR with the literature, there are some differences. The patients operated in the 1970's or early 1980's were operated in a different way from later on. The oral layer was closed by the use of finger flaps. The ratio for using vestibular sulcus finger flaps and retaining a rim of alveolar mucosa in the cleft region was to establish a water- and airtight closure over the bone graft (fig. 31).

A number of complicating factors result from the use of the finger flaps. Quarta and Koch (1985, 1989), Enemark et al (1985), Bergland et al (1986) and Enemark et al (1987) thought lack of attached gingiva and the presence of a soft tissue remnant to be a contributing factor to ABR and eruption disturbances. Some of these phenomena were encountered in our FFG.

VI.4.2.1. Cuspid eruption

In the FFG (n=10, impacted cuspids n=4) the incidence of surgical exposure was 1/4= 25%, spontaneous eruption of the impacted cuspids was 75%. So the above mentioned opinion was not confirmed in this sample.

Since the mucoperiosteal (transposition) flaps were used, the spontaneous eruption (n=7) 63.7% of the impacted cuspids (n=11) in the previous cleft region is in accordance with other reports (Hinrichs et al, 1984; Enemark et al, 1985; Paulin et al, 1988) but not as good as in the FFG although this was not tested statistically. Surgical exposure for both groups together of retained canines was needed in 5/15= 33.3% and is comparable with other centres.

In the UCLP-group we encountered 2/5= 40% enlarged dental follicle formation around the impacted cuspid teeth. Paulin et al (1988), Hinrichs et al (1984), El Deeb et al (1982) mentioned also cyst formation around the impacted teeth, however the incidence of the pathological follicle differs widely in the reported cases.

VI.4.2.2. Periodontal status

The periodontal health as referred to mPD, BOP, mobility and color of the gingiva, treated either by finger flaps or the (transpositional) mucoperiostal flaps shows no pathology and no major differences in respect to the non-cleft control teeth. This is rather surprising if one has the actual clinical situation in mind.

Width of the attached gingiva did not differ either. This is remarkable since we expected a wider attached gingiva area in the MPFG. We cannot give a sufficient explanation for this phenomenon. Maybe the FFG people just had a harder thooth brush!

External cervical root resorption of the canine tooth is a serious complication which may lead to the loss of the tooth if left unchecked. Cervical root resorption is usually detected on the routine radiograph and occurs 3-4 years after ACR (Enemark et al, 1985; Bergland et al, 1986). The in the literature reported incidence of cervical root resorption of the canine was not detected in our patients. However it is possible that one or more of the lost canines were extracted because of cervical resorption.

VI.4.2.3. Morphology of the alveolar process

The contour seems highly dependent on the closed dental arch and maybe weakly dependent on angulation of the CAT. The vestibular sulcus is dependent on the scar in the vestibulum and on the surgical technique used.

The degree of total ABR and the depression at the nasal side determines whether a diabolo shaped remodelled alveolar process occurs. This was often seen in our patient-sample (n=9).

We cannot compare this finding with reports in the literature since it is not mentioned. Clearly, also from our results it may be concluded, that scar tissue formation and finger flaps have an unfavourable influence on the buccal aspect of the alveolar process.

The final verdict will be passed in chapter VIII and IX.

VI.4.2.4. Orthodontic status

In most cases 21/30 (70%) the dental arch could be closed orthodontically after ACR, although limitations in the orthodontic results had to be accepted. 8/21 UCLP patients developed a dental arch relation that was beyond orthodontic correction alone: a retrognathia in combination with an anterior open bite, so surgical intervention was indicated. So only in 13/30 (43.3%) the combined ACR and orthodontic treatment could achieve a normal dental arch relation. In addition four had a normal relation with a fixed bridge (13.3%).

Orthodontic closure of the dental gap can also be imagined to be disturbed by the use of finger flaps because of:

1. The soft tissue remnant between the anterior teeth and cuspid.
2. Lack of alveolar crest bone because of resorption due to the scar tissue.
3. A combination of 1 and 2.

However all this did not influence the orthodontic treatment in our UCLP patients.

The overall orthodontic results must be judged as unfavourable, 8/21 maxillary malocclusion (38.1%) and 5/9 compensated interrupted dental arches, means 43.3% patients with a malocclusion that was beyond orthodontic correction alone. In addition eleven anterior open bites (some in combination) were seen. 17 patients had received pre-surgical orthodontic treatment. They did actually better than the 13 patients without pre-surgical orthodontic treatment. Most of these 13 patients received postsurgical orthodontic treatment (11/13) but still needed prosthetic rehabilitations in 5 instances (38.5%). Postsurgical orthodontic treatment therefore did not seem to have improved the end-

results.
In respect of the eleven anterior open bites, we can conclude that the primary surgery (Vomer flap for anterior palate closure), may have produced a remarkable growth retardation in the vertical downgrowth of the maxilla (11/30). As mentioned before our orthodontic results were unfavourable as compared with those of other cleft palate centres (Berkowitz et al, 1982; Enemark et al, 1985; Bergland et al, 1986; Enemark et al, 1987 and Stoelinga et al, 1990; Mars et al, 1992).
Maybe it is the outcome of both anterior palatal surgery and lack of protocolled orthodontic treatment.
However, six patients had undergone a surgical procedure in the alveolar cleft region prior to ACR. As mentioned by Amanat and Langdon (1991) excessive scarring in the cleft area can contribute to ABR because blood supply is diminished and the bone is not covered by periosteum. The orthodontic outcome therefore could also have been influenced by this phenomenon.
Apical root resorption in the cuspid as well as the incisor teeth may be due to the orthodontic treatment (Koole and Egyedi, 1990) and is more frequently encountered in cleft patients than in others (Bergland et al, 1986). Our data weakly confirm this phenomenon. Apical root resorption in UCLP-patients was seen in 4 patients in 6 teeth (4 central incisors, 2 canines). The presence of a semi-permanent bar at the palatal side was noted once. In 9 patients the dental arch was reconstructed by prosthetics, this rather high percentage (30%) is due to hypodontia in the cleft region and the attempt of closing the dental gap by intensive orthodontic treatment could interfere with a normal anterior teeth relation. When a normal sagittal relation is present some of the orthodontists choose for prosthodontic closure. Today maybe a dental implant could solve the problem of atrophy of the grafted cleft area (lack of functional loading).

VI.4.2.5. Oronasal fistula

The results of oronasal fistula closure in FFG and MPFG with iliac crest bone grafting was average as compared with other authors (table 12, chapter V). The incidence of fistulae after ACR was 2/30, 6.67%, about the same as the one reported in chapter V.

VI.4.2.6. Findings at the harvesting site

The complication rate of the harvesting procedure, on the whole, is in accordance with several other reports (Kokcin, 1971; Weikel and Haban, 1977; Stoll et al, 1981; Van der Wal et al, 1986; Canady et al, 1993).

VI.4.2.7. Radiographic examination

Whenever the dental arch was closed and soft tissue configuration favourable, the interdental alveolar crest height as compared to the results of other centres is satisfactory. The mABR in uninterrupted dental arches is 23.6% and therefore one may conclude that iliac crest bone, when functionally stressed, is a reliable bone graft (Bergland et al, 1986). In the

interrupted dental arch group mABR was 43.3%.
We want to stress, however, that also the soft tissue configuration was unfavourable in most of these cases, thus reinforcing the effect of the dental arch not being closed.

VI.5. Conclusions

ACR with iliac crest in unilateral alveolar clefts is a well known, reliable and predictable procedure when prerequisites like timing, oral closure with mucoperiosteal flaps, orthodontic treatment are part of a routine protocol.
These prerequisites were only partially met in the group of patients described in this chapter. Especially the use of finger flaps had an unfavourable influence on the overall result as far as maintenance of the bone graft is concerned. Still, in case of a closed dental arch this mesenchymal bone graft is incorporated satisfactory with an acceptable (23.6%) ABR. And as far as canine eruption is concerned, the result seems quite acceptable.

References

Amanat, N., J.D. Langdon: Secondary alveolar bone grafting in clefts of the lip and palate. J. Cranio-Max.-Fac. Surg. 19 (1991) 7

Axhausen, G.: Technik und Ergebnisse der Spaltplastiken. Hanser, München, 1952

Bardach, J., H. Morris, W. Olin: The Hamburg Project: Late results of multidisciplinary management at the IOWA cleft palate center. In Bardach, J., Morris, H., Eds: Multidisciplinary management of cleft lip and palate. Philadelphia, W.B. Saunders & Co. 1990; 98-112

Bergland, O., G. Semb, F.E. Abyholm: Elimination of the residual alveolar cleft by secondary bone grafting and subsequent orthodontic treatment. Cleft Palate J. 23 (1986) 175

Berkowitz, S., G. Gonzales, L. Nghiem-Phu: An optical profilometer - a new instrument for the three dimensional measurements of cleft palate casts. Cleft Palate J. 19 (1982) 129

Boyne, P.J.: Use of marrow-cancellous bone grafts in maxillary alveolar and palatal clefts. J. Dent. Res. 53 (1974) 821

Boyne, P.J., N.R. Sands: Secondary bone grafting of residual alveolar and palatal clefts. J. Oral Surg. 30 (1972) 87

Boyne, P.J., N.R. Sands: Combined orthodontic-surgical management of residual palato-alveolar cleft defects. Am. J. Orthod. 70 (1976) 20

Canady J.W., D.P. Zeitler, S.H. Thompson, C.D. Nicholas: Cleft Palate-Cranio-Fac. J. 30 (1993) 579

Cockin, J.: Autologous bone grafting. Complication at the donor site. J. Bone Joint Surg. 53 (1971) 153

El Deeb, M., L.B. Messer, M.W. Lehnert, T.W. Hebda, D.E. Waite: Canine eruption into grafted bone in maxillary alveolar cleft defects. Cleft Palate J. 19 (1982) 9

Enemark, H., E. Krantz-Simonsen, J.E. Schramm: Secondary bone grafting in unilateral cleft lip palate patients: indications and procedure. Int. J. Oral Surg. 14 (1985) 2

Enemark, H., S. Sindet-Pedersen, M. Bundgaard: Long-term results after secondary bone grafting of alveolar clefts. J. Oral Max.-Fac. Surg. 45 (1987) 913

Hinrichs, J.E., M.E. El Deeb, D.E. Waite, R.R. Bevis, C.C. Bandt: Periodontal evaluation of canines erupted through grafted alveolar cleft defects. J. Oral Max.-Fac. Surg. 42 (1984) 717

Koberg, W.R.: Present view on bone grafting in cleft palate (a review of literature). J. Max.-Fac. Surg. 1 (1973) 185

Koole, R., P. Egyedi: The case for postoperative orthodontics in orthognathic surgery. J. Cranio-Max.-Fac. Surg. 18 (1990) 293

Krüger, E. K. Krumholz, H.-W. Krannich, E.A. Holtgrave, J. Schlupper-Beckmann: Long-term results in unilateral clefts of lip, alveolus and palate. In: Pfeifer, G.: Craniofacial abnormalities and clefts of the lip, alveolus and palate. 4th Hamburg International Symposium 1991

Larson, O., M. Ideberg, J. McWilliam, K.-E. Nordin: Early bone grafting in unilateral complete cleft lip and palate cases following maxillofacial orthopedics (skeletal and soft tissue development from 7 to 17 years of age). In: Pfeifer, G.: Craniofacial abnormalities and clefts of the lip, alveolus and palate. 4th Hamburg International Symposium 1991

Mars, M., C. Asher-McDade, V. Brattström, E. Dahl, J. McWilliam, K. Molsted, D.A. Plint, B. Prahl-Andersen, G. Semb, W.C. Shaw, R.P.S. The: A six-center intrenational study of treatment outcome in patients with clefts of the lip and palate: part 3. Dental arch relationships. Cleft Palate-Craniofac. J. 29 (1992) 405

Mrazik, J., C. Amato, S. Leban, A. Mashberg: The ilium as a source of autogenous bone for grafting: clinical considerations. J. Oral Surg. 38 (1980) 29

Nordin, K.E., B. Johanson: Freihe Knochentransplantationen bei Defekten im Alveolarkamm nach Kieferorthopädischer Einstellung der Maxilla bei Lippen-Kiefer-Gaumen-Spalten. Fortschr. Kiefer-Gesichtschir. Vol. 1, Thieme, Stuttgart (1955) 168

Paulin, G., P. Astrand, J.B. Rosenquist, L. Bartholdson: Intermediate bone grafting of alveolar clefts. J. Cranio-Max.-Fac. Surg. 16 (1988) 2

Pruzanski, S.: Pre-surgical orthopedics and bone grafting for infants with cleft lip and palate: a dissent. Cleft Palate J. 1 (1964) 164

Quarta, M., J. Koch: Mundvorhofplastik beim LKGS-Spaltträger unter Verwendung von Polyglactin-Netz. Zahnärztl. Prax. 35 (1985) 344

Quarta, M., J. Koch: Metric results of vestibuloplasty in unilateral cleft patients. J. Cranio-Max.-Fac. Surg. 17 (1989) 175

Rosenstein, S.W., C.W. Monroe, D.A. Kernahan, B.N. Jacobson, B.H. Griffith, B.S. Bauer: The case for early bone grafting in cleft lip and cleft palate. Plast. Reconstr. Surg. 70 (1982) 297

Rosenstein, S.W., D.A. Kernahan: Long-term follow-up on patients with complete clefts of the lip, alveolus and palate. In: Pfeifer, G.: Craniofacial abnormalities and clefts of the lip, alveolus and palate. 4th Hamburg International Symposium (1991) 279

Ross, R.B.: Treatment variables affecting facial growth in complete unilateral cleft lip and palate. Part 1-7. Cleft Palate J. 24 (1987) 5

Schmid, E.: Die Annäherung der Kieferstümpfe bei Lippen-Kiefer-Gaumen-Spalten; ihre schädlichen Folgen und Vermeidung. In: K. Schuchardt: Fortschr. Kiefer-, Gesichtschir. Vol. 1, Thieme, Stuttgart (1955) 37

Schwenzer, N.: Primary bone grafting and maxillary growth in unilateral clefts or lip, alveolus and palate. In: Pfeifer, G.: Craniofacial abnormalities and clefts of the lip, alveolus and palate. 4th Hamburg International Symposium (1991) 282

Stoelinga, P.J.W., P.E.J.J. Haers, R.J. Leenen, R.J. Soubry, P.A. Blijdorp, J.H.A. Schoenaers: Late management of secondarily grafted clefts. Int. J. Oral Max.-Fac. Surg. 19 (1990) 97

Stoll, P., W. Schilli: Long-term follow-up of donor and recipient sites after autologous bone grafts for reconstruction of the facial skeleton. J. Oral Surg. 39 (1981) 676

Stoll, P., W. Schilli, U. Joos, I. Jonas, W. Mann: Growth of the facial skeleton in adult patients with unilateral cleft lip and palate following either early or late secondary osteoplasty of the alveolus. In: Pfeifer, G: Craniofacial abnormalities and clefts of the lip, alveolus and palate. 4th Hamburg International Symposium (1991) 289

Van de Wal, K.G.H., J.G.A.M. de Visscher, P.J.W. Stoelinga: The autogenous innertable iliac bone graft. J. Max.-Fac. Surg. 14 (1986) 22

Weikel, A.M., M.B. Habal: Meralgia Paresthetica: a complication of iliac bone procedurement. Plast. Reconstr. Surg. 60 (1977) 572

Witsenburg, B., H.P.M. Freihofer: Autogenous rib graft for reconstruction of alveolar bone defects in cleft patients. Long term follow-up results. J. Cranio-Max.-Fac. Surg. 18 (1990) 55

Chapter VII

Mesenchymal bone grafting (anterior iliac crest) for alveolar cleft repair in tertiary cases; Late results - a clinical and radiological follow-up -

Chapter VII

Mesenchymal bone grafting (anterior iliac crest) for alveolar cleft repair in tertiary cases; Late results
- a clinical and radiological follow-up -

VII.1. Introduction

In the teen-aged or adult cleft patient (fig. 36) with scarring of the palate and/or other growth retarding factors, notwithstanding orthodontic treatment a (severe) maxillary retrognathia can result (fig. 37).
In former days these cleft patients were reconstructed by overdentures or other maxillofacial prothetic appliances. Since 1972 the Le Fort I osteotomy was introduced in our department (Egyedi, 1973, 1975), many patients shared the benefits of this procedure. In order to prevent relapse it was, at least in our department, routine to open the fibrous alveolo-palatal cleft scar. The reopened cleft was closed in another surgical intervention after 6-12 month (Koole, 1990) including the so called TACR. The interrupted dental arch was treated prosthodontically. Another category of cleft patients subjected to TACR are those with oro-nasal communications: the closure of the fistula in the alveolar process region is best performed with a bone graft (3-layer closure) (Perko, 1966).

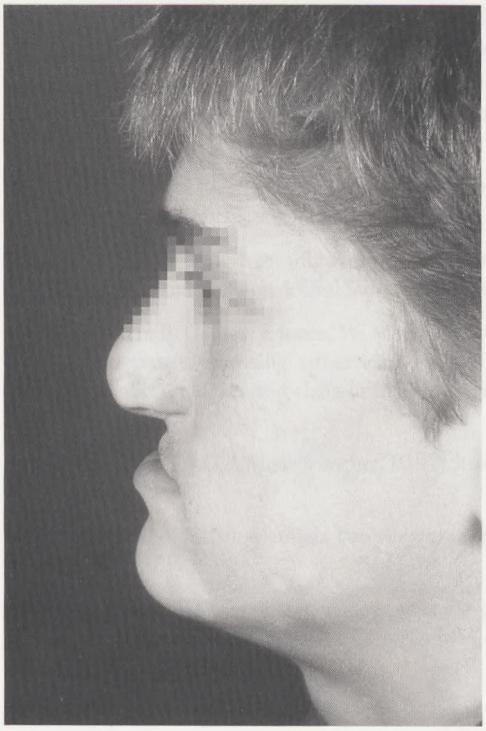

Figure 36. *Retrognathia of the maxilla in an UCLP-patient. Note the reversed lip relation and the hypoplasia in the molar region. Typical nose deformity.*

Figure 37. *Class III, reversed interdental arch relation. A closed dental arch in the cleft region was achieved after ACR and orthodontic treatment.*

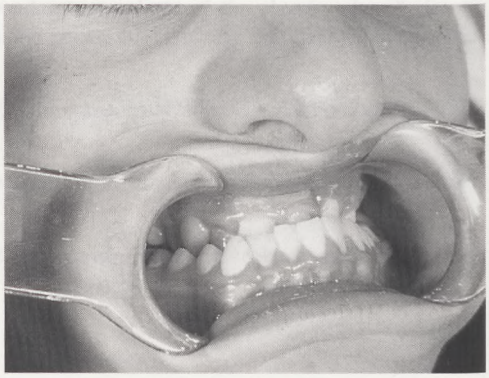

This UCLP patient group is introduced in this study to put the results of (secondary) ACR in perspective and to compare orthodontic (functional) versus prosthodontic (non-functional) treatment. However, at present, when hypodontia exist in the grafted cleft area and/or orthodontic treatment is not indicated/not-able to close the gap in the dental arch, insertion of a dental implant is advocated (Hillerup et al, 1987; De Wijs, 1993).
A functional stimulus to the bone is intended to be transferred, so volume and contour of the reconstructed alveolar process is hopefully maintained. These patients are not included in the study. The results of the TACR is reported in this chapter.

VII.2. Material and methods

VII.2.1. Patients

This patient sample consists of 18 patients born with a complete unilateral cleft lip alveolus and palate.
As described in chapter VI the patients are part of an extended cleft population treated in our department since 1938 by Tjebbes and his successors. The majority of the older cleft patients had a poor dental health, all patients showed acquired or congenital hypodontia. The alveolar cleft was classified as wide in 9/18, normal in 8/18 and small in one patient. Fourteen patients had previously undergone a Le Fort I advancement procedure because of moderate to severe retrognathia of the maxilla, some in combination with presurgical orthodontic treatment (5/14). The alveolar palatal defect had been obturated for a long time with a prosthodontic appliance in four patients. These patients underwent TACR with iliac crest bone for oronasal fistula closing and subsequent new prosthodontic treatment.
In all patients the TACR took place after 17.5 years of age.

VII.2.2. Previous surgery and dental treatment

All patients had been treated as a baby (by the same surgeon) for cleft lip repair according to Veau and anterior palate closure (Vomer flap). In principle, at the age of 30 months they had been operated for hard and soft palatal repair according to Wardill-Kilner.

Table 20.

variables	*gender distribution male:female*	*left-right*	*mean and median age at TACR*	*pre-surgical orthodontics*			*previous surgery*	*postoperative orthodontic treatment*	*follow-up*
N=18			*range: 17.65-28.90*	*front*	*expansion*	*front + expans.*			*range: 0.72-9.83y*
UCLP	*14:4*	*14:4*	*mean 20.44 median 19.64*	*2*	*–*	*3*	*Le Fort: 14 oronasal fist.: 4*	*2*	*mean 5.52 y median 5.89 y*

Sometimes however the procedure had been delayed up to an age of 6 years (Blijdorp, 1984).
The mean age at TACR, previous treatment before TACR and other variables are depicted in table 20.
The Le Fort I surgical procedure (Wassmund, 1935; Axhausen, 1941, Obwegeser, 1965) executed before 1987, was performed via vertical vestibular incisions, tunneling, osteotomy, down-fracture, positioning, inter-osseous wiring, rib grafts and cranio-mandibular fixation by peri-zygomatic wiring. After Le Fort I osteotomy and TACR twice a pre-prosthetic-post-surgical orthodontic treatment was executed; the dental arch was reconstructed by fixed (n=12) or removable prosthodontics (n=2).
The 4 patients who had not had an osteotomy before TACR all got new dentures after healing had occurred.
One maxillary canine was impacted at the time of TACR.

VII.2.3. Treatment procedure
The surgical procedure (performed between 1978-1987) did not differ essentially from the ACR described in the previous chapter. Finger (Burian) flaps (n=13) from the vestibular sulcus were mainly used for oral closure; antibiotics were administered i.v. for 7 days. The procedure was executed in general endo-tracheal anaesthesia. Postoperatively, the 18 patients after TACR, were treated in the department of Maxillofacial Prosthetics of the former Dental School Utrecht and reconstructed by removable prosthodontic appliances or fixed crown- and bridgework. The dental treatment commenced approximately one year after TACR.

VII.2.4. Methods of examination
The evaluation took place in the same way, although the UCLP-patients differed considerably with the patients described earlier. Investigated were:
1. Periodontal state of the maxillary test teeth
2. Morphology of the reconstructed alveolar process and vestibular sulcus
3. "Orthodontic status" was dictated by the prosthodontist's reconstructed dental arch
4. Presence of fistulae to the nose
5. Bone donor area
6. Radiological examination of ABR
   a. the interdental alveolar crest height
   b. status of the piriform aperture

VII.3. Results

Ad 1. Periodontal status.
The size of the residual edentulous space was variable; the distance of the central incisor (n=7) adjacent to the cleft to the opposing cleft adjacent tooth varied; even the contrala-

Table 21.

Probing depth distofacial

	CLPD4	NCPD4	CLPD3 CAC	NCPD3	CLPD2 CALI	NCPD2	CLPD1 CACI	NCPD1
Count	18	18	18	18	18	18	18	18
Valid N	17	16	14	16	–	14	7	16
Mean	2.12	1.75	2.29	1.81	–	1.79	2.00	1.94
St. dev.	0.78	0.58	0.91	0.66	–	0.58	–	0.57
P values	ns		P=0.028		no variance		no variance	
Minimum	1.00	1.00	1.00	1.00	–	1.00	2.00	1.00
Median	2.00	2.00	2.00	2.00	–	2.00	2.00	2.00
Maximum	4.00	3.00	4.00	3.00	–	3.00	2.00	3.00

CLPD= cleft side probing depth distofacial aspect
NCPD= non cleft side probing depth distofacial aspect
1, 2, 3, 4= central, lateral incisor, cuspid, bicuspid
ns= not significant
CAC= cleft associated canine
CALI= cleft associated lateral incisor
CACI= cleft associated central incisor

Probing depth mesiofacial

	CLPM4	NCPM4	CLPM3 CAC	NCPM3	CLPM2 CALI	NCPM2	CLPM1 CACI	NCPM1
Count	18	18	18	18	18	18	18	18
Valid N	17	16	14	16	–	14	7	16
Mean	2.06	1.75	1.86	1.69	–	1.86	2.00	2.13
St. dev.	0.90	0.58	0.66	0.60	–	0.53	–	0.62
P values	ns		ns		no variance			ns
Minimum	1.00	1.00	1.00	1.00	–	1.00	2.00	1.00
Median	2.00	2.00	2.00	2.00	–	2.00	2.00	2.00
Maximum	4.00	3.00	3.00	3.00	–	3.00	2.00	3.00

CLPM= cleft side probing depth mesiofacial aspect
NCPM= non cleft side probing depth mesiofacial aspect
1, 2, 3, 4= central, lateral incisor, cuspid, bicuspid
ns= not significant
CAC= cleft associated canine
CALI= cleft associated lateral incisor
CACI= cleft associated central incisor

Attached gingiva (width), mean values (FFG+MPFG)

	CLAG4	NCAG4	CLAG3 CAC	NCAG3	CLAG2 CALI	NCAG2	CLAG1 CACI	NCAG1
Count	18	18	18	18	18	18	18	18
Valid N	17	16	14	16	–	14	7	16
Mean	3.53	3.31	2.29	2.50	–	3.29	1.43	2.50
St. dev.	1.18	1.40	1.14	0.97	–	1.33	1.40	1.57
P values	ns		ns		–		ns	
Minimum	1.00	2.00	0.00	1.00	–	1.00	0.00	0.00
Median	4.00	3.00	2.50	2.50	–	3.50	2.00	3.00
Maximum	6.00	6.00	4.00	5.00	–	5.00	3.00	5.00

CLAG= cleft side attached gingiva
NCAG= non cleft side attached gingiva
1, 2, 3, 4= central, lateral incisor, cuspid, bicuspid
ns= not significant
CAC= cleft associated canine
CALI= cleft associated lateral incisor
CACI= cleft associated central incisor

teral incisor often "bordered" the former cleft area (n=11); The CAC was more constantly present (n=14).

A comparison of mPD of the CAT mesial of the cleft at the surface facing the clefts (often the distofacial aspect) and the mPD on the contralateral side showed no significant difference in a paired samples t-test (mPD= 2.00mm). The mPD's _ 2mm, at the cleft side and non-cleft related teeth are depicted in table 21.

Comparing the mesiofacial PD of the CAC with the non-cleft, the mPD (1.86mm) was not significantly different. The PD of 4mm was measured in a single cleft patient. Teeth supporting a removable appliance or the teeth with fixed bridgework showed more pathology: mPD CAC distofacial 2.29mm versus 1.81mm ($P<0.05$). BOP was 1:3.4 in the CAT, however prosthodontic abutments were present in all cases which explains this finding sufficiently in our view. The mobility was not investigated, because of the prosthodontic appliances.

The mean width of attached gingiva in the former cleft region at the CACI was reduced (1.43mm); due to finger flap closure (n=13). The CAC at the grafted cleft showed sufficient attached gingiva (width > 2.0mm). The colour of the gingiva was in accordance with what to expect in the removable or fixed dental appliances group. It was not remarkably more bluish-red in the cleft related teeth than in the non-cleft related teeth.

Cervical root resorption was not found at follow-up time. Why so many teeth were lost in the cleft region remains unclear however (CACI, n=7).

results / closure / oral layer	UCLP Patients N=18				
	vestibulum			buccal contour alveolar process	
	physiological	shallow	scarred	concave	normal
local mucoperiosteal flaps n=3	1	2	–	2	1
transpositional mucoperiosteal flaps n=2	1	1	–	1	1
finger flaps n=13	2	9	2	12	1
total	4	12	2	15	3

Table 22. *Influence of flap design on resulting vestibular sulcus depth in 18 UCLP-patients treated by TACR > 17.5 years*

Ad 2. Morphology of the alveolar process and vestibular sulcus.
The contour of the alveolar process was registered as concave in most cases (15/18), in accordance with the extent of the edentulous grafted area. All patients had been reconstructed with prosthetic dentistry, one overdenture, 5 stainless steel removable dentures and 12 fixed bridges (fig. 5).
In the buccal sulcus of the former alveolar cleft we found scars perpendicular to the alveolar process in 12/13 patients closed with a finger flap. In the mucoperiosteal group (n=5) two normal vestibular sulci were found (viz. table 22).

Ad 3. Prosthetic/orthodontic status.
Orthodontic treatment pre-operatively had been given in 5 patients, one received also postsurgical orthodontics and was reconstructed with fixed bridgework. The other four were reconstructed with a removable appliance (2) and fixed prosthodontics (2). The two patients who underwent post-surgical orthodontic treatment only, ended up with a fixed bridge over the cleft area. Eleven (non orthodontically treated) UCLP-patients (seven after Le Fort I and TACR, four with TACR for fistula closing) were reconstructed with seven fixed and 3 removable appliances respectively, one was treated with an overdenture. The intermaxillary relationship of the prosthetically reconstructed cleft patients can be summarized as follows: molar region 10/18 normal, cuspid area 14/18 normal, sagittal front relation 15/18 normal, two anterior open bites and one vertical deep overbite. It appears that the corrective osteotomy (Le Fort I) allowed the prosthodontist on the whole to make a (fixed) reconstruction in a more or less class I relation.

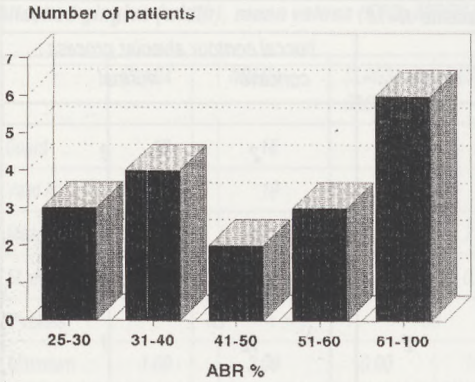

Figure 38. *Alveolar bone resorption (ABR%) in 18 UCLP-patients grafted after 17.5y with iliac crest bone - interrupted dental arch.*

Figure 39. *Atrophy, "demodelling", of the alveolar process in a non-cleft patient. Note the resemblance of the area of interest and the resorption sites.*

Ad 4. Oronasal fistula.

Oronasal fistulae were present pre-operatively in 11/18 UCLP-patients, most patients had actual complaints about liquid passage to the nose. One patient still had an oronasal fistula at follow-up and complained about liquid and air leakage to the nose (9.1%). Also a fistula was produced after TACR (1/6= 16.6%). The overall presence of oronasal communications after TACR was 2/18 (11.1%).

Ad 5. The bone donor area.

An unpleasant scar was seen in 3/18 patients, one patient had complaints about intermittent pain in the donorregion.

The length of the scars varied from 3.1-8.2cm with a mean of 6.2cm. Complaints about the dip in the iliac crest were minimal. Long term gait disturbances were not mentioned. Severe complications were not observed in this patient sample.

Ad 6. Radiological examination. Measurement of ABR.

The interdental alveolar crest height was reduced in all patients far over 25% (fig. 38). The mABR is 54.9%. The presence of scar tissue or a pedicle of a finger flap gave rise to an ABR between 26.7% and 100% (mABR=55.3%). The physiological vestibular sulcus (n=4) showed a mABR of 50.7%.

On the X-OPT the caudal part of the reconstructed piriform aperture was observed: a symmetrical appearance was seen in 2/18 patients. Moderate asymmetry was present in 5/18. The majority of the patients (11/18) showed an excavated, asymmetrical aperture. The diabolo shaped appearance of the bone grafted cleft was present in 16/18 patients due to ABR at all sites.

VII.3.2. File analysis

Complications. In this group, direct postoperatively major complications were not observed. Minor bone sequestration due to wound dehiscencies was seen in 4 patients (22.7%). Complications concerning orthodontic treatment were not seen because no extended orthodontic therapy was performed. Prosthodontic reconstructions were not investigated.

VII.4. Discussion and conclusion

All these patients underwent bone grafting for oronasal fistula closure and alveolar process reconstruction after a Le Fort I osteotomy and prior to subsequent prosthodontic treatment.
The periodontal status after ACR and subsequent prosthodontic closure of the dental arch resulted in a comparable state of periodontal health that is accomplished in a non-cleft patient with extensive crown and bridge rehabilitation. This is in accordance with Ramstad (1989). The oral hygiene after extended surgery and dental treatment was improved dramatically compared with the initial pre-operative findings. This was deducted from remarks in the files.
The not functionally loaded former alveolar cleft area showed a mABR 54.9%. An additional negative factor was the scar tissue in the vestibular sulcus (viz. table 22).
The data illustrate clearly the lack of functional loading of of bone (fig. 39).
Another main point of interest is the size of the pre-operatively existing alveolar cleft, after Le Fort I expanding surgery: the cleft was classified as wide in 9/14 patients. This point is also of interest for the findings at the harvesting site (scar length) more iliac crest bone had to be harvested.
From a prosthodontic point of view the presence of the vestibular sulcus flaps was not unfavourable because the alveolar process was in a way built up by soft tissue and the dummy of the fixed bridges could be placed on top of the soft tissue, so the vestibular appearance of the fixed bridgework was satisfactory. In case of removable appliances the acrylic part of the appliance restored the buccal alveolar aspect.
Oronasal fistula in this group (re)occurred in 11.1%, but were "functionally" closed by the prosthodontic appliance.

The need for prosthodontic postsurgical treatment will diminish in the near future, due to better primary surgery, interceptive orthodontic treatment, proper timing for orthodontic treatment and ACR. The incidence of severe retrognathia is also expected to diminish; so for children born nowadays with a cleft, the prosthetic appliances will almost be banished. In most cases the dental arch can be closed by natural teeth. Only a single tooth (CALI) will hopefully have to be replaced by dental implants in bone grafted clefts (Hillerup et al, 1987). When yet there is severe hypodontia extended prosthodontic dentistry and dental implants will still have to be the treatment modality.

References

Axhausen, G.: Technik und Ergebnisse der Lippenplastik. Georg Thieme Verlag Leipzig (1941) 107-109

Blijdorp, P.A.: De invloed van de leeftijd van sluiten van het palatum bij de schisispatiënt op kaakgroei, KNO-status, spraak en persoonlijkheidsontwikkeling. Proefschrift R.U. Utrecht, 1984

Egyedi, P.: Chirurgische correctie van de gedeformeerde maxilla bij volwassen patiënten met cheilognathopalatoschisis. Ned. Tijdschr. Geneesk. 117 (1973) 25

Egyedi, P.: Orthodontische chirurgie bij volgroeide schisispatiënten. Ned. Tijdschr. Tandheelk. 82 (1975) 289

Hillerup, S., E. Dahl, O. Schwartz, E. Hjorting-Hansen: Tooth transplantation to bone graft in cleft alveolus. Cleft Palate J. 24 (1987) 137

Koole, R.: Behandeling van de schisispatiënt. Overzicht en achtergronden. Ned. Tijdschr. Tandheelk. 97 (1990) 472

Obwegeser, H.: Eingriffe am Oberkiefer zur Korrektur des progenen Zustandsbildes. Schweiz. Monatschr. Zahnheilk. 75 (1965) 365

Perko, M.: Gleichzeitige Osteotomie des Zwischenkiefers, Restspaltenverschluss und Zwischenkieferversteifung durch sekundäre Osteoplastik bei Spätfällen von beidseitigen Lippen-Kiefer-Gaumen-Spalten. Dtsch. Zahn-Mund-Kieferheilk. 47 (1966) 1

Ramstad, T.: Periodontal condition in adult patients with unilateral complete cleft palate. Cleft Palate J. 26 (1989) 14

Wassmund: Lehrbuch der Praktischen Chirurgie des Mundes und der Kiefer. Vol. I. Meusser, Leipzig, 1935

De Wijs, F.: Academisch Proefschrift Universiteit Utrecht, 1993

Chapter VIII

Comparative analysis of the results of ACR in 20 UCLP-patients grafted with mandibular symphysis bone and 30 UCLP-patients grafted with anterior iliac crest bone; General Discussion

Chapter VIII

Comparative analysis of the results of ACR in 20 UCLP-patients grafted with mandibular symphysis bone and 30 UCLP-patients grafted with anterior iliac crest bone; General Discussion

VIII.1. Introduction

The number of patients in the Groningen (Group I) and Utrecht (Group II) patientsamples was reduced from 57 to 20 and from 113 to 30 UCLP-patients respectively; it enabled us to arrive at some sort of standardization of those patients which we wanted to compare. In the older group (III) which was introduced for perspective goal, the selection criteria here were an unilateral complete cleft of lip, alveolus and palate and bone graft surgery after 17.5 years of age.

"Discarded" were all patients with an intact palate at birth, "regrafted" patients, patients grafted during an osteotomy, the truly adult ones, the BCLP-patients, the patients with overdentures.

We assume all six parameters (viz. I.2.) to be distributed equally in the patient groups. Selection, however is a "biasing" factor; nevertheless the three remaining UCLP-patients samples are regarded as useful for an exploratory study. To some extent a confirmatory analysis will be attempted.

The validity and the relevance of the parameters is dealt with in the discussion of chapter III, V, VI and VII. If necessary, additional remarks are made in this chapter. As stated

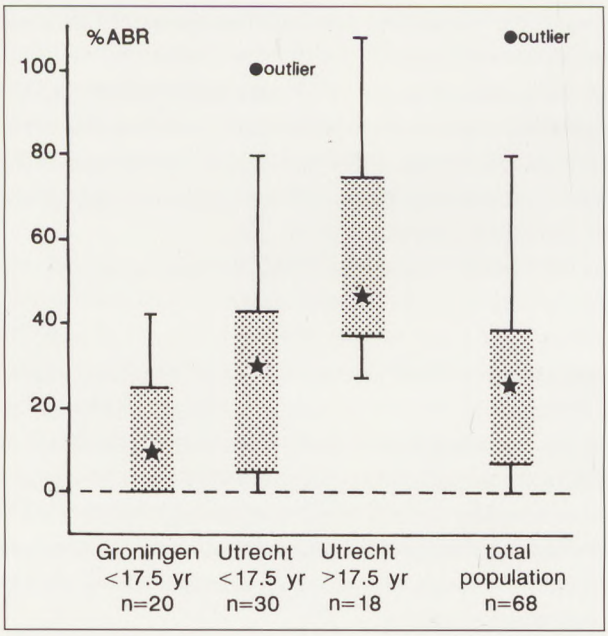

Figure 40. *Boxplot of the three UCLP-patientsamples indicating the IQR of the ABR and the range of ABR.*
** = median ABR*
IQR= Inter Quartile Range= the dotted bar

before the radiological parameter mABR is used as an indicator for functional loading of the transplanted bone and also as a measure for the quality of the graft.
The ABR, in the total UCLP-patient sample (group I, II and III: N=20 - chapter V; N=30 - chapter VI, N=18 - chapter VII) (n=68) is normally distributed (viz. fig 40). The grand mean mABR in the total population is 30.7% (0-100%) with a standard error 3.27%. In the Groningen patients (I), the mABR=10.9% (0-42.3%) with standard error of 2.47%. The distribution is normal with one outlier (42.3%) (Skewness: 1.1607, Kurtosis: 1.9143).
In group II grafted with iliac crest bone before 17.5 years (n=30) the ABR was normally distributed, mABR 29.5%, standard error 4.84% (Skewness: 0.9009, Kurtosis: 0.5064). In group III (n=18) the ABR was also normally distributed, a mABR 54.9%, standard error 6.21% (Skewness 0.9308, Kurtosis 0.1348). In VIII.2 the results will be compared and analysed as to the six parameters which were mentioned in the "statement of problems" (I.2); in VIII.3 the General Discussion is presented.

VIII.2. Comparison and analysis of the results with respect to the research objectives

VIII.2.1. Cuspid eruption

Is there a difference in spontaneous canine eruption into the graft?
In group I 10 cuspids were unerupted after ACR. One was transplanted during grafting surgery. Six erupted spontaneously, the other 4 (40%) had to be assisted. In group II 15 (50%) cuspids were still unerupted after ACR of which 10 (66.7%) erupted spontaneously and 5 (33.3%) had to be assisted. The length of the root (if $\leq$ 2/3 of the estimated final length) of the canine is of importance because eruption should be facilitated (Boyne and Sands, 1972, 1976). In group I two out of two "2/3 root cuspids" needed surgical uncovering, in group II 5 out of 9 needed surgical assistance in the eruption.
Apparently there is a slightly more favourable result in the "mesenchymal bone graft" group (II) as compared to the ectomesenchymal (I) one (66.7% vs 60% spontaneous eruption). The follicle cyst formation was not found to be very different either. It is obvious that statistics is not needed for further analysis.
In respect to the outcome of ABR, the length of the canine root may be important, many authors in accordance with Boyne and Sands (1972, 1976) state that the optimal dental age for ACR is the period when the canine root is up to 2/3 of its final length. In group I 2 canines and in group II 9 roots were in that stage of development. Nine canines in group I

cuspid status / group	impacted prae-op	spontaneous eruption	surgical uncovering	cyst formation
I. Groningen	11 (55%)	6 (60%)	(4) 40%	10%
II. Utrecht	15 (50%)	10 (66.7%)	(5) 33.3%	13.3%

Table 23. *Cuspid status and eruption after ACR in UCLP patients < 17.5 years*

	<2/3 cuspid length	cuspid root completed covered by mucoperiost	fully erup-ted during ACR	mABR
Group I Groningen < 17.5 y	7.2 (2)	14.6 (9)	8.1 (9)	10.9 (20)
Group II Utrecht < 17.5 y	17.8 (12)	27.5 (3)	39.3 (15)	29.5 (30)
Total numbers n=50	16.2 (14)	17.8 (12)	26.6 (24)	22.1 (50)

Table 24. *The mABR% in 50 UCLP patients in relation with the cuspid root length*

were covered by an intact periosteum whereas in group II 3 showed a similar condition.
If we perform an ANOVA procedure (analysis of variances) with respect to ABR with the variables canine root length and research group (I+II n=50), no two way interactions are seen (F=0.985, P=0.381).
The difference in ABR (grand mABR: 22.1%) between the research groups (I and II) is highly significant (F= 11.757; P= 0.001). However, the length of the cuspid tooth is of importance but not significant anymore (F= 2.794; P=0.072). For details see table 24.

VIII.2.2. Periodontium

Is there a difference in the periodontal condition of the teeth in the former cleft area?

The findings are summarized in table 25.
As to the results, we can state in the first place, that a truly pathological condition was found in one patient only in the Groningen and in the (younger) Utrecht groups. So in this respect, there does not seem to be a different outcome of the investigation.
Because of the other numbers being too small, only the CAC and the CACI are compared. It is clear that the difference mf mPD (1.83mm) versus mf mPD (2.00mm) at the CAC in favour of the Groningen group in combination with df mPD (1.63mm) versus df mPD (1.91mm) at the CACI show a slight advantage of the Groningen periodontal condition as far as PD is concerned. To the width of the attached gingiva, it being at the CAC 3.72mm (group I) versus 2.30mm (FFG) and 1.75mm (MPG) (group II) and at the CACI 3.37mm vs 1.86 (FFG) and 1.88 (MPG) (group II) respectively, the Groningen patients were more favourable.
The BOP in the Groningen group is less favourable, than in the Utrecht one, which mainly reflects on a better dental hygiene in the latter.
It should be noted that there is hardly any difference between the two groups as far as the non-cleft adjacent teeth is concerned.
As to group no. III the periodontal status is less favourable with respect to the cleft adjacent teeth, than in group I and II, very likely due to the more extensive prosthodontic rehabilitation.

		C test CAC	c l e f t * c l e f t * c l e f t *	I1 test CACI	m i d l i n e * m i d l i n e * m i d l i n e *	I1	I2 control elements	C
number		18		19		20	9	20
Groningen I	mPD (mm)	mf 1.83 ± 1.15		df 1.63* ± 0.76		df 1.30* ± 0.47	mf 1.56 ± 0.73	mf 1.65 ± 0.99
chin bone graft n=20 <17.5 y	WG (mm) MP	3.72 ± 2.65		3.37 ± 2.01		3.80 ± 1.36	5.22 ± 1.64	4.10 ± 1.59
	bleeding (36%)	+		+		+		
number		26		23		30	19	29
Utrecht II	mPD (mm)	mf 2.00 ± 0.63		df 1.91 ± 0.51		df 1.87 ± 0.78	df 1.95 ± 0.78	mf 1.90 ± 0.83
iliac crest graft n=30 <17.5 y	WG (mm) FF MP	2.30 ± 1.06 1.75 ± 1.57		1.86 ± 0.90 1.88 ± 1.15		2.40 ± 0.97 2.53 ± 1.43	3.43 ± 1.27 4.18 ± 4.33	2.11 ± 0.93 1.68 ± 1.49
	bleeding (23%)	+		+				
number		14		7		16	14	16
Utrecht III	mPD (mm)	mf 1.86 ± 0.66 df 2.29** ± 0.91		mf 2.00 ± 0.0 df 2.00 ± 0.0		mf 2.13 ± 0.62 df 1.94 ± 0.57	mf 1.86 ± 0.53 df 1.79 ± 0.58	mf 1.69 ± 0.60 df 1.81** ± 0.66
iliac crest > 17.5y n=18	WG (mm) FF/MP	2.29 ±1.14		1.43 ± 1.40		2.50 ± 1.51	3.29 ± 1.33	2.50 ± 0.97
	bleeding (30%)	+		+		+		+

Table 25

Bleeding + mPD= mean probing depth (mm) mf= mesiofacial (mm) FF= finger flap
Moderate Bleeding ++ df= distofacial (mm) WG= width gingiva (mm) MP= mucoperiosteal flap

*Periodontal differences of importance and/or significance. *= P<0.01, **= P<0.03 (paired samples t-test)*

VIII.2.3. Morphology of the alveolar process

Is there a difference in the morphology of the alveolar process in the former cleft area?

Here a clear difference was found in favour of the Groningen group (table 26): a concave buccal alveolar contour was found in two cases only (10%) in the 20 patients, whereas in the 20 Utrecht patients who also had an oral closure by mucoperiosteal flaps 8 (40%) had a concave alveolar process. The two Groningen patients with a concave alveolar process both had an interrupted dental arch which had been treated with a bridge, whereas only one Utrecht patient had an interrupted arch (which had been treated with a partial denture).

In order to judge the results of the oral closure method an analysis was done on the correlation mucoperiosteal flaps - vestibular sulcus. No predictable outcome could be determined. In 50% (table 26) a normal or shallow vestibular sulcus resulted (chapter V, VI)

		I Groningen			II Utrecht				
		mucoperiost. flap (MPF)		mABR (%)	mucoperiost. flap (MPF)		finger flaps (FF) (n=10)	mABR (%)	
		local (n=11)	transp. (n=9)	MPF	local (n=15)	transp. (n=5)		MPF	FF
vestibulum	Normal	54.5%	44.4%	13.0	60%	40%	50%	19.4	39.9
	Shallow	45.5%	55.6%	8.8	40%	60%	50%	23.0	52.3
concavity	Concave	10%		9.1	40%		80%	29.1	53.3
	Normal	90%		11.1	60%		20%	18.8	17.5
divergence	CAT	no influence		–	minor import.		no influence	–	–
overall mABR (%)				10.9				21.2*	46.2*

Table 26. *Vestibular sulcus and buccal contour of the reconstructed alveolar cleft in relation to oral closure method and mABR%*
Local= mobilised local mp-flaps
Transp.= transpositional MP-flaps

independent of the operating technique. Even the finger flaps give rise to a normal or a shallow vestibular sulcus in 50% of the patients.

VIII.2.4. Orthodontic results

Is there a difference in the percentage of uninterrupted dental arches resulting from orthodontic treatment?

The answer to this question is: probably not, 16 (80%) closed dental arches in Groningen versus 21 (70%) in Utrecht. It should be borne in mind that the percentage of lost CAT is: 40% vs 58.7%.

When we consider the dental arch relationship in both groups (exclusion of prosthetic normal front relation) in a clinical way a class I anterior intermaxillary relation was obtained in the Groningen patientsample in 12 (75%). In the Utrecht group 13 (61.9%) resulted in a normal or acceptable class I relation. There may have been a relation with pharyngoplasty (see VIII.2.7).

VIII.2.5. Oronasal fistulae

Is there a difference in success rate as to closure of fistulae?

In the Groningen UCLP-patients there are pre-operatively 7 (35%) fistulae. The incidence of fistulae in the Utrecht UCLP-patients (11 (36.6%)) was not different.

Postoperatively two fistulae persisted in both groups (10% vs 6.6%), but the patients had no complaints of the persisting oronasal communication. Only with pressure air could be blown into the nose. The fistulae were localized on the palatal side.

VIII.2.6. Alveolar bone resorption and X-ray analysis of the piriform aperture

In this section we will deal with the following questions:

a. Is there a difference in ABR of the interdental alveolar crest of the former cleft area in case of a closed dental arch?
b. Is there a difference in ABR if an interrupted dental arch is present (no functional loading)?
c. Is there a difference in the shape of the piriform aperture.

a. Closed dental arch

The maximum ABR in the Groningen group with a closed dental arch (n=16/20) is 25%, (range 0-25) mABR=8.7%, independent of the paralleling of the CAT (chapter V). In a closed dental arch in the Utrecht group (n=21/30) with paralleling of the CAT radices (<30%)(n=15) mABR is 24.2% (0-100%), with a divergency of CAT radices between 30°-45° (n=6; range 0-80.8%) mABR is 21.9%.

The mean ABR-U independent of the CAT radices divergence and a closed dental arch is 23.6%. This difference (8.7% vs 23.6%) is obviously in favour of the Groningen patients. In addition 7 (43.8%) Groningen patients vs 7 (33.3%) Utrecht patients showed no measurable ABR in the former cleft area with an uninterrupted dental arch.

In table 25 some interesting findings can be found e.g. in the Utrecht group with a FF oral closure showed 8 (80%) a concave buccal contour. It appeared also that FF closure has a significant negative influence on ABR: 46.2% vs 21.2% (F=7.148; P<0.012). Furthermore there is a difference between the two groups under investigation (closed by MP-flaps) and a shallow vestibular sulcus in respect to the mABR: 8.8% vs 23.0%. These differences between group I and II also apply, as a result of the oral closure method, for a concave buccal contour in respect to mABR 9.1% vs 29.1%.

In order to answer the question about the quality of the different grafts with the indicator ABR an analysis of variances (ANOVA-)procedure is used to analyse the impact of different circumstances in the two younger groups (I+II) of UCLP-patients. Both "pooled" younger patientgroups showed a calculated *grand mean* ABR of 22.1%. In the first place, it appears that there is no interaction between method of oral closure and patient groups (viz. table 27). Secondly it appeared that oral closure as main effect influenced in a significant way the outcome of the ABR (F=5.897; P=<0.005). Finally the Groningen graft resorbed less than the Utrecht graft although not significantly (F=3.431; P=0.072), when analyzed for all (3) oral closure methods together (10.9% vs 29.5%). However there are no finger flaps in the Groningen Group.

In order to reduce the possible influence on ABR of the finger flaps and to proceed with the ANOVA a new sample was pooled of only MP-flaps used to cover the graft (n=40). This analysis showed no changes in the results (F=3.641; P=0.064) so only a tendency in favour of the Groningen bone graft is clear.

The influence of a closed dental arch on ABR is one of the main topics of this investigation (maintenance of alveolar bone by loading). To establish the outcome of ABR an analysis

patients oral closure	Groningen n=20 mABR 10.9%	Utrecht n=30 mABR 29.5%
local periost. flaps (n=26) (MP)	6.9% (11)	19.4% (15)
transp. periost. flaps (n=14) (MP)	15.8% (9)	26.4% (5)
finger flaps (n=10) (FF)	(0)	46.2% (10)

Table 27. *The outcome of mABR% in relation to oral closure*

on the effects of a closed dental arch and the appearance of the vestibular sulcus was executed in the total population < 17.5 years, n=50 (grand mean ABR: 22.1%). The ANOVA procedure showed that the difference between the patientgroups was significant (F=7.779; P=0.008) and the closed dental arch reduces ABR in the group (n=50) in a significant way (F=5.750; P=0.021).

When the effect of the interrupted dental arch (viz. table 28) is eliminated and the finger flaps are excluded, the ANOVA gives the following results in the new patient sample (n=33): grand mean 14.4%, mABR-G: 8.7%, mABR-U: 19.7%. These patients have: a closed dental arch, a normal or shallow sulcus and are closed by mucoperiosteal flaps only. Main effects of mucoperiosteal closure and outcome of the vestibular sulcus are not significant (F=0.902; P=0.454). In the patient group there is a difference in favour of the Groningen graft, however not significantly (F=2.698; P=0.113).

b. Interrupted dental arch

In the Groningen group mABR=19.9% with an interrupted dental arch (n=4) (max. ABR 42.3%). In the Utrecht group with a non-closed dental arch (n=9) max. ABR=79.3%, mABR: 43.3% (chapter VI). The mABR in the tertiary bone grafted cases is 54.9% (chapter VII, n=18, interrupted dental arch, range: 26.7%-100%). When we consider a "new" group of UCLP-patients (n=31) (table 29) composed of interrupted dental arches nG=4, nU=9 and nU=18 (TACR) (chapter VII), the grand mean ABR= 47.6%. The ANOVA procedure

group		vestibular sulcus		total
		normal	shallow	
I. Groningen	loc. MPF	9.0 (5)	4.3 (5)	6.7 (10)
	trans. MPF	11.0 (3)	13.1 (3)	12.1 (6)
II. Utrecht	loc. MPF	17.3 (9)	22.7 (6)	19.5 (15)
	trans. MPF	22.2 (2)	(0)	22.2 (2)
Total		14.6 (19)	14.1 (14)	14.4 (33)

Table 28. *The mABR% in 33 UCLP patients with a closed dental arch, mucoperiosteal closure, in relation to the appearance of the vestibular sulcus*

group	oral closure	vestibular sulcus			
		normal	shallow	scarified	
I. Groningen	loc. MPF	9.5 (1)	0 (0)	0	9.5 (1)
<17.5y	trans. MPF	42.3 (1)	13.8 (2)	0	23.3 (3)
mABR: 19.9%	FF	0	0	0	(0)
II. Utrecht	loc. MPF	0	0	0	(0)
<17.5y	trans. MPF	0	29.3 (3)	0	29.3 (3)
mABR: 43.3%	FF	42.0 (2)	54.6 (4)	0	50.4 (6)
III. Utrecht	loc. MPF	28.5 (1)	32.8 (2)	0	31.4 (3)
>17.5y	trans. MPF	68.2 (2)	0	0	68.2 (2)
mABR: 54.9%	FF	37.2 (2)	58.4 (10)	100 (1)	58.3 (13)
Numbers		41.7 (9)	46.2 (21)	100 (1)	47.6 (31)

Table 29. *The mABR% in 31 UCLP patients with an interrupted dental arch in relation with the oral closure technique and vestibular sulcus*

showed: no interaction effect between variables as to the way of oral closure and research groups. The oral closure had no influence in the outcome of the mABR (F=1.734; P=0.198). The patient group grafted with chin bone showed the lowest degree of mABR (19.9%) (F=1.951; P=0.164) (viz. table 29). A tendency is seen: the Groningen graft better maintains height of the alveolar process. Further analysis is futile, due to the many empty cells in table 29.

c. Differences in the shape of the piriform aperture

The radiographic findings at the piriform aperture on the cleft side assessed on the X-OPT with closed dental arches show in 10 (62.5%) of the cases an excavation in the Groningen UCLP patients. On the other hand there are in the Utrecht UCLP-patients 12 (57.2%) with an excavation in that area.

In the interrupted dental arches the percentage of excavation of the piriform aperture is respectively 2 (50%) Groningen and 7 (77.7%) Utrecht group. The mABR in these cases is 19.9% vs 43.3%. The trend seems clear, statistics were considered superfluous for such small numbers.

VIII.2.7. File analysis

It could be assessed from the medical files how many times fistula closure had occurred previous to ACR in both younger aged (< 17.5 year) UCLP-patients.

Only five patients in the chin bone grafted (Groningen) group had previous fistula surgery, but mABR (8.0%) did not differ essentially from the overall mABR. In the iliac crest bone grafted patients six had previous surgery in the alveolar cleft region for oronasal communications, but no significant change in mABR was noted either.

The reliability of these figures is questionable, an incidence of 25-30% fistula closing sur-

gery seems reasonable however (Perko, 1966).
Rhinoplasties before ACR were recorded seven times in the UCLP-Groningen and ten times in the Utrecht group. In total twelve Groningen-UCLP-patients had combinations of previous surgery like secondary lip repair, rhinoplasty or fistula closure. Fourteen patients in Utrecht had a lip revision in combination with rhinoplasty or fistula surgery. An interesting feature from the orthodontic point of view was the pharyngoplasty, executed in the chin group in 5 (25%) patients and in the Utrecht group in 12 (40%) UCLP-patients.

VIII.3. General discussion

What were the expectations as to a possible advantage of the use of ectomesenchymal bone for alveolar bone grafting - as compared to mesenchymal bone?
We mainly expected the canine eruption to proceed more smoothly, the orthodontic end result to be better and the bone resorption to be less.
Periodontal health is so much dependent on oral hygiene which in turn is highly influenced by surgical technique (scar, vestibular sulcus), that inconclusive results were expected. Moreover, there is still discussion on whether the epithelial attachment of the gingiva to the cemento-enamel junction of an erupted tooth is influenced by the underlying bone or dependent of the periodontal ligament only. External root resorption has been reported to have a low incidence and it is an erratic and poorly understood phenomenon. Oro-nasal fistulae have been successfully closed making use of iliac crest bone grafts in a high percentage of cases and further improvement seemed hardly possible.

VIII.3.1. Cuspid eruption

In the literature considerable differences in spontaneous eruption after ACR are mentioned (table 12, chapter V). Whatever the numbers, the embryological advantage of chin bone *in our investigation* is not supported by the findings.
Cyst formation was seen once (10%) in the ectomesenchymal (Groningen) group and twice (13.3%) in the mesenchymal (Utrecht) group. Borstlap et al (1990) thought, that cyst formation is more prevalent after ectomesenchymal grafting. Also this hypothesis is not borne out by our investigation.
The 2/3 length of the cuspid and outcome of ABR is in favour in both research groups, however the numbers in group I were too small for a reliable conclusion.

VIII.3.2. Periodontium

Once more it should be stressed that all investigations were done by one examiner and that therefore it may be expected that the problems with respect to systematic errors as mentioned in the literature (see Chapter II.4.1.) could be circumvented.
Enemark et al (1987) confirmed in a major investigation, that there is no significant difference in PD between CAT and non-CAT control teeth in the same patient. This has been

confirmed by our investigation and it also is an indication, that gingival re-attachment to a tooth is independent of the origin of the grafted bone, since this finding occurred in the three groups under investigation. Also Hinrichs et al (1984) arrived at the same conclusion, even though plaque- and gingival bleeding indices were elevated around the CAT.
The BOP in the Groningen group was higher, than in the Utrecht one. There are several possible explanations for this finding. Apart from a different dental hygiene regime, plaque index, right-handed patients with rightsided clefts brushing less thoroughly and other modified brushing patterns in the cleft patient, it may have been a momentary finding only in contrary to e.g. PD which does not change from day to day. None of the other possible explanations seems to be related to the origin of the bone graft and a discussion therefore seems irrelevant in this context.
Finally, the mean PD in our investigation in both younger groups was well under 2mm which is considered to be the limit for periodontal health. As to the width of the attached gingiva, in accordance with our expectations, it appeared not to be of importance in respect to the periodontal health (mPD, BOP). It is known that a minimum of 1.0mm attached gingiva on the alveolar process is required to prevent periodontal damage. Is it however of significant importance in the maintenance of the marginal alveolar crest bone level of the grafted area as Enemark et al (1987) and others stated? This was a seeming proof of evidence in the MPF Groningen (n=20, width gingiva 3.37; mABR 10.9%) vs the FF Utrecht (n=10, width gingiva 1.86; mABR 46.2%) vs MPF Utrecht (n=20, width gingiva 1.88; mABR 21.2%). The difference in mABR however must be explained by the scar tissue in the finger flap resulting in a concave contour and subsequent resorption of the interdental alveolar crest. For a further discussion on this issue and mABR viz. VIII.3 and VIII.3.6.
The periodontal condition in tertiary ACR seemed unfavourable as compared to the other two groups. This is in accordance with what is found in non-cleft prosthetic rehabilitation sites (Silnes and Gustafson, 1985) and also with Brägger's et al (1992) findings.
Although there is one significantly different value in the two younger ACR groups as to probing depth, most values are comparable and thus the quality of the grafted bone does not seem to be involved.
Differences in width of the attached gingiva are to be related to differences in surgical technique.

VIII.3.3. Morphology alveolar process

Why is the Groningen result much better, than the Utrecht one? Even if we discard the 10 FF patients, then there is still a marked difference: 10% concave buccal contour of the alveolar process versus 40%. In the first place we think that in both MPF groups (I, II) the mucoperiosteal covering has been the same, even if the width of the attached gingiva in the Utrecht group is reduced as compared to the Groningen patients. A relation inside the Utrecht group between width of attached gingiva and bone resorption was not established, the resulting subgroups being to small for analysis. So we cannot draw any con-

clusions about such a relation.
Then of course there is the underlying bone, which is of a different nature and this in principle could be the sole explanation of this finding. However, is it the ectomesenchymal nature of chin bone or merely the architecture? I.e. could mesenchymal bone from *any* source with a comparable architecture have produced a result in Utrecht comparable to the Groningen one? An indication that this could be the case can be argued as follows. In iliac crest bone grafting if used for filling in of localized defects, mainly spongious bone is being used because of its rapid vascularization as compared to cortical/spongious grafts. However, from preprosthetic surgical literature it is known, that resorption of purely spongious grafts proceeds much more rapidly, than of the mixed ones (Fazili et al, 1978; Swart, 1984). Therefore it cannot be excluded that the reason for the better morphology of the alveolar process in Groningen has nothing to do with the ectomesenchymal nature of chin bone but with an architecture of tela ossea and marrow which are exceptionably suitable for transplantation purposes. However, the possibility that the ectomesenchymal origin of chin bone is solely responsible for the good results should be taken very seriously.

VIII.3.4. Orthodontic status

The differences in closed dental arches (80% vs 70%) can be explained by a higher degree of hypodontia in the Utrecht group, possibly also by the use of finger flaps in 10 out of 30 patients. Also there might have been a difference in philosophy between the cleft palate teams as to the desirability to create room for prosthetic replacement of the missing teeth (often the CALI).
The results of our study (80%-70%) are compared to some reported in literature: Bergland et al (1986) 90% closed dental arches, Amanat and Langdon (1991) 78.6%. However Enemark et al (1987) had 49.1% closed dental arches only, which is explained by them as being a consequence of CAT loss.
The difference in dental arch relationship may be dependent on an iatrogenic growth disturbing factor such as the outcome of primary palatal surgery (closing of the anterior hard palate by a Vomer flap), pharyngoplasty, attempt of fistula closing, the prae-surgical orthodontic treatment and the postsurgical orthodontic treatment, hypodontia in the cleft region, and functional and other growth disturbing factors (Ross, 1987) (discussion chapter V and VI). The contribution of each difference could not be assessed satisfactory: the patients number became too small after selection of the different treatment modalities to make a reliable statistical comparison and analysis.
Conclusion: the orthodontic parameter is not suitable to give a verdict on the merit of the origin of the bonegraft.

VIII.3.5. Fistula closure

Superiority of either bone graft is not supported by the figures concerning the successrate in this matter.

patient group width of the cleft (+mABR%)	Groningen < 17.5 chin	Utrecht < 17.5 iliac crest	Utrecht > 17.5 iliac crest	total
wide: > 6mm	1 (0%)	4 (33.3%)	9 (54.5%)	14 (44.5%)
normal: 4-6mm	12 (10.6%)	25 (28.5%)	8 (58.7%)	45 (29.1%)
small: < 4mm	7 (13.0%)	1 (40%)	1 (28.6%)	9 (17.7%)
total	20	30	18	68

Table 30. *Width of the cleft and mABR% in the three investigated UCLP-patients groups*

VIII.3.6. Alveolar bone resorption and X-ray analysis of the piriform aperture

a. Closed dental arch

In both younger groups functional loading of the grafted bone as occurring in the closed dental arch configuration reduces bone resorption as expected. For the difference in ABR between the groups the origin of the bone i.e. the embryological nature of the (donor chin) bone and/or its architecture can be held responsible. On the whole, the X-ray examination only confirms what the clinical examination already had delivered. We can therefore refer to the earlier discussion in part VIII.3.3.

An interesting finding is, that the angulation of the CAT in both groups had relatively little influence on the mABR contrary to our expectations.

b. Interrupted dental arch

As to the interrupted dental arch cases, the results proved to be exactly the same i.e. there was a clear trend in favour of the chin bone.

c. Piriform aperture

The discussion on this part of the radiographic findings can be summarized. The shape of the bone graft after remodelling (diabolo, hour-glass) suggests that a minimal functional loading by mimic musculature only preserves the symphyseal graft better than the iliac crest one. Even so it is felt that not only for prosthetic reconstruction of the alveolar process (in respect of implant dentistry and rehabilitation of the dental arch) but also for the asymmetry of the alar base on the cleft side allogenic material must be considered to maintain support for the nasal alar base.

Finally, to avoid any misunderstandings as to the comparability of the two younger groups of this study, we show here in table 30 the relationship between pre-operative cleft width and bone resorption in all three groups. The reader's attention is drawn especially to the "normal" sized alveolar cleft group (4-6mm), which suggests that the ABR was not influenced by some difference or another in group composition, as far as the bony cleft configuration is concerned. Of course the possibility that differences in primary surgery are also responsible for the different results cannot be excluded. This is especially

relevant in view of the results of our animal experiment: here the surgery in both bone types was exactly the same with only one variation - the origin of the bone. And here the results were unequivocally very similar. In retrospect it is a pity that the sham operation in the end filled in with bone either, although the bone remodelling dynamics were studied and we considered it as irrelevant, the critical size of the artificial cleft in sheep is apparently different than in primates and dogs. Furthermore it is a pity that in this animal experiment no quantitative analysis of each bone graft (prior to transplantation) has been done, because this could have yielded insight into the dilemma whether the architecture has been responsible (instead of the embryological nature) for the differing results in graft resorption. Especially the ratio between tela ossea and marrow would have been interesting: if in sheep it is nearly one, but in humans not equal to one, a different mABR after grafting can be expected in humans, contrary to sheep.
It is tempting to speculate on the possibility of bone morphogenetic protein contents of different bone sources, but this is not the aim of this thesis and hard evidence sofar is not available anyway.

Conclusion: although the mABR of the ectomesenchymal graft after statistical analysis is not significantly better there is a strong tendency to favour the chin bone graft.

VIII.3.7. File analysis
The pharyngoplasties (performed before the sixth year of age) in both younger groups were linked with retrognathia of the maxilla. This strongly suggests a growth retarding scar from the vertebral column to the growing maxilla. In addition reduced nasal airway patency may cause growth retardation, and maybe also a combination of both factors can be responsible.

VIII.3.8. Donor site
In our statement of problems two questions were posed with respect to the donor site, which have still to be discussed. Furthermore it is of relevance for the comparison of the groups under investigation.

1. Is there a significant advantage as to local morbidity of one site as compared to the other?

Chin
The complications are listed in table 1. The direct postoperative sequelae like pain and swelling have no significance, but the permanent damage had: 1 mental nerve lesion and 12 devitalized teeth in 61 patients. The other adverse effects like incomplete ossification and pulp obliteration have no consequences for the patients, in fact they were not aware of their existence. In other words, if one does not push ones luck too far (which apparently has been the case in Groningen a few times), donor place morbidity is minimal.

Iliac crest
The immediate postoperative complaints are significant and potentially more dangerous than those in the chin region. We mean the immobility of the lower limb, the gait disturbances and everything this situation may engender. But the late effects are merely of an aesthetic nature with one exception - the case of meralgia paresthetica. This patient was however the only person in our department suffering from this condition out of many hundreds in whom an iliac crest graft has been taken. See also the virtual absence of complications in the publication of Vd Wal et al (1986).
Therefore we think that this extremely rare complication, however serious it may be, should not be weighed as heavily as the much greater chance of a similar condition arising in the mental nerve, if one has to fill up a major cleft for which a lot of bone is needed.

2. Is there a difference in operating time between the two procedures?

In the one-team situation as existing in our department - yes. Whether one first prepares the cleft region and then takes the iliac crest graft or takes the graft first - our routine, the changing of gowns and gloves and the procedure itself are more time consuming, than when a chin bone graft is taken.
If two surgical teams are available this is not the case and with proper coordination between the two teams, the operating time is even shorter than when chin bone is taken. Also sterility problems do not arise in this situation.
Those one-team groups who take the iliac crest graft first (e.g. Utrecht) do so to avoid contaminating the donor site with the oral microflora and accept some storage time of the graft before insertion. If one thinks this time lag to be a major disadvantage, the procedure could be as follows: preparation of the cleft area - de/re-gowning and de/re-gloving - obtaining iliac crest bone and immediately inserting it into the cleft + finishing the surgery there - de/re-gowning and de/re-gloving and closing the donor site.
Anyway, in the patients of the Utrecht group the graft was always stored in blood-soaked gauzes during 2 hours or so before insertion into the cleft, whereas in Groningen this time lag was about zero (closing donor-site after insertion graft and closing acceptor site).
Although it is generally felt, that storage time of a fresh autogenous graft should be as brief as possible, we cannot say for sure, that the difference in mABR between the two groups under discussion is explained by these circumstances. On the other hand this possibility cannot of course be ruled out altogether either.

References

Amanat, N., J.D. Langdon: Secondary alveolar bone grafting in clefts of the lip and palate. J. Cranio Max.-Fac. Surg. 19 (1991) 7

Bergland, O., G. Semb, F.E. Abyholm: Elimination of the residual alveolar cleft by secondary bone grafting and subsequent orthodontic treatment. Cleft Palate J. 23 (1986) 175

Borstlap, W.A., K.L.W.M. Heidbüchel, H.P.M. Freihofer, A.M. Kuijpers-Jagtman: Early secondary bone grafting of alveolar cleft defects. A comparison between chin and rib grafts. J. Cranio Max.-Fac. Surg. 19 (1990) 201

Boyne, P.J., N.R. Sands: Secondary bone grafting of residual alveolar and palatal clefts. J. Oral Surg. 30 (1972) 87

Boyne, P.J., N.R. Sands: Combined orthodontic-surgical management of residual palato-alveolar cleft defects. Am. J. Orthod. 70 (1976) 20

Brägger, U., E. Schurch, S. Gianni, T. von Wyttenbach, N.P. Lang: Periodontal conditions in adult patients with cleft lip, alveolus and palate. Cleft Palate Craniofac. J. 29 (1992) 179

Enemark, H., S. Sindet-Pedersen, M. Bundgaard: Long-term results after secondary bone grafting of alveolar clefts. J. Oral Max.-Fac. Surg. 45 (1987) 913

Fazili, M., G.R. van Overvest, A.M. Vernooy, W.J. Visser, M.A.J. van Waas: Follow-up investigation of reconstruction of the alveolar process in the atrophic mandible. J. Oral Surg. 7 (1978) 400

Hinrichs, J.E., M.E. El Deeb, D.E. Waite, R.R. Bevis, C.C. Bandt: Periodontal evaluation of canines erupted through grafted alveolar cleft defects. J. Oral Max.-Fac. Surg. 42 (1984) 717

Perko, M.: Gleichzeitige Osteotomie der Zwischenkiefers, Restspaltenverschluss und Zwischenkieferversteifung durch sekundäre Osteoplastik bei Spätfällen von beidseitigen Lippen-Kiefer-Gaumen-Spalten. Dtsch. Zahn-Mund-Kieferheilk. 47 (1966) 1

Ross, R.B.: Treatment variables affecting facial growth in complete unilateral cleft lip and palate. Part 1-7. Cleft Palate J. 24 (1987) 5

Silness, J., F. Gustavsen: Alveolar bone loss in bridge recipients after six and twelfe years. Int. Dent. J. 35 (1985) 297

Swart: Academisch Proefschrift. Vrije Universiteit Amsterdam, 1984

Van de Wal, K.G.H., J.G.A.M. de Visscher, P.J.W. Stoelinga: The autogenous inner table iliac bone graft. J. Max.-Fac. Surg. 14 (1986) 22

Chapter IX

Conclusion of the study and future studies

Chapter IX

Conclusion of the study and future studies

IX.1. Conclusions

This clinical retrospective investigation on the merits of chin bone for transplantation into the cleft alveolus as compared to iliac crest bone is one of several recent studies on ACR with chin bone and on chin bone grafting in relation to dental implantology (Sindet-Pedersen and Enemark, 1988, 1990; Freihofer and Kuypers-Jagtman, 1989; Borstlap et al, 1990; Jensen and Sindet Pedersen, 1991; Hoppenreys et al, 1992; Misch et al, 1992; Davis et al, 1993; Freihofer et al, 1993; Witsenburg and Remmelink, 1993).
Freihofer et al (1993) reported in favour of chin bone, Remmelink and Witsenburg (1993) only weakly confirm the advantages of mandibular grafts.
In our investigation we think that it became clear, that the clinical results of both types of grafting material were on the whole satisfactory.
According to the ANOVA analysis the chin bone appeared to be better as to mABR, the amount of it in the iliac crest group being 11.1% higher. As to cuspid eruption and orthodontic treatment no clear advantage was found. And if we focus on the ultimate aim of the complete cleft treatment - to obtain a (near) normal former cleft area, we can arrange our results as follows:
The number of Groningen patients with a normal class I front tooth relation (without orthognathic surgery), a closed dental arch, a normal buccal contour and vestibular sulcus and without an oronasal fistula is 4= 20%.
The number of Utrecht patients with comparable qualifications was 6, also 20%.

On the other hand, some of the six parameters under investigation tend to favour the Groningen group even if no statistically significant difference emerged. We mean the periodontal findings, although BOP was higher, a better buccal contour, a lower percentage of lost CAT, the incidence of a depressed or shallow vestibular sulcus and the status of the piriform aperture.
All in all we think, that a clear superiority of ectomesenchymal versus mesenchymal bone did not emerge from this investigation, neither from the clinical part, nor from the animal experiment.
This even more so if one takes the deficient surgical technique (finger flaps) in some patients, the slightly wider clefts and the one layer closure (at the age of 3 months) in Utrecht into account. Whether the latter is really an *un*favourable factor is not certain and the same is true with respect to the two-hour delay between preservation and placement of the graft. Moreover in the literature as far as a comparison is allowed, even better results than we found in the Groningen group are reported (viz. table 12). So, in the end the basic flaws of this investigation become clear: in several aspects the groups seem not really comparable and allow a rough comparison only. In other words, not surprisingly,

this study is a mere exploratory one, only a prospective randomized confirmatory study may one day provide the reliable evidence which we tried to obtain in this retrospective one. Such a study could be a multi-centred one provided strict protocols, starting already in the patients' infancy are adhered to. It seems almost impossible to start such an investigation in one centre considering the time span involved, unless a great number of patients presenting with primary clefts are available, but even then the problems seem considerable.

Finally, in conclusion which graft does the author in the end prefer?

In view of the foregoing the reader would not be surprised at the following:

In the one-team approach in UCLP-patients and in other cleft patients, where a moderate amount of bone is required, mandibular symphysis bone is preferred (since 1986 up till now over 200 chin bone grafts were used for ACR).

But whenever a lot of bone is needed (as in most tertiary ACR cases) or whenever the chin is underdeveloped or pathology is present, iliac crest bone will be used (as is now a rarity), if possible with the help of a second team to obtain the graft. Also a thin layer of cortical bone will be left in this graft type in the future.

IX.2. Future studies

No mention has so far been made of a possibly promising line of investigations on osteoinduction by Bone Morphogenetic Proteins (Urist, 1965, 1981, 1992) placed in bonegrafts or implanted subperiosteally (Kübler et al, 1992). The idea to incorporate these BMP's in resorbable artificial carriers, possibly carbohydrate polymers seems very interesting. On the other hand, further research into the epithelial-ectomesenchymal interaction as reported among others by Boyne and Scheer (1991) also is worthwhile pursuing.

The necessary experimental animal studies require strict standardization as to:

1. Type of animal model, higher mammal, preferably a primate.
2. Age of the animal.
3. Similarity (embryological) between donor and acceptor site and
4. similarity of test-sites (bone deposition site # bone resorption site).
5. Qualitative and quantitative standardization of the graft.
6. Direction of the insertion of the graft.
7. Fixation of the graft.
8. Vascularization of the acceptor site must be the same.
9. Periosteal covering of the graft.

And last but not least, a prospective clinical study as stated above should be considered.

References

Borstlap, W.A., K.L.W.M. Heidbüchel, H.P.M. Freihofer, A.M. Kuijpers-Jagtman: Early secondary bone grafting of alveolar cleft defects. A comparison between chin and rib grafts. J. Cranio Max.-Fac. Surg. 18 (1990) 201

Boyne, P.J., P.M. Scheer: Stimulation of bone induction by odontogenic epithelium in the treatment of alveolar clefts. In: Pfeifer G. Craniofacial abnormalities and clefts of the lip, alveolus and palate. 4th Hamburg International Symposium. 1991, 171

Davis, P.I., M. Hakman, T. Funcik: Alveolar cleft bone grafts. Fac. Plast. Surg. 9 (1993) 232

Freihofer, H.P.M., A.M. Kuijpers-Jagtman: Early secondary osteoplastic closure of the residual alveolar cleft in combination with orthodontic treatment. Suppl. J. Cranio Max.-Fac. Surg. 17 (1989) 26

Freihofer, H.P.M., W.A. Borstlap, A.M. Kuijpers-Jagtman, R.A.C.A. Voorsmit, P.A. van Damme, L.W.M. Heidbüchel, V.M.F. Borstlap-Engels: Timing and transplant materials for closure of alveolar clefts. A clinical comparison of 296 cases. J. Cranio Max.-Fac. Surg. 21 (1993) 143

Hoppenreijs, T.J.M., E.S. Nijdam, H.P.M. Freihofer: The chin as a donor site in early secondary osteoplasty: a retrospective clinical and radiological evaluation. J. Cranio Max.-Fac. Surg. 20 (1992) 119

Jensen, J., S. Sindet-Pedersen: Autogenous mandibular bone grafts and osseointegrated implants for reconstruction of the severely atrophied maxilla. A preliminary report. J. Oral Max.-Fac. Surg. 41 (1991) 1277

Kübler, N., M.R. Urist, J. Reuther: Subperiostaler Osteoinduktion durch BMP - eine zukünftige Alternative zur Osteoplastik bei LKG Spalten? Dtsch. Z. Mund-Kiefer-Gesichtschir. 17 (1993) 281

Mish, G.C., C.E. Mish, R.R. Resnik, J.H. Ismail: Reconstruction of maxillary alveolar defects with mandibular symphysis grafts for dental implants. A preliminary procedural report. Int. J. Oral Max.-Fac. Implants 7 (1992) 360

Sindet-Pedersen, S., H. Enemark: Mandibular bone grafts for reconstruction of alveolar clefts. J. Oral Max.-Fac. Surg. 46 (1988) 533

Sindet-Pedersen, S., H. Enemark: Reconstruction of alveolar clefts with mandibular or iliac crest bone grafts. A comparative study. J. Oral Max.-Fac. Surg. 48 (1990) 554

Urist, M.R.: Bone formation by autoinduction. Science 150 (1965) 893

Urist, M.R.: Bone transplants and implants. In: Urist, M.R. ed. Fundamental and clinical bone physiology. Philadelphia: J.P. Lippincott (1981) 331

Urist, M.R.: Bone morphogenetic protein. In: Bone grafts and Bone substitutes. Ed.: Habal and Reddi, W.B. Saunders Company. Chapter VII (1992) 70

Witsenburg, B., H.J. Remmelink: Reconstruction of residual alveolo-palatal bone defects in cleft patients. A retrospective study. J. Cranio Max.-Fac. Surg. 21 (1993) 239

Summary/Samenvatting

Summary

The choice of a bone graft for alveolar cleft repair is the object of this study. Traditionally iliac crest bone grafts are widely used. In this thesis an attempt is made to compare it with the mandibular symphysis bone graft. In order to find an answer to this problem a literature review and an animal experiment were done and a group of patients treated with a mandibular bone graft thoroughly investigated. The results were compared with a group of patients that was treated with a bone graft from the iliac crest.

In **chapter I**, the introduction, the above mentioned problems are enunciated and a number of questions regarding the problem of different bone donor sites and the goals of the alveolar cleft reconstruction, are formulated. The ultimate aim of the investigation - to judge the usefulness of the mandibular symphysis bone graft in alveolar cleft repair is described.

In **chapter II** the working hypothesis is presented: superiority of the ectomesenchymal mandibular symphysis graft based on embryological similarity, i.e. membranous bone versus endochondral bone of the iliac crest.
In addition there is a review of the favourable results already known from clinical reports concerning mandibular bone grafts.

Chapter III deals with patient material and methods and a discussion about these methods. A clinical and radiographical follow-up of three patientcohorts was done, one treated with a mandibular symphysis graft, one treated with an iliac crest bone graft and a third patient population also treated with an iliac crest bone graft but, contrary to the other two cohorts, after completion of growth (>17,5 years). The results were partly analyzed by a computer study.

Chapter IV is the description of an animal experiment in which artificial bone defects in the upper jaw of a sheep are reconstructed with an autologous mandibular bone graft or an iliac crest bone graft. Clinical and radiographical follow-up was performed in a semi-standardized way during six months postoperatively. The sheep were sacrificed after six months and the area of interest was investigated histologically, histomorphometrically, and microradiographically. The results of the animal experiment showed that mandibular bone is similar to the iliac crest graft in respect of the total bone volume. The architecture of the grafted bone was often in accordance with the donor site. The distribution of the trabecular system still reminds one of the origin of the graft. The bone remodelling was not yet completed after six months. However there was a tendency of the mandibular bone graft adapting more completely to the maxillary bony architecture than the iliac crest bone graft did.

Chapter V deals with the examination of 20 UCLP-patients (out of a group of 57 cleft patients) treated in the Martini hospital in Groningen by drs. Bosker and Van Dijk and who underwent alveolar cleft repair with a mandibular bonegraft. Investigated were the eruption and migration of teeth into the former alveolar cleft area; the periodontal status, the morphology of the alveolar process and the orthodontic results were also examined. A radiographical follow-up using a semi-standardized X-ray technique was done. The interdental alveolar crest height was calculated with a newly introduced method. The incidence of oronasal fistulae was monitored pre- and postoperatively. Compared with the literature on mesenchymal bonegrafting the results of ectomesenchymal bone grafting (the chinbone) appeared very encouraging.

In **chapter VI** the same investigation was performed in 30 UCLP children treated in the University clinic for oral and maxillofacial surgery in Utrecht to judge the results of ACR with iliac bone grafts. As far as a comparison is possible the results were slightly inferior to those in Groningen.

The third patientpopulation (n=18) aged > 17,5 year (**chapter VII**) was investigated in order to get insight in the importance of functional loading of the bone graft versus non functional loading. It appeared that physiological loading of the transplanted bone ensures its maintenance. Physiological loading is achieved by a closed dental arch.

The results of the alveolar cleft repair are compared and analysed in **chapter VIII** and are extensively discussed with regard to the research objectives set forth in the introduction. The comparability of both younger UCLP-patientgroups is discussed and despite the fact that there are differences there are also similarities which make the comparison of the results to a certain extent possible.

It is concluded in **chapter IX** that the mandibular bonegraft is quite useful in the bridging of an alveolar cleft. The patient does not need a second distant operation for harvesting the graft, the morbidity is less than in other harvesting procedures (if one exercises moderation as to the quantitiy of bone taken) and the overall result is satisfactory.

However the results of iliac crest grafts are also quite satisfactory, in the literature even more so than in the 30 UCLP patients from Utrecht. And if a lot of bone is needed, the iliac crest might be preferred.
Finally, the working hypothesis on the advantage of an ectomesenchymal bone graft over a mesenchymal one could not conclusively be confirmed especially in view of comparable results as to canine eruption into the graft, orthodontic treatment outcome and alveolar bone resorption.
Future studies are briefly outlined.

Samenvatting

In **hoofdstuk I** wordt de inleiding, probleemstelling en doel van het onderzoek beschreven. Daarbij komt in het kort aan de orde het verschil tussen de primaire osteoplastiek en de secundaire osteoplastiek. Hiermee wordt bedoeld de bottransplantatie op zeer jeugdige leeftijd tijdens het sluiten van de lip (primaire osteoplastiek) tegenover de sluiting van het kaakdefect op een latere leeftijdsperiode (secundaire osteoplastiek). De keuze van de verschillende beenderen als donorplaats wordt kort beschreven.
De probleemstelling is geformuleerd aan de hand van het doel van de operatie en de uit de literatuur bekende resultaten. Het uiteindelijke doel van het onderzoek is, door middel van een retrospectief patiëntenonderzoek, de waarde van het mandibulaire bottransplantaat in de gnathoschisischirurgie te beoordelen.

Hoofdstuk II geeft de hypothese weer: de theoretische superioriteit van het ectomesenchymale mandibulaire symphysis bottransplantaat. Hierbij wordt verwezen naar o.a. de embryologische oorsprong, uitvoerig worden de voordelen van membraneus bot versus endochondraal bot besproken. Tevens is er een overzicht gegeven van de gunstige resultaten, die reeds uit klinische waarnemingen met mandibulair bot als transplantaat bekend waren in de literatuur.

In **hoofdstuk III** zijn het patiëntenmateriaal en de gehanteerde onderzoeksmethoden beschreven en is hieraan een discussie gewijd. Gekozen is voor een klinisch en röntgenologisch onderzoek van drie patiëntengroepen, waarvan de resultaten middels een computeranalyse worden vergeleken.

In **hoofdstuk IV** wordt een vergelijkende studie bij schapen beschreven, waarbij in twee artificiele botdefecten in de bovenkaak van een schaap een autoloog mandibulair botstuk of een botstuk uit de crista iliaca wordt getransplanteerd. Klinische en röntgenologische follow-up vindt plaats op vaste intervallen gedurende de eerste 6 maanden postoperatief. De schapen worden na 6 maanden geofferd en de onderzoeksregio middels histologische en histomorfometrische methoden met elkaar vergeleken. Uit dit onderzoek blijkt dat het mandibulair botstuk gelijkwaardig is aan het crista iliaca transplantaat met dien verstande dat de architectuur van het getransplanteerde botstuk veelal in de acceptorregio is te herkennen, waarbij met name de verdeling van de botbalkjes nog herinnert aan de oorsprong van het transplantaat. De botombouw is derhalve na 6 maanden nog niet volledig. Er bestaat een tendens dat het mandibulaire donorbot meer ombouwt naar de maxillaire botstructuur dan het crista iliaca donorbotstuk.

Hoofdstuk V doet verslag van de resultaten van 20 unilaterale schisispatiënten uit een groep van 57 patiënten die een bottransplantatie naar de gnathoschisis vanuit de mandibulaire symphyse hebben ondergaan. Uitgebreide analyse van de resultaten vindt plaats,

waarbij als parameters worden gebruikt de eruptie en migratie van tanden in het getransplanteerde vroegere gnathoschisisgebied, tevens wordt er een parodontale status opgenomen. De morfologie van de processus alveolaris wordt beoordeeld, de orthodontische status wordt geëvalueerd.
Tevens wordt gekeken naar de incidentie van oronasale fistels vóór en na de operatie.
Na een röntgenologische beoordeling, middels een semi-gestandaardiseerde opnametechniek en geïntroduceerde berekening, wordt de interdentale Alveolaire Bot Resorptie (ABR) bepaald.

In **hoofdstuk VI** wordt eenzelfde onderzoek gedaan bij 30 kinderen uit een groep van 113 schisispatiënten die getransplanteerd zijn met een crista iliaca transplantaat. Als referentiegroep dient een patiëntenpopulatie waarbij een bottransplantatie heeft plaatsgevonden nà een corrigerende osteotomie in de bovenkaak (**hoofdstuk VII**). Hierbij is er geen orthodontische nabehandeling maar een prothetische nabehandeling, die geen physiologische belasting geeft van het getransplanteerde bot.
Uit deze hoofdstukken valt te concluderen dat physiologische belasting van bot het behoud van het bot betekent. Dit wordt bij de kinderen bereikt door een aaneengesloten tandboog middels orthodontische behandeling na te streven.
Bij een onderbroken tandboog met ontbreken van physiologische belasting is er sprake van grote botresorptie voornamelijk bij de mesenchymale bottransplantaten. De andere onderzochte parameters in beide groepen vertonen geen grote verschillen.

De resultaten worden in **hoofdstuk VIII** door middel van de vragen uit de probleemstelling, aan vergelijking, analyse en discussie blootgesteld. Ondanks het feit dat er (grote) verschillen zijn, zijn er óók overeenkomsten in de beide groepen, die vergelijking van de resultaten weliswaar beperkt, maar toch mogelijk maakt.

Het **hoofdstuk IX** tenslotte formuleert de conclusies, het blijkt dat:
- het mandibulaire bottransplantaat een waardevolle bijdrage in de gnathoschisisbehandeling is en hierbij de patiënt een tweede operatie op afstand ter verkrijging van het botstuk wordt bespaard.
- Superioriteit van het kinbotstuk is niet aangetoond. De bruikbaarheid, met goede resultaten, echter wel.
- Aanbeveling wordt gedaan voor wetenschappelijk vervolgonderzoek in samenwerking met craniofaciale embryologen, biologen, en biomateriaalkundigen.

Addendum I

Computerform used for dataprocessing

```
Case 58 of 58----------------<active file>----------------Page  1 of  10-

        Bot-transplantatie bij (Cheilo-)gnatho-palatoschizis

        Academisch Ziekenhuis Utrecht - Vakgroep Kaakchirurgie
        ------------------------------------------------------
 Invoergegevens:                          d. m. j.
                                          .  .  . Geboorte datum
      . Ident.nr  . M/V        Naamcode
                                          .  .  . B.I.G.-datum

      . Utrecht/Groningen (1,2)           .  .  . Na-onderzoek datum
                              /1 = cgp
                              ! 2 = cg
      . Cheilo/Gnatho/Palato < 3 = gp     . Duplex/Links/Rechts/variant!
                              ! 4 = ch                   (1,2,3,4)!
      . Omvang Cheilo  \      \5 = gn     . Cheilo     \            !
                              ! 1 = compleet . Gnato    ->        <---
      . Omvang Gnatho  > 2 = incompleet     . Palato /
                              ! 9 = n.v.t
      . Omvang Palato  /
                                   S&F
 Add Cases On                Enter/Edit Data                        Caps
```

```
Case 58 of 58----------------<active file>----------------Page  2 of  10-

                 PERIODE 0 - 18 MAANDEN

 . Breedte spleet bij geboorte (1,2,3,9)=(Breed,Normaal,Smal,?)

   .  .  . Sluiting lip (d.m.j.)     .  .  . Sluiting palatum (d.m.j.)

 . Praechir.orthodontie-1 (0,1,9)=(Nee,Ja,?)

                 PERIODE 1.5 - 9 JAAR

 . Restfistels (0,1)=(Nee,ja)

 . Fistelsluitingen (0,1-8,9)=(Nee,ja,?) . Pharynxplastiek (0,1)=(Nee,ja)

 . Tonsil-/Adenectomie (0,1,2,3,9)=(Nee,TE,AE,TE+AE,?) . Tr.vl.buisjes (0,1)

 . Neuscorrecties (0,1-9) . Lipcorrecties (0,1-9) . Orthodontie (0,1)
                                   S&F
 Add Cases On                Enter/Edit Data                        Caps
```

```
Case 58 of 58----------(active file)----------Page  3 of  10
                    PERIODE 9 - 12 JAAR

Praeoperatief BIG:

. Orthodontie-2 (0,1,2,3)=(Nee,Front,Expansief,F+E)

. Hypo-/hyperdontie (0,1,2)=(Nee,hypo,hyper)    . Rechts  . Links

. Hypoplasie (0,1,2,3)=(Nee,Rechts,Links,R+L)

. Spleetoreedte-2 (1,2,3)=(Breed,normaal,smal)  . Rechts   . Links

. Oro-nasale fistel (0,1,2,3)=(Nee,Rechts,Links,R+L)

. Lengte cuspidaat (1,2,3,4)=(1/3, 2/3 wortel, eruptie, voll.doorgebr.)

----------S&F----------
Add Cases On          Enter/Edit Data                    Caps
```

```
Case 58 of 58----------(active file)----------Page  4 of  10

                 Bottransplantatie In Gnato (B.I.G.)

. Donorplaats (1,2,3,4)=(Kin,heup,rib,anders)

. Mate van vulling (1,2,3)=(Over-,norm,ondervuld)  . Rechts . Links

. Cortic.proc.alv.geaviveerd (0,1)

. Wijze van sluiten buccaal (1,2,3)=(Lab.sulc.flaps,Mucoperiost,Anders)

. Wijze van sluiten palatinaal (1,2)=(Mobilisatie,Pal.plastiek)

Post-operatief:
. Wondinfectie donorplaats (0,1)  . Idem acceptorplaats (0,1)

. Dehiscentie (0,1)               . Sequester (0,1)

. Postop.orthodontie (0,1)        . . . Datum postop.orthod.(d.m.j.)

. Doorbraak cuspid.(1,2,3)=(Spont.,Chir.,Geen)   . Cyste cuspid.(0,1)
----------S&F----------
Add Cases On          Enter/Edit Data                    Caps
```

```
Case 58 of 58----------------(active file)-----------------Page  5 of  10-

  Bovenkaak:                 Na-onderzoek
  ---------

                        14 13 12 11 21 22 23 24
  Aangehechte gingiva   . . . . . . . .  (mm)   (99 = n.v.t.,
                                                 element ontbreekt)
  Vrije gingiva         . . . . . . . .  (mm)

  Pocketdiepte mesiaal  . . . . . . . .  (mm)

  Pocketdiepte distaal  . . . . . . . .  (mm)

  Mobiliteit klasse     . . . . . . . .  (1,2,3,4)

  Bloedingsindex        . . . . . . . .  (0,1,2,3)=(geen,+,++,+++)

  Kleur gingiva         . . . . . . . .  (1,2,3)=(Norm.,hyperaem.,
                        14 13 12 11 21 22 23 24                blauw-rood)
                                   ^
  .   Divergentie radices rond spleet rechts\
                                          (1,2,3)=(<30,31-45,>45 graden)
  .    "        "     "     "     links /
                                  S&F
Add Cases On                Enter/Edit Data                          Caps
```

```
Case 58 of 58----------------(active file)-----------------Page  6 of  10-
                        Na-onderzoek (vervolg)
                        ----------------------

   Molaren 1 en 2 + onderkaak (alleen Utrecht):
   --------------------------------------------
                                 v
                        mol.1 43 42 41 31 32 33 mol.2
  Aangehechte gingiva   . . . . . . . .  (mm)   (99 = n.v.t.)

  Vrije gingiva         . . . . . . . .  (mm)   ( 9 = n.v.t.)

  Pocketdiepte mesiaal  . . . . . . . .  (mm)

  Pocketdiepte distaal  . . . . . . . .  (mm)

  Mobiliteit klasse     . . . . . . . .  (1,2,3,4)

  Bloedingsindex        . . . . . . . .  (0,1,2,3)=(geen,+,++,+++)

  Kleur gingiva         . . . . . . . .  (1,2,3)=(Norm.,hyperaem.,
                        mol.1 43 42 41 31 32 33 mol.2
                                   ^
                                  S&F
Add Cases On                Enter/Edit Data                          Caps
```

```
Case 58 of 58----------------(active file)-----------------Page  7 of  10
                    Na-onderzoek (vervolg)
                    ----------------------

 . Wijze van sluiten (1=Loc.mucoperiostlapjes, 2=Verschuifpl.,
                     3=Lab.sulcus flaps, 4=Bucket handle fl.)

 . Diepte omslagplooi (1,2,3)=(Physiol.,verstreken,verlittekend)
                 . Rechts  . Links

 Oro-nasale fistel:    . (0,1,2,3)=(Nee,rechts,links,beide)

          Rechts:   .\
                       (1,2,3)=(Buccaal,palatinaal,beide)
          Links:    ./

          Rechts:   .\
                       (1,2,3)=(Klein,medium,groot)
          Links:    ./

                    . Klachten (0,1)

 Proc. Alveolaris: . Rechts  . Links   (1,2,9)=(Concaaf,Normaal,Anders)
-------------------------------------S&F-------------------------------
Add Cases On                 Enter/Edit Data                        Caps
```

```
Case 58 of 58----------------(active file)-----------------Page  8 of  10
                    Na-onderzoek (vervolg)
                    ----------------------

 Donorplaats:
      - Litteken  . (1,2)=(fraai,niet fraai)

                  . Klachten (0,1)

      - Regeneratie (Röntgen)   . (0-100 %)


 Onderfront:
                                 43 42 41 31 32 33
 - Vitaliteit                     . . . . . .  (1,0,9)=(+,-,ontbreekt)

 - Peri-apicale radiolucentie  . . . . . . (mm)


-------------------------------------S&F-------------------------------
Add Cases On                 Enter/Edit Data                        Caps
```

```
Case 58 of 58 ----------------<active file>----------------Page  9 of  10

                          Eindsituatie

    . jaren na BIG, (2 decimalen)

  . MFP (0 = geen, 1=Zwevende brug  3=Frame
                   2=Vaste brug     4=Overkapping)

  . Osteotomie (0,1,2)=(Nee,Le Fort,Robinson)  .  .  . datum (d.m.j.)

   . Byzonderheden (0,1,2)                          / 0=Nee
          / 0) Geen                      / . Incisieven /  1=Apicaal
          ¦  1)                          ¦  . Cuspidaat \  2=Cervicaal
          ¦    - Wortelresorptie: - <                    \ 3=Api+Cer
        <                                ¦
          ¦    - . Perm.fixatie          \ . Dubbelzijdig (0,1)
          ¦
          ¦    - . Apertura piriformis L (1=Norm, 2=Licht verdiept,
          ¦      . Apertura piriformis R            3=Verdiept)
          ¦
          \  2) Zie status
                                   S&F
Add Cases On                Enter/Edit Data                        Caps
```

```
Case 58 of 58 ----------------<active file>----------------Page 10 of  10

                    Orthodontische situatie

  . Eindsituatie bereikt (0,1,9=n.v.t.)?  .  .  . Datum eindsituatie (dmj)

  Front:          Sagittaal: . (1,2,3)=(Norm.,binnenb.,kruisbeet)

                  Verticaal: . (1,2,3)=(Norm.,open,diep)

                             R  L
  Transversaal:  Molaar:     .  .  (1,2,3)=(Norm.,binnenb.,buitenbeet)

                 Cuspidaat:  .  .  (1,2,3)=(Norm.,binnenbeet,end to end)

                                       R     L
  Botresorptie interdent.alveol.septum:   .     . (%)

  Re-operatie BIG: . (0,1)
                                                          EINDE

                                   S&F
Add Cases On                Enter/Edit Data                        Caps
```

Addendum II

GROUP I								
no	cleft	oral closure	buccal contour	vestibular sulcus	divergence	ABR	dental arch	piriform aperture
1	2	1	2	2	2	0.0	0	2
2	2	1	2	2	1	0.0	0	3
3	2	1	2	1	1	11.4	0	3
4	2	1	2	2	2	21.3	0	2
5	2	1	2	1	2	0.0	0	1
6	2	1	2	2	1	0.0	0	2
7	2	1	2	1	1	9.6	2	1
8	2	1	1	2	1	0.0	0	3
9	2	1	2	1	1	10.0	0	3
10	2	1	2	1	1	17.2	0	3
11	2	2	2	2	1	25.0	0	1
12	2	2	2	2	2	14.3	0	1
13	2	2	2	1	1	18.7	0	2
14	2	2	2	2	1	0.0	0	1
15	2	2	1	2	.	18.2	2	3
16	2	2	2	1	1	0.0	0	1
17	3	1	2	1	1	6.6	0	2
18	3	2	2	1	2	42.3	2	1
19	3	2	2	2	2	9.4	2	3
20	3	2	2	1	1	14.2	0	1
	2=left 3=right	1=loc. MPF 2=trans. MPF 3=FF	1=concave 2=normal	1=normal 2=shallow 3=scarified	1= < 30° 2= 30°-45° 3= >45° .=missing		0=closed 1+2=bridge 3=removable appliance	1=normal 2=slight depression 3=excavated

GROUP II								
no	cleft	oral closure	buccal contour	vestibular sulcus	divergence	ABR	dental arch	piriform aperture
1	2	1	2	2	1	35.0	0	1
2	2	1	2	1	1	0.0	0	1
3	2	1	2	2	2	0.0	0	1
4	2	1	2	1	1	3.1	0	3
5	2	1	1	1	1	18.2	0	2
6	2	1	2	1	1	12.5	0	2
7	2	1	2	1	2	0.0	0	3
8	2	1	1	1	1	6.3	0	1
9	2	1	1	1	1	100.0	0	3
10	2	1	1	2	2	0.0	0	2
11	2	1	1	2	2	40.0	0	1
12	2	2	2	2	.	0.0	3	2
13	2	2	2	2	1	42.5	2	3
14	2	2	2	1	1	33.3	0	1
15	2	3	2	1	1	10.0	0	3
16	2	3	2	1	1	25.0	0	2
17	2	3	1	2	1	43.3	0	1
18	2	3	1	1	1	51.6	3	2
19	2	3	1	3	1	61.3	2	1
20	2	3	1	2	1	37.2	2	2
21	2	3	1	1	1	32.4	2	3
22	2	3	1	1	2	80.8	0	1
23	2	3	1	2	1	79.3	3	3
24	3	1	1	1	1	15.2	0	3
25	3	1	2	2	1	35.7	0	2
26	3	1	2	1	1	0.0	0	2
27	3	1	2	2	1	25.5	0	2
28	3	2	1	2	1	45.5	3	1
29	3	2	1	1	2	11.1	0	3
30	3	3	1	2	1	40.6	3	2
	2=left 3=right	1=loc. MPF 2=trans. MPF 3=FF	1=concave 2=normal	1=normal 2=shallow 3=scarified	1= < 30° 2= 30°-45° 3= >45° .=missing		0=closed 1+2=bridge 3=removable appliance	1=normal 2=slight depression 3=excavated

GROUP III								
no	cleft	oral closure	buccal contour	vestibular sulcus	divergence	ABR	dental arch	piriform aperture
1	2	1	1	2	2	38.9	3	1
2	2	2	1	1	1	100.0	3	3
3	2	3	1	1	1	30.9	3	1
4	2	3	1	3	1	45.8	2	1
5	2	3	1	3	1	100.0	2	3
6	2	3	1	2	2	68.0	2	3
7	2	3	1	2	1	27.3	2	3
8	2	3	1	2	1	34.6	2	3
9	2	3	1	2	1	66.0	2	1
10	2	3	2	1	1	43.5	3	2
11	2	3	1	2	1	58.6	2	3
12	2	3	1	2	1	100.0	3	2
13	2	3	1	2	2	66.7	4	2
14	2	3	1	2	1	51.9	2	2
15	3	1	1	2	1	26.7	2	2
16	3	1	2	1	3	28.6	2	3
17	3	2	2	2	1	33.3	2	1
18	3	3	1	2	.	56.7	2	1
	2=left 3=right	1=loc. MPF 2=trans. MPF 3=FF	1=concave 2=normal	1=normal 2=shallow 3=scarified	1= < 30° 2= 30°-45° 3= >45° .=missing		0=closed 1+2=bridge 3=removable appliance 4=overdenture	1=normal 2=slight depression 3=excavated

Curriculum Vitae

De schrijver van dit proefschrift werd geboren op 17 juni 1950 te Leiden. In 1968 werd het diploma HBS-B aan het Rembrandt Lyceum te Leiden behaald. De studie Tandheelkunde te Utrecht, na 1 jaar studie Farmacie te Leiden, werd aangevangen in 1969. Het tandartsexamen werd behaald in Juni 1975. Van augustus 1975 tot augustus 1979 werd hij in de Vakgroep Mondziekten en Kaakchirurgie (Subfaculteit Tandheelkunde, R.U. Utrecht), onder leiding van Prof.dr. P. Egyedi, opgeleid tot kaakchirurg.
De studie Geneeskunde (R.U. Utrecht) werd in februari 1983 afgesloten met het behalen van het arts-examen. Sindsdien is hij als staflid verbonden aan de kliniek/afdeling Mondziekten en Kaakchirurgie van het Academisch Ziekenhuis Utrecht. Vanaf de oprichting (1984) is hij lid van het W.K.Z.-schisis team.
Van maart 1990 tot augustus 1992 werd het opleiderschap waargenomen.
Sinds maart 1990 is schrijver dezes medisch afdelingshoofd (a.i.) van de afdeling Mondziekten en Kaakchirurgie van het A.Z.U.
Hij is gehuwd met Petronella Kisman, heeft een zoon, Michiel, en een dochter, Evelien.

Publicaties

Koole, R.: Behandeling van chronische osteomyelitis van de mandibula. Ned. Tijdschr. Tandheelk. 86 (1979)

Koole, R., P. Egyedi: Kaakabces en (of) osteomyelitis? Ned. Tijdschr. Geneesk. 124 (1980) 177

Slootweg, P.J., R. Koole: Recurrent Calcifying Odontogenic Cyst. J. Max.-Fac. Surg. 8 (1980) 143-145

Verzamelbundel wetenschappelijke artikelen "Tussen Zürich en Singapore". 1985

Koole, R., P. Egyedi: Postoperative contamination of mandibular osteotomy sites with saliva. Int. J. Oral Max.-Fac. Surg. 16 (1987) 554

Koole, R.: Diagnostiek en chirurgische interventie bij pijn rond het kaakgewricht. In: Steenks, M.H., A. de Wijer: Cranio-mandibulaire dysfuncties. De Tijdstroom. 1989. 51

Koole, R.: Standaardisatie Nomenclatuur Halsklierdissectie. In: Het Oncologieboek. IKMN. 1989

Koole, R., H. Bosker, M.F. Noorman van der Dussen: Late Secondary Autogenous Bone Grafting in Cleft Patients Comparing Mandibular (Ectomesenchymal) and Iliac Crest (Mesenchymal) Grafts. J. Cranio Max.-Fac. Surg. 17 Suppl. 1 (1989) 28

Koole, R.: Pijn in het hoofd/halsgebied, visie van een kaakchirurg. N.V.G. Congres 1989, 8e jaargang, nr 2 1990

Koole, R.: Behandeling van de schisispatiënt. Overzicht en achtergronden. Ned. Tijdschr. Tandheelk. 97 (1990) 472

Koole, R., P. Egyedi: The Case for Postoperative Orthodontics in Orthognathic Surgery. J. Cranio Max.-Fac. Surg. 18 (1990) 293

Verzamelbundel wetenschappelijke artikelen "Utrecht, 1985-1990"

Bosker, H., R.D. Jordan, S. Sindet-Pedersen, R. Koole: The transmandibular implant: a 13 year survey of its use. J Oral Max.-Fac. Surg. 49 (1991) 482

Koole, R., H. Bosker, S. Sindet-Pedersen: The TMI in the Netherlands; A 13-year survey. Oral Surgery Oral Diagnosis 2 (1991) 27

Koole, R., W.J. Visser, W.R. Klein, A.M.H. Suiker: A Comparative Investigation on Autologous Mandibular and Iliac Crest Bone Grafts. J. Cranio Max.-Fac. Surg. 19 (1991) 133

Slootweg, P.J., C.W. Bolle, R. Koole, G.J. Hordijk: Cause of death in squamous cell carcinoma of the head and neck. An autopsy study on 31 patients. J. Cranio Max.-Fac. Surg. 20 (1992) 225

Hazewinkel, H.A., R. Koole, G. Voorhout: Mandibular coronoid process displacement: signs, causes, treatment. VCOT 6 (1993) 29

Schenberg, M.E., P.J. Slootweg, R. Koole: Leiomyosarcomas of the oral cavity. Report of four cases and review of the literature. J. Cranio Max.-Fac. Surg. 21 (1993) 342

Slootweg, P.J., R. Koole, G.J. Hordijk: The Presence of p53 Protein in Relation to Ki-67 as Cellular Proliferation Marker in Head and Neck Squamous Cell Carcinoma and Adjacent Dysplastic Mucosa. Oral Oncol., Eur. J. Cancer 30 (1994) 138

Koole, R.: Ectomesenchymal Mandibular Symphysis Bone Graft: An Improvement in Alveolar Cleft Grafting? Cleft Palate-Craniofac. J. 31 (1994) 217