Journal of Pediatric Surgery Case Reports 30 (2018) 68–73

Contents lists available at ScienceDirect

Journal of Pediatric Surgery Case Reports

journal homepage: www.elsevier.com/locate/epsc

The unique characteristics of intussusception after renal tumor surgery in children

S.E. van Peer[a], C.P. van de Ven[a], C.E.J. Terwisscha van Scheltinga[a], J.A. Hol[a], M.H.W.A. Wijnen[a], A.S. Littooij[b], M. van Grotel[a], M.M. van den Heuvel-Eibrink[a,*]

[a] Princess Máxima Center for Pediatric Oncology, Utrecht, The Netherlands
[b] Department of Radiology and Nuclear Medicine, University Medical Center Utrecht, Utrecht, The Netherlands

ARTICLE INFO

Keywords:
Postoperative intussusception
Wilms tumor
Nephroblastoma
Tumornephrectomy
Renal tumor surgery
Postoperative complication
Pediatric tumor

ABSTRACT

Introduction: To further optimize survival rates as well as quality of cure for pediatric kidney tumors, attention for treatment related morbidity and mortality has become increasingly important. Intussusception is a rare but important complication after tumornephrectomy in children, causing morbidity, mortality and prolonged hospitalization. In this study, we describe two recent cases in our institute and provide a comprehensive review of the literature.

Methods: For our narrative review, we searched for all reported cases of post tumor nephrectomy intussusception published until November 2016, using Pubmed and Embase libraries.

Results: A total of 52 pediatric renal tumor cases who developed intussusception after tumor nephrectomy were identified. Median age was 23 months (range 3–84). Median time of onset was postoperative day 6 (range 1–18). Of 41 patients described in detail, only 4/41 were ileocolic, the others suffered from a small bowel intussusception. Most frequent presenting symptom was bilious vomiting. Preceding treatment approach was documented in 47 cases; i.e. preoperative chemotherapy had been administered to 10/47 patients. In 29 of 30 well documented cases, successful manually reduction during re-laparotomy was described and only 1 patient needed resection. All patients survived without recurrence of intussusception.

Conclusion: In pediatric renal tumor patients, small bowel obstruction seems to reflect mostly post nephrectomy intussusception cases in contrast to the ileocolic idiopathic intussusceptions that are observed in healthy children. Symptoms of intussusception mimic chemotherapy related toxicity and general post-surgical symptoms, thereby initiating a significant delay in diagnosis. Awareness of intussusception after renal tumor surgery is warranted.

1. Introduction

Pediatric kidney tumors occur mainly in children under the age of 5 years thereby representing around 6% of all pediatric tumors [1]. The most common subtype is Wilms tumor (WT). Survival rates for children with Wilms tumor have increased up to 90–95% over the past decades. Consequently, to further optimize survival rates as well as quality of cure, attention for treatment related morbidity and mortality has become increasingly important. Radical tumor nephrectomy is an important component of pediatric renal tumor treatment. Complications following tumor nephrectomy include postoperative bowel obstruction that can be caused by adhesions or, (more rarely) intussusception [2,4–7]. Extensive research is pursued on postoperative adhesions after tumor nephrectomy in children and adults, however to date, only a few reports address intussusception after nephrectomy for pediatric renal tumors and a comprehensive review is lacking. Consequently, the frequency and the determinants of development of intussusception is unclear. In addition, intussusception symptoms can be disguised, as they mimic general post-surgical symptoms, and chronic chemotherapy related side effects such as nausea. This could potentially lead to delay in recognizing bowel obstruction in this clinical setting. Hence, it is important to recognize the rare event of intussusception after tumor nephrectomy and to be aware of its provoking determinants. We reviewed all available cases in order to identify possible determinants of such a condition, including a literature review of well documented cases as well as two recent patients in our institute.

2. Cases

Two patients in the Princess Máxima Center for pediatric oncology, diagnosed with a renal tumor, developed small bowel intussusception within 30 days after tumor nephrectomy. Both patients had received

* Corresponding author. Room: Q.05.2.302, Princess Máxima Center for Pediatric Oncology, Lundlaan 6, 3584 EA Utrecht, The Netherlands.
E-mail address: m.m.vandenheuvel-eibrink@prinsesmaximacentrum.nl (M.M. van den Heuvel-Eibrink).

https://doi.org/10.1016/j.epsc.2017.12.016
Received 15 December 2017; Accepted 20 December 2017
Available online 21 December 2017

primary chemotherapy for localized stage renal tumor according to the SIOP 2001 protocol. Data on clinical presentation, patient characteristics, surgery, histopathology, treatment and outcome were collected from their medical records.

3. Case 1

A 5-years old male presented with a history of hematuria and abdominal pain. Ultrasound revealed a right sided kidney mass with a volume of 380 cm^3. Treatment with 4 weeks of preoperative chemotherapy according to SIOP 2001 (vincristine and actinomycin-D), preceded tumor nephrectomy. Three days after surgery, the patient suffered from bilious vomiting without passing stools and one day later, bowel sounds became impaired. Abdominal x-ray, performed on day 4 after surgery, showed a small bowel obstruction. Subsequent ultrasound of the abdomen confirmed the small bowel obstruction, however the cause of the obstruction was not seen. Relaparotomy showed an evident ileoileal intussusception without a leading point, which was remedied by manual reduction during relaparotomy. Recovery was slow but unremarkable, and the child was discharged on day 9 after tumor nephrectomy. Histology of the tumor revealed nephroblastoma. Follow up was unremarkable, without recurrence of intussusception.

4. Case 2

An 8 months old boy was diagnosed with a localized centrally located left kidney tumor with a volume of 29 cm^3 while being treated for urine tract infection. The patient was preoperatively treated according to the SIOP 2001 protocol. On the first postoperative day, the patient vomited and developed a distended abdomen and did not pass any stools. Abdominal X-ray showed a small bowel obstruction. Subsequent ultrasound of the abdomen confirmed a small bowel intussusception in the right upper quadrant. During relaparotomy an illeoileal intussusception of approximately 10 cm was found which was manually reduced. Further recovery was unremarkable, and the patient was discharged on day 5 after tumor nephrectomy. No recurrence episode occurred during the follow up time. Histology of the tumor later revealed a metanephric adenofibroma and no further therapy was administered.

5. Methods

We systematically searched for all reported cases of post tumor nephrectomy intussusception in literature in PubMed and Embase until November 2016. The search terms were: (child *OR* boy *OR* girl *OR* infant *OR* pediatr* *OR* paediatr*) AND (tumor nephrectomy *OR* nephrectomy *OR* surgery *OR* renal tumor surgery) AND (tumor, wilms'[MeSH Terms] *OR* bilateral wilms tumor[MeSH Terms] *OR* tumor, wilms[MeSH Terms] *OR* cancer, renal cell[MeSH Terms] *OR* renal cell carcinoma[MeSH Terms] *OR* renal cancer[MeSH Terms]) AND (complication, postoperative[MeSH Terms] *OR* complications, postoperative[MeSH Terms] *OR* intussusception[MeSH Terms] *OR* invagination, intestinal[MeSH Terms] *OR* intestinal obstruction[MeSH Terms] *OR* surgical complication *OR* complication).

Cross reference check was performed to identify additional publications of interest. All selected titles and abstracts were explored for relevance to the subject and full articles were analyzed. All studies written in English reporting patients undergoing tumor nephrectomy for renal tumors were included. In case two or more articles described the same patient cohort, the most recent or relevant article was included.

6. Literature review

Literature review identified 225 papers of which we selected 20 on the basis of full text assessments, using the following inclusion criteria: patients who underwent tumor nephrectomy (1) and developed intussusception within 30 days of surgery (2) (Fig. 1). Fifty postoperative intussusception cases after tumor nephrectomy in children in the literature, and 2 local cases, were summarized (Table 1). All cases revealed a nephroblastoma, with the exception of one of our patients. Median age (data available in 25/52 cases) was 23 months (range 3–84 months, Fig. 2a) and 10/25 patients were younger than 1 year. There was an equal distribution of gender. Data on preoperative chemotherapy were available in 47/52 patients (10/47 patients had preoperative chemotherapy). Site of tumor was available in 16/52 cases (left n = 8 and right n = 8), NSS surgery had been performed in 2/52 patients. No cases of tumor rupturation were described. Only 1 patient had received postoperative radiotherapy, before onset of symptoms of

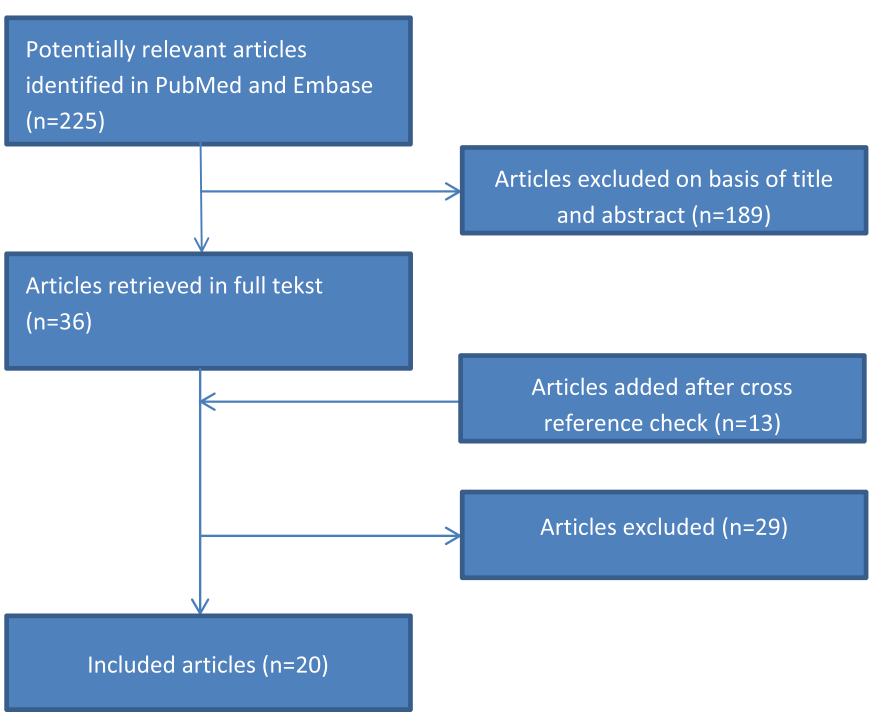

Fig. 1. Flow chart: selection of articles on intussusception after pediatric renal tumor nephrectomy for this narrative review.

Table 1
Reported cases of intussusception after tumor nephrectomy, clinical patient features.

Author, year	No. of pt	Age (months)	Gender (M/F)	Preoperative CT (yes/no)	Tumor nephrectomy site (L, R or NSS)	Postoperative day of onset	Intussusception site	Tumor stage (Loc or Met)	Postoperative day of relaparotomy
Hulbert et al., 1983 [8]	2	5.5	0/2	No	L	5	ileoileal	Loc	5
		84		No	R + RH, partial excision right hemidiafragm	8	midjejunal	Met	37
Kaste et al., 1995 [5]	4	NA	NA	No	NA	1–6	NA	NA	6–18
Pumberger et al., 2002 [7]	1	42	0/1	Yes	NA	3	ileoileal	NA	10
Stevenson et al., 1967 [18]	1	3	1/0	Yes*	L	3	ileoileal	NA	7
Ritchey et al., 1993 [4]	17	NA	NA	No	NA	< 21	ileoileal: 13 ileoileocolic:3 jejunojenunal: 1	NA	NA
Bodycomb et al., 1987 [13]	2	21	0/2	No	R	18	jejunojejunal	Loc	21
		72		No	L	9	jejunojejunal	Met	14
Holcomb et al., 1991 [11]	3	36	1/2	No	R	7	NA	Loc	9
		23		No	R	3	NA	Loc	4
		23		No	NA	6	NA	Loc	7
De Vries et al., 1999 [14]	2	NA	NA	No	NA	NA	NA	NA	NA
				No	NA	NA	NA	NA	NA
Ein et al., 1982 [12]	2	8	1/1	No	NA	5	Ileoileal	NA	14
		24		No	NA	8	ileoileal	NA	14**
Klein et al., 2013 [15]	2	11	NA	No	NA	9	Small bowel	NA	NA
		31		No	NA	11	Small bowel	NA	NA
Türkyilmaz et al., 2005 [10]	1	14	NA	NA	NA	NA	ileoileal	NA	3
Kiesling et al., 1989 [9]	1	48	0/1	No	R	NA	jejunojejunal	NA	10
Fawkner-Corbett et al., 2014 [26]	1	NA	NA	NA	NA	NA	NA	NA	NA
Pritchard et al., 1995 [27]	1	NA	NA	NA	NA	NA	NA	NA	NA
Davidoff et al., 2015 [28]	2	NA	NA	Yes	NSS	5–6	ileoileal	Met	NA
		NA	NA	Yes	NSS		ileoileal		NA
Espineda et al., 1990 [19]	2	12	1/1	NA	L	3	ileoileal	NA	8
		12			R	10	ileoileal		21
Wahid et al., 2014 [21]	1	11.5	1/0	Yes	NSS	5	ileoileal and jejunujejunal	Met	NA
Ein et al., 1971 [20]	1	8	NA	No	NA	14	ileoileal	NA	NA
Elshafiey et al., 2012 [16]	4	80	4/0	No	L	6	ileoileal	NA	NA
		5		Yes	L	12	ileoileocolic	NA	NA
		50		Yes	R	4	ileoileal	NA	NA
		61		Yes	L +RH	9	ileoileal	NA	NA
Our cases, 2016	2***	70	2/0	Yes	R	1	ileoileal	Loc	4
		8		Yes	L	1	ileoileal	Loc	3
Total	52		11/10						

No. = number, pt = patients, NA = Not available, CT = chemotherapy, RT = radiotherapy, * = also preoperative radiotherapy, M = male, F = female, TN = tumornephrectomy, L = Left, R = Right, NSS = nephron sparing surgery, RH = right hepatectomy, Loc = localized stage, Met = metastasized, ** this patient needed a resection of bowel segments, *** second patient has diagnosis of metanephric adenofibroma.

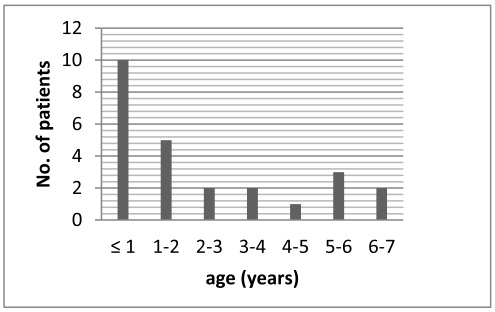

A. Age distribution of reported patients with intussusception

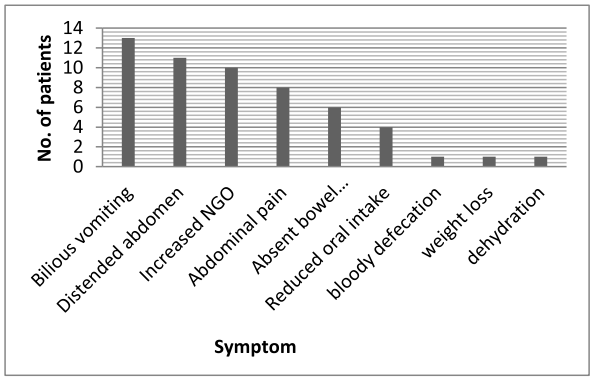

B. Presenting symptoms of patients with postoperative intussusception.

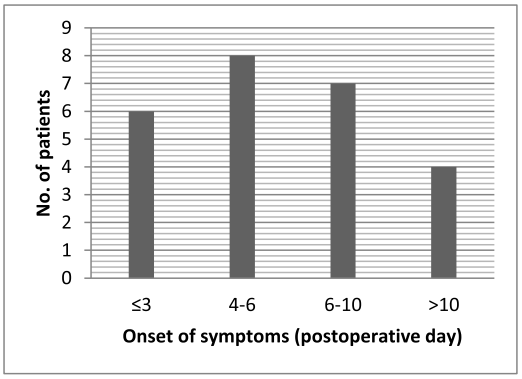

C. Postoperative day at onset of symptoms of intussusception

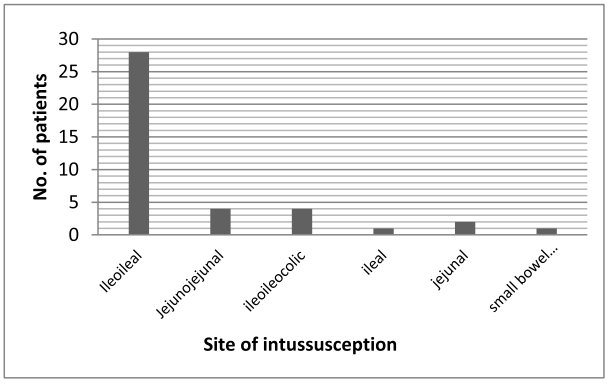

D. Localization of postoperative intussusception in the intestine.

Fig. 2. Details on patients with intussusception and of intussusception type.

intussusception. Reported clinical presenting symptoms of postoperative intussusception (Fig. 2b) were bilious vomiting (n = 13), distended abdomen (n = 11), increased nasogastric tube output (n = 10), abdominal pain (n = 8), impaired bowel movements (n = 6), reduced oral intake (n = 4), bloody defecation (n = 1), weight loss (n = 1) and dehydration (n = 1).

In 25 cases, the exact postoperative day of onset of intussusception was reported (Fig. 2c), median time from initial surgery to onset of symptoms was 6 days (range 1–18 days), 21/25 (84%) patients presented before the 10th postoperative day. Number of days from first symptoms of intussusception to relaparotomy ranged from 1 to 29, with a median of 4 days. There was a median of 9 days between initial tumor nephrectomy and relaparotomy.

Records from 41 patients were available on details of the intussusception: 30/41 of the intussusceptions had been ileoileal, 6 jejunojejunal, 2 unspecified small bowel intussusception and only 4 ileocolic (Fig. 2d). Data on tumor stage in relation to postoperative intussusception was only available in 10 patients, both local stages and metastatic disease were reported in relation to postoperative intussusception. Of the 30/52 patients with well described relaparotomy procedures, 29 patients were successfully manually reduced during second this surgery. Only 1 patient needed a partial bowel resection because of intestinal necrosis due to the intussusception.

None of the patients developed recurrence of obstruction at a later stage in follow up (follow up data on 35/52 patients).

7. Discussion

In literature, we found a limited amount of reports on post tumor nephrectomy intussusception in children. Only few series are available on this relevant complication in the treatment of childhood renal tumors and a comprehensive review on this subject is lacking.

Our data showed that there was no influence of site of tumor nephrectomy (left or right) on the risk of developing postoperative intussusception (Table 1). We identified, based on the included cases, that postoperative intussusception mainly occurred in very young children with an apparent preference for children < 1 year. Our literature review exclusively identified cases of postoperative intussusception after renal tumor surgery in children with Wilms tumor in literature, we have shown here for the first time, that also in more benign non-Wilms tumors, i.e. metanephric adenofibroma, such complications may occur [1–19]. Interestingly, in adults, postoperative intussusception has never been described after sole tumor nephrectomy. In metastatic renal tumors, few case reports of adult intussusception have been described as a result of bowel metastasis, though [23–25].

Our summary shows, that patients suffering from postoperative intussusception present with vague symptoms, but mostly with bilious vomiting, distended abdomen and increased nasogastric output [5,7–16,18,19,21]. Interestingly, none of the patients presented with bloody stools, which is a discrepancy with idiopathic intussusception in children, which has a well-known presentation of palpable abdominal mass, vomiting, colic abdominal pain and pathognomic 'currant jelly' stools [7–9,11,12,14,15,17,19]. The rarity of this condition as well as the lack of such more obviously explicit signs and symptoms may explain the relative delay in diagnosis in the majority of cases reported. This effect is amplified by the fact that patients in the early postoperative period are already suffering from nausea and pain. Moreover, the obstruction signs also mimic effects of surgery as well as chemo- or radiotherapy, which a substantial subset of the patients had recently received. Identification of intussusception, may further be complicated by analgesia use, like opiates, which most patients still use after

surgery, and which may disguise the symptoms of postoperative intussusception [5,7,8–19,21].

The discrepancy in presenting symptoms between postoperative intussusception and idiopathic intussusception as mentioned above, can be explained by the difference of location. We here show, that postoperative intussusception seems to be in nearly every case, located in the small bowel, primarily ileoileal and jejunojejunal, whereas idiopathic intussusception in children seems to be mostly located ileocolic. This may create aberrant symptomatology and provide diagnostic problems, since intussusception can be easily disguised when it is located in the small bowel.

The etiology of postoperative intussusception after tumor nephrectomy remains to be identified. In naïve patients, a variety of perioperative and treatment related factors have been suggested as cause for intussusception. Lymph nodes in case of viral infections, treatment related factors such as radiotherapy and neurotoxicity due to preoperative chemotherapy such as vincristine. In series, 9 patients got preoperative vincristine (chemotherapy data available in 46/52 patients), 1 patient had received preoperative radiotherapy and only 1 patient got postoperative radiotherapy before the onset of intussusception after tumor nephrectomy. Some surgical factors have been reported to be relevant, such as suture lines. Also drying of bowel segments, analgetic use (e.g. opioids), lymph node dissection/biopsy, hypertrophy of Peyer's patches, long term compression of bowel segments, perioperative perfusion deficits and impaired bowel innervation caused by extensive retroperitoneal dissection have been suggested to be relevant [5,7,9–19,21]. Ahmed et al. (IPSO meeting 2015) suggested surgical techniques as a contributing factor to the etiology of intussusception, i.e. cutting anatomical peritoneal reflections and manipulation of the small bowel would cause the small bowel to migrate into the retroperitoneal space and thereby predispose obstruction. In a modified approach, they used a transverse incision where they cut peritoneal reflections short to the caecum or sigmoid thereby well reserving the phrenocolic ligament, so that the small bowel was protected while performing nephrectomy [22].

Our reviewed data and numbers of patients does not provide any evidence based 'golden standard' on which diagnostic tool is preferred to diagnose postoperative intussusception. Abdominal X-rays are obviously used to show obstruction only [13,19]. Ultrasound was reported to show a high diagnostic value in small bowel intussusception [7,10,14], with a sensitivity of 80% [10]. From a clinical logistic standpoint X-rays and ultrasound in expert pediatric radiology settings are the preferred diagnostic step, as, when a patient is suspected to have postoperative intussusception, rapid relaparotomy is important. To date, no other therapeutic alternatives have been described, and enema reduction is obviously not recommended because enema reduction is only performed in ileocolic intussusception. Therefore, rapid relaparotomy is advised to avoid therapeutic delay, and consequent higher the risk of necrosis of bowel parts, which would require (partial) bowel resection. The latter results in the 2–8% mortality in postoperative intussusception, in general [9,12,15]. In 90–96% of cases, the postoperative intussusception was managed by manual reduction during relaparotomy. No recurrences occurred in any of the included reports [5,7–12,14,17,19].

In summary, this first narrative review of all well-documented rare cases with postoperative intussusception in pediatric renal cancer cases shows, that in general, children that develop such a condition, are very young. Here, we add for the first time a so called non Wilms tumor patient, i.e. a patient with a metanephric adenofibroma to the previously only described Wilms tumor cases that developed postoperative intussusception after tumor nephrectomy. Our data shows that site of tumor nephrectomy (right or left) does not seem to influence the development of intussusception. The diagnosis of postoperative intussusception is often disguised and delayed, which may be due to the fact that symptoms mimic chemotherapy related toxicity and general post surgical symptoms and intussusception after tumor nephrectomy seems to predominantly occur in the small bowel (ileoileal and jejunojejunal), in contrast to idiopathic intussusception in children, which mainly includes ileocolic intussusception with a consequent clear presentation. When postoperative intussusception is diagnosed timely, manual reduction during relaparotomy is successful in al reported cases so far. Awareness of intussusception as a rare but important complication after renal tumor surgery is warranted.

Conflict of interest statement

We confirm there is no conflict of interest for any of the authors, who contributed to this manuscript.

References

[1] American Cancer Society. Wilms Tumor: key statistics Available from: http://www.cancer.org/cancer/wilmstumor/detailedguide/wilms-tumor-key-statistics; 2016 Feb 2, Accessed date: 10 October 2016.

[2] Ritchey ML, Shamberger RC, Haase G, Horwitz J, Bergemann T, Breslow NE. Surgical complications after primary nephrectomy for Wilms' tumor: report from the national Wilms' tumor study group. J Am Coll Surg 2001 Jan;192(1):63–8.

[3] American Cancer Society. Wlims tumor: survival rates available from: http://www.cancer.org/cancer/wilmstumor/detailedguide/wilms-tumor-survival-rates; 2016 Feb 2, Accessed date: 10 October 2016.

[4] Ritchey ML, Kelalis PP, Etzioni R, Breslow N, Shochat S, Haase GM. Small bowel obstruction after nephrectomy for Wilms' tumor. A report from the national Wilms' tumor Study-3. Ann Surg 1993 Nov;218(5):654–9.

[5] Kaste SC, Wilimas J, Rao BN. Postoperative small-bowel intussusception in children with cancer. Pediatr Radiol 1995;25:21–3.

[6] Fuchs J, Kienecker K, Furtwängler R, Warmann SW, Bürger D, Thürhoff JW, et al. Surgical aspects in the treatment of patients with unilateral Wilms tumor: a report from the SIOP 93-01/German Society of Pediatric Oncology and Hematology. Ann Surg 2009 Apr;249(4):666–71.

[7] Pumberger W, Pomberger G, Wiesbauer P. Postoperative intussusception: an overlooked complication in pediatric surgical oncology. Med Pediatr Oncol 2002;38:208–10.

[8] Hulbert WC, Valvo JR, Caldamone AA, Putnam TC, Emmens RW, Rabinowitz R. Intussusception following resection of Wilms tumor. Urology 1983 Jun;21(6):578–80.

[9] Kiesling Jr. VJ, Tank ES. Postoperative intussusception in children. Urology 1989 May;33(5):387–9.

[10] Türkyilmaz Z, Sönmez K, Demirogullari B, Karabulut R, Özen IO, Moralioglu S, et al. Postoperative intussusception in children. Acta Chir Belg 2005 Apr;105(2):187–9.

[11] Holcomb 3rd GW, Ross 3rd AJ, O'neill Jr. JA. Postoperative intussusception: increasing frequency or increasing awareness? South Med J 1991 Nov;84(11):1334–9.

[12] Ein SH, Ferguson JM. Intussusception—the forgotten postoperative obstruction. Arch Dis Child 1982 Oct;57(10):788–90.

[13] Bodycomb JL, Beasley SW, Auldist AW. Postoperative intussuception. Pediatr Surg Int 1987;2:108–9.

[14] de Vries S, Sleeboom C, Aronson DC. Postoperative intussusception in children. Br J Surg 1999 Jan;86(1):81–3.

[15] Klein JD, Turner CG, Kamran SC, Yu AY, Ferrari L, Zurakowski D, et al. Pediatric postoperative intussusception in the minimally invasive surgery era: a 13-year, single center experience. J Am Coll Surg 2013 Jun;216(6):1089–93.

[16] Elshafiey MM, Meselhy GT, Refaat A, Younes AA. Postoperative intussusception in pediatric abdominal malignancies: early diagnosis and management. Chin Ger J Clin Oncol 2012;11(8):478–83.

[17] Yang G, Wang X, Jiang W, Ma J, Zhao J, Liu W. Posotperative intussusceptions in children and infants: a systematic review. Pediatr Surg Int 2013 Dec;29(12):1273–9.

[18] Stevenson EO, Hays DM, Snyder Jr. WH. Postoperative intussusception in infants and children. Am J Surg 1967 Apr;113(4):562–6.

[19] Espineda BR, Tsugawa C, Muraji T, Tanaka E, Nishijima E, Matsumoto Y. Postoperative intussusception: a diagnostic dilemma. Pediatr Surg Int 1990 May;5(3):179–81.

[20] Ein SH, Stephens CA. Intussusception: 354 cases in 10 years. J Pediatr Surg 1971;6:16–27.

[21] Wahid FN, Malkan AD, McCarville MB, Davidoff AM. Double small bowel intussusception complicating bilateral partial nephrectomies. J Pediatr Surg Case Rep 2014 Jan;2(1):30–2.

[22] Ahmed G, Hafiz H. Decreasing the incidence of post operative intestinal obstruction in Wilms tumor: a modified surgical approach. Pediatr Blood Canc 2015 Sept 9;62(S4):42.

[23] Bellio G, Cipolat Mis T, Kaso G, Dattola R, Casagranda B, Bortul M. Small bowel intussusception from renal cell carcinoma metastasis: a case report and review of the literature. J Med Case Rep 2016 Aug 11;10(1):222.

[24] Hedge RG, Gowda HK, Agrawel RD, Yadav VK, Khadse GJ. Renal cell carcinoma presenting as small bowel obstruction secondary to a metastatic ileal intussusception. J Radiol Case Rep 2014 Apr 1;8(4):25–31.

[25] Tutar NU, Töre HG, Aydin HM, Geyik E, Coskun M, Niron EA. Case report: jejuno-

jejunal invagination from metastatic renal cell carcinoma. Br J Radiol 2008 Apr;81(964):e115–7.
[26] Fawkner-Corbett DW, Howel L, Pizer BL, Dominici C, McDowell HP, Losty PD. Wilms' tumor – lessons and outcomes – a 25-year single center UK experience. Pediatr Hematol Oncol 2014 Aug;31(5):400–8.
[27] Pritchard J, Imeson J, Barnes J, Cotterill S, Gough D, Marsden HB, et al. Results of the United Kingdom Children's cancer study group first Wilms' tumor study. J Clin Oncol 1995 Jan;13(1):124–33.
[28] Davidoff AM, Interiano RB, Wynn L, Delos Santos N, Dome JS, Green DM, et al. Overall survival and renal function of patients with synchronous bilateral Wilms tumor undergoing surgery at a single institution. Ann Surg 2015 Oct;262(4):570–6.