Controversies in gynaecologic endoscopic surgery

Controversies in gynaecologische endoscopische chirurgie

(met een samenvatting in het Nederlands)

Proefschrift

ter verkrijging van de graad doctor aan de Universiteit Utrecht op gezag van de rector magnificus, prof.dr. J.C. Stoof, ingevolge het besluit van het college voor promoties in het openbaar te verdedigen op donderdag 9 juli 2009 des middags te 4.15 uur.

door

Atef Mohammad Mostafa Darwish

geboren op 7 Juli, 1961 te Assiut, Egypt

Promotor: prof.dr. N.S. Macklon

Co-promotor: dr. F.J. Broekmans

The work presented in this thesis was performed at the Department of Obstetrics and Gynaecology, Woman's Health University Center, Assiut University, Assiut, Egypt.

This work is NOT supported partially or completely, directly or indirectly by any drug company or organization.

To my wife; ***Wafaa***, and my children, without their continuous support this work could not be completed

Contents

Section 1.

1.a Introduction.

1.b Review of the literature.

1.c Remaining research questions.

1.d Aim of the work.

1.a Introduction:

Reconstructive gynaecologic surgery:

The specialty of gynaecology continues to evolve and redefine itself on a regular basis. The scope of primary gynaecologic surgery is mainly focused on removing genital organs partially or completely or lesions related to the genital organs aiming to relieve the patient's complaint. Performing abdominal hysterectomy to treat abnormal uterine bleeding is a clear example. On the other hand, reconstructive gynaecologic surgery is performed to treat the primary disease as well as refashion abnormal genital organs to restore anatomy and more importantly improve function. Reconstructive surgery also aims to put genital organs and tissues back together in a way that makes them more functional, and /or with fewer clinical symptoms. It leads to reduce potential problems and side effects from primary surgery and improve patients' quality of life. Early discharge within 24 hours after the procedure with an excellent outcome is a common sequel to reconstructive gynaecologic surgery even if done via laparotomy (1). Nevertheless, reconstructive surgery requires high level of expertise, delicate instruments, fine maneuvers, longer time, and fine energy modalities. Abnormal structures of the genital tract that are corrected during reconstructive surgery may be the result of birth defects, developmental abnormalities, trauma or injury, infection, tumors, or endometriosis. Thus, reconstructive gynaecologic surgery is a broad term covering a lot of gynaecologic subsepecielities e.g. urogynaecology (2), infertility (3), onocology (4), breast reconstruction (5) and pelvic floor dysfunction (6).

Endoscopic resonstructive gynaecologic surgery

The discovery of penicillin and insulin as well as the introduction of ultrasonography are imprinted in the memory of all physicians as revolutionary stops along the road of advancement of medicine. Likewise, one of the outstanding achievements in medicine has been the development of endoscopic surgery which is nowadays practiced within all surgical specialties. In gynaecology, both hysteroscopic as well as laparoscopic approaches have dramatically changed and in many cases replaced most of the traditional approaches. Thus, adding endoscopic approach to the principles of reconstruction is expected to achieve best results for the women's health.

Hysteroscopic approach to reconstructive gynaecologic surgery

The concept of natural orifice transluminal endoscopic surgery (NOTES) as a minimally invasive surgical technique is gaining increasing popularity (7). The principal advantages of this approach include decreased invasiveness and postoperative pain, lower risk of postoperative hernia formation and improved cosmetic results (8). Hysteroscopy represents an ideal example of NOTES. Moreover, it doesn't require an incision and is performed by using the woman's cervix for uterine access without suturing. Operative hysteroscopic procedures may be performed as day cases, even under local anaesthesia.

However, hysteroscopic access to the endometrial cavity can be problematic in some cases. Although cervical priming prior to hysteroscopic procedures may be helpful, particularly in nulliprous or postmenopuasal women, little data exists to guide patient selection or the method to be employed. In this thesis, we introduce a randomized trial comparing two

methods of cervical priming prior to hysteroscopic surgery. The mode of access to the uterus is common to all hysteroscopic interventions.

Laparoscopic approach to reconstructive gynaecologic surgery

Since the early breakthroughs by its pioneers (9-12), laparoscopic gynaecologic surgery is gaining popularity due to developments in illumination and instrumentation that led to the emergence of laparoscopy in the late 1980's as a credible diagnostic as well as therapeutic intervention. Performing reconstructive gynecological surgery is appreciated as it is cosmetically acceptable to patients due to small skin incisions with short hospital stay, low liability of ileus, fast recovery, minimal post-operative pain and discomfort, and early resumption of normal activities and employment (13). Furthermore, there is reduced contamination of the surgical field with glove powder or lint, bleeding is reduced due to tamponade of small vessels by the pneumoperitoneum, and drying of tissues is minimal because surgery occurs in a closed environment (14). All these factors contribute to reduced postoperative adhesion formation and its associated morbidity (eg, pain, impaired fertility, bowel obstruction) (15). Of particular importance, laparoscopy offers easy intraoperative access to the pouch of Douglas and the posterior aspects of the genital organs with good magnification, and the ability to perform an underwater examination at the end of the procedure during which all blood clots are evacuated and meticulous hemostasis is obtained (16). Nevertheless, the adage that no surgery is without risk also applies to laparoscopic surgery (17-20). Out Of 25,764 laparoscopic procedures, 145 complications (rate 5.7 per 1000) were reported in one study (20). The authors concluded that operative laparoscopic procedures are still hazardous and women with a previous laparotomy are particularly at

risk. Nevertheless, most of these complications occur with blind insertion of instruments (21). Continuous training and upgrading of the level of the laparoscopist as well as preoperative preventive measures of complications should be encouraged (22).

Fertility-preserving reconstructive gynaecologic surgery:

If future fertility is of concern, endoscopic reconstructive gynaecologic surgery should follow microsurgical principles (23,24) which include avoidance of serosal insults e.g. tissue trauma, ischemia, hemorrhage, infection, foreign-body reaction, and leaving raw surfaces (25). Other microsurgical principles include minimizing tissue trauma by using atraumatic techniques, meticulous hemostasis, complete excision of abnormal tissues and precise alignment and approximation of tissue planes (26). With this so meticulous reconstruction of the gynaecological structures, maximal possibilities of pregnancy without the utilization of other complex procedures of assisted reproduction can be achieved. It has been estimated by some enthusiastic proponents that microsurgery could results in double the pregnancy rate compared conventional macrosurgery (27). However, a recent Cochrane review did not demonstrate any advantage of microsurgery over the conventional approach (25). Laparoscopic microsurgeons should have enough experience in classical microsurgery as well as highly-developed two-handed laparoscopic skills for intracorporeal knotting (28,29).

Robotics in reproductive medicine

Along the road of refinement of endoscopic reconstructive gynaecologic surgery, robotic technology, more specifically telerobotic surgical systems, has been used to bridge this gap between laparotomy and laparoscopy by enabling minimally invasive surgery with three-

dimensional vision, ergonomically optimal positioning, tremor filtration, and laparoscopic instruments with intra-abdominal articulation (30,31). This remarkable technology facilitates suturing and discestion (32). Although the learning curve is steep, the robot may actually level the playing field among various skilled gynecologic surgeons performing laparoscopy for the management of complex pathology. Nevertheless, a skilled laparoscopic surgeon may not find any advantage in the meantime with the current robotic prototypes. Some major disadvantages of robot-assisted endoscopy iclude lack of tactile feedback or haptics and the high costs of the equipements. The size of some of the robotic systems may also be a limitation (33).

1.b Review of literature

In the following section, some examples of endoscopic reconstructive gynaecologic surgeries related to the topics of this thesis will be overviewed with stress on the pros and cons of the endoscopic approach in comparison to the conventional laparotomic approach.

1.b.1 Hysteroscopic reconstruction of Müllerian duct anomalies:

Most of the published data on this topic are related to hysteroscopic metroplasty of complete or partial uterine septum, which has been practiced since 1981 when Chervenenak and Neuwirth performed the first hysteroscopically-guided metroplasty (34). Since that time, laparotomic Tompkin's metroplasty has become an old technique (35). Hysteroscopic metroplasty, with its simplicity, minimal postoperative sequelae, and improved reproductive outcome has enabled a more liberal approach to treatment that is now being extended to include not only patients in whom an anatomic anomaly is considered to underly recurrent pregnancy loss and premature labour but also patients with infertility, especially if IVF is being contemplated (36). However, caution is necessary, as hysteroscopic metroplasty has not been shown to increase pregnancy rates in infertile women (35, 37-41).

1.b.2. Reconstructive hysteroscopic myomectomy:

Submucous myoma may cause abnormal vaginal bleeding, pain, &/or infertility. The incidence of myoma in women with otherwise unexplained infertility is estimated to be 1.0–2.4% (42,43). Submucous myomata can be classified into grade 0 where the myoma is totally intracavitary, grade 1 where more than 50% of the myoma is intracavitary, and grade 2 where less than 50% of the myoma is intracavitary (44). A systematic review of 11 cohort studies suggests that women with submucous myoma have lower pregnancy rates compared with women with other causes for their infertility (RR 0.30, 95% CI 0.13 to 0.70). Myomectomy was not associated with an increase in live birth rate (RR 0.98, 95% CI 0.45 to 2.41) but was associated with a higher pregnancy rate (RR 1.72, 95% CI 1.13 to 2.58) (45). Both hysteroscopic polypectomy and myomectomy appeared to enhance fertility

compared with infertile women with normal cavities in one study (44). Hysteroscopic myomectomy currently represents the standard minimally invasive surgical procedure for treating submucous fibroids, with abnormal uterine bleeding and reproductive issues being the most common indications (46,47). Nevertheless, this technique is associated with significant risks of excessive bleeding, prolonged operative time required for cutting the myoma into chips of tissues and extractiing them, risks of fluid overload, and the possibility of incomplete resection and perforation (48). To reduce these risks, more effective patient selection and improved techniques are necessary (49).

1.b.3 Role of hysteroscopy in assisted reproduction:

Failure of IVF treatment can be broadly attributed to embryonic, uterine or transfer factors, but remains unexplained in most cases (50). A number of interventions have been proposed to improve IVF outcome, many of which are not strictly evidence-based and their efficacy in improving pregnancy rates remains controversial (51,52). One of the main causes of failure of implantation after proper embryo transfer is intrauterine pathology. Whether to perform hysteroscopic evaluation of the endometrial cavity prior to IVF/ICSI especially in patients with repeated failures is a very controversial issue that is open for critisim and deserves further studies (53).

In a recent systematic review (Level Ia evidence), 5 reliable studies were included (54). Two RCT showed a statistically significant improvement in the clinical pregnancy rate in the group who had office hysteroscopy (pooled RR = 1.57, 95% CI 1.29–1.92, $P < 0.00001$). The miscarriage rate was not statistically different between the office hysteoscopy and control groups in either study (24% versus 29%, respectively, RR = 0.83,

95% CI 0.56–1.21, $P = 0.33$). Three non-randomized controlled studies suggests that office hysteroscopy improves the pregnancy rate in the subsequent IVF cycle (pooled RR = 2.01, 95% CI 1.60–2.52, $P < 0.00001$). In addition to the well known diagnostic as well as therapeutic advantages of performing hysteroscopy, even if the endometrial cavity was completely free, high pregnancy rate was achieved after diagnostic hysteroscopy since uterine instrumentation during hysteroscopy would inevitably cause a degree of endometrial injury and provokes a posttraumatic reaction that involves release of cytokines and growth factors (53,54), which in turn may influence the likelihood of implantation (56). Commencing IVF treatment soon after hysteroscopy may take advantage of this immunological response (57). Performing diagnostic hysteroscopy before assisted reproductive technologies (ART) may be advisable not only from the clinical but also from the economic point of view (58). Enhanced clinical pregnancy rates would be achieved on adding office hysteroscopy as a complementary step prior to IVF specially patients with recurrent IVF embryo transfer failures even after normal hysterosalpingography findings (59-62). Some abnormal intrauterine findings that would affect the prognosis of IVF/ICSI can be easily diagnosed by hysteroscopy like chronic endometritis, Müllerian anomalies, retained fetal bones, or endocervical ossification (63). Moreover, contact hysteroscopy may reveal addition valuable findings such as polyposis, strawberry pattern, hypervascularisation, irregular endometrium with endometrial defects, or cystic haemorrhagic lesion which are commonly seen with adenomyosis (64).

In recent years, considerable attention has been given to the possible impact of the presence of hydrosalpinx on implantation and ongoing pregnancy rates following IVF/ICSI (65-66). The mechanism of disruption remains uncertain. However, proposed mechanisms may be

attributed to alteration in endometrial receptivity or direct embryo toxic effect (67). Furthermore, hydrosalpnix is liable be unintentionally punctured at the time of egg retrieval or it may disturb the access to the ovary if it is too big. A systematic review of three RCTs (68) showed that tubal surgery such as laparoscopic salpingectomy significantly increased live birth rate (OR 2.13; 95% CI 1.24 to 3.65) and pregnancy rate (OR 1.75; 95% CI 1.07 to 2.86) in women with hydrosalpinges before IVF when compared with no treatment. There were no significant differences in the odds of ectopic pregnancy (OR 0.42; 95% CI 0.08 to 2.14), miscarriage (OR 0.49; 95% CI 0.16 to 1.52), treatment complication (OR 5.80; 95% CI 0.35 to 96.79) or implantation (OR 1.34; 95% CI 0.87to 2.05) (68). Since hydrosalpinx reduces IVF pregnancy rates (69), t is therefore suggested that women with hydrosalpinges should be offered diagnostic/operative laparoscopy and a trial of salpingoneostomy. If failed or inaccable, salpingectomy could be offered prior to IVF/ICSI to improve the chance of a live birth. Sometimes, laparoscopic access to the isthmic part of the tube is not feasible even in experienced hands particularly in patients with history of repeated laparotomies, intestinal reanastomosis, or kidney transplantation. This situation may pave the way to hysteroscopic occlusion of the fallopian tubes based on the reported success in hysteroscopic tubal cannulation and sterilization techniques.

1.b.4 Overview on laparoscopic ovarian drilling in PCO:

In modern practice, surgical methods of ovulation induction for women with clomifene citrate-resistant polycystic ovarian syndrome (PCOS) only include laparoscopic ovarian drilling (LOD). This technique is designed to create several ovarian stromal drills, which may help correct endocrine abnormalities and trigger ovulation. LOD, which has been evaluated in well-designed trials, may be an alternative to gonadotropins (70). A systematic review of four RCTs found no significant differences between LOD after 6–12 months follow-up and 3–6 cycles of ovulation induction with gonadotrophins in cumulative pregnancy rate (OR 1.42; 95% CI 0.84 to 2.42) or miscarriage rate (OR 0.61; 95% CI 0.17 to 2.16) in women with clomifene citrate-resistant PCOS(71). Multiple pregnancy rates were considerably reduced in those women who conceived following laparoscopic drilling (OR 0.16; 95% CI 0.03 to 0.98). Although gonadotropin treatment and LOD have demonstrated similar reproductive outcomes, LOD has some advantages over gonadotropin treatment such as lower cost per pregnancy, improvement in menstrual regularity, and better long-term reproductive performance (72). However, ovarian reserve assessed by hormonal levels and sonography seems to be lower in the LOD than in the PCOS group without LOD in a recent study (73). This risk of damaged ovarian reserve could be minimized if LOD is restricted to patients with high preoperative LH level as demonsterated in a retrospective cohort study (74). One RCT showed a significant difference between the use of a fine or thick needle in the occurrence of adhesion formation (52% with fine needle versus 88% with a thick needle, RR 0.59, 95% CI 0.39 to 0.91) in LOD in patients with PCOS (75). A retrospective study showed that three punctures per ovary appeared to be the plateau dose for laparoscopic ovarian diathermy (76).

Nevertheless, more punctures were recommended like 5 punctures (77) or even up to 15 punctures in another study (78). In a recent RCT, unilateral ovarian drilling in PCOS was shown to be effective, less time-consuming and probably associated with fewer complications than bilateral drilling (79). LOD can impose technical problems and anaesthetic risks in obese women with PCOS (80). Whether done via standard laparoscopy or microlaparoscopy, the efficacy of LOD in PCOS, estimated by ovulation and pregnancy rates within 12 months of follow-up is similar as well as the trends in hormonal changes. Ovarian electrocautery was significantly longer in microlaparoscopy, but the difference in time was of no practical impact (81). Nevertheless, a small sample sized study demonsterated decreased adhesion formation following microlaproscopic LOD compared with conventional laparoscopic LOD. This finding may possibly be due to lack of or minimal adverse effects on peritoneal microcirculation and cell-protective systems, which are proposed mechanisms for adhesion formation and closely related to peritoneal injury (82).

In recent years, there is a growing interest in transvaginal hydrolaparoscopic LOD by some teams in France (83), Italy (84), and Belgium (85). Utilizing fine bipolar electrode, LOD can be easily performed in a shorter time compared to the standard laparoscopy. They achieved high pregnancy rate within 6 months of the procedure (71% at 6 months (83), 76% at about 8 months (85)). Neveretheless, many gynecologists don't practice transvaginal hydrolaparoscopy as they consider it less informative than standard laparoscopy (86) or even minilaparoscopy. Therefore, further comparative studies of hydrolaparoscopy versus standard laparoscopy especially efficacy and cost effectiveness are badly needed.

1.b.5 Laparoscopic reconstructive surgery in gynaecologic emergencies:

The clinical situation in some gynaecologic emergencies may oblige some gynecologists to rush in performing unneeded laparotomies. Emergency laparoscopic surgery allows both the evaluation of acute abdominal pain and the treatment of many common acute abdominal disorders. Laparoscopic surgery is firmly established as the best intervention in acute appendicitis, acute cholecystitis and most gynaecologic emergencies but requires further RCTs to definitively establish its role in other conditions (87). Many acute gynaecologic disorders can be diagnosed and treated via laparoscopy (88). Following conventional investigations, diagnostic laparoscopy is highly effective (89) and recommended (90).

A. Ectopic pregnancy:

One of the best examples is ectopic pregnancy (EP). There is a significant amount of high quality evidence regarding the role of laparoscopic surgery in ectopic pregnancy (EP). In confirmed EP, laparoscopy should be performed unless haemodynamic instability is present. The first case report of laparoscopic excision of a tubal ectopic pregnancy was published in 1973 (91). Since then, much data has been published concerning the effectiveness of treatment as well as the fertility outcome of EP treated by laparoscopic salpingostomy and salpingectomy. Laparoscopy is fast, cheaper (92), and fertility outcome is comparable to laparotomy (93). Furthermore, hospitalization and sick leave times are shorter, and adhesion development reduced when compared to laparotomy (94). Laparoscopic salpingostomy in the treatment of EP has been associated with an 85% tubal patency rate; a subsequent intrauterine pregnancy rate of 55–61.2% and a recurrent EP rate of between 14 to 15.5%(95-98). The rate of persistent EP after laparoscopic salpingostomy

has been reported to range from 3.3% to 20% with a mean of 8.3%15. If tubal rupture has occurred, a laparoscopic salpingectomy should be performed. Data on laparoscopic salpingectomy is less extensive but investigators (99) have reported subsequent IUP rates of 50–54% and recurrent ectopic pregnancy (REP) rates of 7.7%–15.2%. However, in cases of unruptured tubal pregnancy, a tube preserving operation should be considered (100). Compared to laparotomy, several authors have shown that for hemodynamically stable patients, the laparoscopic approach had similar operating times, less blood loss and significantly shorter hospital stays (93,101-103). A RCT of cost-effectiveness (103) done on 109 patients subjected to either laparotomic or laparoscopic treatment of EP, reported that laparoscopic treatment was as effective as laparotomy but at lower costs. Laparoscopic surgery has improved our management of surgical emergencies and in certain conditions is now an essential part of recent practice. What is clear is that as surgical expertise and technology both continue to improve, so the remit for laparoscopic surgery will expand, to the benefit of patients (104).

In modern practice, there is a place for medical treatment of EP (105) thanks to the use of sensitive assays for hCG and the high definition of vaginal ultrasound. By using these sensitive diagnostic tools, we are now able to select those patients who are most likely to respond to medical management. A variable dosing methotrexate regimen is more effective if compared with single dose regimen. The fixed multiple regimen is associated with a high rate of side effects (106). Besides being less invasive and associated with significantly lower risks, medical therapy with methotrexate (MTX) was found to be more cost effective than laparoscopic surgery, but the frequent need for second-line treatment should be assessed (107). Thus, the main goal is to identify those patients with EP who are most likely to respond to MXT and least likely to develop significant side effects. Recent studies

have helped us define the predictors of success with MXT treatment in women with ectopic pregnancy. The reported success rates of treating EP with methotrexate vary from 71% to 100%. The highest success rates have been reported from institutions that have detailed diagnostic and therapeutic protocols, readily available assays for serum hCG levels, high-resolution vaginal probe ultrasound, and support staff that can closely monitor clinical response. The importance of developing specific protocols to create a clinical environment that supports the effective use of medical therapy for ectopic pregnancy is confirmed by the associated cost savings, decreased morbidity, and patient preference. Modern diagnostic advances and minimally invasive treatments coupled with improved success rates for assisted reproductive technologies should reduce the morbidity and mortality associated with ectopic pregnancy and offers the affected couple a much more optimistic outlook for subsequent reproductive potential (107). In the Netherlands, a controlled clinical trial was conducted to evaluate patient preferences for systemic MXT therapy relative to laparoscopic salpingostomy in the treatment of tubal pregnancy. They concluded that systemic methotrexate therapy would be preferred by most patients as part of a completely nonsurgical management strategy (108). However, the same team found MXT to have a more negative impact on patients' health-related quality of life than did laparoscopic salpingostomy (109).

B. Adnexal torsion:

Ovarian cyst accidents include cyst rupture, haemorrhage and torsion. These accidents are considered organ-threatening conditions that cause patients to present with acute lower abdominal pain. Initially, pregnancy must be excluded, and transvaginal scan performed to exclude ovarian cyst formation. Torsion commonly occurs to the whole adnexa and is not

necessarily associated with an ovarian cyst. Suspected adnexal torsion should always be managed with early laparoscopy and de-torsion of the twisted tube or ovary. Ovarian cyst rupture and haemorrhage usually occur in association with functional cysts and are generally self-limiting (110). However, torsion of other types of benign cysts has been reported like dermoid cysts or paraovarian cysts (111). Early diagnosis can help prevent irreversible structural damage and may allow conservative, ovary-sparing treatment.

Laparoscopy may be necessary in cases where the diagnosis is in doubt or for haemodynamic compromise. If pain fails to settle, laparoscopy must be performed to exclude adnexal torsion (112). Clinical features of ovarian cyst accidents are nonspecific. Ultrasound is the first-line investigation and is diagnostic in the case of haemorrhage. Typical ultrasound findings have been described for ovarian torsion, including an enlarged oedematous ovary with peripheral displacement of follicles. In adnexal torsion, the ovary, ipsilateral fallopian tube, or both twist with the vascular pedicle, resulting in vascular compromise. Unrelieved torsion is likely to cause hemorrhagic infarction as the degree of arterial occlusion increases. Therefore, early diagnosis is important to preserve the affected ovary. Adnexal torsion commonly accompanies an ipsilateral ovarian neoplasm or cyst but can also occur in normal ovaries, usually in children. Although ultrasonography is typically the initial emergent examination, computed tomography (CT) and magnetic resonance (MR) imaging may also be useful diagnostic tools. Common CT and MR imaging features of adnexal torsion include fallopian tube thickening, smooth wall thickening of the twisted adnexal cystic mass, ascites, and uterine deviation to the twisted side (113). Doppler blood flow findings are variable and not diagnostic. If clinical suspicion for torsion is high, early diagnosis and treatment via laparoscopy is encouraged as a means of preserving

ovarian and fallopian tube integrity and maintaining fertility, especially in reproductive-age women. Recurrent cyst rupture or haemorrhage should be prevented by suppression of ovulation, usually with the combined oral contraceptive. Fixation of the ovary by a variety of techniques should be considered to prevent recurrent torsion. Most of twisted ovarian cysts found during laparoscopy can be treated laparoscopically (114). Laparoscopic surgery to repair ovarian torsion is superior to laparotomy (115) and is suitable even in pregnancy. Laparoscopic procedure for ovarian conservation is recommended to treat patients suffering from ovarian torsion owing to its shorter hospital stay, fewer postoperative complications and ovarian preservation (116). Commonly both fallopian tube and ovarian cyst are involved in the process of torsion. Few studies on isolated fallopian tube torsion have been reported (117).

C. Acute pelvic infection:

Pelvic inflammatory disease (PID) is one of the most common infections seen in nonpregnant reproductive-age women. It is a major public health problem associated with substantial medical complications (e.g., infertility, ectopic pregnancy, and chronic pelvic pain) and healthcare costs. Prevention of these long-term sequelae requires treatment strategies that are based on the microbiologic etiology of acute PID (118). Acute salpingo-oophoritis commonly causes acute pelvic and lower abdominal pain, and can mimic other surgical diagnoses. Diagnostic laparoscopy can be useful to exclude other common pathologies. If the diagnosis is correct, microbiological samples can be taken to target anti-microbial therapy, and in pyosalpinx, pus can be drained laparoscopically (119). If gynaecologic disorders are the suspected cause of pain, diagnostic laparoscopy should be performed, as frequently simultaneous therapy will be possible. Acute-phase operative

laparoscopy provides a final diagnosis and prompt management of most cases with acute PID (120).

Many of these patients will undergo exploration for suspected appendicitis, but in 20-35% of cases a normal appendix is found. Because of the limited access provided by the gridiron incision, a definitive diagnosis may not be found. Other patients may be treated conservatively and discharged. In patients with acute abdominal pain, early laparoscopy is an accurate means of both making a definitive diagnosis and proper management (121).

1.c.1 Remaining research question on hysteroscopic surgery:

Elective hysteroscopic incision of the septum in asymptomatic patients or before first pregnancy is currently not supported by the published evidence. Likewise, among women with fertility problems, further research is necessary to evaluate any benefit on live birth rates of surgical resection of a uterine septum (122). Moreover, some paramesonephric duct anomalies are not included in the current widely used American Fertility Society (AFS) Classification such as complete vaginocervicouterine septum. Future high-quality randomized trials are needed to confirm the favourable effect of standard (5 mm) office hysteroscopy in different IVF populations and examine whether newer and less invasive techniques of uterine cavity evaluation such as mini-hysteroscopy (61) or hysterocontrast sonography (62) would have an equally beneficial effect when compared with no intervention before IVF (54). The effectiveness of draining of hydrosalpinges or performing salpingostomy on improving live birth rate prior to IVF/ICSI needs further evaluation (122). So far, there is little published data available on the role of hysteroscopic tubal occlusion of hydrosalpinx prior to IVF/ICSI.

1.c.2 Remaining research questions on reconstructive gynaecologic laparoscopic surgery:

Over the last decade, major advances in laparoscopic surgery have made it possible for most gynaecologic problems to be treated via laparoscopy and there is a wide plethora of publications on laparoscopic procedures. However, a lot of the published work on laparoscopic reconstructive surgery demonstrates the feasibility of the procedure, highlights the possible advantages, and the skills of the surgeons. The question now is not whether the procedure is feasible laparoscopically, but whether the laparoscopic approach is superior and beneficial to a particular patient as well as cost effective for the community at large (123). Many of the published studies are descriptive studies or even case reports with rarity of randomized controlled trials (RCTs) comparing laparoscopic approach with conventional laparotomic approach for reconstructive gynaecologic surgery. Data on laparoscopic management of ovarian cysts represents a clear example. Ovarian cysts have long been a common indication for laparoscopic intervention (124-125). Despite being practiced in nearly all endoscopic units all over the world and the publication of hundreds of articles on this topic, nevertheless, there remains uncertainty as to the value of this intervention compared to laparotomy. Surprisingly, only six RCTs were identified involving 324 patients when comparing laparoscopy with laparotomy for treating benign ovarian tumors in a recent systematic review (126). Since reconstructive gynaecologic procedures mainly focus on fertility preservation in women in their child-bearing periods, so far infrequent studies on the fertility after reconstructive gynaecologic surgery are published. The endoscopic societies are kindly requested to define the exact role of robotic

surgery in modern practice. The heterogeneity of population and the cost effectiveness of laparoscopic approach for reconstructive surgery in different countries are not well addressed in literature. Moreover, there is insufficient evidence to support any one surgical technique for LOD over another relating to adhesion formation. There are little data on the long-term health consequences of ovarian drilling or the formation of adhesions. Further research is needed to evaluate the effect of LOD on the formation of adhesions and the long-term health consequences of this procedure (122). The impact of LOD on the subsequent ovarian hysterstimulation syndrome is poorly understood. Two studies in this thesis try to answer some of these questions. Regarding gynaecologic emergencies, a decision of laparotomy is preferred in many causality units even in tertiary centers. There is growing consensus among the gynecologists that pregnancy rate after laparotomy is accepted provided that the basic microsurgical principles are followed, but this consensus lacks evidence. The question, however, is: how should we provide proper training to all those involved in reconstructive surgery, certainly in the field of reproductive surgery? If properly trained, better outcome after laparoscopic surgery is expected. Constructing randomized studies comparing the outcomes and fertility following laparoscopic versus laparotomic approaches in gynaecologic emergencies seems to be very valuable.

1.d. Aims of this thesis:

The studies presented in this thesis were designed to investigate some areas for improvement of hysteroscopic operative procedures and to assess merits of laparoscopic surgery for fertility enhancement and preservation in reproductive medicine. The following sub questions are answered under the main aims which are:

1. Compare efficacy of intravaginal misoprostol versus endocervical laminaria tents prior to operative hysteroscopy in selected cases.
2. Determine whether hysteroscopic tubal occlusion will produce the same efficacy as laparoscopic tubal occlusion of functionless hydrosalpnix prior to IVF/ICSI.
3. Compare a modified mechanical versus traditional morcellation technique of hysteroscopic removal of big submucous myomata as regards feasibility, efficacy, operative time, and possible complications, and to assess the efficacy of preoperative sonohysterography (SHG).
4. Determine whether resectoscopic sectioning of complete uterocervicovaginal septum is as effective as cold knife excision of the longitudinal vaginal septum followed by resectoscopic cutting of the cervicouterine septum in symptomatic patients.
5. Assess the impact of LOD on ovarian and metabolic parameters in women with PCO.
6. Determine the prevalence extent, and location of adhesion formation following microsurgical monopolar LOD among fertile and infertile women with clomiphene resistant PCO.

7. Estimate pregnancy rate after surgical treatment of ectopic pregnancy (EP), adnexal torsion, ruptured ovarian cyst and acute pelvic inflammatory disease (PID) within 1 year of operative laparoscopy when compared to laparotomy and to define different factors that would affect this pregnancy rate in women desiring fertility.

1.e. References

1. Fayez JA, Dempsey RA. Short hospital stay for gynaecologic reconstructive surgery via laparotomy. Obstet Gynaecol 1993;81:598-600.
2. Miklos, JR. Laparoscopic Repair of Vesicouterine Fistula. J Am Assoc Gyn Laparosc 1999;6(3):339-341.
3. Peacock LM, Rock JA. Distal tubal reconstructive surgery. In. Sanfilippo JS, Levine RL. Operative Gynaecologic Endoscopy. 2nd edition. New York, Springer Verlag Inc., 1996, Chapter 2.
4. Friedman RM, Gyemishi I, Robinson JB, Rohrich RJ. Saline made viscous with polyethylene glycol: a new alternative breast implant filler material. Plastic and Reconstructive Surgery1996; 98: 1208.
5. Marcickiewicz J, Brannstrom M. Fertility preserving surgical treatment of borderline ovarian tumour: long-term consequence for fertility and recurrence. Acta Obstet Gynaecol Scand. 2006;85(12):1496-500.
6. Paraiso MF, Chen CC. Laparoscopic surgery for pelvic organ prolapse. Minerva Ginecol. 2006;58(5):381-91.
7. Varadarajulu S, Tamhane A, Drelichman ER. Patient perception of natural orifice transluminal endoscopic surgery as a technique for cholecystectomy. Gastrointest Endosc. 2008 May;67(6):854-60.
8. Wéber G, Hossein B, Ferencz A. .Natural orifice transluminal endoscopic surgery. Magy Seb. 2007;60(6):277-83.
9. Semm K: Tissue puncher and loop ligation: new side for surgical-therapeutic pelviscopy (laparoscopy). Endoscopy 1978;10:119-124.

10. Bruhat MA, Manhes H, Mage G, Pouly JL: Treatment of ectopic pregnancy by means of laparoscopy. Fertil Steril 1980; 33:411-414.
11. Daniell JF, Brown DH: Carbon dioxide laser laparoscopy: critical experience in animals and humans. Obstet Gynaecol 1982; 59:761-764.
12. Reich H, McGlynn F: Treatment of ovarian endometriosis using laparoscopic surgical techniques. J Reprod Med 1986, 31:577-584.
13. Reich H, McGlynn F: Treatment of ovarian endometriosis using laparoscopic surgical techniques. J Reprod Med 1986, 31:577-584.Gynaecologic Laparoscopy. Principles and Techniques. 2nd edition, NewYork ,McGraw Hill., 2000,Ch 9.
14. Papp A, Vereczkei , Lantos J, Horváth OP. The effect of different levels of peritoneal CO 2 pressure on bleeding time of spleen capsule injury. Surgical Endoscopy 2003; 17(7);1125-1128.
15. Diamond, M.P. and Schwartz, L.B. (1998) Prevention adhesion development. In Sutton, C. and Diamond, M.P. (eds), Endoscopic Surgery for Gynaecologists , 2nd edn. Philadelphia, W.B.Saunders, pp. 398–403.
16. Garry R. Laparoscopic surgery. Best Pract Res Clin Obstet Gynaecol. 2006; 20(1):89-104.
17. Harkki-Siren P, Sjoberg J, Kurki T. Major complications of laparoscopy: a follow-up Finnish study. Obstet Gynecol. 1999;94:94-98.
18. Chapron C, Querleu D, Bruhat MA, et al. Surgical complications of diagnostic and operative gynaecological laparoscopy: a series of 29,966 cases. Hum Reprod. 1998;13:867-872.

19. Jansen FW, Kapiteyn K, Trimbos-Kemper T, Hermans J, Trimbos JB. Complications of laparoscopy: a prosepctive multicentre observational study. Br J Obstet Gynaecol. 1997;104:595-600.
20. Jansen FW, Kolkman W, Bakkum EA, de Kroon CD, Trimbos-Kemper TC, Trimbos JB. Complications of laparoscopy: an inquiry about closed- versus open-entry technique.Am J Obstet Gynecol. 2004;190(3):634-8.
21. Vilos GA, Ternamian A, Dempster J, Laberge PY, The Society of Obstetricians and Gynaecologists of Canada. Laparoscopic entry: a review of techniques, technologies, and complications. J Obstet Gynaecol Can. 2007 May;29(5):433-65.
22. Cohen SM, Singer AJ. Preventing complications before the operation. In. Complications of Gynaecologic Endoscopic Surgery. Isaacson K Philadelphia, Saunders Elsevier. 2006,Ch 3.
23. Wiedermann R, Hepp H. Selection of patients for IVF therapy or alternative therapy methods. Hum Rep 1989.;4:23-27.
24. Watson A, Vandekerckhove P, Lilford R. Techiques for pelvic surgery in subfertility. Cochrane Database Syst Rev 2:CD00022, 2000.
25. Ahmad G, Watson A, Vandekerckhove P, Lilford R. Techniques for pelvic surgery in subfertility.Cochrane Database Syst Rev. 2006 Apr 19;(2):CD000221.
26. Sauer MV. Tubal infertility. The role of reconstructive surgery. In. Lobo RA, Mishell DR, Paulson RJ, Shoupe D. Infertility, Contraception and Reproductive Endocrinology. Boston, Blackwell Scientific Publications, 4th edition, 1997,Ch 36.
27. Bateman BG, Nunley JW, Kitchen JD. Surgical management of distal tubal occlusion-are we making progress?. Fertil Steril 1987;48;523.

28. Gomel V, Taylor PJ (Ed). Fertility-promoting procedures and assisted reproductive technology. In. Diagnostic and Operative Gynaecologic Laparoscopy. St Louis, Mosby-Year Book, Inc., 1995,Ch 15.
29. Koh CH. Anastomosis of the fallopian tube. In. Tulandi T. Atlas of Laparoscopic and Hysteroscopic Techniques for gynaecologists. 2nd edition, London, W.B. Saunders, 1999. Ch 7.
30. Nezhat FR, Shama Datta M, Liu C, Chunag L, Zakashansky K. Robotic radical hysterectomy versus total laparoscopic radical hysterectomy with pelvic lymphadenectomy for treatment of early cervical cancer. JSLS 2008;12:227-237.
31. Ballantyne GH. Robotic surgery, telerobotic surgery, telepresence, and telementoring. Surg Endosc 2002;16:1389–402.
32. Diaz-Arrastia C, Jurnalov C, Gomez G, Townsend Jr. Laproscopic hysterectomy using a computer enhanced surgical robot. Surg Endosc 2002;16:1271-1273.
33. Advincula A.P, Falcone T, Laparoscopic robotic gynecologic surgery. Obstet Gynecol Clin N Am 2004;31:599– 609.
34. Whitelaw N. Hysteroscopic metroplasty. In. Endoscopic surgery for gynaecologists. Ed by Sutton C and Diamond MP. W.B. Saunders Co Ltd., London, 1993, Ch 37, pp291-293.
35. Homer HA, Li TC, Cooke ID. The septate uterus: a review of management and reproductive outcome. Fertil Steril. 2000 ;73(1):1-14.
36. Pabuçcu R, Gomel V. Reproductive outcome after hysteroscopic metroplasty in women with septate uterus and otherwise unexplained infertility. Fertil Steril. 2004;81(6):1675-8.

37. Heinonen PK. Reproductive performance of women with uterine anomalies after abdominal or hysteroscopic metroplasty or no surgical treatment. J Am Assoc Gynecol Laparosc 1997;4:311–7.

38. Grimbizis G, Camus M, Clasen K, Tournaye H, De Munck L, Devroey P. Hysteroscopic septum resection in patients with recurrent abortions or infertility. Hum Reprod 1998;13:1188–93.

39. Malik E, Berg C, Sterzik K, Stoz F, Rossmanith WG. Reproductive outcome of 32 patients with primary or secondary infertility and uterine pathology. Arch Gynecol Obstet 2000;264:24–6.

40. Heinonen PK. Complete septate uterus with longitudinal vaginal septum. Fertil Steril. 2006;85(3):700-5.

41. Patton PE, Novy MJ, Lee DM, Hickok LR. The diagnosis and reproductive outcome after surgical treatment of the complete septate uterus, duplicated cervix and vaginal septum. Am J Obstet Gynecol. 2004;190(6):1669-75.

42. Buttram VC Jr, Reiter RC. Uterine leiomyomata: etiology, symptomatology, and management. Fertil Steril 1981;36:433–45.

43. Verkauf BS. Myomectomy for fertility enhancement and preservation. Fertil Steril 1992;58:1–15.

44. Wamsteker K, Emanuel MH, de Kruif JH. Transcervical hysteroscopic resection of submucous fibroids for abnormal uterine bleeding: results regarding the degree of intramural extension. Obstet Gynecol. 1993 Nov;82(5):736-40.

45. Pritts EA. Fibroids and infertility: a systematic review of the evidence. Obstet Gynecol Surv 2001;56:483–91.

46. Varasteh NN, Neuwirth RS, Brucelevin, Keltz MD. Pregnancy Rates After Hysteroscopic Polypectomy and Myomectomy in Infertile Women. Obstetrics & Gynecology 1999;94:168-171
47. McLucas B: Intrauterine applications of the resectoscope. Sur Gynecol Obstet 1991; 172(6):425-430.
48. Sardo AD, Mazzon I, Bramante S, Bettocchi S, Bifulco G,Guida M, Nappi C Hysteroscopic myomectomy: a comprehensive review of surgical techniques. Human Reproduction Update 2008; 14(2):101-119
49. Pasini A, Belloni C: Intraoperative complications of 697 consecutive operative hysteroscopies. Minerva Ginecol 2001;53(1):13-20.
50. Hamou J: Electroresection of fibroids. In Endoscopic Surgery for Gynaecologists. Ed by Sutton C and Diamond M. London. Sauhders Co LTD, 1993, Ch41.
51. Margalioth EJ, Ben Chetrit A, Gal M, Eldar Geva T. Investigation and treatment of repeated implantation failure following IVF-ET. Human Reproduction *2006;*21, 3036–3043.
52. Urman B, Yakin K, Balaban B. Recurrent implantation failure in assisted reproduction: how to counsel and manage. A. General considerations and treatment options that may benefit the couple. Reproductive BioMedicine Online 2005; 11, 371–381.
53. De Sutter P. Rational diagnosis and treatment in infertility. Best Practice and Research in Clinical Obstetrics and Gynaecology 2006; 20, 647–664.
54. Tarek El-Toukhy, Sesh Kamal Sunkara, Arri Coomarasamy, Jan Grace, Yakoub Khalaf. Outpatient hysteroscopy and subsequent IVF cycle outcome: a systematic review and meta-analysis. Reprod Biomed Online. 2008;16 (5):712-9.

55. Sharkey A. Cytokines and implantation. Reviews of Reproduction 1998; 3, 52–61.

56. Basak S, Dubanchet S, Zourbas S. Expression of proinflammatory cytokines in mouse blastocysts during implantation: modulation by steroids hormones. American Journal of Reproductive Immunology2002; 47, 2–11.

57. Raziel A, Schachter M, Strassburger D. Favourable influence of local injury to the endometrium in intracytoplasmic sperm injection patients with high-order implantation failure. Fertility and Sterility 2007*;* 87, 198–201.

58. Lea RG, Sandra O. Immunoendocrine aspects of endometrial function and implantation. Reproduction 2007; 134, 389–404.

59. La Sala, G.B., Montanari, R., Dessanti, L, Cigarini C, Sartori F. The role of diagnostic hysteroscopy and endometrial biopsy in Assisted Reproductive Technologies. Fertil. Steril. 1998; 70, 378–380.

60. Rama Raju GA, Shashi Kumari G, Krishna KM, Prakash GJ, Madan K. Assessment of uterine cavity by hysteroscopy in assisted reproduction programme and its influence on pregnancy outcome. Arch Gynecol Obstet. 2006;274(3):160-4.

61. De Placido G, Clarizia R, Cadente C. Compliance and diagnostic efficacy of mini-hysteroscopy versus traditional hysteroscopy in infertility investigation. European Journal of Obstetrics and Gynecology and Reproductive Biology 2007; 135, 83–87.

62. Tur-Kaspa I, Gal M, Hartman M. A prospective evaluation of uterine abnormalities by saline infusion sonohysterography in 1,009 women with infertility or abnormal uterine bleeding. Fertil Steril 2006; 86, 1731–1735.

63. Di Spiezio Sardo A, Guida M, Bettocchi S, Nappi L, Sorrentino F, Bifulco G, Nappi C. Role of hysteroscopy in evaluating chronic pelvic pain. Fertil Steril. 2008 ;90(4):1191-6.

64. Molinas CR, Campo R. Office hysteroscopy and adenomyosis. Best Pract Res Clin Obstet Gynaecol. 2006 Aug;20(4):557-67.

65. Ahinko-Hakamaa K, Huhtala H, Tinkanen H. The validity of air and saline hysterosalpingo-contrast sonography in tubal patency investigation before insemination treatment. European Journal of Obstetrics and Gynecology and Reproductive Biology 2007; 132, 83–87.

66. Strandell A. The influence of hydrosalpinx on IVF and embryo transfer: a review. Hum Reprod Update 2000;6:387–95.

67. Nackley, A.C. and Muasher, S.H. The significance of hydrosalpinx in in vitro fertilisation. Fertil Steril 1998; 69, 373–384.

68. Camus E, Poncelet C, Goffinet F, Wainer B, Merlet F, Nisand I, et al. Pregnancy rates after in-vitro fertilization in cases of tubal infertility with and without hydrosalpinx: a meta-analysis of published comparative studies. Hum Reprod 1999;14:1243–9.

69. Strandell A, Waldenstrom U, Nilsson L, Hamberger L. Hydrosalpinx reduces in-vitro fertilization/embryo transfer pregnancy rates. Hum Reprod 1994;9:861–3.

70. Urman B, Yakin K.Ovulatory disorders and infertility. J Reprod Med. 2006;51(4):267-82.

71. Farquhar C, Vandekerckhove P, Arnot M, Lilford R. Laparoscopic “drilling” by diathermy or laser for ovulation induction in anovulatory polycystic ovary syndrome. Cochrane Database Syst Rev 2000 ;(2):CD001122.

72. Unlu C, Atabekoglu CS. Surgical treatment in polycystic ovary syndrome. Curr Opin Obstet Gynecol. 2006;18(3):286-92.

73. Weerakiet S, Lertvikool S, Tingthanatikul Y, Wansumrith S, Leelaphiwat S, Jultanmas R. Ovarian reserve in women with polycystic ovary syndrome who underwent laparoscopic ovarian drilling. Gynecol Endocrinol. 2007;2;1-6

74. Hayashi H, Ezaki K, Endo H, Urashima M. Preoperative luteinizing hormone levels predict the ovulatory response to laparoscopic ovarian drilling in patients with clomiphene citrate-resistant polycystic ovary syndrome. Gynecol Endocrinol. 2005;21(6):307-11.

75. El Saeed M, Ezzat R, Hasan M, Elhelw B, Aboulmaaty Z, Aboulghar M. High incidence of pelvic adhesions detected by second look laparoscopy after laparoscopic ovarian drilling. Middle East Fertility Society Journal 2000;5:519–25.

76. Amer SAK, Li TC, Cooke ID. Laparoscopic ovarian diathermy in women with polycystic ovarian syndrome: a retrospective study on the influence of the amount of energy used on the outcome. Hum Reprod 2002; 17:1046–51.

77. Malkawi HY, Qublan HS. Laparoscopic ovarian drilling in the treatment of polycystic ovary syndrome: how many punctures per ovary are needed to improve the reproductive outcome?. J Obstet Gynaecol Res. 2005;31(2):115-9.

78. Tabrizi NM, Mohammad K, Dabirashrafi H, Nia FI, Salehi P, Dabirashrafi B, Shams S. Comparison of 5-, 10-, and 15-point laparoscopic ovarian electrocauterization in patients with polycystic ovarian disease: a prospective, randomized study. JSLS. 2005;9(4):439-41.

79. Youssef H, Atallah MM. Unilateral ovarian drilling in polycystic ovarian syndrome: a prospective randomized study. Reprod Biomed Online. 2007;15(4):457-62.

80. Muenstermann U. Long-term GnRH analogue treatment is equivalent to laparoscopic laser diathermy in polycystic ovarian syndrome patients with severe ovarian dysfunction. Hum Reprod 2000; 15:2526–30.

81. Marianowski P, Kaminski P, Wielgos M, Szymusik I. The changes of hormonal serum levels and ovulation/pregnancy rates after ovarian electrocautery in microlaparoscopy and laparoscopy in patients with PCOS. Neuro Endocrinol Lett. 2006;27(1-2):214-8.

82. Taskin O, Sadik S, Onoglu A, Gokdeniz R, Yilmaz I, Burak F, Wheeler J. Adhesion formation after microlaparoscopic and laparoscopic ovarian coagulation for polycystic ovary disease. The Journal of the American Association of Gynecologic Laparoscopists 1999; 6, 2,159-163.

83. Fernandez H, Alby JD, Gervaise A, de Tayrac R, Frydman ROperative transvaginal hydrolaparoscopy for treatment of polycystic ovary syndrome: a new minimally invasive surgery. Fertil Steril. 2001;75(3):607-11.

84. Ferraretti AP, Gianaroli L, Magli MC, Iammarrone E, Feliciani E, Fortini D. Transvaginal ovarian drilling: a new surgical treatment for improving the clinical outcome of assisted reproductive technologies in patients with polycystic ovary syndrome. Fertil Steril. 2001;76(4):812-6.

85. Gordts S, Gordts S, Puttemans P, Valkenburg M, Campo R, Brosens I. Transvaginal hydrolaparoscopy in the treatment of polycystic ovary syndrome. Fertil Steril. 2008 Aug 16. Online.

86. Daraï E, Rouzier R, Ballester M. Transvaginal hydrolaparoscopy: practices in French teaching hospitals. J Minim Invasive Gynecol. 2008 May-Jun;15(3):273-6.
87. Taylor EW, Kennedy CA, Dunham RH, Bloch JH: Diagnostic laparoscopy in women with acute abdominal pain. Surg Laparosc Endosc 1995; 5(2):125-128.
88. Sallam HN, Garcia-Velasco JA, Dias S, Arici A. Long-term pituitary down-regulation before in vitro fertilization (IVF) for women with endometriosis. Cochrane Database Syst Rev. 2006 25;(1):CD004635.
89. Ma C, Qiao J, Liu P, Chen G. Ovarian suppression treatment prior to in-vitro fertilization and embryo transfer in Chinese women with stage III or IV endometriosis. Int J Gynaecol Obstet. 2008;100(2):167-70.
90. Gray DT, Thorburn J, Lundorff P, Strandell A, Lindblom B: A cost-effectiveness study of a randomised trial of laparoscopy versus laparotomy for ectopic pregnancy. Lancet 1995; 345(8958):1139-1143.
91. Shapiro HI, Adler DH. Excision of an ectopic pregnancy through the laparoscope. Am J Obstet Gynaecol 1973; 117: 290-291.
92. Lundorff P, Thorburn J, Lindblom B: Fertility outcome after conservative surgical treatment of ectopic pregnancy evaluated in a randomized trial. Fertil Steril 1992; 57(5):998-1002.
93. Lundorff P, Thorburn J, Hahlin M, Kallfelt B, Lindblom B: Laparoscopic surgery in ectopic pregnancy. A randomized trial versus laparotomy. Acta Obstet Gynaecol Scand 1991; 70(4-5):343-348.
94. Pouly JL, Mahnes H, Mage G, Canis M, Bruhat MA. Conservative laparoscopic treatment of 321 ectopic pregnancies. Fertil Steril 1986; 46: 1093-7.

95. Vermesh M, Presser SC. Reproductive outcome after linear salpingostomy for ectopic gestation: a prospective 3-year follow-up. Fertil Steril 1992; 57: 682-4.

96. Sultana CJ, Easley K, Collins RL. Outcome of laparoscopic versus traditional surgery for ectopic pregnancies. Fertil Steril 1992; 57:285-9.

97. Yao M, Tulandi T. Current status of surgical and nonsurgical management of ectopic pregnancy. Fertil Steril 1997; 67:421-33.

98. Silva PD, Schaper AM, Rooney B. Reproductive outcome after 143 laparoscopic procedures for ectopic pregnancy. Obstet Gynaecol 1993; 81:710-5.

99. Dubuisson JB, Morice P, Chapron C, De-Gayffier A Mouelhi T. Salpingectomy - the laparoscopic surgical choice for ectopic pregnancy. Hum Reprod 1996; 11(6):1199-203.

100. Vermesh M, Silva PD, Rosen GF, Stein AL, Fossum GT, Sauer MV: Management of unruptured ectopic gestation by linear salpingostomy: a prospective, randomized clinical trial of laparoscopy versus laparotomy. Obstet Gynaecol 1989; 73(3 Pt 1):400-404.

101. Brumsted J, Kessler C, Gibson C, Nakajima S, Riddick DH, Gibson M. A comparison of laparoscopy and laparotomy for the treatment of ectopic pregnancy. Obstet Gynaecol 1988; 71:889-92.

102. Baumann R, Magos A, Turnbull A. Prospective comparison of videopelviscopy with laparotomy for ectopic pregnancy. Br J Obstet Gynaecol 1991; 98:765-771.

103. Murphy AA, Nager CW, Wujek JJ, Kettel LM, Torp VA, Chin HG. Operative laparoscopy versus laparotomy for the management of ectopic pregnancy: a prospective trial. Fertil Steril 1992; 57:1180-5.

104. Warren O, Kinross J, Paraskeva P, Darzi A. Emergency laparoscopy – current best practice. World Journal of Emergency Surgery 2006, 1:24.

105. Cheong Y, Li TC. Controversies in the management of ectopic pregnancy. Reprod Biomed Online. 2007;15(4):396-402.

106. Vaissade L, Gerbaud L, Pouly JL, Job-Spira N, Bouyer J, Coste J, Glanddier PY. Cost-effectiveness analysis of laparoscopic surgery versus methotrexate: comparison of data recorded in an ectopic pregnancy registry. J Gynecol Obstet Biol Reprod (Paris). 2003;32(5):447-58.

107. Luciano AA, Roy G, Solima E. Ectopic pregnancy from surgical emergency to medical management. Ann N Y Acad Sci. 2001;943:235-54.

108. Nieuwkerk PT, Hajenius PJ, Van der Veen F, Ankum WM, Wijker W, Bossuyt PM. Systemic methotrexate therapy versus laparoscopic salpingostomy in tubal pregnancy. Part II. Patient preferences for systemic methotrexate. Fertil Steril 1998;70(3):518-22.

109. Nieuwkerk PT, Hajenius PJ, Ankum WM, Van der Veen F, Wijker W, Bossuyt PM Systemic methotrexate therapy versus laparoscopic salpingostomy in patients with tubal pregnancy. Part I. Impact on patients' health-related quality of life. Fertil Steril 1998;70(3):511-517.

110. Bottomley C, Bourne T.Diagnosis and management of ovarian cyst accidents. Best Pract Res Clin Obstet Gynaecol. 2009 Mar 17.

111. Kostov M, Mijović Z, Mihailović D. Giant paraovarian cyst in a child complicated with torsion. Vojnosanit Pregl. 2008 Nov;65(11):843-6.

112. Sauerland S, Agresta F, Bergamaschi R, Borzellino G, Budzynski A, Champault G, Fingerhut A, Isla A, Johansson M, Lundorff P, Navez B, Saad S,

Neugebauer EA: Laparoscopy for abdominal emergencies: evidence-based guidelines of the European Association for Endoscopic Surgery. Surg Endosc 2006; 20(1):14-29.

113. Rha SE, Byun JY, Jung SE, Jung JI, Choi BG,Kim BS, Hyun Kim H, Lee JM. CT and MR Imaging Features of Adnexal Torsion. Radiographics. 2002;22:283-294.

114. Mais V, Ajossa S, Piras B, Marongiu D, Guerriero S, Melis GB: Treatment of nonendometriotic benign adnexal cysts: a randomized comparison of laparoscopy and laparotomy. Obstet Gynaecol 1995; 86(5):770-774.

115. Yuen PM, Yu KM, Yip SK, Lau WC, Rogers MS, Chang A: A randomized prospective study of laparoscopy and laparotomy in the management of benign ovarian masses. Am J Obstet Gynaecol 1997; 177(1):109-114.

116. Lo LM, Chang SD, Horng SG, Yang TY, Lee CL, Liang CC. Laparoscopy versus laparotomy for surgical intervention of ovarian torsion. J Obstet Gynaecol Res. 2008 Dec;34(6):1020-5.

117. Phillips K, Fino ME, Kump L, Berkeley A. Chronic isolated fallopian tube torsion. Fertil Steril. 2009 Mar 31, on line.

118. Sweet RL. Treatment strategies for pelvic inflammatory disease. Expert Opin Pharmacother. 2009;10(5):823-37.

119. Teisala K, Heinonen PK, Punnonen R: Laparoscopic diagnosis and treatment of acute pyosalpinx. J Reprod Med 1990; 35(1):19-21.

120. Molander P, Cacciatore B, Sjöberg J, Paavonen J. Laparoscopic management of suspected acute pelvic inflammatory disease. J Minimally Invasive Surgery 2000; 7, 1,107-110.

121. Golash V, Willson PD. Early laparoscopy as a routine procedure in the management of acute abdominal pain: a review of 1,320 patients. Surg Endosc. 2005;19(7):882-5.

122. National Collaborating Centre for Women's and Children's Health. Fertility assessment and treatment for people with fertility problems. RCOG Press. London, 2004, Ch 7,8,9.

123. Chew S, L C F. An assessment of present day laparoscopic surgery in Gynaecology. Singapore Journal of Obstetrics and Gynaecology 2001;32(1): 1-13.

124. Hasson H. Laparoscopic management of ovarian cysts. J Rep Med 1990;35(9):863-867.

125. Peterson H, Hulka J, Phillips J. American Association of Gynaecologic Lparoscopists: Membership Survey on Operative Laparoscopy. J Rep Med 1990;35;587-589.

126. Medeiros LR, Fachel JM, Garry R, Stein AT, Furness S. Laparoscopy versus laparotomy for benign ovarian tumours. Cochrane Database Syst Rev. 2005 20;(3):CD004751.

Section 2. Materials and methods

2.a. Hysteroscopic reconstructive surgery

2.a.1 Hum Reprod 2004;19:2391-2394

A.M. Darwish, A.M. Ahmad and A.M. Mohammad Cervical priming prior to operative hysteroscopy: a randomized comparison of laminaria versus misoprostol Human Reproduction 2004;19(10):2391-2394.

2.a.2. Acta Obst. Gyn. Scand 2007 86,12,1484

Atef M. Darwish, Ali M. ElSaman. Is there a role for hysteroscopic tubal occlusion of functionless hydrosalpinges prior to IVF/ICSI in modern practice? Acta Obstetricia et Gynecologica Scandinavica 2007; 86,12, 1484 – 1489.

2.a.3. Gyn Obstet Invest 2003;56:192-6

Darwish A. Modified hysteroscopic myomectomy of large submucous fibroids. Gynaecol Obstet Invest. 2003;56(4):192-6.

2.a.4. Fertility Sterility, 2008, Online, 8 Aug.

Atef M. Darwish, Ali M. ElSaman. Extended resectoscopic versus sequentional cold knife-resectoscopic excision of the unclassified complete uterocervicovaginal septum: a randomized trial. Fertility Sterility, 2008, 8 Aug,Online.

2.a.1 Cervical priming prior to operative hysteroscopy: a randomized comparison of laminaria versus misoprostol

A.M.Darwish, A.M.Ahmad and A.M.Mohammad

Human Reproduction 2004; Vol.19, No.10 pp. 2391–2394

Introduction

Operative hysteroscopy has gained popularity as a minimally invasive approach to intrauterine lesions (Siegler and Valle, 1988). Cervical dilatation represents a real challenge during operative hysteroscopy, particularly in nulligravidae, postmenopausal women and women with cervical stenosis. Furthermore, some lengthy hysteroscopic operations such as myomectomy require adequate cervical dilatation to facilitate repeated insertions and withdrawals of the resectoscope. Another technical problem is the need for a considerable degree of cervical dilatation as well as softening to allow complete extraction of the excised endouterine lesions. Misoprostol is a prostaglandin E1 analogue which is commonly mused in obstetrics for induction of abortion and labour as well as postpartum to control vaginal bleeding (Bugalho et al., 1994). Its utilization in gynaecology has been limited. It was recently used prior to artificial insemination and operative hysteroscopy. Vaginal misoprostol applied before operative hysteroscopy has reduced the need for cervical dilatation, facilitated hysteroscopic surgery and minimized cervical complications (Preutthipan and Herabutya, 1999). On the other hand, laminaria tents, made from the stems of Laminaria japomica or Laminaria digitata (brown sea weed), are attractive natural substances that can cause cervical dilatation with minimal local and no systemic side-effects. They have been shown to be effective in inducing cervical priming prior to operative hysteroscopy (Ostrzenski, 1994). However, there have been no comparative studies of the efficacy of the two methods for cervical priming (Sowter et al., 2003). The aim of this work was to compare efficacy of intravaginal misoprostol versus endocervical laminaria tents prior to operative hysteroscopy in selected cases.

Materials and methods

This study was carried out at the Gynecologic Endoscopy Unit, Assiut University Hospital from February 2002 to July 2003. It was approved by the Medical Ethics Committee of the Faculty of Medicine. All patients gave a written consent. The study comprised 144 patients recruited from the Gynaecology, Infertility, and Family Planning Clinics with different indications for operative hysteroscopy (Table II). Inclusion criteria included nulliparous or multiparous women with primary or secondary cervical stenosis (defined as a difficult or failed cervical sounding in the office) who were scheduled for operative hysteroscopy. Selected cases had a full history, thorough general and pelvic examinations, and transvaginal ultrasonography to determine the nature, site and extent of intrauterine lesions. Patients were randomly divided into two groups. Group A (72 cases) received 200mg misoprostol (Misotac; Sigma Co., Egypt) into the posterior fornix 8 h prior to surgery. Patients in group B (72 cases) received a single laminaria (Med Gyn Products, Inc., USA) as fine as 2mm inserted into the cervical canal. The patient was put in the dorsal lithotomy position, where a sterile Cusco's speculum was applied and the cervix was sterilized using Bovidone iodine solution. The laminaria was removed aseptically from its package and grasped from its proximal end where the string is attached using Ring forceps. It was inserted into the cervical canal until it passed theinternal os with the string resting in the vaginal vault for easy removal. In the operating room, the degree of initial cervical dilatation was assessed by introducing Hegar dilators under general anaesthesia. It was defined as the maximal calibre dilator that passed without resistance in a descending order, starting with the largest size dilator. The duration of subsequent cervical dilatation until reaching 10 mm, and feasibility of the procedure, were recorded. Cervical canal dilatation complications (false passage or perforation) were reported. At the end of the procedure, we

recorded doctor assessment in the form of feasibility of the hysteroscopic operation, and patient impression in the form of insertion difficulties, convenience and fear of either method. All operations were done by only three members of the Endoscopic Unit with a comparable level of experience. Sample size estimation was adequate to detect a difference of 3.2mm (type I error of 0.01) with a power of 0.99. As a result, 144 cases were included in this study. Randomization was done by means of sealed envelopes. It was a double-blind randomization study in that the evaluator (first author) masked the key from the researcher (third author) to avoid bias. Collected data were revised and coded for computerized data entry. A data entry file was created on EPI Info version 9. After complete data entry, the file was converted to an SPSS file. Analysis was undertaken using SPSS version11 and expressed as mean ± SD. Statistical methods were applied including descriptive statistics (frequency, percentage, mean and SD) and tests of significance (two-tailed Student's t-test, analysis of variance (ANOVA) and x2). $P \leq 0.05$ was considered statistically significant.

Results

One hundred and forty-four patients who fulfilled the inclusion criteria were randomized. There was no statistically significant difference between the groups for age and parity (Table I), indications (Table II), and type of surgery (Table III) of operative hysteroscopy. Primary or secondary infertility were the main indications in 38 (52.8%) and 38 (52.71%) patients in both groups respectively due to a suspected intrauterine cause as diagnosed by transvaginal scan (TVS) or hysterosalpingography (HSG). Technical details and disadvantages of both methods of cervical priming are demonstrated in Tables IV and V. Even when inerstion of the laminaria was reported as difficult, it was achieved without causing perforation in all cases of group B. Two cases of cervical perforation in group A

were treated conservatively. Doctor and patient's comments on the method of priming are reported in Table VI.

Discussion

One of the major problems of hysterosocpic surgery is difficulty in entering the internal cervical os with the outer sheath of the operative hysteroscope or the resectoscope. Traditional cervical dilatation using Hegar's dilators may not be feasible in some patients with very tight cervix or cervical abnormalities regardless of the parity of the patient. That is why we included a heterogeneous group of patients with respect to parity. However, all patients had difficult or failed sounding, with no significant difference between both groups. In a previous study, three cases of uterine perforation had occurred during endometrial ablation, where difficulty in cervical dilatation was the predisposing factor in one case (Itzkowic and Beale, 1999). In a large sample size study of 800 hysteroscopic endometrial ablations (Vilos et al., 1996), the overall complication rate was 3.9%. Cervical trauma and uterine perforation were the most common complications. Obviously, cervical priming would have a central role in facilitating the procedure. Trials of cervical priming started as early as 1985 where intracervical sulprostone gel was applied before diagnostic hysteroscopy which led to a significant reduction in the force required to dilate the cervix (Rath et al., 1985). Likewise, the vaginal use of metenoprost potassium before outpatient hysteroscopy in infertile patients provided sufficient dilatation of the cervical canal to permit the insertion of a hysteroscope without additional mechanical dilatation (Hald et al., 1988). Oral misoprostol was compared with placebo for cervical priming before diagnostic hysteroscopy (Ngai et al., 1997) with a significant reduction in the amount of force required to dilate the cervix to 8mm (40.1 compared with 103.7 newtons, P, 0.001). The mean baseline cervical dilatation was significantly greater in the misoprostol group (6.0

compared with 3.3 mm, P, 0.001). However, it produced a non-significant beneficial effect in post-menopausal women whether given orally (Ngai et al., 2001) or vaginally (Fung et al., 2002). In practical terms, those patients obtain a definite benefit from cervical priming using misoprostol, which causes cervical softening (Wing and Paul, 1996). In this study, we included nine post-menopausal women who had successful cervical priming. In a recent study (Thomas et al., 2002), misoprostol demonstrated a benefit compared with placebo in the ease of cervical dilatation in premenopausal and post-menopausal women and in those pretreated with a GnRH analogue. A randomized double-blind study comparing the effectiveness of vaginal misoprostol versus placebo for cervical dilatation found that the baseline cervical dilatation was significantly greater with shorter duration of dilatation in the treatment group (Preutthipan and Herabutya, 1999). Laminaria is a sea-grown plant that swells in the presence of liquid. It has been found to provide a fast and adequate cervical dilatation prior to transcervical removal of submucous leiomyoma (Townsend and Melkonian, 1990) and to reduce significantly the frequency of inadequate cervical dilatation before resectoscopic surgery (Ostrzenski, 1994). Laminaria was evaluated in 300 patients before diagnostic or operative hysteroscopy (Townsend and Melkonian, 1990). A 5mm diagnostic hysteroscopy was performed 2–3 h after insertion, while a 9mm operative resectoscope was inserted ,24 h after insertion of the laminaria tent. There were no complications with the use of laminaria tents such as infection or bleeding, but some patients complained of mild menstrual-like lower abdominal discomfort. In all cases, laminaria resulted in softening and dilatation of the cervix, which facilitated the passage of the diagnostic and operative hysteroscopes. In this study, we reported 26 cases of insertion difficulties, explaining a highly significant patient inconvenience with insertion of laminaria (Table V). To determine its efficacy, laminaria were used prior to hysteroscopic

adhesiolysis of severe intrauterine synechiae in seven patients with secondary amenorrhoea due to severe uterine synechiae diagnosed by HSG and hysteroscopy (Chen et al., 1997). The uterine cavity appeared short, narrow and scarred coned or column-shaped. Not only did the women achieve normal menstruation, but also a normal uterine cavity as confirmed by subsequent HSG or hysteroscopy. In addition, three patients became pregnant, two of whom have had successful term deliveries. Misoprostol is a chemical method with a systemic absorption of the drug whereas laminaria tents act by a mechanical dilatation. We did not find any randomized comparative studies of the two methods of cervical priming. In this study, we found that both were effective in dilating the cervix with a mean cervical width of 7.6 ± 1.2 and 7.5 ± 1.2mm respectively. There was no significant difference between laminaria and misoprostol with regard to the mean cervical width or the time required for cervical dilatation. In contrast, there was a significant difference between laminaria and misoprostol with regard to insertion difficulty and doctors' and patients' satisfaction with the procedure. The time required for cervical dilation up to Hegar 10 was longer in both groups (51.6 s for misoprostol and 51.4 s for laminaria) compared to previous studies (Ostrzenski, 1994; Preutthipan and Herabutya, 1999). This may be due to inter-observer variability as we included all cases done by three hysteroscopists in the Unit. A significant difference in cervical injury between misoprostol and placebo was found in a previous study (Preutthipan and Herabutya, 1999). They reported one (1.4%) cervical tear in the treated group compared with nine patients (11.4%, P ¼ 0.018) in the control group, seven of whom required suturing. Recently, three cases of extensive cervical laceration that lead to inability to perform hysteroscopy and two cases of retroperitoneal installation of the distending media due to lateral cervical laceration were reported in one study (Ghazizadeh, 2003). In our study, two cases of cervical perforation occurred during myomectomy in the

misoprostol group, while no case of perforation was encountered in the laminaria group. From this study, it is concluded that both laminaria and misoprostol were shown to be effective in inducing adequate cervical priming prior to operative hysteroscopy with minimal time of cervical dilatation. Nevertheless, misoprostol is superior as it has the following advantages: easy application (it can be inserted by the patient herself at home), cheaper price (one tablet costs $0.2 versus $5 for each laminaria piece), more economic (eliminates the charge of insertion in the office or the hospital), patient convenience (saves time and the expense of attending clinics or hospital for insertion without requiring time off work), and greater acceptability. More studies are needed to compare misoprostol and laminaria with placebo before recommending routine cervical priming prior to operative hysteroscopy in selected cases. Furthermore, the need for sequential applications of laminaria of increasing diameters rather than a single application requires further study.

Table I. Demographic data of the patients

	Misoprostol group N(%)	**Laminaria group N(%)**	**P value**
Age (years, n,%)			
20-29	26 (36.1)	22 (30.6)	NS
30-39	31 (43.1)	41 (56.9)	NS
40-49	9 (12.9)	6 (8.3)	NS
50-60	6 (8.3)	3 (4.2)	NS
Age (years, mean ±SD)	32.7±8.7	30.7±6.3	NS
Nullipara	48 (66.7)	36 (50)	NS
Primipara	9 (12.9)	12 (16.7)	NS
Multipara	15 (20.8)	24 (33.3)	NS

Table II. Main complaints (indications for hysteroscopy)

Complaint	Misoprostol group No(%)	Laminaria group No (%)	P value
Primary infertility[a]	30 (41.7)	31 (43.1)	NS
Secondary infertility[a]	8 (11.1)	7 (9.70)	NS
Abnormal uterine bleeding[a]	13 (18)	14 (19.4)	NS
Recurrent abortion[a]	5 (6.9)	3 (4.20)	NS
Missed intrauterine device	4 (5.6)	0	-
Proximal tubal obstruction	7 (9.7)	11 (15.3)	NS

[a] Suspected intrauterine cause.

Table III. Hysteroscopic procedures in both groups

Procedure	Misoprostol group No(%)	Laminaria group No(%)	P value
Myomectomy	12 (16.7)	3 (4.2)	NS
Polypectomy	11 (15.3)	12 (16.7)	NS
Metroplasty	5 (6.9)	6 (8.3)	NS
Endometrial resection	4 (5.6)	7 (9.7)	NS
Adhesiolysis	23 (31.9)	18 (25)	NS
Intrauterine device extraction	4 (5.6)	0	–
Tubal cannulation	7 (9.7)	19 (26.4)	NS
Endometrial biposy	6 (6.3)	7 (9.7)	NS

NS = non-significant.

Table IV. Technical characteristics of the two studied groups

Characteristic	Misoprostol group (Mean±SD)	Laminaria group Mean±SD)	P value
Duration of application (h)	8.4±0.6	8.3±0.5	NS
First Hegar dilator (mm)	7.5±1.2	7.6±1.2	NS
Duration of dilatation (s)	51±33.8	50±29.8	NS

Table V. Disadvantages of the procedure

	Misoprostol group No(%)	Laminaria group No(%)	P value
Insertion difficulty	0. (0.0)	26 (36.1)	0.001
Difficult cervical dilatation	8 (11.1)	12 (16.7)	NS
Cervical perforation	2 (2.8)	0 (0.00)	NS
Feasibility of the procedure:			NS
Easy	70 (97.2)	63 (87.5)	
Difficult	2 (2.80)	9 (12.5)	

NS = non-significant.

Table VI. Doctor assessment and patient acceptability of cervical priming

	Misoprostol group No(%)	Laminaria group No(%)	P value
Doctor assessment			0.015
Excellent	68 (99.4)	60 (83.3)	
Good	2 (2.80)	6 (8.30)	
No change	0	6 (8.30)	
Bad	2 (2.80)	0	
Patient acceptability			0.001
Yes	70 (97.2)	55 (76.4)	
No	2 (2.80)	17 (23.60)	

References:

Bugalho A, Bique C, Machungo F and Faunder A (1994) Induction of labor with intravaginal misoprostol in intrauterine fetal death. Am J Obstet Gynecol 171,538–541.

Chen FP, Soong YK and Hui YL (1997) Successful treatment of severe uterine synechiae with transcervical resectoscopy combined with laminaria tent. Hum Reprod 12,943–947.

Fung TM, Lam MH, Wong SF and Ho LC (2002) A randomized placebo controlled trial of vaginal misoprostol for cervical priming before hysteroscopy in postmenopausal women. Br J Obstet Gynaecol 109,561–565.

Ghazizadeh S (2003) Complications of operative hysteroscopy, report of rare cases. Proceedings of the 12th Annual Congress of the European Society for Gynecologic Endoscopy, Luxemburg, November 26–29, p 88, 006.

Goldrath MH (1987) Vaginal removal of the pedunculated submucous myomata. The use of laminaria. Obstet Gynecol 70,670.

Hald F, Kristoffersen SE and Gregresen E (1988) Prostaglandin vaginal suppositories in nonpregnant women required cervical dilatation prior to hysteroscopy. Acta Obstet Gynecol Scand 67,219–222.

Itzkowic D and Beale M (1999) Uterine perforation associated with endometrial ablation. Aust NZ J Obstet Gynecol 32,359–361.

Ngai SW, Chan YM and Ho PC (2001) The use of misoprostol prior to hysteroscopy in postmenopausal women. Hum Reprod 16,1486–1488.

Ngai WN, Chan YM, Liu KL and Ho PC (1997) Oral misoprostol for cervical priming in non pregnant women. Hum Reprod 12,2373–2375.

Ostrzenski A (1994) Resectoscopic cervical trauma minimized by inserting laminaria digita preoperatively. Int J Fertil Menopausal Stud 111,39.

Preutthipan S and Herabutya Y (1999) A randomized controlled trial of vaginal misoprostol for cervical priming before operative hysteroscopy. Obstet Gynecol 94,427–430.

Rath W, Kuhn W and Hilgers R (1985) Facilitation of cervical dilatation by intra cervical application of sulprostone gel prior to hysteroscopy. Endoscopy 17,191–193.

Siegler AM and Valle RF (1988) Therapeutic hysteroscopic procedures. Fertil Steril 50,685–699.

Sowter MC, Lethaby A and Singla AA (2003) Preoperative endometrial thinning agents before endometrial destruction for heavy menstrual bleeding (Cochrane Review). In The Cochrane Library, Issue 2. Update Software, Oxford.

Thomas JA, Leyland Y, Durand N and Windrim RC (2002) The use of oral misoprostol as a cervical priming agent in operative hysteroscopy: a double-blind, placebo-controlled trial. Am J Obstet Gynecol 186,876–879.

Townsend DE and Melkonian R (1990) Laminaria tent for diagnostic and operative hysteroscopy. J Gynecol Surg 6,271–274.

Vilos GA, Vilos EC and King JH (1996) Experience with 800 hysteroscopic endometrial ablations. J Am Assoc Gynecol Laparosc 4,33–38.

Wing DA and Paul RH (1996) A comparison of differing dosing regimens of vaginally administered misoprostol for preinduction cervical ripening and labor induction. Am J Obstet Gynecol 175,158–164.

2.a.2 **Is there a role for hysteroscopic tubal occlusion of functionless hydrosalpinges prior to IVF/ICSI in modern practice?**

Atef M. Darwish, Ali M. ElSaman

Acta Obstetricia et Gynecologica Scandinavica 2007; 86,12, 1484 – 1489.

Introduction:

Obstruction of the distal fallopian tube is one of the most common causes of female infertility (1). Nowadays, it is conceived that the presence of hydrosalpinx is associated with compromised outcome of IVF/ICSI. Hydrosalpnix is associated with lower implantation and fecundibility rates which may be attributed to alteration in endometrial receptivity (2) or direct embryo toxic effect. Furthermore, it is liable be unintentionally punctured at the time of egg retrieval or it may disturb the access to the ovary if it is too big. In a meta-analysis, it has been demonstrated that there was a reduction by half in the probability of achieving a pregnancy in the presence of hydrosalpinx and an almost doubled rate of spontaneous abortion (3). In an animal study, hydrosalpinx fluid was shown to contain toxins that are potentially teratogenic (4). Proposed mechanisms of impaired implantation rate due to hydrosalpinges are well addressed in literature (5). Selected patients with unilateral hydrosalpinges and a patent contralateral Fallopian tube may exhibit increased cycle fecundity after salpingectomy or proximal tubal occlusion of the affected tube and may conceive without the need for IVF (6). In a retrospective case-control study, bilateral salpingectomy due to hydrosalpinges restored a normal delivery as well as implantation rate after IVF treatment compared to controls (7). Randomized controlled trials recommended performing laparoscopic salpingectomy prior to IVF especially in patients with ultrasound-visible hydrosalpinges (8). In a recent Cochrane review (9), it was concluded that further randomised trials are required to assess other surgical treatments for hydrosalpinx, such as salpingostomy, tubal occlusion or needle drainage of a hydrosalpinx at oocyte retrieval. Functionless hydrosalpnix can be defined as big blocked tube with lost major and minor folds as seen at salpingoscopy after laparoscopic salpingoneostomy. This

study aims to determine whether hysteroscopic tubal occlusion will produce the same efficacy as laparoscopic tubal occlusion of functionless hydrosalpnix prior to IVF/ICSI.

Patients and methods:

The invitro safety phase of this study was done on fresh uterine specimens removed by abdominal or vaginal hysterectomy. In this phase the study, fresh hysterectomy specimens were placed on the return electrode of diathermy, then the corneal ends of both tubes were coagulated simulating the same manner as in the clinical phase. Temperature study was done using digital thermometer over the uterine serosa at site of the coagulation. Histopathologic sections were made to assess tissue effects and depth of penetration using Nitro Blue Tetrazolium (NBT) to evaluate the extent of coagulation on the tubal uterine junction. Computerized image analyzer (Leica Q 500 MB Computerized Image Analyzer) was used to measure the depth of diathermy damage to the surrounding myometrium.

The clinical phase of this study was conducted at the out-patient Infertility clinic of Women Health hospital, Assiut University, from April 2004 to October 2006 and included 27 patients with definite uni- or bilateral laparoscopically-proved functionless hydrosalpinges scheduled for IVF/ICSI. All patients gave a written consent and the study was approved by. the institutional ethics committee. They were randomly divided into 2 groups. Randomization was done using simple computer generated randomization tables method. Group A comprised 14 patients who were randomly allocated for laparoscopic occlusion. Laparoscopy was performed under general endotracheal anaesthesia using a standard double puncture technique. Once the peritoneal cavity was entered, a panoramic evaluation of the pelvis was done. If the pelvis looks frozen or if the access to the fallopian tubes was impossible, the patient was considered failed laparoscopic approach. Those cases were subsequently treated by open laparotomic or hysteroscopic approach but the results of these procedures were not included in this study. If

the procedure seems feasible, a third auxillary puncture was done. Utilizing a bipolar forceps, the isthmic part of the fallopian tube was coagulated and incisied to ensure complete tubal occlusion as a case of tubal sterilization. The procedure was completed after securing hemostasis. The patient was discharged after 3-4 hours under antibiotic prophylaxis. Group B included 13 patients scheduled for hysteroscopic approach. The cervix was primed in all cases using 200 Mg misoprostol 8 hours prior to the procedure as previously described (10). The procedure was done immediately postmenstrual without specific preparation. Local paracervical anesthesia was selected in 5 cases while spinal anesthesia in 6 cases, and general anesthesia in 2 cases. Selection of the anesthestic technique was chosen according to patient preference after proper explanation by the anesthiologist. The cervix was gently dilated till Hegar's 10 which was followed by insertion of a rotatory continuous flow monopolar resectoscope. Once the peritubal pulge (the proximal part of the intramural segment of the tube (11)) was clearly seen, a roller ball electrode of 3 mm size was bluged inside it and activated at 50 watts for about 8 seconds. A thorough comment on the fundus and the rest of the endometrial cavity was reported. The patients were discharged immediately if the procedure was done under local paracervical anesthesia, while the remaining cases were discharged few hours later. In both groups, the procedure was preceded and done under prophylactic broad spectrum antibiotic coverage to guard against any risk of flaring up of infection of the functionless hydrosalpnix. In both groups, patients were instructed to come back the next cycle postmenstually where hysterosalpingography (HSG) was done for most cases specially those with unilateral functionless hydrosalpnix. If the patient refused and has bilateral hydrosalpnix, sonohysterography (SHG) was done utilizing a simplified technique as previously described (12). Tubal occlusion of the affected side was confirmed if marked resistance was encountered on repeated injection of saline without evidence of intraperitoneal leakage from the occluded side which is the main outcome measure. Second-look office hysteroscopy was done for

patients in group B whenever possible. Data were collected and analyzed with SPSS version 11 (SPSS, Inc., Chicago, IL) and expressed as mean± standard deviation (SD). Statistical methods were applied including descriptive statistics (frequency, percentage, mean and standard deviation) and tests of significance (student t-test was used to determine statistical significance between the two groups, while paired t-test was used to determine statistical significance pre and post-treatment in the same group). P value was considered as statistically significant when less than 0.05.

Results:

The in-vitro safety phase resulted in bilateral complete coagulation of the proximal part of the tubes with secondary coagulation shown of up to 3 mm as shown in the histopathologic sections. When the power of coagulation was 50-60 W and operating time not prolonged more than 20 seconds , the thermal damage covered corneal end as complete coagulation in addition to 2mm -3 mm secondary coagulation of the adjacent cornual endo- myometrium. Serosal temperature was not exceeding 41.9 Cº (range 39 Cº - 41.9 Cº) at any time during the procedure. No full thickness injuries were demonstrated either histologically or suggested by the temperature studies.

Demographic data showed that both groups were nearly similar as regards age (25±3.2 vs. 23±1.7 years), parity (0 vs. 0), and period of infertility (5±2.9 vs. 4.2±1.8 year). Most cases had a history of at least one diagnostic or operative laparoscopy before. Those patients who had operative laparoscopy (3 (21.4%) and 4(30.8%) cases in both groups respectively) were subjected to a control HSG to confirm the presence of functionless hydrosalpnix prior to their inclusion in this study. The suspected main cause of hydrosalpnix was iatrogenic (pelvic surgery) in 9 (64%) and 8 (61.5%) cases in both groups respectively (Table1).

Table I. Past history of the studied patients.

	Group A	Group B	P value
History of appendectomy	3(21.4%)	4(30.8%)	NS
History of gynecologic operation	6(42.8%)	4(30.8%)	NS
History of genital tuberculosis	2(14.3%)	1(7.7%)	NS
History of PID	3(21.4%)	1(7.7%)	NS
No possible causal history	0	3(23%)	NS
History of diagnostic laparoscopy	5(40%)	6(46%)	NS
History of operative laparoscopy	3(21.4%)	4(30.8%)	NS

Table II. Pri-operative findings in both groups.

	Group A (14 patient)	Group B (13 patients)	P value
Feasible access:	10(76.9%)	12 (85.7%)	NS
Operative time (min):	23.6 ±4.75	9 ±2.76	0.0001
Concomitant procedures:	8(57%)	3(22.7%)	NS
Hospital stay (hours):	5 ±1.13	2 ±1.84	0.0001
Successful occlusion:	10(76.9%)	9 (64.2%)	NS

The mean number of abdominal scars/patient was 1.4 and 1.5 in both groups respectively. Unilateral hydrosalpnix was encountered in five (35.7%) and three (23%) cases in both groups respectively. In group A, the procedure was possible in only 10cases (76.9%) while extensive intestinal or omental adhesions hindered access to the tubes in the remaining cases.

Hysteroscopic access was achieved in 12 (85.7%) and occlusion was achieved in 9 (64.2%) cases. If the peritubal pulge was not clearly visible, the case was considered as failed access to the proper site of occlusion. In group B, diagnostic hysteroscopy showed fine marginal adhesions in 2 cases (15%) and a small polyp in one case (7.7%). Hysteroscopic tubal occlusion showed shorter operative time (9 ±2.76 min vs. 23.6 ±4.75 min, p= 0.0001) and hospital stay as well (2 ±1.84 hours vs. 5 ±1.13 hours, p= 0.0001) (table 2). No case of intraoperative complication in either group was reported. There was no case of exaggerated postoperative pelvic pain or fever in either group. HSG or SHG demonstrated complete tubal occlusion of the affected side in all cases in both groups). Second-look office hysteroscopy was done in 8 cases of group B which revealed no significant corneal lesions at the site of hysteroscopic occlusion. Pregnancy was achieved in 4 (28.5%) and 4(30.7%) cases in both groups respectively following IVF/ICSI without any significant difference between both groups.

Discussion:

The reported main cause of distal tubal occlusion is salpingitis, which is usually secondary to pelvic inflammatory disease (1). In the present study, the main cause of tubal damage was iatrogenic where pelvic surgery resulted in trauma to the tubal serosa with subsequent adhesion formation. Most cases followed appendectomy or gynecologic operations like ovarian cystectomy or myomectomy. This observation highlights the documented superiority of the endoscopic surgery in terms of less possibility of adhesions formation. In case of laparotomy, the gynecologists as well as the general surgeons should follow the microsurgical principles (13) to preserve the fertility of females. Salpingectomy is done for the dilated tubes that are visible on ultrasound and have a severely damaged mucosa (14). That is why we kept the term “functionless” throughout the manuscript. In a Cochrane review (9), it

has been recommended that laparoscopic salpingectomy should be considered for all women with hydrosalpinges prior to IVF treatment. However, salpingectomy has some drawbacks. The tubes may be inaccessible in some cases due to extensive pelvic adhesions. In the present study, access to the tubes could not be achieved in two cases (14%). Since most of these patients had previous laparotomies, a special expertise is required which is not available in all centers. Instead, open salpingectomy is practiced which carries well-documented disadvantages of laparotomy (15). We noticed poor acceptability of our patients to the salpingectomy decision as it is thought to have a poor impact on their psychological status. Ovarian function seems to be impaired after laparoscopic unilateral salpingectomy in terms of impaired ovarian blood flow and reduced antral follicle count at short-term assessment (16).

Laparoscopic salpingectomy or bipolar proximal tubal occlusion yielded statistically similar responses to controlled ovarian hyperstimulation and IVF-ET cycle outcome. The authors concluded that proximal occlusion may be preferable in patients who present with dense pelvic adhesions and easy access only to the proximal fallopian tube (17). Occlusion is considered a minimally invasive procedure, requires less experience, feasible in most cases, and has fewer burdens on the psychological status of those infertile women. In literature, there is no comment on the anatomic efficacy of occlusion procedure in patients with hydrosalpnix. This is the first study that documents anatomic efficacy of the occlusion procedure on performing HSG or SHG postoperatively. SHG is a simple, very cheap, office, non-invasive and rapid technique (12). Follow-up period of complete occlusion was only for one month as the main objective of the present study was to prepare patients for IVF/ICSI unlike tubal sterilization procedures.

Hysteroscopic tubal occlusion is not a new technique as it is practiced since 1975 (18). An electrode was inserted 5 mm into the intramural portion of the tube and a current (27.8 watts) was passed for 6 seconds. The patients were given oral contraceptives for 1 year, during which time they were checked by hysterosalpingography for occlusion of both tubes. Following

the electrocoagulation, 87.8% of the women were found to have both tubes occluded, 11.4% had 1 tube open and 0.8% had both tubes open. In the present study, we achieved access to the peritubal pulge in 12(85.7%) cases and 9 of them achieved complete occlusion as proved by HSG or SHG. The used occlusion technique in the present study is completely different and simulates that used in roller ball endometrial ablation (19). A power setting of 50 Watts coagulation current was utilized as guided by the histopathologic evaluation during the invitro part of the present study. No case of intra or postoperative diathermy complication was reported in the present study. In hysteroscopic surgery, 40-60 Watts usually will provide sufficient energy to cause the desired level of destruction (19). Recent very effective hysteroscopic tubal occlusion procedures like Ovabloc, tubal screw, essure or others (20) are not suitable in such cases as these foreign bodies may interfere with implantation by inducing uterine contractility. However, a case report of successful pregnancy following hysteroscopic occlusion utilizing microinsert was recently published (21). We think that resectoscopic occlusion is superior as it leaves the endometrial cavity ready for implantation. It should be stressed that the cavity is completely free after this procedure as the block is actually intratubal.

In the present study, the main outcome measure was proximal tubal occlusion rather than achievement of pregnancy despite being reported. Most of the studies that recommended prompt management of hydrosalpnix prior to IVF, reported occurrence of pregnancy in patients with opened hydrosalpnix, yet significantly lower than that occurred in the patients with occluded hydrosalpnix (22). The implantation rate was significantly higher in patients who had undergone salpingectomy (27.2% versus 20.2%, P = 0.03) and, in the subgroup of patients with ultrasound-visible hydrosalpinges, the difference was even larger (30.3% versus 17.1%, P = 0.003). Moreover, achievement of pregnancy is a multifactorial event and tubal occlusion is just one of these factors. As tubal occlusion is expected to increase the chance of pregnancy, we just compared two approaches of occlusion. An important safety issue is the freedom of the

endometrial cavity from the possibility of postoperative adhesions as the roller ball electrode is sucked inside the pretubal pulge which is actually a tubal rather than a uterine part. We reported pregnancy rate similar to laparoscopic occlusion. However, this point would be better addressed in a large multicentric study.

Conclusions:

Hysteroscopic tubal occlusion of proximal part of the hydrosalpnix is feasible and promising as a safe, effective, fast, and easy approach. It can be done as an out-patient procedure under local paracervical block. It has the advantage of adding valuable evaluation of the endometrial cavity prior to IVF/ICSI. Further large sample-sized studies are required specially those utilizing bipolar resectoscope. The impact of hysteroscopic tubal occlusion on subsequent implantation and pregnancy rates needs to be addressed in another larger study. Since it is a preliminary study, the current role of hysteroscopic occlusion should be limited to cases of failed laparoscopic approach. Nevertheless, based on our practice, we would suggest a guideline algorithm for management of cases of hydrosalpnix (Figure 1). Further studies are required before moving hysteroscopic occlusion to replace laparoscopic occlusion prior to IVF/ICSI.

Figure (1): A suggested flowchart for management of functionless hydrosalpnix prior to IVF/ICSI.

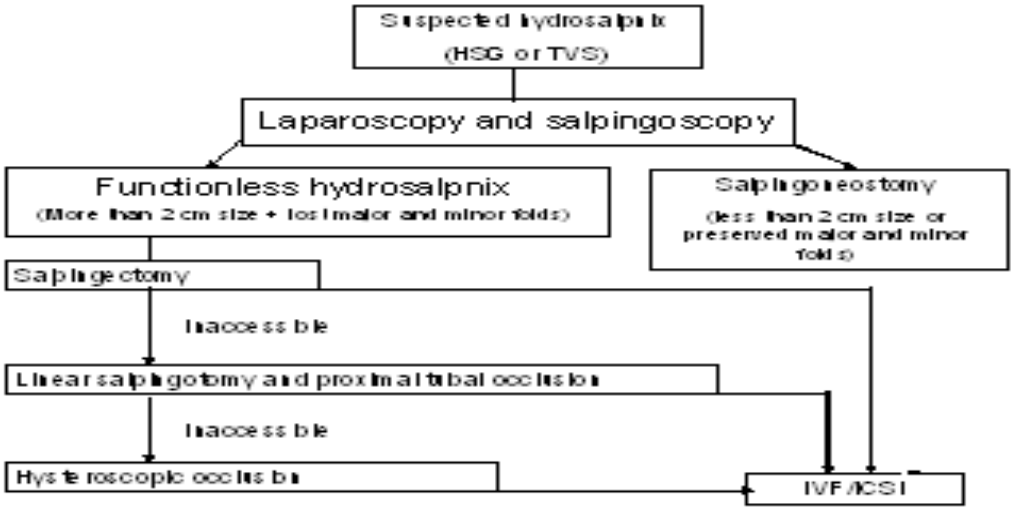

HSG: Hysterosalpingography. **TVS:** Transvaginal ultrasonography.

References:

(1) Peacock LM, Rock JA. Distal tubal reconstructive surgery. In. Operative Gynecologic Endoscopy. By Sanfilippo JS, Levine RL. 1996, Springer-Verlag New York, Inc. pp 182-191.

(2) Seli E, Kayisli UA, Cakmak H, Bukulmez O, Bildirici I, Guzeloglu-Kayisli O. Removal of hydrosalpinges increases endometrial leukaemia inhibitory factor (LIF) expression at the time of the implantation window. Hum Reprod 20(11):3012-7, 2005.

(3) Zeyneloglu HB, Arici A., Olive DL. Adverse effects of hydrosalpinx on pregnancy rates after in vitro fertilization-embryo transfer. Fertil.Steril. 70, 492-499, 1998.

(4) Chan LY, Chiu PY, Cheung LP, Haines CJ, Tung HF, Lau TK. A study of teratogenicity of hydrosalpinx fluid using a whole rat embryo culture model Hum Reprod. 18, (5), 955-58, 2003.

(5) Nackley, A.C. and Muasher, S.H. The significance of hydrosalpinx in in vitro fertilisation. Fertil Steril., 69, 373–384, 1998.

(6) Sagoskin A.W., Lessey BA, Mottla GL, Richter KS,Chetkowski RJ, Chang AS, Levy MJ, Stillman1 RJ. Salpingectomy or proximal tubal occlusion of unilateral hydrosalpinx increases the potential for spontaneous pregnancy. Hum Reprod 18(12) 2634-2637, 2003.

(7) Ejdrup H, Bredkjær, Ziebe S, Hamid B, Zhou Y, Loft A, Lindhard, Nyboe A, Andersen A. Delivery rates after in-vitro fertilization following bilateral salpingectomy due to hydrosalpinges: a case control study. Human Reproduction 14,1, 101-105,1999.

(8) Strandell A, Lindhard A, Waldenström U, Thorburn J, Janson PO, Hamberger. Hydrosalpinx and IVF outcome: a prospective, randomized multicentre trial in Scandinavia on salpingectomy prior to IVF Hum Reprod,16(11), 2403-2410, 2001.

(9) Johnson NP, Mak W, Sowter MC. Surgical treatment for tubal disease in women due to undergo in vitro fertilisation (Cochrane Review). The Cochrane Library, Issue 2, 2005. Chichester, UK: John Wiley & Sons, Ltd.

(10) Darwish AM, Ahmad AM, Mohammad AM. Cervical priming prior to operative hysteroscopy: a randomized comparison of laminaria versus misoprostol. Hum Reprod 19(10):2391-2394, 2004.

(11) Siegler A, Valle R, Lindemann H, Mencaglia L. Therapeutic hysteroscopy. Indications and techniques. Philadelphia. Mosby Co., 1990.

(12) Darwish AM, Youssef AA. Screening sonohysterography in infertility.Gynecol Obstet Invest. 48(1):43-7,1999.

(13) Sauer MV. Tubal infertility: the role of reconstructive surgery. In Lobo RA, Mishell Dr, Paulson RJ, Shoupe D. Infertility, Contraception, and Reproductive Endocrinology. Boston Blackwell Scientific Publications, 4th edition, pp390, 1997.

(14) Strandell A, Lindhard A. Hydrosalpinx and ART Salpingectomy prior to IVF can be recommended to a well-defined subgroup of patients Hum Reprod. 15(10):2072-4, 2000.

(15) Darwish A, Amin AF, AbdelAleem MA, Youssef MA. Laparoscopic management of benign adnexal masses: experience in a developing country. Gynaecol Endosc 10,159-165, 2001.

(16) Chan CC, Ng EH, Li CF and Ho PC. Impaired ovarian blood flow and reduced antral follicle count following laparoscopic salpingectomy for ectopic pregnancy. Human Reproduction, 18, 10, 2175-2180, 2003.

(17) Surrey ES, Schoolcraft WB. Laparoscopic management of hydrosalpinges before in vitro fertilization-embryo transfer: salpingectomy versus proximal tubal occlusion. Fertil Steril. 75(3):612-7, 2001.

(18)Quinones GR, Alvarado AD, Ley EC. Tubal electrocoagulation under hysteroscopic control (three hundred and fifty cases). Am J Obstet Gynecol. 15;121(8):1111-3,1975.

(19) Vancaillie TG. Endometial electroablation. In Sutton C, Doiamond MP. Endoscopic surgery for gynaecologists. London W.B. Saunders Co Ltd, p313-28, 1993.

(20)Magos A. Hysteroscopic tubal sterilization. Lynne Chapman, Obstet Gynecol Clin N Am 31,705– 719,2004.

(21)Rosenfield RB, Stones RE, Coates A, Matteri RK, Hesla JS**.** Proximal occlusion of hydrosalpinx by hysteroscopic placement of microinsert before in vitro fertilization-embryo transfer. Fertil Steril. 83(5):1547-50, 2005.

(22)Strandell A, Lindhard A, Waldenstrom U, Thorburn J. Hydrosalpinx and IVF outcome: cumulative results after salpingectomy in a randomized controlled trial. Hum Reprod. 16(11):2403-10, 2001.

2.a.3 Modified hysteroscopic myomectomy of large submucous fibroids.

Darwish A.

Gynaecol Obstet Invest. 2003;56(4):192-6.

Introduction:

Hysteroscopic myomectomy is the standard approach for treating submucous leiomyomata of suitable size (1). Resectoscopic myomectomy had some disadvantages like excessive bleeding, time consumed for cutting the myoma into chips of tissues and their extraction outside the uterine cavity in addition to the risks of fluid overload (2,3). The larger the size of the myoma, the longer the time required for its excision. Residual part of the myoma is a common hysteroscopic finding on second-look hysteroscopy in cases of big myomata. Five patients out of 42 with a myoma of 2-5 cm diameter required a second resection in a previous study (4). Some authors prefer to coagulate big myoma with YAG laser (5), or more recently using bipolar electrode in normal saline (6). Others prefer a two step technique for large sessile myoma (7). This study aims to compare a modified versus traditional morcellation technique of hysteroscopic removal of big submucous myomata as regards feasibility, efficacy, operative time, and possible complications, and to assess the efficacy of preoperative sonohysterography (SHG).

Patients and methods:

This prospective comparative study was approved by the ethical commettee of the Faculty of Medicine, Assiut University. It comprised patients presenting to the Gynecologic out patient clinic of the department of Obstetrics & Gynecology, Assiut University Hospital from June 1998 to May 2002 with the complaints of menorrhagia, infertility or recurrent abortions. They were examined by transvaginal ultrasonography with comments on the myometrial architecture, the presence and diameter of any intrauterine lesion. If an intrauterine lesion simulating myoma was diagnosed, the patients were included in this study with the following conditions. The myoma should be solitary and at least 3 cm in diameter. Smaller myomata were excluded. If the myoma was pedunculated, the pedicle

should exceed 2 cm. The intracavitary part of the myoma should be larger than the intramural part (types 0 and I). More delineation of the myoma was achieved by injecting sterile saline via the cervix (sonohysterography) using a simplified technique (8).

All cases were subjected to diagnostic hysteroscopy in the immediate postmenstrual period not preceded by hormonal priming. The objectives were to confirm the sonographic diagnosis of myoma, comment on the number and the size, assess the site of the myoma in relation to the tubal ostia and the uterine walls, detect a pedicle as this study included cases with broad pedicles, and to estimate the depth of the myoma in relation to the uterine wall. If more than half of the myoma protrudes into the endometrial cavity, the case will be considered a submucous myoma. If the intramural part is more than the intracavitary part, the case will be considered an intramural myoma (type II) and was excluded from the study.

One-hundred forty two patients fulfilling the proposed inclusion criteria were randomly divided into 2 groups according to the technique of the hysteroscopic removal. Group A comprised 65 patients who were submitted to a modified resectoscopic technique. Modification started 8 hours prior to the time of surgery by inserting 200 µg misoprostol (Misotac, Sigma Pharm, Egypt) intravaginally to allow softening of the cervical canal and the myoma itself. The resectoscope was used to make a deep circumfrential incision all around the base of the myoma until complete separation occurs and the myoma became completely free inside the endometrial cavity. This crucial step required changing the angle of the loop electrode into 15 degrees below the horizontal plane to allow easy access to the base. Cutting was made 3-4 mm from the base towards the myoma side to preserve some healthy endometrium for postoperative creeping to cover the row area of the myoma. A specially designed 2 mm myoma driller simulating the laparoscopic myoma driller was

introduced alongside the resectoscope under vision. It is a stainless steel wire with a terminal screw. This driller was used to tract the myoma at one side of the endometrial cavity to have an easy access to the base. This step was followed by extraction of the whole myoma through the primed cervical canal using a ring forceps. If some difficulty was encountered, the myoma was longitudinally bisected into 2 parts using resectoscopic knife electrode prior to extraction.

In group A, if an intramural extension was diagnosed, the following additional steps were done. A vertical linear incision was made over the whole length of the myoma to allow bulging of the myoma into the endometrial cavity i.e. to become a more submucous myoma like opening of the capsule at open myomectomy. IV injection of diluted 0.25 mg ergometrine was given by the anesthiologist to promote uterine contraction in this non-pregnant uterus and to reduce the vascularity (9). Moreover, minimization of the intrauterine pressure was done to allow most of the myoma to become intracavitary "Myoma shift" as previously described (10). The base of the myoma was circumfrentially cut with resectoscope using the former mechanical technique. In group B (77 patients), a morcellation technique was done where the resectoscope was used for shaving the myoma into chips of tissues followed by ring forceps extraction of these tissues.

In both groups, the resectoscope was reinserted after extraction of the myoma to ensure complete excision. Operative hysteroscopy was performed using continuous-flow resectoscope after cervical dilatation up to Hegar's 10 utilizing 1.5% glycine as a distending medium. Operative notes included comment on the feasibility of the operation, operating time calculated from the starting myomectomy until complete extraction of all tissues from the endometrial cavity, amount of fluid used for distending the uterine cavity, possible intraoperative or postoperative complications, and the amount of postoperative

blood loss estimated by insertion of an intrauterine balloon at the end of the procedure. All the extracted tissues were weighted. Prophylactic antibiotics were prescribed for all cases.

Data were collected and manipulated using SPSS for windows. The $\chi 2$ test was used to compare the 2 groups. Exact Fisher test was used when appropriate. $P>0.05$ was considered not significant and $P\leq 0.05$ was considered significant. The relation of several variables with the outcome was analyzed using Cox proportional hazard regression analysis. Agreement was assessed using kappa statistics. Cohen's kappa coefficient (k) has a maximum value of 1 when agreement is perfect.

Results:

There was no statistically significant difference between both groups in their age, parity, and the main complaints as shown in table 1. Transvaginal SHG was able to define the location of the submucous myomata and to accurately estimate the width of the pedicle, if present, in all cases as confirmed by diagnostic hysteroscopy . Moreover, it could easily detect the intramural element in 19(29%) and 19(25%) patients versus 21(32.3%) and 23(41.5%) patients diagnosed by diagnostic hysteroscopy in both groups respectively (k=0.34). Complete and safe resection of the myoma was possible in 60 (92.3%) and 51 (66.2%) patients respectively as shown in table (2). Stoppage of the procedure was decided in 3 cases in group A due to excessive bleeding of the intramural element of the myoma. In 6 cases (8.7%) in group B, the procedure was stopped due to fluid overload defined as deficit of more than 1.5 liters. Incomplete resection was decided in 2(3%) and 20(25.9%) in both groups respectively due to prolonged operative time or technical difficulty to excise the whole mass.

The operative time was highly statistically significantly shorter in group A (15.6±3.02 versus 28.9±4.3 seconds)(p 0.001). Likewise, fluid volume utilized for the procedure was minimal in the first group (2.3±0.86 versus 6.3±1.7 liters)(p 0.001) (table 3). Intraoperative complications were encountered in 9 (13.8%) and 22 (28.6%) patients in both groups respectively as shown in table (4). Postoperative complications were only 4 cases of considerable visual disturbances in group B (5%). The mean weight of the myoma tissue extracted after the procedure was 47±2.6 and 51±1.57 grams in both groups respectively. A second session was needed in 2 cases (3%) and 20 cases (25.9%) in both groups respectively.

Discussion:

Despite being the standard procedure for treating submucous myomata of suitable sizes, hysteroscopic myomectomy is considered to be the most dangerous hysteroscopic procedure mainly due to possible fluid overload as the myoma is very vascular and the higher incidence of blood loss with the possibility of incomplete resection of the lesion in one session (11,12). Large-sized myoma represents a real challenge to the experienced hysteroscopist. Due to the large size of the leiomyomas, 35 out of 200 patients (17.5%) had 2 or 3 resections in one study (13). However, they included patients with multiple fibroids in 77.2% of cases. More than one session of hysteroscopic surgery exposes the patient to repeated risks of the surgery and anesthesia as well as the distension media complications. These common problems were the provocative factors for constructing this work. The two main problems of large myoma treated by the usual morcellation technique are prolonged operative time and excessive fluid overload. They were signifi-cantly minimized using this modified technique and hence the need for a second session was encountered in only 2 cases (3%) versus 20 cases (25.9%) in the morcellation technique. In group A, some

modifications resulted in definite simplification of the procedure. The preoperative use of 200 µg misoprostol was considered an important step in this study as it led to elimination of the time of cervical dilatation and the operative duration was also shortened as previously described (14). Moreover, softening of the myoma itself was evident particularly at the step of the myoma extraction. Likewise, using IV ergometrine might reduce the vascularity and stimulate uterine contractility.

Extraction of big myoma from the cervical canal represents a real problem of hysteroscopic approach. Many centers leave the myoma in place and inform the patient that she will abort pieces of tissues within 7-14 days (15). This attitude was not used in this study as the patient will suffer of continuous colicky pain for a long time and most importantly leaving this degenerated tissue inside the uterus may carry the risk of possible tubal obstruction due to secondary infection. Many centers prefer to give the patient a short course of preoperative GnRh-analogues to achieve shrinkage of the myoma (16). Really, it makes resection less bloody but the myoma extraction would be more difficult than using misoprostol, which causes softening of both the cervical canal and the myoma. In this study, safe extraction of the big myomata was successful in all except 3 cases (4.6%) of cervical lacerations that required suturing. This figure is slightly higher than others (17) who reported only one case of cervical tear (1.4%) in the misoprostol group. Their study group (73 patients) included only 15 cases (20.5%) of hysteroscopic myomectomy. Moreover, selecting patients with big solitary myomata to be included in this study is a logic additional explanation. In most cases, bisection of the soft myoma was performed which may be a good step to minimize risk of cervical lacerations. It differs from morcellating the myoma as the former procedure is done after complete separation of the

myoma with proper coagulation of the vessels at the bed, which means minimal fluid absorption.

In group B, 2 cases (2.6%) of uterine perforation occurred when the resectoscope goes deeply to cut the intramural element of the myoma. This complication could be avoided if proper preoperative sonographic assessment of the myometrial thickness at the implantation site was done. It should be more than 5mm (18). This problem was not encountered in group A due to the vertical incision made along the myoma and myoma shift technique to allow myoma bulging to become more submucous. Four cases of visual disturbances in the form of blurring of vision for up to 12 hours postoperatively were diagnosed in the morcellation group. This rare complication is attributed to excessive fluid absorption as previously described (19).

Preoperative transvaginal sonohysterography was proved to be an effective diagnostic aid to assess the location of submucous myomata and may eventually supplant both hysterosalpingography and diagnostic hysteroscopy (20). It also gives a good idea about the tubal patency of at least one tube in addition to diagnosis of intramural extension. This was confirmed by good agreement with diagnostic hysteroscopy prior to resection (k= 0.34). Practically, it is simple, fast and cheep (8).

In this study, tubal damage was encountered in 2 (3%) and 6 (7.8%) patients in both groups respectively. This complication is common if the monopolar electrode is applied very near to the ostium. It can be explained by secondary coagulation which is a clear disadvantage of monopolar surgery. Recently, with the advent of bipolar hysteroscopic surgery, precise tissue cutting is expected (21).

From this study, we conclude that a hysteroscopic resection of solitary symptomatic submucous myoma > 3 cm in diameter, with minimal intramural encroachment, is feasible using a modified technique of resectoscopic cutting of the myoma base or stalk and extraction of it with forceps after cerevicsal priming. It shows minimal complication rate and fluid deficit; and shorter operative time than the standard morcellation technique. If the excised myoma is extracted as one mass, this carries a small risk of cervical lacerations and possible cervical incompetence in subsequent pregnancy. Transvaginal SHG is a reliable diagnostic aid to assess submucous myomata.

Table (1): Patient characteristics and complaints.

	Group A	Group B	P value
Age (mean ± SD)	27.1±7.24	25.06±4.89	0.431*
Parity (mean± SD)	3.5±1.22	3.8±1.41	0.631*
Menorrhagia	23 (35.4%)	31 (40.2%)	0.372*
Infertility	27 (41.5%)	36 (46.7%)	0.517*
Recurrent abortions	15 (23%)	10 (12.9%)	0.051*

* Non-significant

Table (2): Feasibility of hysteroscopic myomectomy.

	Group A	Group B	P-value
Complete resection	60 (92.3%)	51 (66.2%)	0.01*
Incomplete resection	2 (3%)	20 (25.9%)	
Stopped procedure	3 (4.6%)	6 (7.8%)	

* moderately significant

Table (3): Main operative notes.

	Group A	Group B	Significance
Operative time	15.6±3.02	28.9±4.3	0.001*
Glycine volume	2.3±0.86	6.3±1.7	0.001*

* Highly significant.

Table (4): Intraoperative complications.

Complication●	Group A	Group B	P value
Considerable bleeding	4 (6.15%)	14 (18%)	0.03*
Uterine perforation	0	2 (2.5%)	0.50
Tubal damage	2 (3%)	6 (7.8%)	0.03*
Cervical laceration	3 (4.6 %)	0	0.9
Total	9(13.8%)	22(28.5%)	0.03*

● Odds ratio = 6.9

* Statistically significant.

References:

1. McLucas B: Intrauterine applications of the resectoscope. Sur Gynecol Obstet 1991; 172(6):425-430.
2. Vancaillie TG. Endometial electroablation. In Sutton C, Doiamond MP. Endoscopic surgery for gynaecologists. 1993, London W.B. Saunders Co Ltd, p313-28.
3. Molsberry RL, Neuwirth RS. Complications of hysteroscopic myomectomy. In Corfman RS, Diamond MP, DeCherney A (eds): Complications of laparoscopy and hysteroscopy, ed, Boston, Blackwell, 1993, Ch 38.
4. Hamou J: Electroresection of fibroids. In Endoscopic Surgery for Gynaecologists. Ed by Sutton C and Diamond M. London. Sauhders Co LTD, 1993, Ch 41.
5. Baggish MS, Eze E, Morgan G. Hysteroscopic treatment of symptomatic submucous myomata uteri with the Nd:YAG laser. J Gynecol Gurg 1989;5:27-32.
6. Chark TJ, Mahajan D, Sunder P, Gupta JK. Hysteroscopictreatment of symptomatic submucous fibroids using a bipolar intrauterine system; a feasibility study. Eur J Obstet Gynecol Reprod Biol 2002;100:237-242.
7. Corson S and Brooks A: Resectoscopic myomectomy. Fertil Steril 1991; 55 (6):1041-54.
8. Darwish AM, Youssef AA. Screening sonohysterography in infertility.Gynecol Obstet Invest 1999; 48(1):43-7.
9. Monaghan JM: Myomectomy In, Bonney's Gynaecological Surgery. London, Bailliere Tindal, 9th Ed, 1986, Ch: 10, p:89.
10. Diebold P, Keller D, Brander P, Neis KJ: Influence of hysteroscopic intrauterine pressure on the intramural extension of submucous myomas " myoma shift"

11. Corson S and Brooks A: Resectoscopic myomectomy. Fertil Steril 1991; 55 (6):1041-54.

12. Molsberry RL and Neuwirth RS: Complications of hysteroscopic myomectomy. In Complications of laparoscopy and hysteroscopy. 1st ed. Edited by Corfman RS, Diamond MP and DeCherney A. Boston, Blackwell Scientific Publications, 1993, Ch 38.

13. Fenandez H, Kadoch O, Capella-Allouc S, Gervaise A, Taylor S, Frydman R. Hysteroscopic resection of submucous myomas: long term results. Ann Chir 2001;126:58-64.

14. ACOG News Release: Misoprostol effective for cervical priming before hysteroscopy. November 30, 2000.

15. March CM: Uterine fibroids: difficulties with tissue removal. In Complications of laparoscopy and hysteroscopy. 1st ed. Edited by Corfman RS, Diamond MP and DeCherney A. Boston, Blackwell Scientific Publications, 1993, Ch 41.

16. Hany AF: Clinical decision making regarding leiomyomata: what we need in the next millenium. Environ Health Perspect 2000;108, 5:835-9.

17. Preuttipan S, Herabutya Y: Vaginal misoprostol for cervical priming before operative hysteroscopy: A randomized controlled trial. Obstet Gynecol 2000; 96:890-894.

18. Yang JH, Lin BL: Changes in myometrial thickness during hysteroscopic resection of deeply invasive submucous myomas. J Am Assoc Gynecol Laparosc 2001; 6(4):501-5.

19. Motashaw ND, Dave S: Vision disturbances after operative hysteroscopy. J Am Assoc Gynecol Laprosc 1999;6(2):213-15.

20. Christian SS, Schlaff WD: Hysteroscopic myomectomy. In Azziz R, Murphy AA. Practical manual of operative laparoscopy and hysteroscopy. 2nd edition, NewYork, Springer-Verlag Inc., 1992, ch 28.

21. Kresch A, Longacre T, Feste JR, Lotze EC, Wstland A, Miller G, Savage G: Initial exoerience with a physiologic morcellating resectoscope. J Am Assoc Gynecol Laparosc 1998;5(4):419-421.

2.a.4 **Extended resectoscopic versus sequentional cold knife-resectoscopic excision of the unclassified complete uterocervicovaginal septum: a randomized trial.**

Atef M. Darwish, MD, Ali M. ElSaman, MD

Fertility Sterility,

Augest 2008, online

Introduction:

Since a long time, hysteroscopic metroplasty is considered the ideal evidence-based treatment modality of complete cervicouterine septum (1). According to the AFS classification of Müllerian duct anomalies, complete cervicouterine septum is considered as class V-a (2). In recent years, there is an increased interest in a new unclassified anomaly which is longitudinal vaginal septum in conjunction with complete cervicouterine septum (3). It has not been evaluated as a homogeneous group. Most studies have concentrated on reproductive outcome, but it is unknown whether or not this uterovaginal anomaly is associated with gynecologic complaints such as endometriosis, infertility, and malignant potential (4,5). It is mostly asymptomatic and detected incidentally during routine examination or during delivery. It may cause dystocia in delivery, dyspareunia, or hygienic problems indicating surgical intervention (6). This anomaly is found more often in patients with a didelphic or bicornuate uterus with high frequency of endometriosis as shown in one study (7). Till the year 2004, throughout the literature, only eight known cases have been reported (8). Thereafter, an increasing number of publications on this anomaly are issued. Traditional surgical management in symptomatic patients with this anomaly includes cold-knife excision of the vaginal septum followed by resectoscopic resection of the complete cervicouterine septum. Nevertheless, incomplete resection of the longitudinal vaginal septum has been reported in some studies (9,10). This study aims to determine if resectoscopic sectioning of complete uterocervicovaginal septum is as effective as cold knife excision of the longitudinal vaginal septum followed by resectoscopic cutting of the cervicouterine septum in symptomatic patients.

Patients and methods:

This study was conducted at the Endoscopy Unit of the Women's Health University Center of Assiut University between January 2004 and December 2007. It comprised 32 women with complete longitudinal vaginal septum and a complete cervicouterine septum who had a history of pregnancy wastage, dyspareunia or infertility. All patients gave a written consent to enter this study which was approved by the IRB.

Preoperative diagnosis was made based on clinical visualization of the longitudinal vaginal septum and 2D ultrasonography to detect uterine shape and the presence of intrauterine septum. In cases with suspicious diagnosis, sonohysterography was done as previously described by our team (11) but using one catheter in each hemivagina. In seven cases, MRI is ordered to confirm the diagnosis. Three-dimensional ultrasonography was done for six cases only. In all cases, transabdominal 2D ultrasonography was performed on the upper abdomen to detect any associated renal malformations. Patients were randomized into two groups according to the surgical approach. Randomization was performed using a computer generated simple randomization method. In group A resectoscopic excision of the complete septum starting from the vaginal interoitus was made while in group B cold knife excision of the vaginal part followed by resectoscopic excision of the cervical and uterine parts was the treatment modality.

Inclusion criteria consists of patients with a complete vaginocervicouterine septum who had a history of at least one first-trimester or second-trimester pregnancy loss and who had undergone preoperative evaluation to exclude other causes of reproductive failure, preterm delivery, or unexplained infertility. Some patients complaining of only dyspareunia were included. Dyspareunia was either superficial due to obstacle by the edge of the septum or deep due to narrowing of the hemivagina used for intercourse. When this anomaly was

accidentally discovered in asymptomatic patients, those cases were excluded from the study.

The operative procedures were essentially in the early proliferative phase without preoperative endometrial preparation. Cervical priming was done in all cases utilizing vaginal misoprostol 200 Mg 8 hours prior to the operation as previously recommended (12). General anesthesia was used for all patients. Concomitant diagnostic laparoscopy was performed in all cases to delineate the external uterine contour and detect any associated pelvic lesion particularly in infertile women. The patient was put in the modified lithotomy position with mild abduction of the thighs to facilitate vaginal maneuvers.

In group A (15 cases), resectoscopic incision of the septum was made. The 90 degrees loop electrode of the resectoscope was turned manually to become 180 degrees (like a knife) to have a central access to the septum. The electrode was connected to an electrosurgical unit set at 60 W and unmodulated (pure cut) monopolar current. Resection was started from the lower pole of the septum centrally. Any bleeding spot was immediately controlled with the coagulating mode. Once the cervix has been reached, resection of the cervical followed by the corporeal parts were performed keeping the electrode all the time in the center of the septum till having an even fundus with well visualization of both tubal ostea on panoramic view.

In group B (18 cases), after proper sterilization of the vagina, a 0 Vicyrl traction stitch was applied in the central part of the longitudinal vaginal septum. Using a fine dissecting scissors, the septum is gradually excised till reaching the cervix. Any bleeding point was immediately coagulated with monopolar diathermy. At the end of excision, the raw surfaces of the anterior and posterior vaginal wall were sutured with 2/0 Vicryl stitch in continuous

lock fashion. Thereafter, the resectoscope was introduced into the cervical canal. Hysteroscopic metroplasty was done in the same manner as group A.

In both groups, neither postoperative intrauterine device nor balloon was left in utero. No postoperative hormonal treatment was prescribed in any case. However, patients received a perioperative prophylactic dose of broad spectrum antibiotics. All patients were discharged from the hospital within 6 hours following the procedure. Patients were instructed to continue on local antiseptic bovidone iodine vaginal douches thrice daily. Trial of sexual intercourse was allowed after two weeks. On the first follow-up visit one month postoperatively, the patient was asked about any postoperative complication in the form of excessive bleeding or discharge, vaginal scar related-dyspareunia, and husband satisfaction. Clinical and sonographic follow-up were done after one month to detect any residual vaginal or uterine parts respectively. In cases of difficult evaluation of the endometrial cavity with the conventional 2D ultrasonography, sonohysterography was performed. Patients were followed up for 6-12 months postoperatively with comment on reproductive outcome in patients with abortions or preterm labor. Statistical analysis was carried out using the two-sample *t*-test and Mann-Whitney U test for age, gravidity, total volume of distending media, distending media deficit, operative time, and period of follow-up. Fisher's exact test was used to analyze other parameters *P*_.05 was considered statistically significant. Values are expressed as mean±SD.

Results:

This study comprised 32 women with a diagnosis of complete vaginocervicouterine septum aged 19-25 years presented to our clinic with complaints of dyspareunia, dysmenorrhea, primary or secondary infertility, or chiefly recurrent pregnancy losses. They were randomized into two groups: group A underwent resectoscopic excision of the complete septum starting from the vaginal interoitus; group B underwent cold knife excision of the vaginal part followed by resectoscopic excision of the cervical and uterine parts. Table 1 summarizes demographic data of patients in both groups. Transabdominal ultrasonography revealed no associated renal anomalies. At laparoscopy, all patients displayed a single uterus with smooth fundal contour, double cervix and longitudinal vaginal septum. All patients had normal tubal perturbation test. Septum-related Superficial or deep female dyspareunia due to the vaginal part was reported in 6 (40%) and 7 (38.3%) cases in both groups without significant difference. All these cases showed good satisfaction after excision of the vaginal septum. On the other hand, scar-related dyspareunia was reported in 3(20%) and 11(61%) cases in both groups respectively (p:0.017). Preoperative pregnancy loss was reported in 8 (53.3%) and 12 (66.6%) cases in both groups respectively. Postoperatively, they conceived and achieved term live births or ongoing pregnancies in the third trimester in 6 (40%) and 9 (50%) in both groups respectively without a statistically significant difference. We recruited 4 (26.6%) and 5 (27.7%) infertile cases in both groups respectively. Some additional abnormal findings were associated with this anomaly in infertile patients: polycystic ovaries were diagnosed in 3 (20%) and 5 (27%) cases and different degrees of endometriosis in 2 (13.3%) and 4 (22.2%) cases in both groups respectively without statistically significant difference. These findings were treated simultaneously at laparoscopy. Among those infertile women, pregnancy was achieved in

1/4 (25%) and 2/5 (40%) cases in both groups without significant difference. However, laparoscopic procedures were concomitantly performed in most of these cases. Table 2 shows operative and postoperative details in both groups. We reported a significant less operative time and scar-related dyspareunia in group A.

Discussion:

Complete vaginocervicouterine septum is a relatively rare anomaly seen in practice. Classically, embryologists suggest that the upper part of the vagina develops from the paramesonephric ducts, while its lower part develops from the urogenital sinus. However, this assumption doesn't account for the even complete vaginal septum in conjunction with a complete uterine septum. It seems strange to have the same anomalies of two different origins in the same individual with proper alignment to each other. These unclassified anomalies calls into question the classic hypothesis of unidirectional (caudal to cranial) Müllerian development (13) and suggests an alternate developmental mechanism. In 1967, it was proposed that fusion begins at the level of the isthmus and proceeds simultaneously in both the cranial and caudal directions (14). Development of the uterine corpus is followed by resorption of the septum, which begins at the isthmus and proceeds in both directions. We think that this theory is a practical logic explanation for our findings despite being older than the traditional classification. We called this anomaly "unclassified" since the American Fertility Society (2) doesn't consider complete vaginocervicaouterine septum as a separate class. We think, like others (15), that the addition of a classification category allowing for alternative developmental models might now be appropriate.

Before starting this study, it was expected to face some technical problems due to leakage of glycine distending media at the time of resection of the vaginal septum. However, this

troubleshooting was negligible due to the ability of the vagina to distend easily unlike the endometrial cavity, and proximity of the septum to the exterior. Likewise, we tried using a monopolar electrode (hot knife) in some cases before this study. However, the resectoscopic approach has the advantage of inherent protection of the lateral vaginal walls by the ceramic end of the inner sheath, thus avoiding unintentional diathermy burn of the lateral vaginal walls. Moreover, hysteroscopic resection with fluid provides a better view of the longitudinal septum at high magnification (16).

For the cervicouterine septum, there is growing evidence that the modern surgical procedure of choice is hysteroscopic transcervical metroplasty combined with concurrent laparoscopy (1, 17-24). Sparing of the cervical part was recommended to minimize the risk of cervical incompetence in the subsequent pregnancy (20,23-24) However, we believe that resection of the cervical part makes the procedure safer, easier, and less complicated than preserving the cervical septum (25). In this study, hysteroscopic transection of the vaginal septum resulted in satisfactory results with less operative time and better patient satisfaction. This can be explained by the precise resection and proper hemostasis achieved with the resectoscope. Similarly, short recovery with quick return to normal activities was reported following resectoscopic excision of a vaginal septum (16). Interestingly, scar-related dyspareunia was significantly less in the resectoscopic group as previously demonstrated by others (16). This can be explained by the absence of sutures. On follow-up, a wide vagina with a perfectly healed incision was observed in a previous study (16). On the other hand, cold knife approach was followed by incomplete resection of the longitudinal vaginal septum in some studies (9,10).

In this study, we recruited 20 cases with pregnancy loss who postoperatively conceived and achieved term live births or ongoing pregnancies in the third trimester in 15 (75%) of them. These marvelous results were similarly obtained by others (26). All proposed mechanisms of first or second trimester pregnancy loss including mechanical expulsion, changing intrauterine pressure, stimulation of uterine contractility, or vascular insufficiency, can be overcome after metroplasty. Some studies underestimate the role of septate uterus in cases of recurrent pregnancy losses (6). One case had underwent resection of the vaginal septum with no treatment for the septate uterus and later delivered a viable infant (27). Large sample-sized studies are required to define the eimplication of septate uterus in cases of pregnancy loss.

We included 9 infertile cases who succeeded to achieve pregnancy in 3 (33.3%) of them after surgical treatment. Since laparoscopic procedures were concomitantly performed in most of these cases, we can't judge whether pregnancy was achieved due to either procedure. The association of this anomaly with infertility is unclear. The mechanism for infertility could include defective implantation, or associated endometriosis or tubal anomalies. We think that hysteroscopic resection of this anomaly in an otherwise normal infertile patient during endoscopic infertility work-up should be encouraged as metroplasy is a fast and relatively easy additive procedure.

The idea of resectoscopic excision of the vaginal septum is not new. Some case reports of a similar technique were found in the literature (16,28-29). This study demonstrated applicability of this approach for a larger scale of women. Moreover, it describes for the first time the extended technique for this specific anomaly of combined vaginocervicouterine septum. Based on results of this preliminary study, it seems that

resection of the vaginal septum in symptomatic women utilizing resectoscopic metroplasty makes the procedure faster with less possibility of scar-related dyspareunia than cold knife excision. Subsequently, it is recommended for all cases of complete vaginocervicouterine septum. Inclusion of this anomaly in the coming revised classifications of paramesonephric duct anomalies is recommended.

Table (1): Demographic data of the studied patients.

	Group A (15 cases)	**Group B (18 cases)**	**Significance P- value**
Age (years] (means ±SD] (range)	20.36±0.19 (19-31)	21.64±2.11(22-32)	NS
Parity (means ±SD] (range)	0.4±2.0(0-1)	0.3±1.0(0-1)	NS
Gravidity (means ±SD] (range)	2.03 ±1.41(1-4)	2.7 ±1.1(1-5)	NS
BMI (kg/m2) (means ±SD] (range)	19.1±5.0(14-25)	21.3±3.5(18-24)	NS
Infertility (No,%]	4 (26.6%)	5(27.7%)	NS
Dysmenorrhea (No,%]	3(20%)	2(11.%)	NS
Dyspareunia* (No,%]	4 (26.6%)	6 (33.3%)	NS
Early abortion (No,%]	1(6%)	2 (11%)	NS
Late abortion (No,%]	3(20%)	4 (22%)	NS
Preterm labor (No,%]	2(13.3%)	3 (16.6%)	NS

* Alone or with other complaints.

Table (2) Perioerative data in both groups

	Group A (15 cases)	**Group B (18 cases)**	**Significance P- value**
Operative time (min) (means ±SD] (range)	7±1.28 (5-8)	20.8±2.23 (18-23)	0.000
Significant operative bleeding	1(6%)	4(22%)	NS
Significant postoperative vaginal discharge	2 (13.3%)	7 (38.8%)	NS
Scar-related dyspareunia	3(20%)	11(61%)	0.017
Husband satisfaction	9 (60%)	9(50%)	NS

References:

1. Fedele L, Bianchi S. Hysteroscopic metroplasty for septate uterus. Obstet Gynecol Clin North Am 1995;22:473– 89.
2. American Fertility Society. The American Fertility Society classification of adnexal adhesions, distal tubal occlusion, tubal occlusion secondary to tubal ligation, tubal pregnancies, müllerian anomalies and intrauterine adhesions. Fertil Steril 1988;49:944–55.
3. Haddad B, Louis-Sylvestre C, Poitout P, Paniel B-J. Longitudinal vaginal septum: a retrospective study of 202 cases. Eur J Obstet Gynecol Reprod Biol 1997;74:197–9.
4. Acién P. Reproductive performance of women with uterine malformations. Hum Reprod 1993;8:122– 6.

5. Maneschi F, Parlato M, Incandela S, Maneschi M. Reproductive performance in women with complete septate uteri. J Reprod Med 1991;36:741– 4.
6. Heinonen PK. Complete septate uterus with longitudinal vaginal septum. Fertil Steril_ 2006;85:700–5.
7. Candiani GB, Fedele L, Candiani M. Double uterus, blind hemivagina, and ipsilateral renal agenesis: 36 cases and long-term follow-up. Obstet Gynecol 1997;90:26 –32.
8. Chang A,Siegel C, Moley K,Ratts V, Odem R. Septate uterus with cervical duplication and longitudinal vaginal septum: a report of five new cases. Fertil Steril 2004;81:1133– 6.
9. Le Ray C, Donnadieu AC, Gervaise A, Frydman R, Fernandez H.Management of ten patients with complete septate uterus: hystersocopic section of and obstetrical outcome. J Gynecol Obstet Biol Reprod 2006;35(8 Pt 1):797-803.
10. Joki-Erkkilä MM, Heinonen PK. Presenting and long-term clinical implications and fecundity in females with obstructing vaginal malformations. J Pediatr Adolesc Gynecol. 2003;16(5):307-12.
11. Darwish AM, Youssef AA. Screening sonohysterography in infertility. Gynecol Obstet Invest. 1999;48(1):43-7.
12. Darwish AM, Ahmad A, Mohammad AM. Cervical priming prior to operative hysteroscopy: a randomized comparison of laminaria versus misoprostol Human Reproduction 2004 ;19(10):2391-2394.
13. Buttram VC, Gibbons WE. Mullerian anomalies: a proposed classification. (An analysis of 144 cases). Fertil Steril 1979;32:140 –146.

14. Muller P, Musset R, Netter A, Solal R, Vincourd JC, Gillet JY. State of the upper urinary tract in patients with uterine malformations. Study of 133 cases. Presse Med. 1967 ;75(26):1331-6.
15. Pavone ME, King JA, Vlahos N, Septate uterus with cervical duplication and a longitudinal vaginal septum: a müllerian anomaly without a classification. Fertil Steril 2006;85:2, 494.e9 –10.
16. Montevecchi L, Valle RF. Resectoscopic treatment of complete longitudinal vaginal septum. Inter J Gynecol Obstet 2004; 84:65–70.
17. Israel R, March CM: Hysteroscopic incision of the septate uterus. Am J Obstet Gynecol 1984;1. 149(1): 66-73
18. DeCherney AH, Russell JB, Graebe RA, Polan ML: Resectoscopic management of mullerian fusion defects. Fertil Steril 1986; 45(5): 726-8.
19. March CM, Israel R: Hysteroscopic management of recurrent abortion caused by septate uterus. Am J Obstet Gynecol 1987; 156(4): 834-42
20. Rock JA, Murphy AA, Cooper WH. Resectoscopic technique for the lysis of a class 5 complete uterine septum. Fertil Steril 1987;48:495– 6.
21. Donnez J, Nisolle M: Hysteroscopic surgery. Curr Opin Obstet Gynecol 1992 Jun; 4(3): 439-46
22. Rock JA. Surgery for anomalies of the Mullerian ducts, In: Thompson JD, Rock JA, eds. Telined's operative gynecology. Philadelphia: W.W. Lippincott, 2003:705–52.
23. Daly, D.C., Tohan, N., Walters, C. Hysteroscopic resection of the uterine septum in the presence of a septate cervix. Fertil. Steril. 1983; 39,560–563.
24. Römer T, Lober R. Hysteroscopic correction of a complete septate uterus using a balloon technique. Hum Reprod. 1997;12(3):478-9

25. Parsanezhad ME, Alborzi, S, Zarei A, Dehbashi,S, Shirazi, LG, Rajaeefard, A, Schmidt EH. Hysteroscopic metroplasty of the complete uterine septum, duplicate cervix, and vaginal septum. Fertil Steril_ 2006;85: 1473–7.
26. Litta P, Pozzan C, Merlin F, Sacco G, Saccardi C, Ambrosini G.,Capobianco G, Dessole S. Hysteroscopic metroplasty under laparoscopic guidance in infertile women with septate uteri: follow-up of reproductive outcome. J Reprod Med 2004;49:274–8.
27. Duffy DA, Nulsen J, Maier D, Schmidt D, Benadiva C Septate uterus with cervical duplication: a full-term delivery after resection of a vaginal septum. Fertil Steril. 2004 Sep;82(3):766-7
28. Tsai EM, Chiang PH, Hsu SC, Su JH, Lee JN. Hysteroscopic resection of vaginal septum in an adolescent virgin with obstructed hemivagina. Hum Reprod1998;13:1500 –1501.
29. Cicinelli E, Romano F, Didonna T, Schonauer LM, Galantino P, Di Naro E. Resectoscopic treatment of uterus didelphys with unilateral imperforate vagina complicated by hematocolpos and hematometra: case report. Fertil Steril 1999;72:553 –555.

Section 2.b. Reconstructive Laparoscopic Surgery

2.b.1 **Evaluation of the impact of laparoscopic ovarian drilling on Doppler indices of ovarian stromal blood flow, serum vascular endothelial growth factor, and insulin-like growth factor-1 in women with polycystic ovary syndrome**

Ahmed F. Amin, Diaa-Eldeen M. Abd El Aal, Atef M. Darwish, Abdel-Raheim M. A. Meki.

Fertility Sterility Vol 79 No. 4 pp. 938-4,2003

2.b.2 **Risk of adhesion formation following microsurgical laparoscopic ovarian drilling: a comparative study.**

Darwish AM, AbdelAleem MA, Ismail AM

Gynecological Surgery 2009 May; Volume 6 Number 2, 135-141.

2.b.3 **Fertility after laparoscopic management of gynaecologic emergencies: the experience of a developing country.**

Atef M. Darwish, Mahmoud Zhakhera and Alaa A. Youssef

Gynaecological Surgery 2007;4,2, 85-90.

2.b.1 Evaluation of the impact of laparoscopic ovarian drilling on Doppler indices of ovarian stromal blood flow, serum vascular endothelial growth factor, and insulin-like growth factor-1 in women with polycystic ovary syndrome

Ahmed F. Amin, Diaa-Eldeen M. Abd El Aal, Atef M. Darwish, Abdel-Raheim M. A. Meki

Fertility Sterility Vol 79 No. 4 pp. 938-4, 2003

Introduction:

Polycystic ovary syndrome (PCOS) is characterized by infertility, oligomenorrhea, and hyperandrogenism (1). The first line of treatment is clomiphene citrate. If clomiphene citrate fails to induce ovulation, laparoscopic ovarian drilling (LOD) is offered (2). Angiogenesis within the reproductive system may be coordinated by gonadotropins and/or locally produced steroids and proteins. Vascular endothelial growth factor (VEGF) is a potent angiogenic factor that is expressed and secreted in the human ovary. It may have a role in cyclic angiogenesis and regulation of vascular permeability, which are critical for ovarian folliculogenesis. Abnormality in ovarian angiogenesis may contribute to anovulation and infertility and may be involved in the increased predilection to ovarian hyperstimulation in PCOS (3). A reduction has been observed in the incidence of OHSS after LOD in cases of PCOS (4,5). This may be an advantage for women with PCOS, who will receive gonadotropins for IVF.

Increased expression of VEGF has been described in the hyperthecotic stroma of polycystic ovaries (6,7), which have been shown to be associated with increased ovarian stromal blood flow (8). Another locally produced protein, insulin-like growth factor I (IGF-1), may play a role in human follicular development and steroidogenesis. Abnormalities of IGF-1 may contribute to a disturbed follicular development in PCOS (9). The present study aims to determine the serum levels of VEGF and IGF-1, hormonal profile, and Doppler blood flow indices in women with clomiphene-resistant PCOS

Materials and methods:

The study included 25 infertile patients with clomiphene-resistant PCOS (group 1) (they had failed to ovulate after being given 150 mg/d during six consecutive cycles, for 5 days

each). Diagnosis of PCOS was based on clinical manifestations (oligomenorrhea, hirsutism, and obesity) and standard ultrasound criteria (10). Twenty fertile women with ovulatory cycles and normal ovaries (by ultrasound examination) were used as a comparison group (Group 2). LOD was carried out in the early follicular phase of menstrual cycle. Each ovary was cauterized at four points, for 4 seconds, using 40 W of power with a high-frequency monopolar microneedle, regardless of the size of the ovary. The whole length of the needle (10 mm) was inserted into the ovary to ensure stromal damage.

Ultrasound examination was done using an ultrasound duplex system (Acuson, Mountain View, CA). Doppler examination was done using a 5-MHz transvaginal probe with pulsed and color Doppler facilities. Examinations were per formed at the beginning of a menstrual cycle before LOD and in the early follicular phase of the first postoperative cycle. Areas of maximum color intensity, representing the greatest Doppler frequency shifts, were selected for pulsed Doppler examinations. The resistance index (RI) and pulsatility index (PI) were used as measures of blood flow impedance distal to the point of sampling. All examinations were performed before midday to reduce the effects of diurnal variations in blood flow (11).

On the morning of the operation, a blood sample was taken from each patient before LOD, and the second sample was taken in the early follicular phase of the first postoperative cycle after LOD. An early follicular phase blood sample was taken from comparison group. Serum LH and FSH were assayed by using an ELISA kit (Medix Biotech, Inc., San Carlos, CA) with a sensitivity of <0.5 mlU/mL. Assay of VEGF was done by using an ELISA kit (Cyt Immune Sciences, Inc., College Park, MA) with a sensitivity of 0.195 ng/mL. Testosterone was measured using an ELISA kit (Orion Diagnostica, Finland) with a sensitivity of 0.05 + 0.02 ng/mL. Solid-phase RIA with a sensitivity of 12 ng/mL was used

to determine serum IGF-1 (I125 kit; Immunotech, France). Estradiol was also measured using solid-phase RIA (I125 kit; Diagnostic Products Corp., Los Angeles, CA) with a sensitivity of 6 pg/mL. All samples were run on the same assay. Our internal ethics committee approved the research protocol. Informed consent was obtained from all studied patients and the comparison group. Comparisons of the measured parameters between groups were carried out by Student's / test. Comparison before and after LOD was done using paired t test. Linear regressionanalysis was done to assess any correlation between the different variables.

Results:

Before LOD, the serum levels of LH, T, VEGF, IGF-1, and LH-FSH ratio were significantly higher in group 1 than in group 2. The serum levels of LH, T, VEGF, as well as LH-FSH ratios were significantly lower, whereas FSH was significantly higher in group 1 after LOD than before LOD (Table 1). Vascular endothelial growth factor was positively correlated with IGF-1, T, and LH in group 1 before LOD. On the other hand, VEGF was positively correlated with only T and LH in the same group after LOD (Table 2).

Discussion:

In the current study, the serum levels of VEGF, IGF-1, LH, and T were significantly higher in group 1 before LOD than in group 2. Vascular endothelial growth factor was positively correlated with IGF-1, LH, and T in group 1 before LOD. Our results revealed that ovarian stromal PI and RI were significantly lower in women with PCOS compared with in healthy women. Doppler blood flow velocities rose in parallel with serum VEGF levels.

Table 1. Serum concentrations of hormones (mean ± SE) in patients with PCOS (before and after LOD) as compared with concentrations in healthy, fertile women.

Variables	Healthy women (n = 20)	Women with PCOS (n = 25)	
		Pre-LOD[a]	Post-LODb
LH (IU/L)	8.8 ± 0.48	14.23 ± 0.82 C	9.61 ± 0.40 C
FSH (IU/L)	7.84 ± 0.45	6.45 ± 0.42	8.78 ± 0.53 C
E2 (pg/mL)	62.25 ± 4.67	78.25 ± 10.68	79.67 ± 6.45
T (nmol/L)	1.35 ±0.07	4.77 ± 0.32 C	2.61 ± 0.2T
LH-FSH ratio	1.13 ±0.04	2.28 ±0.17 C	1.16 ± 0.18 C
VEGF (ng/mL)	2.39 ± 0.09	4.79 ±0.18 C	2.96 ± 0.1 l C
IGF-1 (ng/mL)	186.65 ±9.55	253.15 ± 13.42d	226.47 ± 11.65

a Significance marks in this column refer to comparison of pre-LOD and control groups.

b Significance marks in this column refer to comparison of post-LOD and pre-LOD groups.

C P<0.001.

d p<0.01.

Table 2. Correlation of VEGF serum concentrations with IGF-1 and hormones in patients with PCOS before and after LOD.

	Pre-LOD		Post-LOD	
Comparison	r	P	r	P
VEGF vs.				
IGF- 1	0.41	<.05	0.15	NS
LH	0.61	<.001	0.47	<.05
FSH	0.13	NS	0.22	NS
T	0.71	<.001	0.55	<.003
Estradiol	0.08	NS	0.21	NS

Note: NS = not significant

Table 3. Doppler indices (mean±SE) in normal ovaries and in PCOS befpre and after LOD.

Doppler indices	Normal women (n = 20)	PCOS (n = 25)	
		Pre-LODa	Post-LODb
Right ovarian stromal vasculature			
RI	0.87 ± 0.09	0.77 ±0.12C	0.83 ±0.07C
PI	2.98 ± 0.77	2.01 ± 0.77C	2.88 ± 0.67C
Left ovarian stromal vasculature			
RI	0.89 ± 0.09	0.82 ± 0.09C	0.87 ± 0.07d
PI	3.75 ±0.98	2.66 ± 1.00C	3.31 ± 0.88C

a Significance marks in this column refer to comparison of pre-LOD and control groups.

b Significance marks in this column refer to comparison of post-LOD and pre-LOD groups.

C <0.001.

These findings are consistent with results of previous studies (7,12). Increased VEGF production in women with PCOS may be the result of elevated LH (3). The rise in VEGF may cause increased ovarian stromal vascularity and may explain the higher risk of OHSS in women with PCOS (10). The increase in IGF-1 in women with PCOS compared with in healthy women was previously reported (13). It has been proposed that the elevated LH may increase IGF-1 and androgen production (14). Insulin-like growth factor I also induced LH receptors and, consequently, LH-mediated angiogenesis (15). Moreover, IGF-1 induces VEGF-mRNA and protein production (1).

Laparoscopic treatment is increasingly recommended as an early treatment option for women with clomiphene-resistant PCOS. The reduction in serum LH levels after LOD is reported to be the main mechanism by which reproductive outcome is improved (16).

The levels of VEGF, LH, and T in group 1 after LOD were also statistically significantly lowered by LOD. Reduction in LH and T after LOD has been reported by others (17). However, Tulandi et al. (2) did not find a significant difference in serum VEGF levels before and after laparoscopic treatment. This difference may be because they applied the electric current for only 2 seconds (4 seconds in our study), and they measured serum VEGF 2 months after LOD (first postoperative cycle in our study).

The reduction in LH and T resulting from LOD may explain the reduction of VEGF after LOD. These reductions in VEGF levels may be the cause of increased Doppler indices suggesting corrected stromal blood flow. This may reduce OHSS.

In conclusion, VEGF and IGF-1 levels are higher in women with PCOS than in healthy women. Laparoscopic ovarian drilling reduced VEGF, as well as LH and T and also ovarian blood flow velocities in PCOS. We suggest that LOD may be a first choice for treatment of a woman with clomiphene-resistant PCOS; this avoids the risk of developing OHSS if she will need gonadotropin stimulation later.

References:

1. Frank S, Adams J, Mason H. Ovulatory disorders in women with polycystic ovary syndrome. Clin Obstet Gynecol 1985; 12:605-32.

2. Tulandi T, Saleh A, Morris D, Jacobs HS, Payne NN, Tan SL. Effects of laparoscopic ovarian drilling on serum vascular endothelial growth factor and on insulin responses to the

oral glucose tolerance test in women with polycystic ovary syndrome. Fertil Steril 2000;74:585-8.

3. Geva E, Jaffe RB, Edward WE. Role of vascular endothelial growth factor in ovarian physiology and pathology. Fertil Steril 2000;74:424-38.

4. Rimington MR, Walker SM, Shaw RW. The use of laparoscopic ovarian electrocautery in preventing cancellation of in-vitro fertilization treatment cycles due to risk of ovarian hyperstimulation syndrome in women with polycystic ovaries. Hum Reprod 1997; 12:1443-7.

5. Colacuci N, Zullo F, DeFraciscis P. In vitro fertilization following laparoscopic ovarian diathermy in women with polycystic ovarian syndrome. Acta Obstet Gynecol Scand 1997;76:555-8.

6. Kamat BR, Brown LF, Manseau EJ, Senger DR, Dvorak HF. Expression of vascular permeability factor/vascular endothelial growth factor by human granulosa and theca lutein cells. Role in corpus luteum development. Am J Pathol 1995; 146:157-^65.

7. Agrawal R, Sladkevicius P, Engmann L, Conway GS, Poyne NN, Bekis J, et al. Serum vascular endothelial growth factor concentrations and ovarian stromal blood flow are increased in women with polycystic ovaries. Hum Reprod 1998; 13:651-5.

8. Aleem FA, Pridanic M. Transvaginal color Doppler determination of uterine blood flow characteristics in PCOD. Fertil Steril 1996;6:515-6.

9. Buyalos RP. Insulin-like growth factors: clinical experience in ovarian function. Am J Med 1995;98(Suppl A):IA-55S-66S.

10. Adams J, Franks S, Poison DW, Mason HD, Abdullwahid N, Tuker M. Multifollicular ovaries: clinical and endocrine features and response to pulsatile gonadotropin releasing hormone. Lancet 1985;2:1375-9.

11. Zaidi J, Jurkovic D, Campbell S, Pittrof R, McGregor A, Tan SL. Description of the circadian rhythms in uterine artery blood flow during the pre-ovulatory period. Hum Reprod 1995; 10:1624-46.

12. Loverro G, Vicino M, Lorusso F, Vimercati A, Greco P, Selvaggi L. Polycystic ovary syndrome: relationship between insulin sensitivity, sex hormone levels, and ovarian stromal blood flow. Gynecol Endocri-nol 2001; 15:142-9.

13. Dessel THJ, Lee PD, Faessen G, Fauser BC, Giudice LC. Elevated serum levels of free insulin-like growth factor-1 in polycystic ovary syndrome. J Clin Endocrinol Metab 1999;84:3030-5.

14. Bergh C, Carlsson B, Olsson J, Sellesskog U, Hillensjo T. Regulation of androgen production in cultured human theca cells by insulin-like growth factor-1 and insulin. Fertil Steril 1993;56:323-31.

15. Findlay JK. Angiogenesis is reproductive tissues. J Endocrinol 1986; 111:357-66.

16. Urman B, Fluker M, Yuen BH. The outcome of in vitro fertilization and embryo transfer in women with polycystic ovarian syndrome failing to conceive after ovulation induction with exogenous gonadotrophins. Fertil Steril 1997;57:1269-73.

17. Felemban A, Tan SL, Tulandi T. Laparoscopic treatment of polycystic ovaries with insulated needle cautery: reappraisal. Fertil Steril 2000; 73:266-9.

2.b.2 Risk of adhesion formation following microsurgical monopolar laparoscopic ovarian drilling: a comparative study

A. M. Darwish, M. A. AbdelAleem, A. M. Ismail

Gynecological Surgery 2009; Volume 6 Number 2, 135-141.

Introduction:

Polycystic ovarian disease (PCO) is currently considered as possibly the most frequent cause of female infertility (1). Despite being variable according to age and population, the prevalence of PCOS has been reported in 37.3% among women with self-reported oligomenorrhoea and/or hirsutism (2). In modern practice, the only allowed surgical method of ovulation induction for women with clomiphene citrate-resistant polycystic ovarian syndrome (PCOS) is laparoscopic ovarian drilling (LOD). Drilling aims to destroy a part of the ovarian stroma, which may help correct endocrine abnormalities and trigger ovulation. LOD. LOD has been evaluated in well-designed trials, may be an alternative to gonadotropins (GTs) (2). A systematic review of four randomized controlled trials (RCTs) found no significant differences between LOD after 6–12 months follow-up and 3–6 cycles of ovulation induction with GTs in cumulative pregnancy rate (OR 1.42; 95% CI 0.84 to 2.42) or miscarriage rate (OR 0.61; 95% CI 0.17 to 2.16) in women with clomiphene citrate-resistant PCOS (3). There was insufficient evidence to support any one surgical technique over another relating to adhesion formation e.g. laser, monopolar or bipolar diathermy(3). Since a long time, reasonable ovulation rates between 53% and 92% have been reported following LOD (4,5). Evidence-based advantages of LOD of PCO include minimal risk of ovarian hyperstimulation syndrome (6) and less cost if compared to GTs with comparable ovulation and pregnancy rates. Reduced multiple pregnancy rates is a clear superiority point of LOD over GTs (7-9). In recent years, due to the previously mentioned advantages, the practice of LOD is increasing world wide to the extent that it became one of the most commonly performed fertility-enhancing laparoscopic operation in many centers particularly in the developing countries. Many surgeons are underestimating the possible risks of LOD which include all the risks associated with laparoscopic surgery,

as well as the potential for pelvic adhesions (3) and the very rare possibility of ovarian atrophy. Studies on post-drilling adhesions mainly focus on second-look laparoscopy for infertile women (10-12). Frequent cases of pregnancy following LOD make a false sense of safety of LOD as regard remote sequele including adhesion formation. Many respectable societies interested in reproductive surgery recommend construction of unbiased studies to evaluate the best laparoscopic tool for drilling as well as adhesions formation risk following LOD (13). This study was designed to determine the prevalence, extent, and location of adhesion formation following microsurgical monopolar LOD among fertile and infertile women with clomiphene resistant PCO.

Materials and methods:

This longitudinal cohort follow up study was conducted between November 2004 and October 2007 at the Endoscopy Unit of the Woman's Health University Center, Assiut University, Assiut, Egypt and comprised 347 PCO patients scheduled for LOD as a treatment option for clomiphene-resistance on maximal dosing (150 mg daily for 5 days, starting on day 2) (14). The diagnosis of PCOS was based on the clinical and biochemical evidence of androgen excess and PCO picture on transvaginal ultrasonography following the Rotterdam ESHRE/ASRM-Sponsored PCOS consensus workshop group sonographic description (15). The study was approved by the institutional review board (IRB) of the Faculty of Medicine. All patients gave a clear written consent to participate in this study. Preoperative thorough history taking and careful general and abdominal examinations were done in all cases. Other factors of infertility were within normal including semen analysis, hysterosalpingography (HSG), normal serum prolactin and thyroid hormones. Patients with evidence of general or local abdominal contraindications to laparoscopy were excluded from this study (4 cases) due to previous intestinal resection anastomosis in two cases,

extensive abdominal incisions in one case and congestive heart failure in one case. Additional exclusion criteria were a history of pelvic surgery (16 patients), occurance of intraoperative complications (3 cases) i.e. unusual ovarian surface or ovarian ligament bleedings neccessitating excessive diathermy hemostasis or suturing, postoperative pelvic infection or hematoma as diagnosed by transvginal ultrasonography (one case), or non-use of prophylactic antibiotics (2 cases). Moreover, 75 cases were excluded from the study as the intra-operative panoramic screening revealed concurrent pelvic adhesions (33 cases), typical or atypical endometriosis (21 cases), small simple ovarian cysts (9 cases), and paraovarian or paratubal cysts (12 cases). The remaining 246 cases were subjected to bilateral LOD utilizing standard triple puncture technique only done by the authors mainly the first one. All surgeons were instructed to strictly follow microsurgical principles (16) in the form of minimizing tissue trauma particularly surface ovarian burn induced by the secondary coagulation, drilling of the antimesentric surface only, firing the electrode after surface penetration using fine needles only for 5 seconds with a current at a 30-W power setting to make a puncture that was approximately 4 mm in diameter and 6–8 mm deep, meticulous hemostasis, proper suction-irrigation of the pelvis, and leaving 500-1000 cc of lactated ringer's solution intraperitoneally at the end of the procedure. The numbers of drills was tailored according to the ovarian size, with a range of 4-6 drills/ovary. All operations were done in nearly the same manner. Preoperatively, all patients received prophylactic antibiotics and were discharged within few hours after the procedure.

All cases were followed up for at least 6 months with monitoring of regularity of the cycles, occurrence of ovulation, and ultimately pregnancy. Ovulation monitoring started the subsequent cycle following LOD. Follicular development was monitored using transvaginal ultrasononography from day 10 of the cycle. Human chorionic gonadotropin at dose of

5000 IU was used to trigger ovulation when at least one follicle exceeding 18mm was noted. Occurrence of ovulation was proved by either sonographic detection of corpus luteum or estimation of high luteal phase LH. If ovulation was not achieved, ovulation stimulation was started on the D2 with clomiphene citrate 100 mg/day of the subsequent cycle. Pregnant cases were offered the usual low-risk antenatal care till delivery (extended follow-up period). If there was an indication for cesarean section (group A, 22 cases), the uterus was exteriorated after closure of the uterine incision. Meticulous comments on adnexal adhesions guided by the AFS Classification (17). On the other hand, infertile patients for 6 months were counseled for a second-look laparoscopy provided normal or reasonable other factors of infertility. If the patient accepted, she was subjected to a second-look laparosocopy (group B, 29 patients) where the pelvis was meticulously evaluated for any evidence of adhesions as in group A. In both groups, adhesions were evaluated for the side (right or left), site (periovarian, tuboovarian, peritubal, Douglas, adnexo-uterine, adnexo-lateral pelvic wall),and extent (mild, moderate, and severe). Microsurgical adhesiolysis was performed. Data were collected and analyzed with SPSS version 11 (SPSS, Inc., Chicago, IL, USA) and expressed as mean±standard deviation (SD). Statistical methods were applied including descriptive statistics (frequency, percentage, mean and SD) and tests of significance (the incidence and grade of adhesions in both groups were compared by x2 statistics or Fisher's exact test, as appropriate). A p value <0.05 was considered statistically significant.

Results:

This study comprised 347 cases with PCO planned for LOD. To assess the sole effect of LOD on adhesion formation, only 51 eligible cases were subjected to either cesarean section or second-look laparoscopy. Figure (1) demonstrates the flowchart of cases

throughout the study. Demographic data of those 51 cases are shown in table (1). Operative details in both groups are shown in table (2). Regularity of menstrual cycles was regained in 45/67 (67%) and 65/99 (65.5%) in groups A and B respectively (p 0.5). Sonographically documented ovulation supported by elevated luteal phase serum progesterone was achieved in 44/67 (65.6%) and 41/99 (41.4%) cases in both groups respectively (p 0.002). However, proved ovulation rose up to 62/99 (62.6%) in group B just on 100 mg clomiphene citrate therapy started from day 2 of the subsequent cycle without statistically significant difference if compared to group A (p 0.7).

Figure (1): Flowchart of the study population.

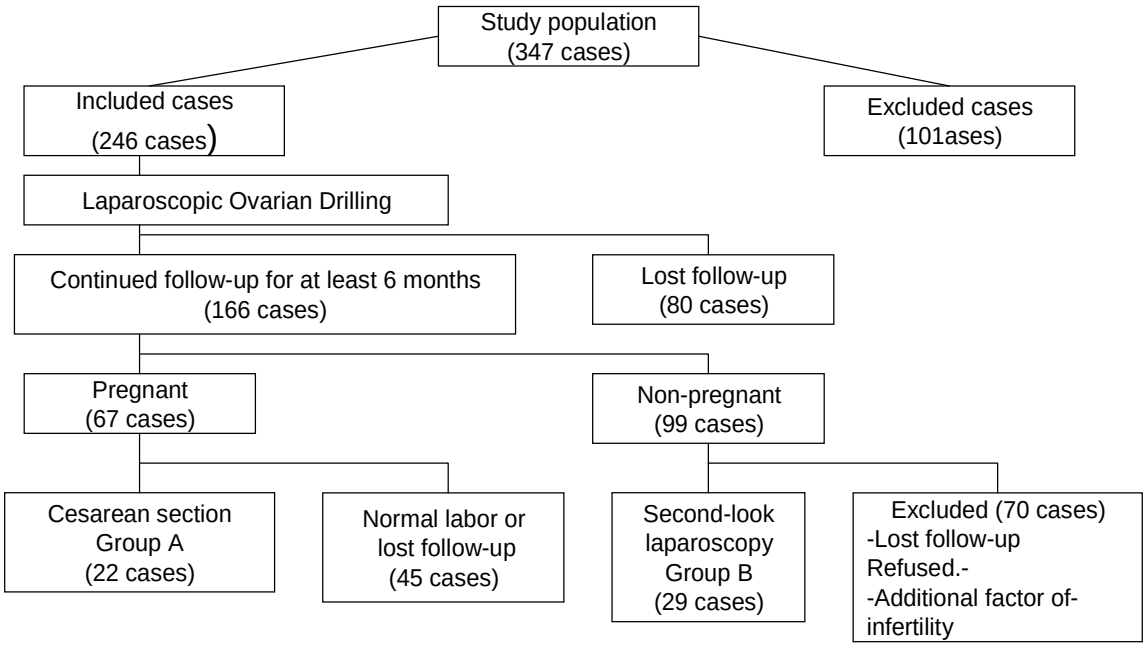

Those patients who did not conceive within six months underwent second-look conventional laparoscopy with the notable findings of a high percentage of post operative adhesions. We succeeded to perform it in only 29 (29 %) out of 99 infertile cases utilizing conventional laparoscopy**.** Totally in both groups, adhesions were diagnosed in 40 cases (78.4%); 15(68.1%) and 25 (86.2%) cases in groups A and B respectively without a statistically significant difference (p:0.21). In 29(56.8%) cases in both groups, adhesions were diagnosed on both sides (right and left adnexae) divided as 8(36.3%) and 21(72.4%) in groups A and B respectively with a statistically significant difference (p: 0.01).

Table (1): Demographic data of the studied patients.

	Group A (22 cases)	**Group B (29 cases)**	**P- value**
Age (years] (means ±SD] (range)	26.36±2.19 (19-31)	27.64±4.21(22-32)	NS
Parity	0.7±3.0(0-2)	0.4±1.0(0-1)	NS
BMI (kg/m2) (range)	26.1±5.0(17-40)	27.3±4.5(18-39)	NS
Infertility Period (years) (means ±SD] (range) Primary, n (%) Secondary, n (%)	 4.27±1.35 (1-8) 19(86.4%) 3(13.6%)	 5.09±2.40 23(79%) 6(21%)	 NS NS NS
Menstrual cycle pattern Regular, n (%) Oligomenorrhea, n (%) Amenorrhea, n (%)	 3(13.6%) 16(72.8%) 3(13.6%)	 3 (10.5%) 22(75.8%) 4(13.7%)	 NS NS NS
LH:FSH ratio(range)	2.2 (0.6–3.2)	2.3 (0.6–3.5)	NS
Interval from primary LOD(months) (means±SD] (range)	16.50±10.11(11-22)	5.40±5.63 (6-14)	0.001

Detailed demonstration of adhesion formation in both groups is shown in table 3 strictly following the AFS classification. We reported important adhesion sites that are not included in AFS classification which are Douglas pouch adhesions (2 cases), tuboovarian adnesions (14 cases), and adnexouterine adhesions (4 cases) in both groups. Collectively, periovarian adhesions were diagnosed in 47/51 (92%) of cases in both groups. No information was obtained from patients that delivered vaginally or were lost to follow-up. In group B, after microsurgical lysis of 2 cases with Douglas pouch fine adhesions, pregnancy was achieved within 3 months.

Table (2): Distribution of adhesions among both groups according to AFS classification.

Adhesions		**Right adnexa**			**Left adnexa**		
		Group A (22 cases)	Group B (29 cases)	Total (51 cases)	Group A (22 cases)	Group B (29 cases)	Total (51 cases)
None		8 (36.3%)	7(24%)	15(29.4%)	13 (59%)	8(27.5%)	21(41%)
Filmy	Periovarian	8 (36.3%)	10 (34.4%)	18(35.2%)	7 (31.8%)	10 (34.4%)	17(33.3%)
	Peritubal	1(4.5%)	1(3.4%)	2(3.9%)	1(4.5%)	2(6.8%)	3(5.8%)
	Douglas pouch	0	1(3.4%)	1(1.9%)	0	1(3.4%)	1(1.9%)
	Tubo-ovarian	0	1(3.4%)	1(1.9%)	0	1(3.4%)	1(1.9%)
Dense	Periovarian	6	3	9	1(4.5%)	2(6.8%)	3(5.8%)
	Peritubal	0	2(6.8%)	2(3.9%)	0	1(3.4%)	1(1.9%)
	Tubo-ovarian or adnexo-uterine	0	3(10.3%)	3(5.8%)	0	4(13.7)	4(7.8%)

Discussion:

LOD for PCO is a continuous dilemma that requires more studies. One of the advantages of LOD over gonadotrophin therapy (GT) is concomitant diagnosis and treatment of any associated lesions that may attribute to the patient's problem of infertility. This is clear in this study where associated fertility-jeopardizing problems were diagnosed in 75 (21.6%) out of 347 PCO patients who were excluded. Moreover, a diagnostic hysteroscopy can be easily performed at the end of the procedure to evaluate the endometrial cavity in selected cases. Lastly, it is evident that LOD is more cost-effective than GTs which represents a valuable advantage particularly in developing countries with limited resources where GT therapy is more expensive and is not covered by most of the health insurance systems. However, LOD has virtually been abandoned by reproductive endocrinologist as medical therapy for PCO has improved. Postoperative adhesion formation is a potential complication in up to 85% of patients (18). Moreover, there are ongoing concerns about long term effects of LOD on ovarian function (19). Ovarian reserve assessed by hormonal levels and ultrasonography seems to be lower in the LOD than in the PCOS group without LOD in a recent study (20). This risk of damaged ovarian reserve could be minimized if LOD is restricted to patients with high preoperative LH level as demonstrated in a retrospective cohort study (21). The influence of LOD on age of menopause onset is unclear (22).

In this study, 22 women who conceived within six months following LOD and subjected to cesarean section we included, to test the pattern of adhesions among those women who get pregnant following LOD. Lack of correlation of adhesions to pregnancy rate was previously reported (10). Occurrence of pregnancy is not a grantee that LOD is a safe procedure if adhesion formation is concerned. It is well-known that adhesions don't always affect fertility.

Since the ovaries are paired organs, the doubled probability of pregnancy would dilute the effect of adhesions on reproductive performance. Unilaterality of adhesions is another factor supported by some studies which demonstrated that adhesion formation was more on the left side than the right side (23). Moreover, most of adhesions seen in group A were filmy and periovarian, except one case of peritubal dense adhesions. Contrarily, in group B, peritubal, tuboovarian or adnexouterine dense adhesions were reported which would explain pregnancy failure in this group.

In group A, pregnancy might have been occurred due to the site and consistency of these adhesions and the unilaterality of adhesions in 5 cases which gives a chance for pregnancy from the other side provided good ovulation. Thus, thin periovarian adhesions are the least adhesions that would affect fertility. Periovarian adhesions would seriously jeopardize fertility whenever the whole ovary is entirely entrapped to the extent that ovulation process is hindered. This concept is supported by a pilot study (10), where periovarian adhesions of variable severity were diagnosed in 100% of cases at second look laparoscopy. However, the authors reported seven of eight women (87.5%) spontaneously conceived eight singleton pregnancies without any further therapy.

Second-look laparoscopy is a difficult decision for many patients who are already psychologically depressed due to prolonged period of infertility. This is clear in this study; where second-look laparoscopy was performed in only 29 (29 %) out of 99 infertile cases utilizing conventional laparoscopy. To increase acceptability of patients to this procedure, we would suggest inclusion of minilaparoscopy (endoscopes ranging from 2-5 mm in diameter) during preoperative counseling as it could be easily done under local infiltration as an office procedure. In a recent study utilizing minilaparoscopic second-look laparoscopy (23), only six patients (6.2%) decided to withdraw from a study including 96

cases and did not undergo the second-look procedure. Despite being in its infancy, microlaparoscopy (endoscopes of < 2 mm in diameter) is a promising out-patient procedure that could be performed under local anesthesia with mild sedation (24). Based on these data, it is recommended to incorporate second-look microlaparoscopy in the counseling of patients planned for LOD in the near future to increase acceptability for second-look if pregnancy could not be achieved despite proper ovulation.

In this study, we reported important adhesion sites that are not included in the AFS classification (17) particularly Douglas pouch adhesions (2 cases), tuboovarian adnesions (14 cases), and adnexouterine adhesions (4 cases). It is not clear whether the adhesions found were significant from a fertility standpoint as the grading system does not address them. Nevertheless, after microsurgical lysis of the 2 cases with Douglas pouch fine adhesions in group B, pregnancy was achieved within 3 months. This can be explained by possible interference of this type of adhesions with ovum pick up. Moreover, tuboovarian or ovarian fossa adhesions have no place in the AFS classification. Likewise, adnexouterine or adnexopelvic wall adhesions are reported under the heading of other findings but are not included in the classification. Collectively, these sites represented 20 (50%) out of 40 cases of adhesions in our study without finding a suitable score based on the AFS classification. Data presented in this study are very preliminary and call for more extensive studies. A more detailed classification has been published by the Adhesion Scoring Group (25) which was proposed to be a more comprehensive scoring system based on evaluation of 23 individual locations in the abdominal cavity for severity and extent of total area or length. However, it seems to be complicated and again missing important items like adnexouterine or tuboovarin adhesions as well as ovarian fossa adhesions. In this study, we didn't follow

it as we didn't find any further published studies testing it in contrast to the AFS classification.

Post-drilling adhesion formation may occur in 30 to 100% of patients undergoing LOD (22) which represents a real limiting factor for LOD. Table (3) summarizes the results of this study versus examples of the published studies (10,23,26-32) on postdrilling adhesions. It is clear that the idea of evaluating post-drilling adhesions by second-look is not new. Despite this plethora of publications, recent recommendations of fertility-interested societies call for more well-designed unbiased studies on adhesion formation following LOD (13). If compared to other studies, it is evident that the rate of adhesions in our population is relatively high. However, in only 8% of cases, adhesions were diagnosed between the ovary and the adjacent organs. This positive finding of LOD highlights the importance of following microsurgical principles during reconstructive adnexal laparoscopic surgery. Most of the published studies focus on ovulation and pregnancy rates following LOD (9) rather than evaluating the safety of this invasive procedure that destroys the intact surface epithelium of the ovary to have an access to the stroma. This study was designed to be specific, informative and practical, that is why any contributing factor that would predispose to adhesion formation (101 cases, 29.1%) was excluded. This point is missing in many published studies on LOD (11,12). A well designed recent study (23) focused on demonstrating preferential spread of adhesions more on the left side and attributed this pattern to endometriosis, but didn't stress on the type of adhesions common after LOD. Since this study is interested in evaluating the technique of microsurgical monopolar LOD per se, ; 22 women who conceived within six months following LOD and subjected to cesarean section cases were quoted. It is important to know the distribution of adhesions among cases of group A to highlight the type of adhesions that would poorly

affect fertility. The reported high prevalence of periovarian adhesions in this study (92%) is great evidence that LOD is an invasive procedure that destroys the intact ovarian surface epithelium. Even if microsurgical principles are followed, an inevitable inherent high incidence of periovarian adhesions would be anticipated due to the monopolar electrode firing on direct contact with the ovarian surface with subsequent secondary coagulation. An important issue in this study is to evaluate the prevalence of adhesions among patients in a developing country set up.

Nevertheless, limitations of this study are many. Both strict inclusion criteria and high numbers lost to follow-up weaken the collected data. An attempt was made to draw conclusions from the comparisons with 2/3's of one group excluded from consideration. These 51 women with adhesions have suitable follow up out of a total of 246 for a 21% known outcome figure (low sample size). It would be hard, therefore, to generalize to the entire group from such a sample other than to say that adhesions are common. Lastly, comparisons were made between groups with a dissimilar endpoint.

Since a long time, it has been suggested that LOD is advised only when hormonal therapy failed or if the patient is at high risk of hyperstimulation or multiple pregnancy (31). The unequivocal high rate of adhesion formation following LOD shown in a recent study suggested the importance of undertaking complete and comprehensive medical therapy before proceeding with surgical treatment (23). In our study, despite we were restricted to microsurgical principles; our data are also alarming against LOD. More research should be seriously constructed to focus on different techniques that would make LOD as valuable as possible without the nightmare of adhesion formation for example evaluating bipolar fine needle drilling approach as compared to bipolar hydrolaparoscopic approach (33). In conclusion, the documented high prevalence of adhesions among

infertile as well as women who conceived following LOD is an adding evidence to the established risk of post-LOD adhesion formation. Following microsurgical principles would minimize the risk of these adhesions except periovarian adhesions. There is a bad need for studies on more refinement of LOD to make it as less adhesiogenic procedure as possible.

Table (3): Prevalence of postdrilling adhesions in this study versus some published studies.

Authors	Year	Sample size	Adhesions/Second look (%)	Remarks
Weise et al (26)	1991	39	7/26(26.9%)	-
Guergan et al (27)	1991	7	6/7 (85.7%)	-
Dabirashrafi et al (28)	1991	31	2/12 (16.6%)	Mild to moderate
Naether and Fischer (29)	1993	199	12/62 (19%)	the incidence reduced to 16.6% with the use of abdominal lavage.
Naether et al (30)	1993	133	7/26(26.9%)	-
Grenblatt and Casper (10)	1993	8	8/8(100%)	7/8 (87.5%) got pregnant
Saravelos and Li (31)	1996	21	7/21 (33%)	Unilateral: 3/21(14%) Bilateral: 4/21(19%)
Felemban et al (32)	2000	112	4/15(26.6%)	Periovarian adhesions
Mercorio et al (23)	2007	90	54/90 (60%)	Unilateral:25/54 (46.3%). Bilateral: 29/54 (53.7%)
Current study	2008	347	40/51(78.4%)	Unilateral:11 (27.5%) Bilateral: 29(56.8%) Periovarian: 47/51(92%)

References:

1. Gleicher N, Barad D. An evolutionary concept of polycystic ovarian disease: does evolution favor reproductive success over survival? Reproductive BioMedicine Online 2006;12(5):587-589.

2. Taponen S, Ahonkallio S, Martikainen H, Koivunen R, Ruokonen A, Sovio U, Hartikainen AL, Pouta A, Laitinen J, King V, Franks S, McCarthy MI, Järvelin MR. Prevalence of polycystic ovaries in women with self-reported symptoms of oligomenorrhoea and/or hirsutism: Northern Finland Birth Cohort 1966 Study. Hum Reprod. 2004 May;19(5):1083-8.

2. Urman B, Yakin K. Ovulatory disorders and infertility. J Reprod Med. 2006 51(4):267-82.

3. Farquhar C, Vandekerckhove P, Arnot M, Lilford R. Laparoscopic "drilling" by diathermy or laser for ovulation induction in anovulatory polycystic ovary syndrome. Cochrane Database Syst Rev 2000;(2):CD001122. Update in: Cochrane Database Syst Rev 2001;(4):CD001122.

4. Gjonnaes H. Polycystic ovarian syndrome treated by ovarian electrocautery through the laparoscope. Fertil Steril 1984;41:20.

5. Daniell JF, Miller W. Polycystic ovaries treated by laparoscopic laser vaporization. Fertil Steril 1989;51:232.

6. Amin AF, Abd el-Aal DE, Darwish AM, Meki AR. Evaluation of the impact of laparoscopic ovarian drilling on Doppler indices of ovarian stromal blood flow, serum vascular endothelial growth factor, and insulin-like growth factor-1 in women with polycystic ovary syndrome. Fertil Steril. 2003,79(4):938-41.

7. Kaya H, Sezik M, Ozaya O. Evaluation of a new surgical approach for the treatment of clomiphene-resistant infertility in polycystic ovary syndrome: laparoscopic ovarian multi-needle intervention. Minim Invasive Gynecol 2005;12(4):355-8.

8. Liguori G, Tolino A, Moccia G, Scognamiglio G, Nappi C. Laparoscopic ovarian treatment in infertile patients with polycystic ovarian syndrome (PCOS): endocrine changes and clinical outcome. Gynecol Endocrinol. 1996;10(4):257-64.

9. Bayram N, van Wely M, Kaaijk EM, Bossuyt PM, van der Veen F. Using an electrocautery strategy or recombinant follicle stimulating hormone to induce ovulation in polycystic ovary syndrome: randomised controlled trial. BMJ. 2004 24;328(7433):192.

10. Greenblatt EM, Casper RF. Adhesion formation after laparoscopic ovarian cautery for polycystic ovarian syndrome: lack of correlation with pregnancy rate. Fertil Steril 1993;60:766.

11. Gurgan T, Urman B. Adhesions after ovarian drilling and intercede. Fertil Steril 1994;62:424–6.

12. Saravelos H, Li TC. Post-operative adhesions after laparoscopic electrosurgical treatment for polycystic ovarian syndrome with the application of Interceed to one ovary—a prospective randomized controlled study. Hum Reprod 1996;11:992–7.

13. National Collaborating Centre for Women's and Children's Health. Fertility assessment and treatment for people with fertility problems. RCOG Press. London, 2004, Ch 7.

14. Vandermolen DT, Ratts VS, Evans WS, Stovall DW, Kauma SW, Nestler JE. Metformin increases the ovulatory rate and pregnancy rate from clomiphene citrate in patients with polycystic ovary syndrome who are resistant to clomiphene citrate alone. Fertil Steril. 2001;75(2):310-5.

15. The Rotterdam ESHRE/ASRM-Sponsored PCOS consensus workshop group. Revised 2003 consensus on diagnostic criteria and long-term health risks related to polycystic ovary syndrome (PCOS). Hum Reprod. 2004;19(1):41-7.

16. Wiedermann R, Hepp H. Selection of patients for IVF therapy or alternative therapy methods. Hum Rep 1989.;4:23-27.

17. The American Fertility Society classifications of adnexal adhesions, distal tubal occlusion, tubal occlusion secondary to tubal ligation, tubal pregnancies, müllerian anomalies and intrauterine adhesions. Fertil Steril. 1988;49(6):944-55.

18. Kaya H, Sezik M, Ozkaya O. Evaluation of a new surgical approach for the treatment of clomiphene citrate-resistant infertility in polycystic ovary syndrome: laparoscopic ovarian multi-needle intervention. J Minim Invasive Gynaecol. 2005; 12(4):355-8.

19. Al-Fadhli R, Tulandi T. Laparoscopic treatment of polycystic ovaries: is its place diminishing? Endoscopic surgery. Current Opinion in Obstetrics & Gynecology 2004; 16(4):295-298.

20. Weerakiet S, Lertvikool S, Tingthanatikul Y, Wansumrith S, Leelaphiwat S, Jultanmas R. Ovarian reserve in women with polycystic ovary syndrome who underwent laparoscopic ovarian drilling. Gynecol Endocrinol. 2007; 2:1-6

21. Hayashi H, Ezaki K, Endo H, Urashima M. Preoperative luteinizing hormone levels predict the ovulatory response to laparoscopic ovarian drilling in patients with clomiphene citrate-resistant polycystic ovary syndrome. Gynecol Endocrinol. 2005;21(6):307-11.

22. Letterie GS (Ed.). Polycystic ovary syndrome. In. Surgery, Assisted Reproductive Technology and Infertility. Taylor & Francis. Oxon. Second edition, 2006, pp442-6.

23. Mercorio F, Mercorio A, Di Spiezio Sardo A, Vincenzo Barba G, Pellicano M, Nappi C. Evaluation of ovarian adhesion formation after laparoscopic ovarian drilling by second-look minilaparoscopy. Fertil Steril. 2008 May;89(5):1229-33.

24. Marianowski P, Kaminski P, Wielgos M, Szymusik I, Ludwikowski G. The comparison of microlaparoscopy and laparoscopy in pelvic region assessment in infertile women. Neuro Endocrinol Lett. 2007;28(5):704-7.

25. Adhesion Scoring Group. Improvement of interobserver reproducibility of adhesion scoring systems. Fertil Steril. 1994;62(5):984-8.

26. Weise HC, Naether O, Fischer R, Berger-Bispink S, Delfs T. Results of treatment with surface cauterization of polycystic ovaries in sterility patients. Geburtshilfe Frauenheilkd. 1991;51(11):920-4.

27. Gurgan T, Kisnisci H, Yarali H, Develioglu O, Zeyneloglu H, Aksu T. Evaluation of adhesion formation after laparoscopic treatment of polycystic ovarian disease. Fertil Steril 1991;56:1176–8.

28. Dabirashrafi H, Mohamad K, Behjatnia Y, Moghadami-Tabrizi N. Adhesion formation after ovarian electrocauterization on patients with polycystic ovarian syndrome. Fertil Steril 1991;55:1200–1.

29. Naether OG, Fischer R. Adhesion formation after laparoscopic electrocoagulation of the ovarian surface in polycystic ovary patients. Fertil Steril. 1993;60(1):95-8.

30. Naether OGJ, Fisher R,Weise HC, Geiger Kotzler L, Delfs T, Rudolf K. Laparoscopic electrocauterization on patients with polycystic ovarian syndrome.Fertil Steril 1993;60:66–94.

31. Saravelos H, Li TC. Post-operative adhesions after laparoscopic electrosurgical treatment for polycystic ovarian syndrome with the application of Interceed to one ovary: a prospective randomized controlled study. Hum Reprod. 1996;11(5):992- 7.

32. Felemban A, Tan SL, Tulandi T. Laparoscopic treatment of polycystic ovaries with insulated needle cautery: a reappraisal. Fertil Steril. 2000;73(2):266-9.

33. Casa A, Sesti F, Marziali M, Gulemì L, Piccione E. Transvaginal hydrolaparoscopic ovarian drilling using bipolar electrosurgery to treat anovulatory women with polycystic ovary syndrome. J Am Assoc Gynecol Laparosc. 2003;10(2):219-22.

2.b.3 Fertility after laparoscopic management of gynecologic emergencies: the experience of a developing country.

Atef M. Darwish, Mahmoud Zhakhera and Alaa A. Youssef

Gynecological Surgery Vol 4, No 2, 85-90,2007.

Introduction:

Prompt diagnosis and effective treatment of gynecologic emergencies prevent complications and help preserve fertility (1). Unfortunately, the poor patient's situation sometimes makes saving the patient's life the main goal of surgical intervention with little attention to her future fertility. Future fertility in gynecologic emergencies is not compromised and in some cases may be improved with laparoscopic treatment (2). Likewise, pregnancy rate after open surgery in emergencies was reported to be of the same efficacy of laparoscopy (3). This prospective study aims to estimate pregnancy rate after surgical treatment of ectopic pregnancy, adnexal torsion, ruptured ovarian cyst and acute pelvic inflammatory disease (PID) within 1 year of operative laparoscopy or laparotomy in a developing country set-up and to define different factors that would affect this pregnancy rate.

Patients and methods:

This study comprised 152 patients presenting with gynecologic emergencies and was approved by the ethics committee of faculty of Medicine. A senior gynecologist clinically assessed patients with emphasis on the general condition, abdominal and vaginal examination. A quick pregnancy test was done when ectopic pregnancy was suspected. Ultrasonography was performed in all cases using the apparatus ALOKA (Flexus 1100) with a vaginal probe 5 MHz. A full pelvic and abdominal sonograms were done including careful description of the endometrial cavity and adnexa to detect adnexal masses whether cystic or heterogenous, intrauterine or extrauterine gestational sac, fetal pole or free fluid in the pouch of Douglas or the peritoneal cavity. According to the approach of treatment, patients were divided into 2 groups.

Diagnostic laparoscopy (LAS) was done under general anesthesia to confirm the diagnosis in 77 cases (group A), which was followed by operative laparoscopic procedures accordingly. All laparoscopic procedures were started by peritoneal washing of the blood or pus to allow better visualization and precise microsurgical steps. Ectopic pregnancy was easily diagnosed by the presence of a gestational sac in the tube and some free blood in the peritoneal cavity. Laparoscopic microsurgical techniques started with good exposure of the affected tube after proper lavage of any hemoperitoneum. If the ectopic sac was seen in the fimbrial end of the tube, gentle tubal milking was performed. When salpingotomy was decided, a non-traumatic blunt grasping forceps was gently applied just proximal to the ectopic sac. With a fine microneedle, linear salpingotomy was done along the antimesentric surface of the tube just on the ectopic pregnancy. Subsequently, the sac that bulges through the incision could be easily extracted with another grasper. Meticulous exploration of the rest of the tubal lumen with fine instruments could be done to ensure complete evacuation of the sac. Fine coagulation of the edges was sometimes required. The most important step was to ensure proper lavage of the hemoperitoneum with the aid of repeated suction irrigation and changing patient's positions which was followed by leaving a copious amount of lactated Ringer's solution intraperitoneally. Using a 10 mm suction cannula with a competent suction pump allowed fast and effective removal of all clotted blood or even the ectopic sac. Laparoscopic salpingectomy was indicated if the tube was markedly damaged, uncontrollable bleeding was encountered, some cases of isthmic ectopic pregnancy, or if the patient completed her family to minimize the risk of recurrent ectopic pregnancy. It was easily done using a bipolar forceps to safely coagulate the mesosalpinix, which was followed by excision of the tube with a hook scissors. The excised tube and the ectopic sac were extracted using a claw forceps via a 10 mm auxiliary

portal without the need of an endobag. One case of heterotropic pregnancy was treated by laparoscopic salpingostomy and vaginal evacuation of a definite intrauterine blighted sac.

Twisted adnexa were easily diagnosed laparoscopically. Adnexectomy was decided if the adnexa was gangrenous and was done using a bipolar forceps and a hook scissors. Prior cyst aspiration was sometimes done to facilitate adnexectomy procedure. However, detorsion of the adnexa was done if the tissues were healthy by untwisting the tube and the ovary until getting the normal anatomy. If ruptured ovarian cyst was diagnosed, ovarian cystectomy with spray coagulation of the bed was done in most of the cases. Endosutures were rarely required if the ovarian defect was big using intracorporeal suturing technique. Acute PID was diagnosed by the occurrence of pus in the pelvic peritoneum with evidence of inflammatory process in the upper genital tract. Cautious peritoneal toilet and opening of pus locules were done in such cases with minimal tissue manipulations.

In 75 cases (group B) laprotomy (LAP) was done from the start. The same laparoscopic procedures were done via a transverse suprapubic incision using microsurgical instruments. Open microsurgical principles include proper illumination, gentle tissue handling, fine caliber-non-reactive sutures and microsurgical instruments. Moreover, minimizing tissue trauma was done using as atraumatic techniques as possible and meticulous hemostasis. In both groups, the procedures were done under potent broad spectrum antibiotics and were followed by insertion of intraperitoneal tube drains for 24 hours to allow any blood clots to be removed from the peritoneal cavity.

All patients were followed up for one year. When pregnancy was diagnosed, exclusion of ectopic pregnancy was done using TVS. If ectopic pregnancy was diagnosed, it was laparoscopically treated even in group B to minimize the deleterious effect of

repeated laparotomy on fertility. Data were collected and analyzed using SPSS software. Categorial variables were analyzed using Chi square test and Fisher exact test when appropriate. Paired T test was used for comparison between the data within the same group and comparison of data between the two groups was done by the student T test. P value was considered significant if it was lower than 0.05.

Results:

Patients's age ranged from 18 to 36 with a mean of 26 ± 2.43. Their mean parity was 2±1.35. Preoperatively, transvaginal ultrasonography (TVS) could successfully diagnose abnormal findings in all cases as shown in table (1). In 75 cases (group B), laparotomy was done due to hemodynamic instability in 33 (44%), inaccessible LAS in 25 (33%), impossible LAS in 7 (9%), or vague diagnosis in 10 (13%) patients. All patients in LAS group (77 patients) were effectively treated without the need of laparotomy. EP was diagnosed in 60 (78%) and 52 (69%) patients in LAS and LAP groups respectively. The ampulla was the commonest site in both groups while the isthmus and the fimbria were the least common sites in both groups (table2). It was successfully treated by milking in 5 (8.3%) and 4 (7.7%), salpingotomy 41 (68%) and 15 (29%) or salpingectomy in 14 (23%) and 33 (63.5%) in LAS and LAP groups respectively. Twisted adnexa was diagnosed in 7 (9%) and 12 (16%) patients which was treated by adnexectomy in 5 (71%) and 9 (75%) or detorsion in 2 (29%) and 3 (25%) in LAS and LAP groups respectively. Ruptured ovarian cyst was diagnosed in 6 (7.8%) and 5 (6.7%) cases which was treated with coagulation in 5 (83%) and 2 (40%) or suturing in 1 (17%) and 3 (60%) cases,

respectively. PID was diagnosed in 4 (5.2%) and 6 (8%) patients in LAS and LAP respectively and was treated with peritoneal toilet in all cases.

Table (1): Preoperative sonographic findings.

	Laparoscopy (77patients)		**Laparotomy (75patients)**		**P value**
	No	%	No	%	
Extrauterine gestational sac	14	18	34	45	0.01
Intrauterine gestational sac	1	1.3	0	-	-
Extrauterine fetal pole	5	6.5	25	33	0.0001
Adnexal mass	50	65	35	47	0.03
Free fluid	41	53	54	72	0.03

Table (2): Anatomic sites of ectopic tubal pregnancy

	Laparoscopy (60)		**Laparotomy (52)**		**P value**
	No	%	No	%	
Fimbrial (20)	14	23.3	6	11.5	0.02
Ampullary (71)	39	65	32	61.5	0.37
Isthmic (19)	5	8.3	14	27	0.02
Heterotopic (1)	1	1.7	-	-	-
Bilateral ampullary (1)	1	1.7	-	-	-

Table (3): Surgical techniques affecting fertility.

Technique	Laparoscopy group		Laparotomy group		Total	
	No. (77)	Preg 45 (58%)	No. (75)	Preg 24 (32%)	No. (152)	Preg 69 (45%)
Milking	5	2 (40%)	4	1 (25%)$❄	9	3 (33.3%)●
Salpingotomy	41	28 (68.3%)$	15	12 (80%)❄	56	40 (71.4%)●●
Salpingectomy	14	9 (64.3%)$	33	6 (18.2%)	47	15 (32%)●●
Detorsion	2	2 (100%)	3	1 (33.3%)❄	5	3 (60%)
Adnexectomy	5	2 (40%)	9	1 (11%)❄	14	3 (21.4%)●●
Ovarian coagulation	5	1 (20%)$$	2	1 (50%)	7	2 (28.6%)●
Ovarian suturing	1	0	3	1 (33.3%)	4	1 (25%)●●●
Peritoneal toilet	4	1 (25%)$	6	1 (16.7%)	10	2 (20%)●●●

$*P*<0.05, $$*P*<0.01, $$$*P*<0.001 vs. pregnants and non-pregnants in each group.

❄*P*<0.05, ❄❄*P*<0.01, ❄❄❄*P*<0.001 pregnant vs. non-pregnant in LAS vs. LAP groups.

●*P*<0.05, ●●*P*<0.01, ●●●*P*<0.001 vs. pregnants and non-pregnants in the total patients.

Table (4): Miscellaneous factors affecting pregnancy.

	Group A (77)	Group B (75)	Total (152)	P value
Age:				**0.001*** **
<30 years	**38 (84%)**	**20 (83%)**	**58 (84%)**	
>30 years	**7 (16%)**	**4 (17%)**	**11 (16%)**	
Parity:				**0.04***
Multipara	**25 (56%)**	**19 (79%)●**	**44 (64%)**	
Nullipara	**20 (44%)**	**5 (21%)●**	**25 (3%)**	
Timing				**0.03***
<6 months	**31 (69%)**	**17 (71%)**	**48 (70%)**	
>6 months	**14 (31%)**	**7 (29%)**	**21 (30%)**	
Contralateral tube				**0.001*** **
Normal	**34 (76%)**	**20 (83%)●**	**54 (78%)**	
Pathologic	**11 (24%)**	**4 (17%)●**	**15 (22%)**	
Concomitant procedure				**0.04***
Adhesiolysis	**37 (82%)**	**15 (62.5%)●**	**42 (42%)**	
No	**8 (18%)**	**9 (37.5%)●**	**27 (39%)**	

****P*<0.05, ***P*<0.01, ****P*<0.001 vs. pregnants and non-pregnants in all patients.**

●*P*<0.05, ●●*P*<0.01, ●●●*P*<0.001 vs. pregnants and non-pregnants in both groups.

Table (5): Second-look laparoscopy of recurrent ectopic pregnancy in both groups (14 patients*).

Laproscopic findings	No	%
Peritubal adhesions	5	35
Paratubal cyst	3	21
Pathologic tube	3	21
Bilateral ampullary EP	1	7
Non-specific (? Intratubal)	2	14

*** One case of recurrent ampullary EP 3 times.**

On follow-up for 1 year, fertility was significantly higher in the laparoscopy group (p=0.001) as 45 (58.4%) and 24 (32%) patients got pregnant; of which EP was diagnosed in 5 (11%) and 9 (37.5%) patients in LAS and LAP groups respectively (p=0.01). Different factors that were suspected to affect the fertility after surgical management of gynecologic emergencies are demonstrated in tables (3 and 4). Second-look laparoscopy was done for all the recurrent cases, which revealed some pathologic lesions that would explain the recurrence of ectopic pregnancy (table 5)

Discussion:

Tansvaginal ultrasonography (TVS) could diagnose one or more pelvic abnormalities in all cases of this study prior to surgery. These findings highlight the central role of TVS in gynecologic emergency units day and night with the availability of an experienced sonographer to help residents and young staff reach a reliable diagnosis (4).

Ulrasonography allows identification of ovarian torsion and has both diagnostic and therapeutic capabilities in patients with PID through guidance of abscess drainage via tansvaginal route (5). Furthermore, it has a definite role in treating ovarian cysts even during first and second trimesters of pregnancy using aspiration needles (6).

Laparotomy for treating gynecologic emergencies was the gold standard for a long time. Nevertheless, skilful laparoscopists consider laparoscopy an ideal approach to assess and treat gynecologic emergencies. It is as safe and effective as laparotomy for the treatment of ectopic pregnancy, ovarian cysts, dermoid cysts, and adnexal torsion (2). It considerably reduces costs (7). Other well-known advantages of laparoscopy include less operative time (8), shorter hospital stay (9), less intraoperative blood loss , less narcotic requirement (3), rapid convalescence, and less postoperative adhesions formation (10). These advantages are more valuable in developing countries with limited resources. In this study, no case planned for laparoscopic management was switched to laparotomy unlike others (11) who performed laparotomy for 3 out of 49 cases with gynecologic emergencies

Laparoscopic microsurgical salpingotomy for undisturbed tubal ectopic pregnancy is a universally accepted line of treatment. Since first described in 1977 (12), laparoscopic surgery is considered the cornerstone of treatment in the majority of tubal pregnancy in hemodynamically stable patients desiring further fertility. Unfortunately, it may be impossible to use laparoscopy in many centers due to bad general condition of the patient, or unavailability of a competent laparoscopy set or a well-trained surgeon. Whether to do salpingectomy or try to preserve the fallopian tube whenever possible is controversial. The proposed advantages of preserving the tube are to increase the chances of subsequent pregnancy by leaving a healthy tube and to improve the psychic state of the patient

postoperatively. On the other hand, salpingectomy definitely will decrease the chance of ectopic pregnancy at this side and will minimize the risk of postoperative oozing from the site of the gestational sac and hence postoperative adhesions. Failure of complete trophoblast evacuation or recognition of underlying tubal disease and possibility of trophoblast seeding in the peritoneal cavity are real risks of conservative management (13). In this study, we conceived the concept of conservative management whenever possible since the patients in developing countries have limited resources that hinder assisted reproductive techniques that are not covered by the health care system. Our results significantly supported this concept where pregnancy was achieved in 40 out of 56 cases (71.4%) and 15 out of 47 cases (32%) following salpingotomy and salpingectomy respectively. Likewise, fertility prognosis was better after conservative laparoscopic management (14).

Adnexal torsion is a serious condition (15) that may lead to severe acute pain and even sudden death (16). However, it is most commonly associated with a benign process. A more conservative approach to the treatment of torsion is becoming increasingly common, as seems warranted in light of the low incidence of malignancy (17,18). Laparoscopic detorsion, rather than adnexectomy, seems to be an effective adnexa-sparing approach (18). However, adnexectomy is indicated in cases of gangrenous adnexa, neoplastic ovarian cyst or unusual ovarian attachment (19). In this study, adnexectomy was performed for 14 patients (73.7%) due to extensive gangrenous changes, while detorsion was done for only 5 (26.3%) cases. Late presentation and delayed diagnosis of adnexal torsion were the leading causes of this radical approach. Many of these cases were admitted to other departments with unclear diagnosis for many days before their referral to

gynecology department. Extended awareness of all concerned specialties may lead to early diagnosis and hence more conservative management particularly in infertile women. One-hundred and two women with twisted black-bluish ischemic adnexa were safely treated with detorsion rather than adnxectomy in a previous study (20). They reported smooth postoperative course, good follicular development and normal anatomy in most cases. Since leaving dead tissues in the abdomen is a serious decision, we think that adding Doppler ultrasonography to the preoperative diagnostic work-up in suspected cases of adnexal torsion would differentiate healthy from devitalized tissue to determine the appropriate surgical technique. Instead, intraoperative laparoscopic ultrasonography can properly evaluate the adnexa and the blood vessels (21). In this study in LAS group, cases of large adnexal gangrenous cysts were treated by preliminary aspiration, which was very helpful to have an easy access to the mesosalpnix during adnexectomy. This simple step has made adnexectomy feasible in all cases without the need for laparotomy. Gorkemli et al. (22), performed laparotomy for one case out of 9 of detorsion due to the large size of the ovary. In this study, no case of recurrence of adnexal torsion was encountered and we were not obliged to fix the adnexa by sutures in any case. Ovarian bivalving after detorsion was recently described to decrease intracapsular pressure, increase arterial perfusion, and facilitate adnexal reperfusion and recovery (23).

Acute pelvic inflammatory disease (PID), in addition to antibiotic therapy, may benefit from surgical or laparoscopic intervention. The old concept that surgery during acute pelvic infection results in greater injury than waiting for the infection to subside, has been recently challenged. It is much easier to operate on acute adhesions than on the dense adhesions that obliterate the normal anatomic relationships, and develop neovasularization.

Laparoscopic drainage of a pelvic abscess followed by lysis of all peritoneal cavity adhesions and excision of necrotic inflammatory exudate, allows host defenses to effectively control the infection (24). Rapid subjective improvement of the general status, the absence of early PID complications and the absence of recurrence were noticed when laparoscopy was done to supplement medical treatment of PID (25). Many cases of acute PID are opened in the emergency units simulating acute appendicitis or due to unclear diagnosis. These laparotomies could be avoided, if laparoscopy of those patients was considered.

In this study, fertility after surgical treatment of gynecologic emergencies was achieved in 45 (58.4%) and 24 (32%) patients within one year in both groups respectively. Pregnancy rate was significantly higher in LAS group, which can be explained by having patients with early ectopic pregnancies, minimal tubal damage, less salpingectomy operations, less isthmic and more fimbrial ectopic pregnancies, and, above all, the well-documented advantages of LAS over LAP. On the other hand, despite postoperative conceptions were significantly lower in the laparotomy group, one third of patients in this group got pregnant within 12 months of the procedure. This can be explained by the advantage of following microsurgical principles. Moreover, these patients were young and 112 patients of them were already pregnant (ectopic) at the beginning of the study. Fertility could be higher if the follow-up period was more than one year like others (26) who followed patients for up to 24 months. Nevertheless, the total fertility figure in this study (69 patients,45%) seems reasonable as compared to a large sample-sized study of 1451 patients (27) which reported 52% intrauterine and 14% extrauterine pregnancy rates following laparoscopy or laparotomic salpingotomy for

treating ectopic pregnancy. Our study addressed fertility rate following emergencies other than ectopic pregnancy because those patients are usually subjected to the same situation.

Fertility following LAS vs. LAP for treating ectopic pregnancy is variable. Live birth rates are similar, but the recurrent ectopic pregnancy rate, surprisingly, tends to be lower in LAS group for reasons that are unclear in one study (28). In this study, the lower rate of recurrent ectopic pregnancy { 5 (11%) and 9 (37.5%) patients in LAS and LAP groups respectively} can be explained by minimal laparoscopic trauma to the tubal lumen and less liability to adhesions formation. Pregnancy rates following radical and conservative surgery were 50% and 56% and recurrent pregnancy rates were 11% compared to 8% in both groups respectively in a recent study (29). Likewise, there was no fertility difference between radical and conservative surgery treatment in a study of 138 patients (26). In 167 patients with absent or occluded contralateral tube, conception rate after salpingotomy was 75%. Of those 55% were intrauterine and 20% had recurrent EP (30). The choice of surgical treatment was not found to influence the posttreatment fertility and a prior history of infertility was associated with a marked reduction in fertility (31). In our study, high fertility rate was achieved in patients younger than 30 years, in multiprous women, if the contralateral tube was free, if concomitant adhesiolysis was performed and after salpingotomy operation for treating ectopic pregnancy. We think that discussion of these variables, which significantly affect fertility, with patients postoperatively would provide a reliable idea about the prognosis of the surgery. In 14 recurrent EP cases, obvious pathologic lesions could explain the recurrence in 12 of them. These findings highlight the importance of concomitant procedures that would improve fertility or

minimize the risk of recurrent ectopic pregnancy. In a previous study, we recommended routine removal of paratubal or paraovarian cysts during laparoscopy in all patients. One of the objectives was to minimize the possibility of subsequent EP (32).

From this study, we conclude that in patients desiring further fertility, both laparoscopy and laparotomy can achieve fertility preservation following basic microsurgical principles. Better results could be significantly achieved following laparoscopic surgery. High fertility is seen in patients younger than 30 years, in multiparous women, if the contralateral tube is free, if concomitant adhesiolysis is performed and after salpingotomy operation for treating EP.

References:

(1) Porpora MG, Gomel V: The role of laparoscopy in the management of pelvic pain in women of reproductive age. Fertil Steril 1998;70 (3):592-3.

(2) Promecene PA: laparoscopy in gynecologic emergencies. Semin Laparosc Surg 2002;9 (1):64-75.

(3) Murphy AA, Nager CW, Wujek JJ, Kettel LM, Torp V, Chin HG: Operative laparoscopy versus laparotomy for the management of ectopic pregnancy: a prospective trial. Fertil Steril. 1992;57 (6):1180-5.

(4) Estroff JA : Emergency obstetric and gynecologic ultrasound. Radiol Clin North Am 1997;35 (4):921-57.

(5) Derchi LE, Serafini G, Gandolfo N, Martinoli C: Ultrasound in gynecology. Eur Radiol 2001;11 (11):2137-55.

(6) Duic Z, Kukura V, Ciglar S, Podobnik M, Podgajski M: Adnexal masses in pregnancy: a review of eight cases undergoing surgical management. Eur J Gynaecol Oncol 2002;23 (2):133-4.

(7) Mol BW, Hajenius PJ, Englsbel S, Ankum WM, Van der Veen F, Hermrika DJ, Bossuyt PM: An economic evaluation of laparoscopy and open surgery in the treatment of tubal pregnancy. Acta Obstet Gynecol Scand 1997;76:596-600.

(8) Brumsted JB: Managing ectopic pregnancy nonsurgically. Contemporary Obstetrics and Gynecology 1996;41,43-56.

(9) Garry R: The laparoscopic treatment of ectopic pregnancy: the long road to acceptance. Gynaecological Endoscopy 1996;5,65-8.

(10) Lundorff P: Modern management of ectopic pregnancy. Early recognition, laparoscopic treatment and fertility prospects. Acta Obstet Gynecol Scand 71:158-159, 1992.

(11) Magos AL, Baumann R, Turnbull AC: Managing gynaecological emergencies with laparoscopy. BMJ 1989 5;299:371-4.

(12) Bruhat MA, Manhes H, Mage G, Pouly JL: Treatment of ectopic pregnancy by means of laparoscopy. Fertil Steril 33:411-414,1980.

(13) Petrucco OM: Endoscopy in millennium. In: Shaughn O'Brien. The Year Book of Obstetrics and Gynaecology. London, RCOG Press, , 325-343, 2000.

(14) Pouly JL, Chapron C, Wattiez A: Ectopic pregnancy. In. Sutton C, Diamond MP: Endoscopic Surgery for Gynaecologists. London, W.B. Saunders Co Ltd, 1993,Ch 13.

(15) Zacan C, Elik A, Erdner A, Balik E: Adnexal torsion in children may have a catastrophic sequel: asynchronous bilateral torsion. J Pediatr Surg 2002;37 (11):1617-20.

(16) Havlik DM, Nolte kb; Sudden death in an infant resulting from torsion of the uterine adnexa. Am J Forensic med Pathol 2002;23 (2):289-91.

(17) Argenta PA, Yeagley TJ, Ott G, Sodheimer SJ: Torsion of the uterine adnexa. Pathologic correlations and current management trends. J Reprod Med 2000;45 (10):831-6.

(18) Pansky M, Abargil A, Dreazen E, golan A, Bukovsky I, herman A: Conservative management of premenarchal girls. J Am Assoc Gynecol Laparosc 2000;7 (1):121-4.

(19) Mage G, Canis M, Manhes H, Pouly JL, bruhat MA: Laparoscopic management of adnexal torsion. A review of 35 cases. J Reprod Med 1989 34 (8):520-4.

(20) Cohen SB, Wattiez A, Seidman DS, Admo D, goldenberg M, Admon D, Mashiach S, Oesner G: Laparoscopy versus laparotomy for detortion and sparing of twisted ischemic adnexa. JSLS 2003;7:395-299.

(21) Pasic R: Role of pelvic ultrasonography and color Doppler in laparoscopy. In Sanfilippo JS and Levine RL. Operative Gynecologic Endoscopy. New York, Springer-Verlag, 1996, Ch 27.

(22) Gorkemli H, Camus M, Clasen K: Adnexal torsion after gonadotropin ovulation induction for IVF or ICSI and its conservative treatment. Arch Gynecol Obstet 2002;267 (1):4-6.

(23) Styer AK, Laufer MR: Ovarian bivalving after detorsion. Fertil Steril 2002;77 (5):1053-5.

(24) Reich H: Laproscopic treatment of tubo-ovarian and pelvic abscess. In: Azziz R, Murphy AA. Practical Manual of Operative Laparoscopy and Hysteroscopy. Second Ed, Springer-Verlag NewYork Inc., 1997, Ch 19.

(25) Kobal B, Omahen A, Fetih A, Cerar V: Laproscopic treatment of acute adnexitis; one step forward. Acta Eur Fertil 1990;21 (5):225-8.

(26) Joudain O, Hopirtean V, Saint-Amand H, Gdallay D: Fertility after laparoscopic treatment of ectopic pregnancy in a series of 138 patients. J Gynecol Obstet Biol Reprod 30 (3):265-271,2001.

(27) Kooi S, Kock HC: Critical comparisons of alternative therapies for ectopic pregnancy Fertil Steril. 1993 Jan;59 (1):244-5.

(28) Reich H, Pridham D: Ectopic pregnancy. In. Sanfilippo JS, Levine RL: Operative Gynecologic Endoscopy. New York, Springer-Verlag, 1996, Ch 11.

(29) Rashid M, Osman SH, Khashoggi TY, Kamal FA: Factors affecting fertility following radical versus conservative surgical treatment for tubal pregnancy. Saudi Med J 22 (4):337-314, 2001.

(30) Thornton KL, Diamond MP, DeCheney AH: Linear salpingostomy for ectopic pregnancy. Obstet Gynecol Cl N Am 1991;18,95-110.

(31) Ory ST, Nnadi E, Herrman R: Fertility after ectopic pregnancy. Fertil Steril 1993;60:231-35.

(32) Darwish AM, Amin AF, Mohammad SA: Laparoscopic management of paratubal and paraovarian cysts. J Soc Laparoendosc Surg 2003;7:101-6.

Section 3

a. **General discussion**

b. **References.**

3. a. General discussion

In the light of the contents of this thesis, the aim of this chapter is to highlight the implications of our findings, the strengths and weaknesses of the utilized approaches, and where this research should now lead to. Briefly, our findings will be placed in the context of previous work, and their role in the future will be outlined. Detailed discussion of our findings is located in the discussion section of each study.

As the role of endoscopic reconstructive gynaecologic surgery is expanding in modern practice, it seems only logical that every effort should be exerted by gynaecologic endoscopists to improve patients' quality of life as well as restore nearly normal genital organ anatomy and functions. It is observed that most of laparoscopic reconstructive gynaecologic procedures are carried out for women during in their reproductive period. This highlights the importance of fertility-preserving as well as fertility-promoting objectives of endoscopic procedures. In addition to the well-documented advantages of hysteroscopic and laparoscopic approaches, success of any procedure should ultimately end by pregnancy for infertile women. These basic concepts are kept in mind all through this current thesis.

Scope of fertility-sparing reconstructive surgery:

Reconstructive gynaecologic surgery should be considered as the first-line treatment in modern practice particularly when fertility-enhancement or preservation is the goal in the childbearing period. For both specialized reproductive and general gynaecologic surgeons it is crucial to follow microsurgical principles to avoid adhesion formation and conserve normal tissues (1). This concept is well demonstrated in most of the chapters of this thesis. The strategy for reconstructive adnexal and uterine surgery should always be for the potential benefits of alleviation of symptoms, preservation and enhancement of fertility

compared against risks of adhesions, synechiae, integrity of uterine scars and obstetric outcome, and also the dangers of iatrogenic hysterectomy.

Reconstructive hysteroscopic myomectomy:

For a long time, hysteroscopic myomectomy has been the evidence-based (2) standard approach for treating submucus leiomyoma of suitable size(3,4). Nevertheless, it is the most dangerous hysteroscopic procedure due to possible excessive bleeding, prolonged time consumed for cutting the myoma into chips of tissues and their extraction outside the uterine cavity, the risks of fluid overload, possibility of incomplete resection, and liability to perforation. (5). Moreover, there are some studies concerned with the risk of uterine rupture in the subsequent pregnancy (6). Most of complications of hysteroscopic myomectomy are encountered with large sized myomas, or those with intramural extension (grade 1 or 2 according to the European Soceity of Hysteroscopy classification). They represent definite nightmare for endoscopists even with sufficient experience to the extent that some studies preferred laparoscopic approach in such cases (7). Hysteroscopically, several studies tried to facilitate one-step complete excision. In a case report, succeeful removal of myoma up to 12 cm in one session was reported (8). The study presented in this thesis is really a breakthrough in hysteroscopic management of big myoma with or without intramural extension. It has been cited and quoted in subsequent publications (9) and comprehensive review articles (4) on this topic. This achievement can be explained by the introduction of combined resectoscopic and mechanical approaches to enucleate the myoma in a shorter time with minimal complication rate if compared to the standard morcellation technique. Moreover, it demonsterated some additive perioperative steps that facilitated the procedure like preoperative usage of misoprostol based on a randomized controlled trial by our team (10), intraoperative slow IV ergometrine administration, utilizing of a novel

hysteroscopic myoma driller, and performing a vertical incion on top of deeply impacted intramural myomata. If compared to a study on 44 cases published in the same year (11), the difference would be clear. They performed only circumferentrial incion at the level of myoma base followed by morcellation technique. They succeeded to perform this procedure in 41 (93. 1%) of 44 women. Of these, 38 (92.6%) had myomas between 2 and 4 cm in diameter and 3 (7.4%) had myomas exceeding 4 cm. Mean operating time was 27 minutes (range 10-45 min). It seems very risky to perform morcellation of a big myoma with high possibility of overload that would obligate the hysteroscopist to stop the procedure based on the recommendation of the anaesthesia team. As a trial to alleviate this risk, one case report was recently published utilizing our previously recommended basal circumferential incision followed by central vaporization, and intraoperative injection of prostaglandin F2alpha (12). Likewise, laser hysteroscopic myomectomy guided by laparoscopically assisted intra-abdominal sonohysterography (LHMY-GLAIS) was described in a preliminary study (13).

All these trials would be expected to open the door for more ideas on hysteroscopic myomectomy for myomata of considerable size. In this context, innovation of alternative hysteroscopically-guided devices would be promising. Moreover, studies on bipolar resectoscopic myomectomy utilizing saline 0.9% should be encouraged.

Endoscopic myomectomy prior to IVF/ICSI

The impact of uterine myoma on the outcome of IVF/ICSI is a very controversial topic. Many centers are overdoing myomectomy for nearly all myomata regardless size and site considerations. Contrary, other investigators have shown that fibroids don't exert a deleterious effect. Nevertheless, many studies have provided evidence that uterine myomas

have a significant effect on IVF outcomes and there is a large body of evidence that treatment of uterine myomas increases fertility and pregnancy rates, and decreases the rate of pregnancy loss (14). There is no doubt that any cavity-distorting myoma should be removed whether completely submucous or interstitial myoma with submucous encroachment. This highlights the central role of prior hysteroscopy as well as saline infusion solonhysterography (SIS) as previously described (15). Controversy exists for interstitial and subserous myomata. The evidence supports treatment of all very large myomas (>7 cm) (14). Subserosal myomas that are smaller than 7 cm in size and intramural myomas of less than 4–5 cm in diameter appear to have little effect on IVF outcomes. Larger intramural and subserosal myomas present a clinical dilemma and more studies are needed to clarify a definitive plan for management (14). In a prospective controlled study, the distance between the intramural myomas and the endometrial lining did not appear to affect the IVF outcome. An insignificant tendency towards improvement of IVF outcome was found in myomas at more than 5 mm from endometrial lining (16).

Reconstructive hysteroscopic metroplasty.

Since a long time, due to its well-documented advantages, hysteroscopic metrroplasty has replaced abdominal approach in most of cases of complete uterocervical septa (17,18). The advent of bipolar resectoscopy seems to offer a shorter operative time and less complication rate (19). This paper presented in this thesis highlights two important issues concerning a rare variety of malfusion defect of the paramesonephic ducts which is complete vaginocervicouterine septum. Firsty, the old concept of fusion of the urogenital sinus with the paramesonephric ducts resulting in formation of the lower part of the vagina (cranial progress) should be revised following the increasing reports on complete

vaginocervicouterine septum. This is a crucial point that deserves more evaluation by embryologic as well as gynecologic societies. This study adds more support to the rising call for considering a new classification of paramesonephric duct anomalies. Being of a relatively large salmple size compared to previous studies makes its recommendations of considerable importance. Secondly, it demonstrates the feasibility and safety of utilizing monopolar resectoscopic excision of the whole septum starting from the interoitus. An unpublished valuable clinical step used in this study was inserting a bivalve vaginal speculum e.g. Collin's speculum that would facilitate the procedure too much. Neverethless, care should be taken during subsequent pregnancy following metroplasty of these cases for fear of midtrimester abortion due to possible associated cervical incompetence. Further research on different diagnostic tools is required to clarify this controversial point. This study is a real achievement in the field of hysteroscopic surgery and is considered as the first report on this simplified approach in literature. Due to these promising results and couple satisfaction, it can be recommended as the treatment of choice in similar cases. More studies are recommended to support this attractive simple technique.

Role of hysteroscopic surgery in assisted rproduction.

With the advent of technical refinements and advancement in hysteroscopic surgery, it is expected that preoperative hysteroscopic evaluation of uteri prior to IVF/ICSI would be widely performed. Unfortunately, many of studies on this topic focus on the centeral role of hysteroscopic examination of the endometrial cavity in cases with recurrent failures (20-22). This concept should be reviewed since office hysteroscopy or minihysteroscopy is a simple outpatient conscious procedure (22-23) that provides excellent information on the implantation site in the endometrial cavity in a very short time. Relying on

hysterosalpingography alone may be falicious in some cases of fine intrauterine adhesions that may be masked by dye especially oily dye. Likewise, transvaginal ultrasonography as well as sonohysterograohy may miss some important fine intrautrerine lesions that would simply contribute for failures (24). In a recent study, hysteroscopy succeeded to diagnose and treat intrauterine lesions in 26% of patients prior to starting trials of assisted reproduction (21).

The paper presented in this thesis on hysteroscopic tubal occlusion of functionless hydrosdalpngies is a unioque one. It demonstrates a valuable role of hysteroscopic approach that can be performed in difficult cases with poor access to the isthmic part of the tubes via laparoscopy even with experienced hands. The idea is attractive but further large-sample sized studies are required to define the exact role of this approach.

One of the inteseting additive items of this paper to the literature is the term "functionless" hydrosalpnix. The proposed definition is very crucial to stratify cases suitable for microsurgical salpingoneotomy and those cases suitable for occlusive procedures. By this way, the place of reconstructive surgery is still preserved in modern practice even in the era of IVF/ICSI. Ethically, every effort should be exerted to restore normal anatomy whenever possible. This concept is of utmost importance particularly for the developing countries with limited resources where no national programs to support assisted reproductive techniques. Microsurgery to correct localized damage has the advantage of long-standing restoration of fertility. A simple prognostic classification is lacking. The severity of the tubal damage and the health of the mucosa is key in determining outcome (25). Proper selection of the tube for either line of management requires expert knowledge with the principles of salpingoscopy (26). Salpingoscopy during laparoscopy yields the best prognosis in patients with hydrosalpinx (27). Performing salpingoscopy with laparoscopy

could significantly increase accuracy in predicting short-term fertility outcome (28). Whenever the mucosa is unhealthy, surgery is not justified; early referral for IVF is indicated (25).

Reconstructive adenxal laparoscopic surgery:

Practically, adnexal surgery contributes most of the indications of operative laparoscopy in the childbearing period worldwide. Being commonly practiced had made extensive research and a lot of publications on laparoscopic adnexal surgery with considerable sample size. Subsequently, it was expected to face some difficulties in constructing the studies of this thesis on adnexal surgery due to the previous plenty publications. Fortunately, this thesis has a definite objective of demonstration &/or clarification of some missing &/or unclear topics in adnexal surgery respectively. It tries to answer some questions concerning reconstructive laparoscopic adnexal surgery in modern practice.

Main outcome measures:

The proposed optimal main outcome parameters in the laparosopic section of this thesis were feasibility and success of the laparoscopic approach, operative time, patient satisfaction and postoperative discomfort, cost-effectiveness, and the impact of the procedure on society resources particularly in developing countries with limited resources.

Polycystic ovarian disease (PCO) and laparoscopic ovarian drilling (LOD):

Despite many publications on LOD, there is no enough data on the long-term health consequences of LOD with insufficient data on postoperative adhesion formation (29). This thesis includes two studies on the impact of LOD on OHSS and the long-term effect of LOD on adhesion formation.

Effect of LOD on ovarian hyperstimulation syndrome(OHSS):

In this thesis, it was demonstrated that LOD lead to decreased vascularity of the ovary as documented by decreased Doppler indices and reduced serum VEGF and IGF-1. Formerly, our team demonstrated that higher serum levels of VEGF and IGF-1 in PCOS women may be related to the increased vascularity that underlies the increased blood flow demonstrated by Doppler blood flow measurements in these women (30). In this thesis, the reported reduced level of LH post-drilling is suspected to be the main mechanism of improvement of the reproductive outcome. An additional important point was demonstrated in this thesis that may explain the reduced incidence of OHSS following PCO drilling. Since a long time it has been suggested that increased stromal vasculaity may explain the higher risk of OHSS. LOD may avoid or reduce the risk of OHSS and multiple pregnancies than gonadotrophins with the same success rate of conception (31). Despite these promising findings, more larger-sample sized studies are required before including the advantage of decreased risk of OHSS in the preoperative patient counseling.

LOD and the dilemma of adhesion formation:

A recent study on post-LOD adhesion formation was included in this thesis. This particular long-term complication of LOD is the main reason behind reluctance of many centers in treating PCOS with LOD and relying on GTs as a treatment of choice. In this study, we succeeded to document high prevalence of adhesions even if microsurgical principles are followed. Some interesting points were addressed in this study. It highlighted microsurgical principles, which come in harmony with the basic concept of reconstructive surgery demonstrated in this thesis. The role of second-look microlaparoscopy following LOD deserves further studies. Intensive animal and human studies on different techniques of LOD that would lead to the least possibility of adhesion formation are badly needed to

save many patients from this serious risk. One of the limitations of this study is omission of surgical adhesion barrier methods for adhesion prevention. Lactated Ringer's solution was instilated at the end of the procedure in all cases. It is well known that surgical adhesion barriers are more effective (32). LOD carries the risk of destruction of a part of the ovarian capsule that theoretically could be completely covered with these barriers as a trial of adhesion prevention. Neveretheless, adhesion formation is a multifactorial process and practically it is difficult to standardize all factors except the surgical barriers. Therefore, the possible added value of the use of surgical adhesion barriers following LOD requires further studies.

Role of laparoscopic reconstruction in cases of acute abdomen due to gynecologic causes:

Most of gynaecologic emergencies due to adnexal lesions would be promptly treated laparoscopically with better results than laparotomy (33). This study highlights the importance of following microsurgical principles even during laparotomy. Despite inferior to laparoscopic approach, fertility following laparotomy was acceptable (32%). Microsugical basics should be included in all courses for gynaecologists and even other pelvic surgeons to preserve fertility of many women in the childbearing period. It is clearly demonstrated that adnexal causes of acute abdomen should be put in mind during preoperative evaluation of cases even in adolescent females as previously demonstrated (34).

Future perspective

This thesis highlights the central role of operative hysteroscopy and laparoscopy in reconstructive gynaecologic surgery. Both approaches are fast and safe with minimal intra-

and post-operative complications compared with the conventional approach. It is very suitable for money saving particularly in developing countries provided appropriate patient selection and sufficient endoscopist's expertise are applied. The basics of reconstructive surgery should be taught to all gynecologists to refine their procedures in the context of fertility-preservation. The same idea should be extended to cover general surgeons and urologists whenever dealing with non-gynaecologic lesions nearby the female genital organs.

b. References

1. Wiedermann R, Hepp H. Selection of patients for IVF therapy or alternative therapy methods. Hum Rep 1989.;4:23-27.
2. National Collaborating Centre for Women's and Children's Health. Fertility assessment and treatment for people with fertility problems. RCOG Press. London, 2004, Ch 7,8,9.
3. McLucas B: Intrauterine applications of the resectoscope. Sur Gynecol Obstet 1991; 172(6):425-430.
4. Sardo AD, Mazzon I, Bramante S, Bettocchi S, Bifulco G,Guida M, Nappi C Hysteroscopic myomectomy: a comprehensive review of surgical techniques. Human Reproduction Update 2008; 14(2):101-119
5. Pasini A, Belloni C: Intraoperative complications of 697 consecutive operative hysteroscopies. Minerva Ginecol 2001;53(1):13-20.
6. Stamatellos I, Bontis J. The chance of success decreases whenever an intramural element is present Hysteroscopic myomectomy European Clinics in Obstetrics and Gynaecology 2007;1,17-23.
7. Laparoscopic myomectomy for large intramural and submucous fibroids Int J Gynaecol Obstet. 2007 Jun;97(3):206-7 Wang CJ, Soong YK, Lee CL.
8. Kriplani A, Singh BM, Meena S. One-step hysteroscopic myomectomy: unusual cases and a review of the literature. J Laparoendosc Adv Surg Tech A. 2004 Dec;14(6):390-4,
9. Murakami T, Tachibana M, Hoshiai T, Ozawa Y , Terada Y, Okamura K. Successful strategy for the hysteroscopic myomectomy of a submucous myoma arising from the uterine fundus. Fertil Steril. 2006; 86,5,1513.e19-22.

10. Darwish AM, Ahmad AM, Mohammad AM. Cervical priming prior to operative hysteroscopy: a randomized comparison of laminaria versus misoprostol. Hum Reprod 2004; 19(10):2391-2394.
11. Litta P, Vasile C, Merlin F, Pozzan C, Sacco G, Gravila P, Stellia C. A new technique of hysteroscopic myomectomy with enucleation in Toto. The Journal of the American Association of Gynecologic Laparoscopists 2003;10,2;263-270.
12. Murakami T, Tachibana M, Hoshiai T, Ozawa Y , Terada Y, Okamura K. Successful strategy for the hysteroscopic myomectomy of a submucous myoma arising from the uterine fundus. Fertil Steril. 2006; 86,5,1513.e19-22.
13. Kaseki H, Araki T, Valle R. Laser Hysteroscopic myomectomy guided by laparoscopically assisted intra-abdominal sonohysterography (LHMY-GLAIS): a preliminary report. Journal of Gynecologic Surgery 2001; 17(3): 79-86.
14. Bromer JG, Arici A. Impact of uterine myomas on IVF outcome. Expert Review of Obstetrics & Gynecology 2008;3, 4,515-521.
15. Darwish AM, Youssef AA. Screening sonohysterography in infertility. Gynecol Obstet Invest. 1999;48(1):43-7.
16. Aboulghar, M.M., Al-Inany, H.G., Aboulghar, M.A., Serour, G.I., Mansour, R.T. Effect of myomectomy on the outcome of assisted reproductive technologies Middle East Fertility Society Journal 2004; 9 (3), 263-267.
17. Elchalal U, Schenker JG. Hysteroscopic resection of uterus septus versus abdominal metroplasty. J Am Coll Surg. 1994;178(6):637-44.
18. Heinonen PK. Reproductive performance of women with uterine anomalies after abdominal or hysteroscopic metroplasty or no surgical treatment. J Am Assoc Gynecol Laparosc. 1997 ;4(3):311-7.

19. Colacurci N, De Franciscis P, Mollo A, Litta P, Perino A, Cobellis L, De Placido G.. Small-diameter hysteroscopy with Versapoint versus resectoscopy with a unipolar knife for the treatment of septate uterus: a prospective randomized study. J Minim Invasive Gynecol. 2007;14(5):622-7.
20. Rama Raju GA, Shashi Kumari G, Krishna KM, Prakash GJ, Madan K. Assessment of uterine cavity by hysteroscopy in assisted reproduction programme and its influence on pregnancy outcomeArch Gynecol Obstet. 2006;274(3):160-4.
21. Oliveira FG, Abdelmassih VG, Diamond MP, Dozortsev D, Nagy ZP, Abdelmassih R. Uterine cavity findings and hysteroscopic interventions in patients undergoing in vitro fertilization-embryo transfer who repeatedly cannot conceive. Fertil Steril. 2003;80(6):1371-5.
22. Demirol A, Gurgan T. Effect of treatment of intrauterine pathologies with office hysteroscopy in patients with recurrent IVF failure. Reprod Biomed Online. 2004;8(6):726.
23. Cicinelli E, Parisi C, Galantino P, Pinto V, Barba B, Schonauer S.Cicinelli E Reliability, feasibility, and safety of minihysteroscopy with a vaginoscopic approach: experience with 6,000 cases. Fertil Steril. 2003 ;80(1):199-202. Cicinelli E . Diagnostic minihysteroscopy with vaginoscopic approach: rationale and advantages. J Minim Invasive Gynecol. 2005;12(5):396-400.)
24. Kamel HS, Darwish AM, Mohamed SA. Comparison of transvaginal ultrasonography and vaginal sonohysterography in the detection of endometrial polyps. Acta Obstet Gynecol Scand. 2000 ;79(1):60-4.
25. Elstein M. Tubal disease and fertility outcome. Reprod Biomed Online. 2008 Feb;16(2):167-9.

26. Marana R, Catalano GF, Muzii L. Salpingoscopy. Curr Opin Obstet Gynecol. 2003 Aug;15(4):333-6.
27. Zeyneloglu, Hulusi Bulent. Hydrosalpinx and assisted reproduction: options and rationale for treatment. Current Opinion in Obstetrics and Gynecology: June 2001 - Volume 13 - Issue 3 - pp 281-286.
28. . Marchino GL, Gigante V, Gennarelli G, Mazza O, Mencaglia L. Salpingoscopic and laparoscopic investigations in relation to fertility outcome. J Am Assoc Gynecol Laparosc. 2001 May;8(2):218-21.
29. National Collaborating Centre for Women's and Children's Health. Fertility assessment and treatment for people with fertility problems. RCOG Press. London, 2004, Ch 7,8,9.
30. Abd El Aal DE, Mohamed SA, Amine AF, Meki AR.Vascular endothelial growth factor and insulin-like growth factor-1 in polycystic ovary syndrome and their relation to ovarian blood flow. Eur J Obstet Gynaecol Reprod Biol. 2005 1;118(2):219-24.
31. Amin AF, Abd el-Aal DE, Darwish AM, Meki AR. Evaluation of the impact of laparoscopic ovarian drilling on Doppler indices of ovarian stromal blood flow, serum vascular endothelial growth factor, and insulin-like growth factor-1 in women with polycystic ovary syndrome. Fertil Steril. 2003,79(4):938-41.
32. The Practice Committee of the American Society of Reproductive Medicine in collaboration with the Society of Reproductive Surgeons. Pathogenesis, consequences, and control of peritoneal adhesions in gynecologic surgery. Fertil Steril 2006;86,4:S1-S5.

33. Mol BW, Hajenius PJ, Englsbel S, Ankum WM, Van der Veen F, Hermrika DJ, Bossuyt PM: An economic evaluation of laparoscopy and open surgery in the treatment of tubal pregnancy. Acta Obstet Gynaecol Scand 1997;76:596-600.
34. Pansky M, Abargil A, Dreazen E, golan A, Bukovsky I, herman A: Conservative management of premenarchal girls. J Am Assoc Gynaecol Laparosc 2000;7(1):121-4.

Section 4

Miscellaneous

4.a Summary

Section 1

Despite the widespread utilization of assisted reproductive techniques in recent years, hysteroscopic as well as laparoscopic surgery should be firstly offered for patients with adnexal and uterine lesions desiring fertility. Permanent correction of the patient's problem with frequent chances of pregnancy is a definite advantage of endoscopic surgery over assisted reproductive techniques. Reconstructive endoscopic procedures could be performed for fertile women as well e.g. hysteroscopic or laparoscopic myomectomy for abnormal bleeding. The concept of reconstruction following microsurgical principles coupled with refinement of instrumentation and techniques is would improve the results of hysteroscopic and laparoscopic approaches. It is expected to expand to cover many gynaecologic aspects in the coming years particularly with the continuous advances in technology of fine endoscopic surgery and the development of more suitable robotic instrumentation.

Section 2

2.a.1 This study aimed to compare efficacy of intravaginal misoprostol versus endocervical laminaria tents prior to operative hysteroscopy in selected cases. It included a total of 144 patients with diagnosed intrauterine lesions scheduled for operative hysteroscopy were randomly allocated to two groups according to method of cervical priming prior to the procedure. Misoprostol 200mg was inserted into the posterior fornix of the vagina for patients in group A (n 5 72), while laminaria tents were inserted intracervically in group B patients (n 5 72). Both methods were effective for cervical dilatation with a mean cervical

diameter of 7.5 6 1.2 and 7.6 6 1.2mm respectively. There was no significant difference in the mean cervical diameter or the time required for cervical dilatation (51.6 versus 51.4 s respectively). In contrast, there was a significant difference between the groups with respect to the insertion difficulty and in doctors' and patients' assessments of the procedure. It is concluded that both misoprostol and laminaria were equally effective in inducing proper cervical priming prior to operative hysteroscopy with minimal time of cervical dilatation. Nevertheless, misoprostol may be superior due to easy application, reduced cost, and patient convenience and acceptability.

2.a.2 This study aimed to determine whether hysteroscopic tubal occlusion will produce the same efficacy as laparoscopic tubal occlusion of functionless hydrosalpnix prior to IVF/ICSI. It is prospective comparative study done at the Endoscopy Unit of Woman Health Center, Faculty of Medicine, Assiut University, Assiut, Egypt. It comprised a pilot safety phase included 10 uterii removed by hysterectomy in perimenopausal women subjected to roller ball coagulation of the peritubal pulge. The study phase included 27 patients with uni or bilateral functionless hydrosalpnges were randomly divided into 2 groups. Group A comprised 14 patients who were randomly allocated for laparoscopic occlusion. Group B included 13 patients scheduled for hysteroscopic approach. Intervention included laparoscopic occlusion of the isthmic part of the fallopian tube done using bipolar diathermy in 9 (64%) cases or clips in 3 (21.4%) cases in group A. Roller ball electrode of the resectoscope was utilized for occlusion of the tubal ostium under local, spinal, or general anaethesia in group B. Second-look office hysteroscopy was performed in group B whenever possible. In both groups, hysterosalpingography or sonohysterography was done a one month later to confirm tubal occlusion. Main outcome measures included safety

phase aimed at confirmed tubal occlusion with minimal harm to adjacent tissues and confirmed tubal occlusion of the functionless hydrosalpnix. The safety phase resulted in bilateral complete occlusion of the proximal part of the tubes with secondary coagulation less than 8 mm as shown in the histopathologic sections. The suspected main cause of functionless hydrosalpnges was iatrogenic (pelvic surgery) in 9 (64%) and 8 (61.5%) cases in both groups respectively. The mean number of abdominal scars/patient was 1.4 and 1.5 in both groups respectively. Unilateral functionless hydrosalpnix was encountered in 7 (50%) and 5 (38%) cases in both groups respectively. In group A, the procedure was possible and successful in 10 cases (76.9%) while in group B, hysteroscopic access and occlusion were achieved in 12 (85.7%) and 9 (64.2%) cases respectively. In group B, diagnostic hysteroscopy showed fine marginal adhesions in 2 cases (15%) and a small polyp in one case (7.7%). Hysteroscopic tubal occlusion showed shorter operative time (9 ±2.76 min vs. 23.6 ±4.75 min, p= 0.0001) and hospital stay (2 ±1.84 hours vs. 5 ±1.13 hours, p= 0.0001). Second-look office hysteroscopy was done in 8 cases of group B which revealed no significant corneal lesions at the site of hysteroscopic occlusion. This preliminary study demonstrates feasibility of hysteroscopic tubal occlusion of functionless hydrosalpnix in all cases with acceptable efficacy. It has the advantage of adding a valuable evaluation of the endometrial cavity prior to IVF/ICSI. It should be an option for treatment protocol in cases of functionless hydrosalpinges. Further large sample-sized studies are required to test its impact on the implantation rate and clinical outcome.

2.a.3 This study aimed to compare the efficacy, feasibility, operative time and possible complications of a modified technique of hysteroscopic removal of big submucus myomata

versus traditional morcellation technique, and to assess the efficacy of preoperative sonohysterography (SHG). Its design was a prospective comparative study done at the Gynecologic Endoscopy Unit, Assiut University Hospital, Assiut, Egypt. It included one-hundred forty-two women in the childbearing period with a clinical and transvaginal sonographic diagnosis of big solitary submucous myomata (> 3 cm in diameter) with or without an intramural element. They were divided into 2 groups. In group A (65 patients), a modified resectoscopic technique was used where the base of the myoma was excised followed by ring forceps extraction after misoprostol priming. Whereas in group B (77 patients), the myoma was cut using the traditional resectoscopic morcellation. For each patient, the operating time, intra and postoperative complications and feasibility of the procedure were recorded. Accuracy of preoperative SHG to localize submucous myoma and detect intramural extension was assessed by the diagnostic hysteroscopy. Transvaginal sonohysterography (SHG) showed good agreement with hysteroscopy in localizing submucous myoma and detecting intramural extension (k= 0.34). The operating time was significantly shorter in group A (15.6 ± 3.02 min) than in group B (28.9 ± 4.3 min). The procedure was completed in 60 (92%) and 51 patients (66%) whereas, second session was required in 2 (3%) and 20 patients (25.9%) in both groups respectively. Glycine volume was highly significantly less in group A (2.3±0.86 vs. 6.3± 1.7 liters,P=.000). Intraoperative complications were encountered in 9 patients (13.8%) and 22 patients (28.5%) in both groups respectively(p=0.03). Postoperative visual disturbances were diagnosed in 4 cases (5%) in group B. It is concluded that hysteroscopic resection of big submucous myomata with minimal intramural encroachment is feasible using a modified technique. It shows minimal complication rate and fluid deficit; and shorter operative time

than the standard morcellation technique. If the excised myoma is extracted as one mass, this carries a minimal risk of cervical lacerations and possible cervical incompetence in subsequent pregnancy. Transvaginal SHG is a reliable diagnostic aid to assess submucous myomata

2.a.4 This study aimed to determine if resectoscopic sectioning of complete uterocervicovaginal septum is as effective as cold knife excision of the vaginal part followed by resectoscopic cutting of the cervicouterine part in symptomatic patients. Its design was a randomized controlled clinical trial. It comprised thirty two women with a diagnosis of complete uterocervicovaginal septum who had a history of pregnancy wastage or infertility. They were randomized into two groups: group A underwent resectoscopic excision of the complete septum starting from the vaginal interoitus; group B underwent cold knife excision of the vaginal part followed by resectoscopic excision of the cervical and uterine parts. Hysteroscopic metroplasty alone or proceeded by cold knife excision of the vaginal part in both groups respectively. Main outcome measures included operating time, perioperative bleeding, complications, reproductive outcome, and patient and husband satisfaction. Patients in group A showed a significant less operative time and scar-related dyspareunia. There were no significant differences in the reproductive outcome in the two groups. It is concluded that resection of the vaginal part of symptomatizing complete vaginocervicouterine septum utilizing resectoscopic metroplasty, makes the procedure faster with less possibility of scar-related dyspareunia than cold knife excision.

2.b.1 The aim of this chapter is to study the serum levels and correlation of vascular endothelial growth factor (VEGF) insulin-like growth factor 1 (IGF-1), hormonal profile,

and Doppler blood flow changes within the ovarian stroma before and after laparoscopic ovarian drilling (LOD) in women with clomiphene-resistant polycystic ovary syndrome (PCOS). We recruited twenty-five women with clomiphene-resistant PCOS (group 1) and 20 women with regular menstrual cycles as a comparison group (group 2). LOD was done for patients in group A. The serum levels of VEGF, IGF-1, T, and LH were significantly higher in group 1 before LOD than in group 2. The Doppler indices (pulsatility index and resistance index) of ovarian stromal blood flow were also significantly lower in group 1 before LOD than in group 2. The serum levels of VEGF, T, and LH were significantly reduced in group 1 after LOD compared with in group 1 before LOD. Doppler indices (pulsatility index and resistance index) of ovarian stromal blood flow were significantly increased after LOD. The VEGF levels before LOD were positively correlated with IGF-1, LH, and T. After LOD, the VEGF levels were positively correlated with LH and T. It is concluded that higher serum levels of VEGF and IGF-1 may explain the increased vascularity that was demonstrated by Doppler blood flow measurements in PCOS. LOD leads to reduced serum VEGF, IGF-1, T, and LH and reduced ovarian blood flow velocities, which may explain the reduction of ovarian hyper stimulation syndrome in women with PCOS after LOD.

2.b.2 This study was conducted to determine the prevalence, extent, and location of adhesion formation following microsurgical monopolar LOD among fertile and infertile women with clomiphene resistant PCO. It is a longitudinal cohort follow up study and recruited three hundred and forty seven patients with PCO scheduled for LOD as a treatment option for clomiphene-resistant anovulation. Microsurgical monopolar LOD was performed in all cases. Two hundred and forty six patients without possible additional

predisposing factor for postoperative adhesion formation were followed-up. To assess the sole effect of LOD on adhesion formation, only 51 eligible patients were classified into two groups; group A comprised 22 women who conceived within six months following LOD and subjected to cesarean section, while group B included 29 women who failed to conceive over the same period of time and subjected to second-look laparoscopy. Main Outcome Measure(s) were evaluation of the prevalence, side, site and severity of pelvic adhesions following microsurgical monopolar LOD. Totally, adhesions were diagnosed in 40 cases (78.4%). Adhesions were diagnosed in 15 cases (68.1%) and 25 cases (86.2%) in groups A and B respectively without a statistically significant difference (p:0.21). Periovarian adhesions were diagnosed in 47/51 (92%) of cases in both groups. In 29(56.8%) cases in both groups, adhesions were diagnosed on both sides (right and left adnexae) divided as 8(36.3%) and 21(72.4%) in groups A and B respectively with a statistically significant difference (p: 0.01). It is concluded that even if microsurgical principles are followed, an inevitable inherent high incidence of periovarian adhesions would be anticipated due to the monopolar electrode firing on direct contact with the ovarian surface with subsequent secondary coagulation. The documented high prevalence of adhesions among infertile as well as women who conceived following LOD is an adding evidence to the established risk of post-LOD adhesion formation. Following microsurgical principles would minimize the risk of these adhesions except periovarian adhesions. There is a bad need for studies on more refinement of LOD to make it as less adhesiogenic procedure as possible.

2.b.3 This part of the thesis was designed to estimate pregnancy rate after surgical treatment of ectopic pregnancy (EP), adnexal torsion, ruptured ovarian cyst and acute

pelvic inflammatory disease (PID) within 1 year of operative laparoscopy (LAS) or laparotomy (LAP) and to define different factors that would affect this pregnancy rate in women desiring fertility in a prospective longitudinal interventional non-randomized study. It comprised a total of 152 patients presenting with gynaecologic emergencies where transvaginal ultrasonography (TVS) was done in all cases. Patients were divided into 2 groups. Diagnostic laparoscopy was done to confirm the diagnosis in 77 cases (group A) which was followed by operative laparoscopic procedures accordingly. In 75 cases (group B) laparotomy was done from the start. In both groups, the procedures were done based on microsurgical principles and intraperitoneal drains were inserted. Positive TVS findings were seen in all cases. EP was diagnosed in 60 (78%) and 52 (69%) patients, while twisted adnexa was diagnosed in 7 (9%) and 12 (16%) patients in both groups respectively. Ruptured ovarian cyst was diagnosed in 6 (7.8%) and 5 (6.7%) cases, whereas PID was diagnosed in 4 (5.2%) and 6 (8%) patients in both groups respectively. On follow-up for 1 year, fertility was significantly higher in LAS group (p=0.001) as 45 (58.4%) and 24 (32%) patients got pregnant in both groups respectively. It is concluded that in patients desiring further fertility, both laparoscopy and laparotomy can achieve fertility preservation following basic microsurgical principles. High fertility is achieved in patients younger than 30 years, in multiparous women, if the contralateral tube is free, if concomitant adhesiolysis is performed and after salpingotomy operation for treating ectopic pregnancy.

4.b. Samenvatting

Sectie 1

De laatste decennia is er een breed scala aan fertiliteit bevorderende technieken, zoals in vitro fertilisatie (IVF) en intracytoplasmische sperma injectie (ICSI), beschikbaar geworden. Ondanks wijdverspreid gebruik van deze technieken, zouden hysteroscopische en ook laparoscopische chirurgie als primaire behandeloptie moeten worden aangeboden aan patiënten met kinderwens en afwijkingen aan de uterus of ovaria. Een vanzelfsprekend voordeel van endoscopische chirurgie, ten opzichte van fertiliteit bevorderende technieken, is dat door correctie van ovariële en/of uteriene afwijkingen ook de kans op spontane zwangerschap wordt vergroot. Dergelijke reconstructieve, endoscopische chirurgie zou tevens kunnen worden ingezet bij fertiele vrouwen met klachten van andere aard, zoals abnormaal uterien bloedverlies. Implementatie van de principes waarvan gebruik wordt gemaakt binnen de microchirurgie en verfijning van het instrumentaria en de technieken, zullen de resultaten van een hysteroscopische of laparoscopische ingreep in de toekomst zeker verbeteren. Verwacht wordt, dat endoscopische chirurgie in de toekomst -gezien de continue vooruitgang binnen de micro-invasieve endoscopische chirurgie en de ontwikkeling van geschikt robot instrumentarium- bij een verscheidenheid aan gynaecologische aspecten zal worden ingezet.

Sectie 2

2.a.1 Het doel van deze studie was, om het effect van vaginaal toegediend misoprostol voorafgaande aan therapeutische hysteroscopie te vergelijken met endocervicale laminariastiften. Een groep van 144 vrouwen, waarbij een intra-uteriene afwijking was gediagnosticeerd, werd gerandomiseerd voor een van de twee cervixrijping technieken voorafgaande aan een therapeutische hysteroscopie. Bij de patiënten in groep A (n 5 72)

werd 200 mg misoprostol vaginaal in de formix posterior ingebracht en bij de patiënten in groep B (n 5 72) laminariastiften intracervicaal. In beide groepen trad er adequate cervixdilatatie op, de gemiddelde cervix diameter was respectievelijk 7.5 6 1.2 en 7.6 6 1.2mm. Er was geen significant verschil in mate van dilatatie of tijdsduur die nodig was tot adequate cervixdilatatie werd bereikt (51.6 versus 51.4 seconden). Wel werden er significante verschillen gevonden in moeite met medicatietoediening en de beleving van de procedure door zowel arts als patiënt. Er werd geconcludeerd dat misoprostol en laminaria even effectief zijn in het tot stand brengen van vlotte, adequate cervixdilatatie voorafgaande aan therapeutische hysterectomie. Toch verdient misoprostol de voorkeur, gezien de medicatietoediening, kosten en patiëntvriendelijkheid.

2.a.2 Deze studie had als doel om vast te stellen of hysteroscopische afsluiting van de tuba even succesvol was als laparoscopische tuba occlusie, bij patiënten met een onfunctionele hydrosalpinx, voorafgaande aan IVF/ICSI. Deze prospectief vergelijkende studie werd uitgevoerd in de 'Endoscopy Unit' van het 'Woman Health Center, Faculty of Medicine, Assiut University, Assiut, Egypte'. Ter evaluatie van de veiligheid van de hysteroscopische methode, werd er voorafgaande aan de studie een pilot gedaan. Daartoe werden, na hysterectomie, de tubae van de uterus van 10 perimenopauzale vrouwen gecoaguleerd met behulp van de 'rollerball' (balvorminge) elektrode. De studie zelf werd gedaan in een groep van 27 patiënten met een uni- of bilaterale hydrosalpinx, die gerandomiseerd werden gescheiden in twee groepen. Uiteindelijk ondergingen 14 patiënten laparoscopische tuba coagulatie (groep A) en 13 patiënten hysteroscopische tuba coagulatie (groep B). In groep A werd de istmus tubae laparoscopisch afgesloten, bij 9 patiënten werd daarvoor gebruik gemaakt van een bipolaire diathermie (64%) en bij 3 patiënten van clips (21.4%). Bij de

patiënten uit groep B werden de tuba ostea gecoaguleerd door middel van een ‘rollerball’ elektrode en een resectoscoop, onder locale, regionale of spinale anesthesie. Zo mogelijk werd er na de primaire ingreep in deze groep een tweede, diagnostische hysteroscopie uitgevoerd. Alle patiënten uit beide onderzoeksgroepen ondergingen één maand na de ingreep een hysterosalpingogram of echoscopie, ter confirmatie van adequate tuba-afsluiting. De gewenste uitkomst, voor zowel de pilot als de daadwerkelijke studie, was een bewezen ondoorgankelijke tuba, met daarbij minimale schade aan omliggende weefsels. Histopathologie van de verwijderde uteri in de pilot studie, toonde beiderzijds totale occlusie van de proximale tubae, en secundaire coagulatie van het omliggende weefsel van <8mm. De meest waarschijnlijke oorzaak van de onfunctionele hydrosalpinx was iatrogeen bij 9 patiënten (64%) uit groep A en 8 patiënten (61.5%) uit groep B. Het gemiddeld aantal abdominale littekens per patiënt was respectievelijk 1.4 en 1.5. De hydrosalpinx was unilateraal in 7 (50%) en 5 (38%) patiënten uit beide groepen. De laparoscopische procedure in groep A was met succes uitvoerbaar bij 10 patiënten (76.9%). In groep B werd toegang tot het cavum verkregen bij 12 patiënten (85.7%), occlusie van de tuba kon worden uitgevoerd bij 9 patiënten (64.2%). In deze groep werden tijdens het hysteroscopisch onderzoek bij 2 patiënten (15%) geringe adhesies gedetecteerd en bij één patiënt een kleine poliep (7.7%). Hysteroscopiosche tuba occlusie ging gepaard met een kortere operatieduur (9 ±2.76 versus 23.6 ±4.75 minuten, p= 0.0001) en kortere ziekenhuisopname (2 ±1.84 versus 5 ±1.13 uur, p= 0.0001). Acht patiënten uit groep B ondergingen een tweede, diagnostische hysteroscopie. In geen geval werd er een significante afwijking gezien, die tijdens de eerste ingreep niet was gediagnosticeerd. Deze preliminaire studie liet zien, dat de hysteroscopie geschikt is om tuba-afsluiting te bewerkstellingen met acceptabele effectiviteit. Deze hysteroscopische methode heeft tevens als voordeel, dat gelijktijdige

evaluatie van het cavum uteri, voorafgaande aan IVF, mogelijk is. Het zou als optie moeten worden geïmplementeerd in behandelprotocollen voor patiënten met niet functionerende hydrosalpingen. Er is echter wel aanvullend onderzoek nodig naar het effect op de embryo implantatie en IVF/ICSI resultaten.

2.a.3 Het doel van deze studie was om zowel het succes, de toepasbaarheid, operatieduur en mogelijke complicaties te evalueren van een gemodificeerde hysteroscopische techniek voor resectie van grote submuceuze myomen ten opzichte van de traditionele morcellatie techniek. Tevens werd de betrouwbaarheid van de transvaginale echografie (TVE) voor het preoperatief diagnosticeren van myomen geobjectiveerd. Deze studie, prospectief vergelijkend in opzet, werd gedaan aan de 'Endoscopy Unit' van het 'Woman Health Center, Faculty of Medicine, Assiut University, Assiut, Egypte'. In totaal werden 142 vrouwen van reproductieve leeftijd geïncludeerd, waarbij op basis van anamnese, lichamelijk onderzoek en TVE een solitair submuceus myoom met een diameter >3cm was gediagnosticeerd, met of zonder intramuraal gelegen gedeelte. De geïncludeerde patiënten werden onderverdeeld in twee groepen. In groep A werd gebruik gemaakt van een gemodificeerde techniek met de resectoscoop; de basis van het myoom werd gereceseerd en vervolgens verwijderd door middel van een ring forceps na cervixrijping met misoprostol. In groep B (77 patiënten) werd het myoom geëxcideerd door middel van conventionele resectoscopische morcellatie. Tijdens elke procedure werd de operatieduur, uitvoerbaarheid en intra- en postoperatieve complicaties genoteerd. De betrouwbaarheid van de TVE voor het lokaliseren van submuceuze myomen en het vaststellen van eventuele intramurale groei werd bepaald aan de hand van de bevindingen tijdens de diagnostische hysteroscopie. De overeenkomst tussen deze twee onderzoeken bleek goed, voor zowel het detecteren van

submuceuze myomen, als eventuele intramurale extensie (k=0.34). De duur van de ingreep was significant korter in groep A ten opzichte van groep B, respectievelijk 15.6 ± 3.02 en 28.9 ± 4.3 minuten. De procedure werd succesvol uitgevoerd bij 60 patiënten (92%) in groep A en 51 patiënten in groep B (66%). Een tweede ingreep was vereist bij respectievelijk 2 (3%) en 20 (25.9%) patiënten. De benodigde hoeveelheid glycine was sterk significant minder in groep A (2.3±0.86 vs. 6.3± 1.7 liter, p=0.000). Complicaties tijdens de ingreep traden op bij respectievelijk 9 (13.8%) en 22 patiënten (28.5%) uit elke groep (p=0.03). Slechts bij 4 patiënten (5%) uit groep B werden er postoperatief verstoringen waargenomen. De conclusies van deze studie waren dat het de gemodificeerde hysteroscopische techniek geschikt is voor het verwijderen van grote submuceuze myomen, met minimale inbreuk op het uterus myometrium. Deze procedure gaat gepaard met minder complicaties, minder vloeistof verbruik en is in kortere tijd uitvoerbaar dan de traditionele morcellatie techniek. Het verwijderen van het myoom als één geheel vermindert tevens de kans op laceratie van de cervix en daarbij het eventuele risico op cervixinsufficiëntie bij een volgende zwangerschap. Ten slotte werd vastgesteld, dat TVE een betrouwbaar onderzoek is voor het diagnosticeren van submuceuze myomen.

2.a.4 Het doel van deze studie was om vast te stellen of resectoscopische resectie van een compleet uterocervicovaginaal septum, bij symptomatische patiënten, even geschikt is als ‘cold knife’ excisie van het vaginale gedeelte van het septum, gevolgd door resectoscopische resctie van het uterocervicale gedeelte. De studie was in opzet een randomized controlled trial. Er werden 32 vrouwen geïncludeerd, met klachten van habituele abortus of infertiliteit, waarbij er een compleet uterocervicovaginal was gediagnosticeerd. Deze vrouwen werden gerandomiseerd voor één van de volgende twee

groepen. Groep A onderging resectopscopische excisie van het gehele septum, beginnend vanaf de vaginale introïtus. Groep B onderging ‘cold knife’ excisie van het vaginale gedeelte van het septum en resectoscopische resectie van het resterende gedeelte. Gemeten eindpunten waren de tijdsduur van de operatie, het al dan niet optreden van peri-operatieve bloedingen, complicaties, de kans op zwangerschap en de tevredenheid van zowel patiënt als haar partner. Bij de patiënten uit groep A was er sprake van een significant kortere operatieduur en postoperatief minder klachten van dyspareunie ten gevolge van littekenweefsel. Er was geen significant verschil in kans op zwangerschap tussen beide groepen. Geconcludeerd werd, dat resectie van het vaginale gedeelte van een uterocervicovaginaal septum door middel van een resectoscopische excisie, in vergelijking met een ‘cold knife’ excisie, resulteert in afname van de operatietijd en minder litteken gerelateerde dyspareunie.

2.b.1 Deze studie beschrijft de serumconcentraties van en correlatie tussen Vascular Endothelial Growth Factor (VEGF), Insulin-like Growth Factor 1 (IGF-1), veschillende hormonen en veranderingen in doorbloeding van het ovariële stroma gemeten met Doppler, voor en na laparoscopische ovariële elektrocoagulatie (LOE), bij vrouwen met een clomifeen resistente polycysteus ovarium syndroom (PCOS). De onderzoeksgroep bestond uit 25 vrouwen met clomifeen resistente PCOS (groep A), de controlegroep uit 20 vrouwen met een regulaire menstruatie cyclus (groep B). Patiënten uit groep A ondergingen laparoscopische drilling van het ovariële kapsel met elektrocoagulatie (LOE). De bloedwaarden van VEGF, IGF-1, testosteron (T) en luteïniserend hormoon (LH) voor LOE waren significant hoger in groep A ten opzichte van groep B. De Doppler metingen, waarmee de doorbloeding van het ovariële stroma kan worden weergegeven (de

zogenaamde ‘pulsatility index’ en ‘resistency index’) waren voor LOE significant lager in groep A. De hoogte van VEGF voorafgaande aan LOE, vertoonde een positieve correlatie met IGF-1, T, and LH. Na LOE bleek er een positieve correlatie te bestaan tussen VEGF en T en LH. Geconcludeerd werd, dat hogere serumconcentraties VEGF en IGF-1 een verklaring zouden kunnen zijn voor de toegenomen vascluariteit van polycysteuze ovaria gemeten door middel van Doppler. LOE leidt tot afname van VEGF, IGF-1, T en LH in het bloed en reduceert de snelheid van de bloedstroom door de ovaria. Dit mechanisme zou ten grondslag kunnen liggen aan de afname van het risico op het ovarieel hyperstimulatie syndroom bij vrouwen met PCOS, die een LOE hebben ondergaan.

2.b.2 Deze studie werd uitgevoerd, om de prevalentie, uitgebreidheid en lokalisatie van adhesies na unipolaire LOE te verifiëren in een groep fertiele en infertiele vrouwen met clomifeen resistente PCOS. In het kader van deze longitudinale, cohort follow-up studie werden 347 vrouwen met PCOS geïncludeerd. Al deze vrouwen ondergingen unipolaire LOE als microchirurgische behandeloptie voor clomifeen resistente anovulatie. Van deze groep werden 246 patiënten, zonder andere mogelijk predisponerende factoren voor het postoperatief ontstaan van adhesies, vervolgd in een follow-up periode van 6 maanden. Uiteindelijk konden slechts 51 patiënten worden geselecteerd om het effect van uitsluitend de LOE zelf te evalueren. Deze patiënten werden onderverdeeld in twee groepen. Groep A bestond uit 22 vrouwen, die binnen 6 maanden na LOE zwanger waren geworden en hadden gekozen voor een sectio ceasarea. Groep B werd gevormd door 29 vrouwen die binnen de follow-up periode niet zwanger waren geworden en bereidwillig waren een tweede, diagnostische laparoscopie te ondergaan. In beide groepen werd de prevalentie, lokalisatie en uitgebreidheid van pelviene adhesies na unipolaire LOE geëvalueerd. In

totaal werden er bij 40 patiënten (78.4%) adhesies gediagnosticeerd, bij 15 patiënten uit groep A (68.1%) en 25 patiënten uit groep B (86.2%). Dit verschil was niet significant (p=0.21). Peri-ovariële adhesies werden gezien bij 47 van de 51 patiënten (92%). Bij 29 patiënten (56.8%) was er sprake van beiderzijdse adhesievorming. Daarvan behoorden significant minder patiënten tot groep A (8, 36.3%) dan tot groep B (21, 72.4%) (p=0.01). Er werd geconcludeerd dat zelfs deze microchirurgische aanpak resulteert in een onontkoombare hoge incidentie van peri-ovariële adhesies, ten gevolge van direct contact van de unipolaire elektrode met het ovarium, dat gepaard gaat met secundaire coagulatie. De gerapporteerde hoge prevalentie van adhesies onder zowel fertiele als infertiele vrouwen, draagt bij aan het bewijs voor het reeds eerder vastgestelde risico van adhesievorming na LOE. Gebruik van microchirurgie zou de kans op het ontstaan van adhesies minimaliseren, de kans op peri-ovariële adhesies uitgezonderd. Er is grote vraag naar verdere ontwikkeling van de verfijndheid van LOE, om ervoor te zorgen dat het risico op adhesievorming na deze ingreep wordt geminimaliseerd.

2.b.3 Deze studie beschrijft de kans op zwangerschap binnen één jaar na laparoscopische (LAS) of laparotomische (LAP) behandeling van een ectopische zwangerschap (EZ), ovariële torsie, geruptureerde ovarium cyste of Pelvic Inflammatory Disease (PID). In deze prospectieve, longitudinale, niet-gerandomiseerde interventie studie werden tevens de verschillende factoren bepaald, die van invloed zijn op de zwangerschapskans bij deze vrouwen met kinderwens. Er werden in totaal 152 vrouwen geïncludeerd, die zich presenteerden met spoedbehoevende gynaecologische aandoeningen en een TVE hadden ondergaan. De patiënten werden onderverdeeld in twee groepen. Ter bevestiging van de diagnose ondergingen alle 77 patiënten uit groep A een diagnostische laparoscopie, gevolgd

door een operatieve laparoscopische ingreep. Bij de 75 patiënten uit groep B werd er direct besloten om een laparotomie uit te voeren. In beide groepen werd er gehandeld op basis van microchirurgische principes en werden intraperitoneale drains geplaatst. De bevindingen bij de TVE bleken correct in alle gevallen. De diagnose EP werd gesteld bij 60 patiënten (78%) uit groep A en 52 patiënten (69%) uit groep B. Er was sprake van een torsie van het ovarium bij respectievelijk 7 (9%) en 12 (16%) patiënten. Bij 6 (7.8%) en 12 (16%) patiënten werd er een geruptureerde ovarium cyste gedetecteerd en PID bij respectievelijk 4 (5.2%) en 6 (8%) patiënten. Na een follow-up periode van één jaar, bleek de mate van fertiliteit significant hoger in de LAS groep (p=0.001), aangezien er 45 (58.4%) patiënten uit groep A en 24 (32%) patiënten uit groep B zwanger raakten. Geconcludeerd werd, dat zowel laparoscopie als laparotomie de fertiliteit van patiënten met kinderwens waarborgen, zolang er wordt gehandeld naar de principes van minimaal invasieve chirurgie. Factoren die de kans op zwangerschap verhogen zijn: leeftijd <30 jaar, multipariteit, aanwezigheid van een onaangedane contralaterale tuba en het gelijktijdig uitvoeren van adhesiolyse in geval van salpingotomie vanwege een ectopische graviditeit.

4.b. Publications

1994

Keckstein J, Karageorgieva E, Darwish A, Grab D, Paulus W, Tuttlies F. Laparoscopic Myomectomy: Sonographic Follow-Up and Second-Look Laparoscopy for the Evaluation of a New Technique. Journal of American Association of Gynecologic Laparosopists. Vol 1 (4, Part 2):S16, 1994.

1998

Darwish A, Gadallah H. One-step management of cervical lesions. Int J Gynaecol Obstet. 1998;61(3):261-7

1999

Darwish AM, Youssef AA. Screening sonohysterography in infertility. Gynecol Obstet Invest. 1999;48(1):43-7.

Darwish AM, Makhlouf AM, Youssof AA, Gadalla HA. Hysteroscopic myometrial biopsy in unexplained abnormal uterine bleeding.Eur J Obstet Gynecol Reprod Biol. 1999;86(2):139-43.

Darwish A. Laparoscopic evidence of upper genital schistosomiasis. J Obstet Gynaecol 1999;19(2):122-124.

Darwish A, Hassan ZZ. Intraperitoneal bupivacaine vs. tramadol for pain relief following day case laparoscopic surgery. Gynaecological Endoscopy 1999, 8,169-173.

2000

Darwish AM, Amin AF, El-Feky MA. Ovarioscopy, a technique to determine the nature of cystic ovarian tumors. J Am Assoc Gynecol Laparosc. 2000;7(4):539-44.

Kamel HS, Darwish AM, Mohamed SA. Comparison of transvaginal ultrasonography and vaginal sonohysterography in the detection of endometrial polyps. Acta Obstet Gynecol Scand. 2000 Jan;79(1):60-4.

Amin AF, Darwish AM, Makhlouf AM, Salem HT, Zareh ZE Endoscopic management of chronic pelvic pain. MEFS J 2000;5(1):57-61.

2001

Darwish A. M., Amin A. F., Abdel-Aleem M.A., Youssef M. A. Laparoscopic management of benign adnexal masses: experience in a developing country Gynaecological Endoscopy 2001;10, 159-165.

2002

Atef M. Darwish and Zein E. A. Zareh Hassan Haemodynamic, biochemical and haematological changes during hysteroscopic myomectomy. Gynaecological Endoscopy 2002;11, 6:349-53.

Darwish A, Hassan ZZ. Feasibility of laparoscopic abdominal cerclage in the second trimester. Gynaecological Endoscopy 2002, 11,327-329.

2003

Ahmed F. Amin, Diaa-Eldeen M. Abd El Aal, Atef M. Darwish, Abdel-Raheim M. A. Meki. Evaluation of the impact of laparoscopic ovarian drilling on Doppler indices of ovarian stromal blood flow, serum vascular endothelial growth factor, and insulin-like growth factor-1 in women with polycystic ovary syndrome Fertility Sterility 2003; 79,4:938-4.

Atef M. Darwish, Ahmad F.Amin, Safwat A. Mohammad. Laparoscopic management of paratubal and paraovarian cysts. Journal of the Society of Laparoendoscopic Surgeons 2003;7,2 :101-6.

Darwish A. Modified hysteroscopic myomectomy of large submucous fibroids. Gynaecol Obstet Invest. 2003;56(4):192-6.

Darwish A. Female genital organ transplantation in Islamic countries.MEFS J 2003; 8, 3, 7-15.

2004

A.M. Darwish, A.M. Ahmad, A.M. Mohammad Cervical priming prior to operative hysteroscopy: a randomized comparison of laminaria versus misoprostol Human Reproduction 2004;19(10):2391-2394.

Darwish A, Labeeb S, Galal M, Rashad H, Hassan S. Cervical changes associated with progestagen-only contraceptives: a team approach. Contraception. 2004 ; 69(2):121-7.

2005

Darwish AM, Nasr AM, El-Nashar DA. Evaluation of Postmyomectomy Uterine Scars. J Clin Ultrasound 2005;26;33(4):181-186.

Darwish AM, Hafez E, El-Gebali I, Hassan SB. Evaluation of a novel vaginal bromocriptine mesylate formulation: A pilot study. Fertil Steril. 2005;83(4):1053-5.

Darwish AM, Makarem MH, Alnashar EM, Hamadeh SM. Screening for bacterial vaginosis in high-risk pregnancy: the experience of a developing country. Acta Obstet Gynecol Scand. 2005;;84(5):483-5.

2006

Atef M.Darwish, Hassanin, M.S. Abou Sekkin I.A. Epidemiology and risk factors associated with laparoscopically diagnosed typical and atypical endometriosis among Egyptian women. Middle East Fertility Society Journal 2006;11,3,196-201.

2007

Atef M. Darwish, Mahmoud Zhakhera and Alaa A. Youssef. Fertility after laparoscopic management of gynaecologic emergencies: the experience of a developing country. Gynaecological Surgery 2007;4,2, 85-90.

Atef M.M. Darwish. A simplified novel laparoscopic formation of neovagina in cases of Mayer-von Rokitansky-Kuster-Hauser syndrome Fertil Steril. 2007;88(5):1427-30.

Atef M. Darwish, Ali M. ElSaman. Is there a role for hysteroscopic tubal occlusion of functionless hydrosalpinges prior to IVF/ICSI in modern practice? Acta Obstetricia et Gynecologica Scandinavica 2007; 86,12, 1484 – 1489.

Atef. Darwish, Ehab M. Elnshar, Suha . M. Hamadeh, Mohammad H. Makarem Treatment Options of Bacterial Vaginosis in High-risk Patients of Preterm Labor and Premature Rupture of Membranes J Obstet Gynaecol Res. 2007;33(6):781-787.

Atef M. Darwish, Emad Farah, Wafaa A. Gadallah, Ibraheem I Mohammad Superiority of newly developed vaginal suppositories over vaginal use of commercial bromocriptine tablets: a randomized controlled clinical trial. Reproductive Sciences 2007; 14(3);280-85.

Atef M. Darwish, Ehsan Hafez, Ibraheem El-Gebali, Sahar B. Hassan, Mohammad E. Ali Rectal versus vaginal bromocriptine mesylate suppositories in hyperprolactinemic patients : an active comparator trial . MEFS Journal, 2007,12,2:25-29.

2008

Atef M Darwish, Ahmad M El-Sayed, Suasan A El-Harrasb (Late), Khaled A Khaled, Mohamad A Ismail Clinical Efficacy of Novel Unidirectional Buccoadhesive vs. Vaginoadhesive Bromocriptine mesylate Discs for Treating Pathologic Hyperprolactinemia. Fertil Steril. 2008 Nov;90(5):1864-8.

Atef M. Darwish, Ali M. ElSaman. Extended resectoscopic versus sequentional cold knife–resectoscopic excision of the unclassified complete uterocervicovaginal septum: a randomized trial. Fertility Sterility Aug 2008, online.

2009

Darwish AM, Mohamad SN, Gamal Al-Din HR, Elsayed YA, Ahmad SI.. Third trimester prevalence and predictors of deficient dietary calcium intake: the experience of a developing country. J Obstet Gynaecol Res. 2009 Feb;35(1):106-12.

Darwish AM, AbdelAleem MA, Ismail AM. Risk of adhesions formation following microsurgical monopolar laparoscopic ovarian drilling: a comparative study. Gynecological Surgery 2009 May; Volume 6 Number 2, 135-141.

Ali M. El Saman, Darwish AM, Zakherah MS, Hamed HO, Bedaiwy MA, Nasr AM. Tactile Cold Scissor Metroplasty as a Novel Backup Method for Hysteroscopic Metroplasty. Fertility Sterility 2009; In press.

Atef Mohammad Darwish. Fine needle vaginoplasty: a simplified novel approach for correction of vaginal aplasia.. Fertility Sterility 2009, in press**.**

Wafaa A. Hassan, Atef M. Darwish, Emad Farah. Hormonal changes associated with menstrual dysfunction in pulmonary tuberculosis. Middle East Fertility Society Journal 2009; Vol. 14, No. 2, 23-29.

Atef M. Darwish. Fertility-enhancing Reconstructive Endoscopic Myomectomy in modern practice. Middle East Fertility Society Journal 2009; Vol. 14, No. 2, 25-29.

Atef M. Darwish, Zein Z. Hassan, Alaa M. Attia , Sherif S. Abdelraheem., Yahya M. Ahmed. Biological effects of distension media in bipolar vs. monopolar resectoscopic myomectomy: A randomized trial. J Obstet Gynaecol Res. 2009, in press.

Wafaa A. Hassan, Atef M. Darwish. Impact of pulmonary tuberculosis on menstrual pattern and fertility. Chest 2009, in press.

Atef M. Darwish. TRT vaginoplasty: a novel minimally access retropubic approach for correction of vaginal aplasia. International Journal of Gynecology and Obstetrics. 2009; In press.

4.d. CURRICULUM VITAE (C.V.)

Dr Atef Darwish was born in Assiut, Egypt in 1961. He graduated from Assiut School of Medicine, Egypt in 1985 with an excellent grade with first class honors. He completed a residency in Obstetrics and Gynaecology at the departments of Obstetrics and Gynaecology, Assiut (Assiut) and Ain-Shams (Cairo) in 1986-1989. He got his Master degree in 31.12.1989 with Excellent degree. Between 1992-1994, he spent completed 2 years at the Endoscopic Unit of Ulm University, Germany. Therafter, he received his Medical Doctorate in 1995 through a combined program between the University of Ulm, Ulm, Germany and the University of Assiut, Assiut, Egypt with Excellent degree. Thereafter, he joined many center in the US and Europe concentrating on the reproductive medicine. He joined the Endoscopy Unit of Villach University Hospital in Austria, the Assisted Reproduction Unit in Düsseldorf University Hospital in Germany and the reproductive biology and minimally invasive surgery unit in the Cleveland Clinic Foundation, Clevland, Ohio, USA.

Currently, he is a Professor of Obstetrics and Gynaecology, Faculty of Medicine, Assiut University since July 2005. Moreover, he is a consultant of Obstetrics and Gynecology in three hospitals; Woman's Health University Center, Police Hopital (Assiut branch), and Assiut Fertility and Endoscopic surgery center. He is the moderator of the "Egyptian Society of Hysteroscopy and Colposcopy". Likewise, he is a registered trainer and lecturer of the "Egyptian Society of Gynecologic Laparoscopists" which is affiliated to the European Society of Gynecologic Endoscopy (ESGE).

Dr Darwish authored an internationally registered undergraduate book, presented 59 presentations in national and international meetings, delivered a lot of lectures in Egypt, some Arabian countries and the USA and published 39 papers in international medical

journals, and 7 papers in national journals. Dr Darwish received some congress prizes and awards due to his work in the field of reproductive medicine since 1995. In 2006, he got Assiut University Scientific Prize for his distinguished research and publications in the last 8 years. Now, he is a reviewer of Fertility Sterility Journal, Human reproduction Journal, International Journal of Gynecology and Obstetrics, Journal of Obstetric and Gynaecologic Research, International Journal of Medicine and Medical Sciences and many other journals. Recently, he has been selected as an associate editor of the Middle East Fertility Society Journal. His special interest has been in the area of gynaecologic laparoscopy and hysteroscopy, reproductive medicine, and assisted reproduction.

4.e. Acknowledgements

Any clinical study is never a work of one person. The author would sincerely thank all persons shared by diffent means in the contribution of this thesis. Firstly, thanks go to dear patients who kindly accepted to participate in the studies of this thesis free of charge. Moreover, the effort exerted by the coauthors should not be ignored. Assiut University woman's health staff and the operating room teams generously shared in all studies of this thesis. I can't forget my teachers and professors who offered me the best chance of getting experience in endoscopic surgery.

Special thanks go to Nick Macklon, who opened the door for the existence of this thesis since November 2006 and guided me althrough this work with his valuable notes. Likewise, I would like to thank Frank Broekmans who offered me time and effort during his revision of this thesis. Lastly, I should thank the staff of the University of Utrecht for accepting this thesis to be recognized by this distinguished university which is a great honor to any researcher in the field of reproductive medicine.