

## CHAPTER 4

### **Ultrasonographic differentiation of hyperammonemic conditions in dogs**

based on the article by

**Viktor Szatmári<sup>1</sup>,  
Jan Rothuizen<sup>2</sup>, Ted S. G. A. M. van den Ingh<sup>3</sup>,  
Frederik J. van Sluijs<sup>2</sup>, George Voorhout<sup>1</sup>**

Ultrasonographic findings in dogs with hyperammonemia: 90 cases (2000-2002)

*Journal of the American Veterinary Medical Association*  
2004;224:717-727.

<sup>1</sup>Division of Diagnostic Imaging

<sup>2</sup>Department of Clinical Sciences of Companion Animals

<sup>3</sup>Department of Pathology

Faculty of Veterinary Medicine

Utrecht University, Utrecht, The Netherlands

## Summary

Abdominal ultrasound examinations were performed in 90 dogs with hyperammonemia. Hyperammonemia was the result of urea cycle enzyme deficiency, or portosystemic shunting either via congenital shunts or acquired collaterals. Six basic types of congenital portosystemic shunts were found. Intrahepatic shunts originated from the left or from the right portal branch and entered the caudal vena cava, whereas extrahepatic shunts originated either from the splenic vein or from the right gastric or both (double shunts) and terminated in the abdominal caudal vena cava or entered the thorax. Acquired portosystemic collaterals were the result of arteriportal fistulae, primary hypoplasia of the portal vein, or chronic hepatitis. Arteriportal fistulae were diagnosed ultrasonographically, and primary hypoplasia of the portal vein and chronic hepatitis by histopathologic examination of liver biopsy specimen. Nine hyperammonemic pups with normal abdominal vascular anatomy were suspected to have urea cycle enzyme deficiency.

## Structured abstract

**Objectives**—To describe the ultrasonographic findings of the various conditions that lead to hyperammonemia in dogs, and the criteria how these conditions can be ultrasonographically identified.

**Design**—Prospective study.

**Animals**—90 client-owned dogs with high blood ammonia levels.

**Procedure**—Ultrasound examinations of the abdominal vessels and organs were performed in a systematic way. When ultrasonography revealed a congenital portosystemic shunt, surgical shunt-ligation was performed. When ultrasonography revealed acquired portosystemic collaterals or normal abdominal vasculature, liver biopsies were taken for histopathologic examination.

**Results**—Ultrasonography excluded portosystemic shunting in 11 dogs. Acquired portosystemic collaterals were found in 17 dogs, of which 3 had arteriportal fistulae and 14 other hepatic pathologies. Congenital portosystemic shunts were found in 61 dogs, of which 19 had intrahepatic and 42 extrahepatic shunts. Intrahepatic shunts originated from the left portal branch in 14 dogs and from the right portal branch in 5 dogs. Shunts from the right portal branch were either short or long vessels. Extrahepatic shunts originated either from the splenic vein, or from the right gastric vein (single shunts) or simultaneously from both of them (double shunts) and entered the abdominal caudal vena cava or the thorax. Ultrasonography revealed spleno-caval shunts in 24 dogs, right gastric-caval shunts in 9 dogs, spleno-azygos shunts in 8 dogs and right gastric-azygos shunt in 1 dog.

**Conclusions and Clinical Relevance**—Ultrasonography is a reliable diagnostic tool to identify and characterize congenital portosystemic shunts and to recognize acquired portosystemic collaterals as well as to exclude portosystemic shunting. A dilated left gonadal vein as a result of spleno-renal collateral-circulation was a reliable indicator of acquired portosystemic collateral-circulation.

## Introduction

High blood ammonia levels in dogs are usually the results of one of 3 well-defined conditions: **acquired portosystemic collaterals (APSCs)**, **congenital portosystemic shunts (CPSSs)** or urea cycle enzyme deficiency.<sup>1,2</sup>

Portosystemic shunting occurs when anomalous veins allow the portal blood to enter the systemic veins directly without first flowing through the hepatic sinusoids. Acquired portosystemic collaterals are formed as the result of sustained hepatic or prehepatic portal hypertension by enlargement of extrahepatic rudimentary vessels, through which no blood normally passes.<sup>2,3</sup> Collateral-formation is a compensatory mechanism to maintain normal portal pressure by allowing the portal blood to be drained into the lower pressure systemic veins. Since the causes that lead to APSC-formation are either congenital (e.g. arteriportal fistulae) or acquired disorders (e.g. liver cirrhosis), APSCs can develop at any age and in any breed.<sup>2,4-7</sup> Posthepatic portal hypertension (e.g. right-sided heart failure) never results in APSC-formation because not only the portal pressure, but also the pressure in the **caudal vena cava (CVC)** increases.<sup>2,6</sup> A common consequence of any kind of portal hypertension is accumulation of free abdominal fluid, however portal hypertension cannot be excluded in the absence of ascites.<sup>2,8</sup>

Portosystemic shunting is considered to be congenital when a single or double anomalous vein is present without a concurrent portal hypertension.<sup>5</sup> Congenital portosystemic shunts are classified as intrahepatic and extrahepatic.<sup>5,9</sup> Intrahepatic CPSSs tend to occur in large breeds and result in hepatic encephalopathy usually under the age of one year,<sup>9,10</sup> whereas extrahepatic CPSSs occur predominantly in small breeds and can cause symptoms in young animals but may also remain clinically silent until old age.<sup>5</sup> The etiology of CPSSs is obscure except for the left-sided intrahepatic CPSS, which is believed to be a persistent ductus venosus.<sup>11,12</sup>

Urea cycle enzyme deficiency is a rarely detected congenital disease characterized by decreased activity of one or more enzymes that transform ammonia to urea.<sup>1</sup>

In addition to these 3 pathological conditions, healthy Irish wolfhound pups have a physiological period of transient hyperammonemia.<sup>13</sup>

Exceptionally, hyperammonemia may also be caused by conditions when ammonia-containing urine, as a result of the activity of urea-splitting microorganisms, has the possibility to be absorbed into the systemic circulation. This could happen in dogs with ruptured urinary bladder or urethra<sup>14</sup> or after a surgical ureterocolonic anastomosis.<sup>15</sup>

Ammonia is one of the toxins that plays a role in the development of hepatic encephalopathy, therefore an increased blood ammonia level can confirm that the central nervous symptoms of a dog are indeed in association with hepatic encephalopathy, or can reveal that the underlying cause of aspecific clinical symptoms is related to hyperammonemia. Elevated bile acids levels are also sensitive, however in contrast to hyperammonemia, are less specific indicators of portosystemic shunting,<sup>a</sup> since cholestasis and diffuse hepatocellular dysfunction, which may accompany several hepatic disorders, can also result in increased serum bile acids levels.<sup>16</sup>

Differentiating CPSSs from APSCs and from urea cycle enzyme deficiency non-invasively is crucial because CPSSs require surgical treatment and the other two conditions do not. Though ultrasonography is a quick and non-invasive technique to image the abdominal vessels and organs in unsedated dogs, veterinarians tend to rely on the results of angiographic studies.<sup>6,17,18</sup> According to our knowledge, the ultrasound-anatomy of the

different types of CPSSs and APSCs have not been described in dogs yet. The few reports that have been published about ultrasonography of portosystemic shunting focus only on some aspects of CPSSs without detailed anatomic descriptions.<sup>12, 18-22</sup>

Our aims are to describe the ultrasonographic findings of the conditions that result in hyperammonemia in dogs and the ultrasonographic anatomy of the different kinds of CPSSs. We demonstrate that ultrasonography is a reliable method to diagnose CPSSs and APSCs, and to identify the subtypes of CPSSs as well as to rule out portosystemic shunting.

## Materials and methods

Of the dogs that underwent an abdominal ultrasound examination because of hyperammonemia at the Companion Animal Clinic of Utrecht University between July 2000 and December 2002 those were selected that were scanned by the first author and in which a definitive diagnosis was available based on laparotomy or necropsy or histopathologic examination of the liver or had characteristic ultrasonographic signs of arterioportal fistulae (ie, an extremely dilated and tortuous portal branch). Hyperammonemia was diagnosed when the 12-hour-fasting blood ammonia level exceeded the upper normal value (reference range, 24 to 45  $\mu\text{mol/L}$ ). Ninety client-owned dogs fulfilled the inclusion criteria. The animals were not sedated or anesthetized for the ultrasound examination except for a litter of 4 pups because anesthesia was necessary for blood sampling, and one dog that was anesthetized because the suspected anomalous vein could not be visualized in a conscious state, whereas the ultrasonographic findings were compatible with a left-sided intrahepatic CPSS. The examination of this dog was repeated under general anesthesia. No other cases required anesthesia or repeated examination.

When CPSS was the ultrasonographic diagnosis, the dog was subjected to surgical shunt-ligation, unless the owner did not agree with the surgical intervention or the dog was older than 5 years. Only the dogs that underwent a laparotomy or a necropsy were included in the study. Each surgery was performed by one surgeon (FJvS) according to a described protocol.<sup>23</sup>

When portal hypertension with APSCs was the ultrasonographic diagnosis, ultrasound-guided core biopsies of the liver were taken for histopathologic examination, unless the blood coagulation parameters were unsatisfactory. Only the dogs whose livers were histologically examined were included in the study.

When ultrasonography revealed a normal abdominal vascular anatomy without any evidence of portal hypertension or anomalous vessels, then a rectal ammonia tolerance test was performed according to a described method.<sup>24</sup> When the test indicated abnormal ammonia metabolism, a scintigraphy was performed by injecting <sup>99m</sup>Tc-macroaggregates into a parenchymal splenic vein under ultrasound guidance according to a described protocol,<sup>25</sup> and ultrasound-guided core biopsies of the liver were taken for histopathologic examination.

When a dog was examined more than once because of complains related to hyperammonemia in a later time point, only the first examination was included in this study, ie, re-checks are not.

First a B-mode abdominal ultrasound examination was performed [ATL HDI 3000 (Advanced Technology Laboratories) high definition ultrasound system equipped with a 7-4 MHz broad band phased array and a 8-5 MHz broad band curved linear array transducer,

Philips Medical Systems] paying special attention to the presence and amount of free abdominal fluid. The quantity of peritoneal effusion was subjectively estimated and the following categories were established: large amount when the ascites was detectable by physical examination, moderate amount when the ascites was undetectable by physical examination but seemed to be reasonably large amount ultrasonographically, and small amount if thorough ultrasonographic search was needed to detect free abdominal fluid. Ultrasonographic evaluation of the abdominal vasculature was performed in 7 standard planes according to a described protocol (**Chapter 5**). Shortly, with the dog in left lateral recumbency transverse sections of the portal vein and the portal branches were obtained via the right intercostal spaces and longitudinal sections via the right flank. With the dog in dorsal recumbency longitudinal sections of the portal vein were obtained via the ventral body wall. With the dog in right lateral recumbency longitudinal sections were made via the left flank to image the right gastric-caval shunts and the left gonadal vein.

## Results

Ultrasonography of the 90 dogs revealed: normal abdominal anatomy in 11 dogs, CPSS in 61 dogs, APSCs due to arterioportal fistulae in 3 dogs and APSCs due to portal hypertension of hepatic origin in 14 dogs. In one dog both arterioportal fistulae and a CPSS were simultaneously present.

### Normal ultrasound-anatomy

No abnormalities were found ultrasonographically in 11 dogs. In 2 of these dogs repeated measurements of blood ammonia levels and the results of the rectal ammonia tolerance tests were normal.

In the remaining 9 dogs (puppies of 3 litters) the ammonia tolerance tests were abnormal, the serum bile acids levels were normal, scintigraphy excluded portosystemic shunting, ultrasonography revealed a small amount of free abdominal fluid and histopathologic examination of the liver biopsy specimens revealed normal findings. This was found in a litter of 4 Belgian Malinois pups, a litter of 2 cairn terrier pups and in 3 Irish wolfhounds of a litter of 4 pups. (The fourth Irish wolfhound pup of the litter had a left-sided intrahepatic CPSS.) The age of the litters were 48, 59 and 63 days. Metabolic examination of blood and liver samples of the 3 Irish wolfhound pups revealed arginino-succinate synthetase enzyme deficiency.

### Congenital portosystemic shunts

Congenital portosystemic shunt was the ultrasonographic diagnosis in 61 dogs. The liver was always small, sometimes to such an extent that parts of the stomach were in direct contact with the diaphragm. Free abdominal fluid was seen only in young puppies and its amount was always small.

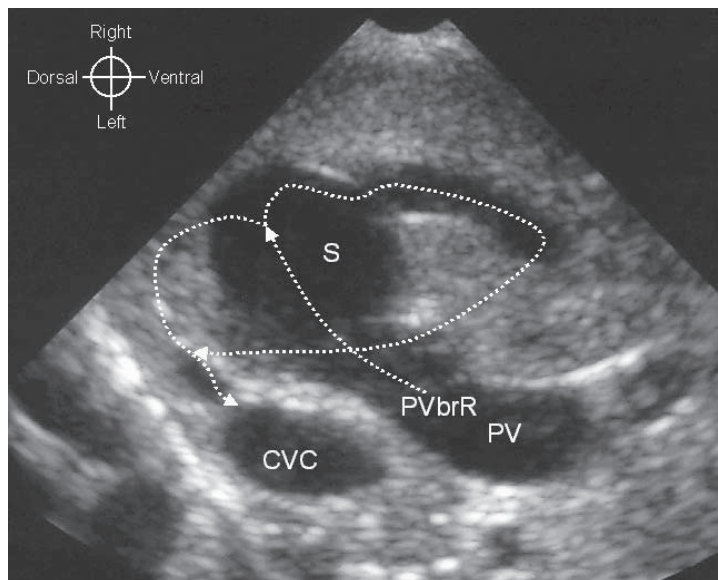
Congenital portosystemic shunts were categorized into intrahepatic and extrahepatic CPSSs based on the origin of the shunt.

*Intrahepatic portosystemic shunts* were diagnosed in 19 dogs. The mean (range) age of the dogs at surgery was 5.9 (2.5-17.6) months. Only large breeds were represented except for a border collie. Intrahepatic CPSSs originated either from the left (14/19 dogs) or from the right portal branch (5/19 dogs) and appeared as the direct continuations of the

**portal vein trunk (PV)** as the diameters of the shunt and of the affected portal branch were the same as that of the PV. All intrahepatic CPSSs terminated in the CVC either directly or via a hepatic vein. The intrahepatic CPSS was a single vein in 18 dogs and was double in one dog (**Fig 1**).

Intrahepatic CPSSs that originated from the left portal branch ran always cranioventrally and to the left (similarly to a normal left portal branch) until the diaphragm, then turned abruptly dorsally to enter the CVC via a dilated segment of the left hepatic vein. In these dogs the right portal branch could not be visualized. A thin vessel with fast hepatopetal flow that was found at the place where the right portal branch was expected, appeared to be a hepatic arterial branch examined by pulsed-wave Doppler mode.

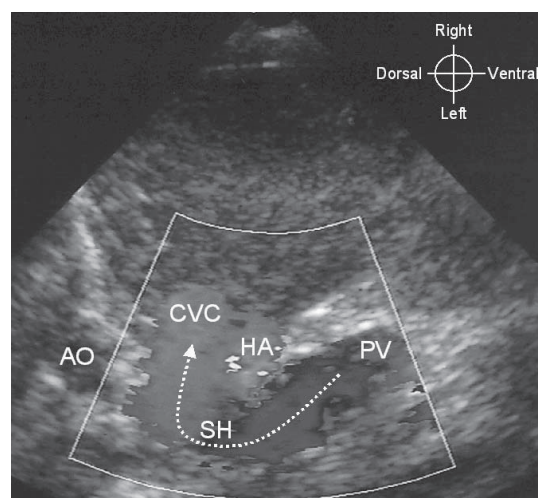
Intrahepatic CPSSs that originated from the right portal branch had a segment that consistently ran dorsolaterally and to the right from the PV, like a normal right portal branch, but then, instead of ramifying, turned medially to enter the CVC. This dorsolaterally running segment was either short (2/5 dogs) or long (3/5 dogs). One of the long shunts (in the border collie) was double (**Fig 1**). Whatever morphology of a right-sided intrahepatic CPSS had, the left portal branch could never be found.



**Figure 1.**

Right divisional congenital *intrahepatic porto-caval* shunt. Gray scale ultrasound image of the right portal branch of a 3-month-old female border collie with a double intrahepatic porto-caval shunt originating from the right portal branch (PVbrR). At the end of the wide right portal branch a sinus (S) is seen, from which two shunt-loops arise: one courses ventrally and the other one dorsally (the dorsal loop cannot be seen in this image, but is indicated with an arrow). The ventral loop turns back to dorsal after a medial loop, then after the confluence with the dorsal loop a short common trunk enters the caudal vena cava (CVC).

*Extrahepatic portosystemic shunts* were diagnosed in 42 dogs. The mean (range) age of the dogs at surgery was 16.0 (2.9-66.4) months. Only small breeds were represented except for a Labrador retriever. Extrahepatic CPSSs originated from the splenic vein, from the right gastric vein, or from both and entered either the abdominal CVC or the thorax. Extrahepatic CPSSs were divided into 4 groups based on their origins and terminations: 24 dogs had a spleno-caval, 9 a right gastric-caval, 8 a spleno-azygos and 1 a right gastric-azygos shunt. Shunts with two loops (one arising from the right gastric vein and the other one from the splenic vein) were categorized as right gastric shunts because the right gastric vein was the main loop and this had an identical morphology with the single shunts that arise from the right gastric vein. These categories were established based on the ultrasonographic results and were in agreement with the surgical findings.

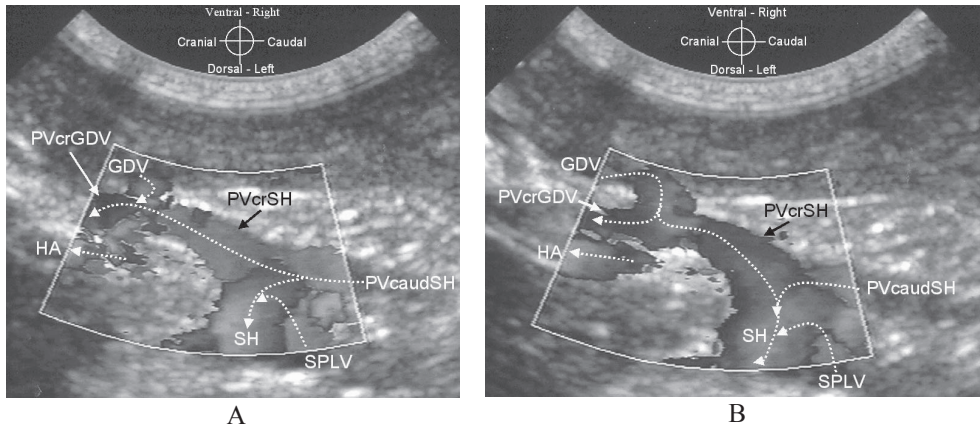


**Figure 2.**

Congenital *extrahepatic spleno-caval* shunt in a 3.5-month-old female Jack Russell terrier. Cross sections of the aorta (AO), caudal vena cava (CVC), hepatic artery (HA) and portal vein (PV) are seen. A short anomalous vein (SH) makes direct connection between the PV and the CVC on their left side. Color Doppler mode reveals that the direction of flow in the shunt is from the PV towards the CVC. The arrow indicates the direction of blood flow. (Color version on page 177.)

The most common type of congenital CPSS was the spleno-caval shunt. This usually formed a short single loop between the PV and the CVC (**Fig 2**). Although in 2 dogs the anomalous vein had a long cranial loop, the points of origin and termination were the same as in cases of short loops. Spleno-caval CPSSs originated from the splenic vein. Since the point of origin was very close to the point where the splenic vein entered the PV and the short segment of the splenic vein that was between the PV and the shunt-origin was dilated and the flow hepatofugal in it, the CPSS seemed to originate from the PV itself and the splenic vein seemed to enter the shunting vessel (**Fig 3A**). The origin of the spleno-caval shunts was slightly cranial to the level where the celiac artery originated from the aorta. The termination of the spleno-caval shunts in the CVC was always at the same point, slightly cranial to the level of shunt-origin (**Fig 4A**).



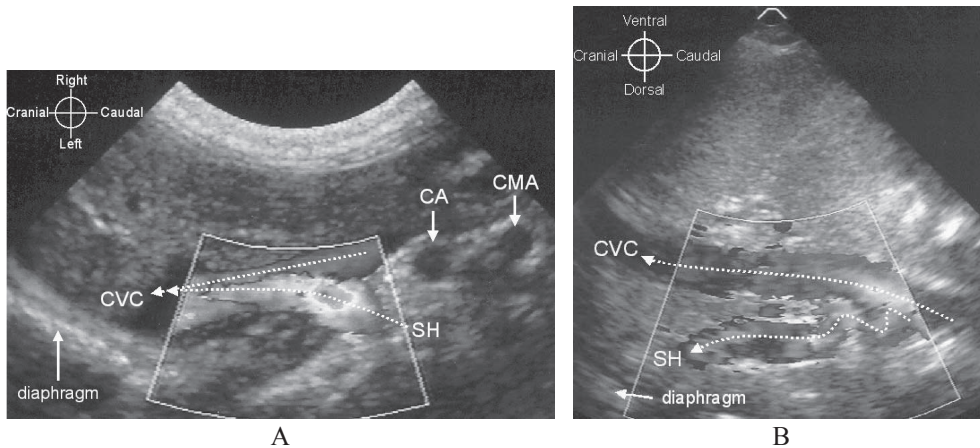


**Figure 3.**

Color Doppler images of a congenital extrahepatic spleno-caval shunt in a 4-month-old male Yorkshire terrier with the dog in dorsal recumbency. A and B images were made at the same point with a difference of 2 seconds. Compare A and B images and note the “to-and-fro” flow-direction (alternating hepatopetal and hepatofugal flow) in the portal vein segment between the shunt-origin and the entering point of the gastroduodenal vein (PVcrSH). Continuous hepatopetal flow is seen in the portal vein cranial to the entering point of the gastroduodenal vein (PVcrGDV) and in the portal vein caudal to the shunt-origin (PVcaudSH). Dotted arrows indicate the direction of blood flow, shunt (SH), HA hepatic artery, SPLV splenic vein. GDV gastroduodenal vein.

**A.** Hepatopetal flow in the entire portal vein. (Full color illustration on page 178.)

**B.** Hepatofugal flow in the portal vein segment between the shunt-origin and the entering point of the gastroduodenal vein. (Full color illustration on page 178.)



**Figure 4.**

Color Doppler images showing the termination of congenital extrahepatic portosystemic shunts imaged with a transducer positioned caudal to the last right rib with the dog in dorsal recumbency. Dotted arrows indicate the direction of blood flow.

**A.** Spleno-caval shunt in a 3-month-old female cairn terrier at the point where the shunt (SH) enters the caudal vena cava (CVC). This point is located always slightly cranial to the point where the celiac artery (CA) originates from the aorta. CMA cranial mesenteric artery. (Full color illustration on page 178.)

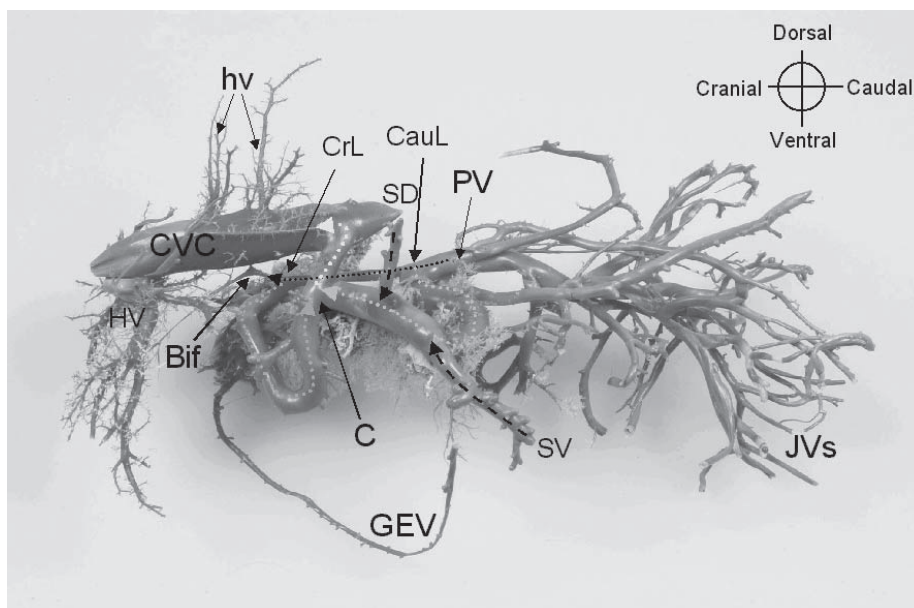
**B.** Spleno-azygos shunt in a 3.5-month-old male Jack Russell terrier. The shunting vessel (SH) runs dorsal to the CVC, and enters the thorax. Dotted arrows indicate the direction of blood flow. (Full color illustration on page 178.)



In cases of spleno-azygos shunts, the shunting vessel ran towards the CVC, but instead of entering it at the point where the spleno-caval shunts terminated, it ran further, dorsal to the CVC and eventually entered the thorax (**Fig 4B**). The point of origin of these spleno-azygos shunts was the same as that of the spleno-caval shunts.

The diameter of the shunt with a splenic vein origin was always wider than that of the PV caudal to the shunt-origin (**Fig 3**). The PV-segment cranial to the shunt-origin was thinner than the PV-segment caudal to it in all 32 dogs whose shunt originated from the splenic vein. Sometimes the PV cranial to the shunt-origin was so thin that it could not be visualized ultrasonographically. The flow-direction in the PV-segment cranial to the shunt-origin was hepatofugal or “to-and-fro” in 17/32 dogs determined by color Doppler mode (**Fig 3**). In the remaining dogs this segment could not be visualized or the flow was normal, ie, hepatopetal. The PV-segment cranial to the origin of the gastroduodenal vein could only occasionally be imaged. Whenever this PV-segment was visualized, its flow was always hepatopetal, even if cranial to the shunt-origin hepatofugal portal flow was seen (**Fig 3B**).

Right gastric-caval shunts were in most of the dogs double shunts, since they had a cranial and a caudal shunt-loop, however the two loops anastomosed before entering the systemic venous system. The cranial loop arose from the right gastric vein and the morphology of its origin was slightly variable depending whether the right gastric vein was a tributary of the gastroduodenal vein or of the PV itself. In both cases the shunt (ie, the dilated right gastric vein) originated immediately caudal to the portal bifurcation. When the right gastric vein was a tributary of the gastroduodenal vein, the origin of the shunt (ie, the right gastric vein) was very close to the point where the gastroduodenal vein entered the PV and the short segment of the gastroduodenal vein that was between the PV and the origin of the right gastric vein was dilated and the flow hepatofugal in it. Regardless of the anatomic variation of the right gastric vein, the course of the shunt was always the same, namely it made a long loop from the liver hilus: running laterally to the left body wall, then turned caudomedially and entered the CVC at the point where the spleno-caval shunts terminate, ie, slightly cranial to the level where the celiac artery originates from the aorta (**Fig 5**). In one dog, the shunt did not enter the CVC after making the above described course, but ran dorsal to the CVC to cranial and entered the thorax. In this dog the ultrasonographic diagnosis was right gastric-azygos shunt. All CPSSs that arise from the right gastric vein were very wide, with a diameter comparable to that of the CVC. At surgical exploration the cranial loop of the right gastric-caval shunts were found to follow the lesser curvature of the stomach, similarly to a normal right gastric vein. The caudal shunt loop, which was occasionally absent, originated at the region where spleno-caval shunts are expected, but unlike the spleno-caval CPSSs, the caudal loop of a right gastric-caval shunt ran from caudal to cranial and not from ventral to dorsal like the spleno-caval shunts, moreover it formed a longer shunt-loop than the spleno-caval shunts. The caudal loop drained the blood of the PV via the dilated segment of the splenic vein, through the left gastric vein to the right gastric vein. As the cranial shunt-loop (right gastric vein—CVC) and the caudal shunt-loop (splenic vein—left gastric vein—right gastric vein) anastomosed, a common trunk entered the CVC. The PV was slightly thinner cranial to the origin of the caudal shunt-loop (ie, cranial to the splenic vein) and the flow direction was always hepatopetal in it. The PV cranial to the origin of the cranial shunt-loop was so thin that could not be visualized by ultrasound.



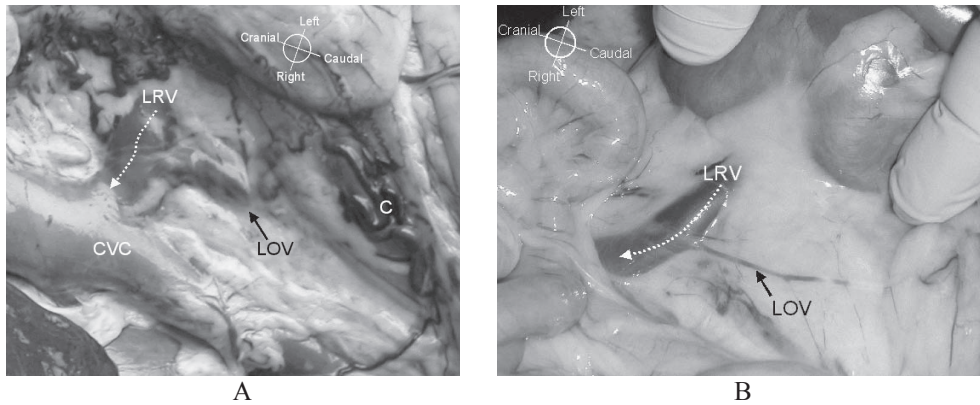
**Figure 5.**

Corrosion cast of the abdominal veins of a Yorkshire terrier with a right gastric-caval shunt. The cranial shunt-loop (interrupted green arrow) and the caudal shunt-loop (interrupted cyan arrow) anastomose with each other. From the point of confluence (C) the shunting vessel (interrupted yellow arrow) drains the portal blood to the caudal vena cava (CVC). Note that the portal vein becomes narrower cranial to the point of the origin of the caudal shunt-loop (CauL), and even more narrower cranial to the point of the origin of the cranial shunt loop (CrL). The cranial shunt-loop originates at the point where the gastroduodenal vein enters the portal vein. (The gastroduodenal vein is on the other side of the cast, so is not visible on this photo.) The ligature is usually placed around the common trunk (interrupted yellow arrow). The arrows indicate the flow-directions in the vessels.

Bif Portal bifurcation with the very thin right and left portal branches. HV Left hepatic vein, hv Hepatic veins, JVs Jejunal veins, GEV Right and left gastroepiploic veins, SV Ventral branch of the splenic vein, SD Dorsal branch of the splenic vein. (Full **color** illustration on page 178.)

### Acquired portosystemic collaterals

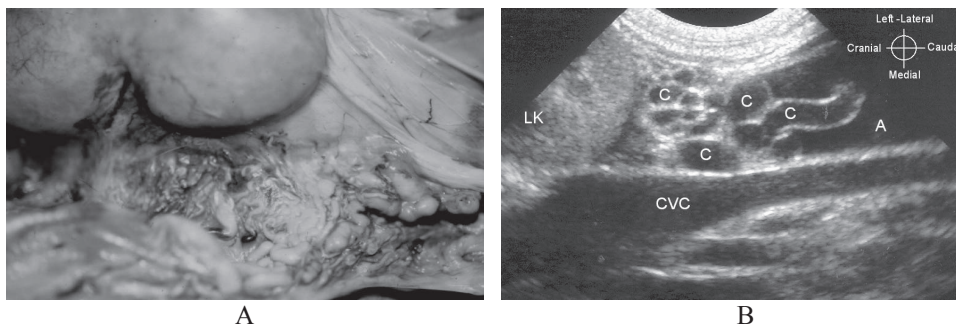
Portal hypertension with APSCs was the ultrasonographic diagnosis in 17 dogs. In all of these dogs a dilated left gonadal vein (testicular vein in males and ovarian vein in females) was seen. This vein ran parallel to the CVC and entered the mid-portion of the left renal vein from caudal (**Figs 6A, 6B**). The diameter of the gonadal vein was usually similar to that of the renal vein, but in some cases it was much wider, and either had a straight or a tortuous course. Lots of tiny tortuous veins were often observed around the left renal vein (**Fig 7**). In one dog the dilated left gonadal vein could be followed caudally to a conglomeration of smaller vessels, whereas in another dog it could be followed all the way to its origin, to the splenic vein at the splenic hilus. In the remaining dogs the dilated left gonadal vein could not be followed.



**Figure 6.**  
Left gonadal vein.

**A.** Dilated left ovarian vein (LOV) in a 5-month-old female great Dane with spleno-renal collaterals as a result of sustained portal hypertension of hepatic origin. C conglomeration of collateral vessels, CVC caudal vena cava, LRV left renal vein. (Full color illustration on page 179.)

**B.** Normal left ovarian vein in a 9-month-old female Labrador retriever. The left ovarian vein (LOV) is much thinner than the left renal vein (LRV). (Full color illustration on page 179.)

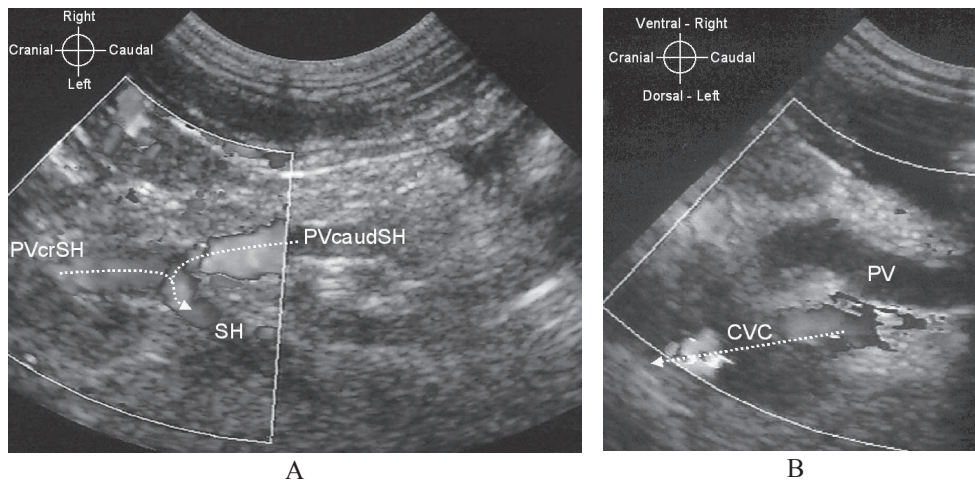


**Figure 7.**  
Acquired portosystemic collaterals

**A.** Spleno-renal collaterals at the region of the left kidney in a 2.5-year-old German shepherd dog with a sustained prehepatic portal hypertension. Purple silicon rubber was injected into the caudal vena cava and yellow into the splenic vein to outline the portosystemic communication in this formalin-perfused specimen. (Full color illustration on page 177.)

**B.** Gray scale ultrasound image of spleno-renal acquired collaterals (C) caudal to the left kidney (LK) in a 1-year-old female Dutch schapendoes with sustained portal hypertension of hepatic origin. A ascites, CVC caudal vena cava

In addition to the dilated left gonadal vein, the origin of an APSC from the PV was seen in 4 dogs at the point where congenital extrahepatic spleno-caval shunts arise (**Fig 8A**). These APSCs originated directly from the PV, and their relations to the splenic vein could not be revealed. In 2/4 dogs the flow in the entire PV was so slow that no color signals were detected with the lowest possible pulse repetition frequency setting (**Fig 8B**), whereas in the 2 other dogs the flow velocity caudal to the APSC-origin was not slow estimated with color Doppler mode, however cranial to the APSC-origin the flow-direction in the PV was hepatofugal (**Fig 8A**).



**Figure 8.**

Hepatic portal hypertension. (Full color illustrations on page 179.)

**A.** Color Doppler ultrasound image of the portal vein and the origin of an acquired portosystemic collateral (SH) in a 5-year-old West Highland white terrier with sustained portal hypertension of hepatic origin. Cranial to the collateral-origin (PVcrSH) hepatofugal portal flow can be seen. Note that the anomalous vein (SH) runs caudally. Dotted arrows indicate the direction of blood flow in the portal vein. Note that no color signals are seen in the portal vein, PVcaudSH portal vein caudal to the collateral-origin. Compare with Figure 3B!

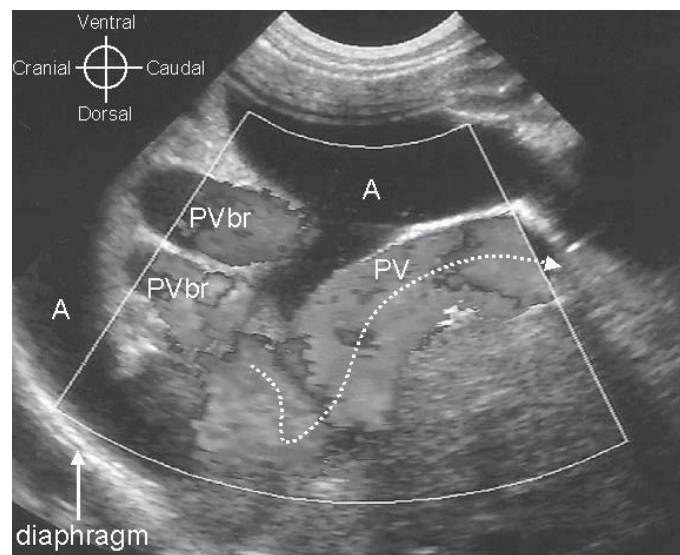
**B.** Color Doppler ultrasound image of the portal vein in a 6.5-year-old female Jack Russell terrier with sustained portal hypertension due to primary hypoplasia of the portal vein shows undetectably slow flow in the portal vein (PV), whereas aliasing artefact is seen in the caudal vena cava (CVC). The dotted arrow indicates the direction of blood flow.

The morphology of APSCs that originated from the PV was very similar to that of congenital extrahepatic spleno-caval shunts. Moreover, in both cases hepatofugal portal flow cranial to the origin of the anomalous vein could be seen. The differences were: an APSC ran caudally from the point of origin and tended to disappear among the intestines, furthermore the diameters of the PV cranial and caudal to the APSC-origin were approximately equal. In contrast, congenital extrahepatic spleno-caval or spleno-azygos shunts ran cranially from the origin and could always be followed to their terminations (CVC or thorax). Thirdly, the PV-segment that was cranial to the origin of a spleno-caval or a spleno-azygos shunt was always thinner than the PV-segment caudal to it. Moreover, an APSC was never wider than the PV caudal to the anomalous vein, unlike in cases of CPSSs. In addition to these features, the simultaneous presence of the dilated left gonadal vein always proved that an extrahepatic anomalous vein that originated from the PV was the origin of an APSC.

Three kinds of underlying diseases were found that led to the formation of APSCs: arterioportal fistulae, **primary hypoplasia of the portal vein (PHPV)**, and chronic hepatitis. Arterioportal fistulae were diagnosed ultrasonographically, whereas chronic hepatitis and PHPV were differentiated by histopathologic examination of liver biopsy specimens. The size of the spleen was normal in all portal hypertensive patients.



*Arterioportal fistulae* were diagnosed in 4 dogs, however the classical ultrasonographic appearance (**Fig 9**) was seen only in 2 of them (a 6-month-old American Staffordshire terrier and a 2.5-month-old bullmastiff); namely (1) ascites, (2) extremely dilated and tortuous portal branch in a liver lobe, (3) hepatofugal flow in the PV (with a variable or a clear arterial Doppler spectrum) and (4) APSCs. A 3-year-old basset hound was presented without any free abdominal fluid, but the other 3 features were found. A 9-month-old Labrador retriever had only an extremely dilated and tortuous portal branch without ascites or APSCs, and the flow-direction in the PV was normal, ie, hepatopetal. These findings suggested that in addition to the arterio-portal communication, an intrahepatic porto-caval communication must have existed, which was confirmed during necropsy. Histopathologic examination of the liver biopsy specimens of the Labrador retriever and of the basset hound revealed hypoplastic portal branches.



**Figure 9.**

Congenital arterio-portal fistula. Color Doppler ultrasound image of the liver of a 6-month-old male American Staffordshire terrier. Note the dilated portal branches (PVbr) in the affected liver lobe. The flow-direction in the portal vein (PV) is hepatofugal. The dotted arrow indicates the direction of blood flow, A ascites. (Full color illustration on page 179.)

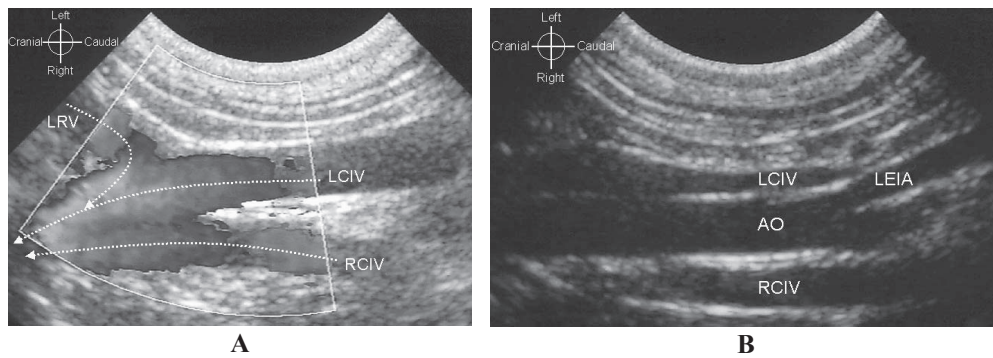
*Primary hypoplasia of the portal vein* as the cause of APSC-formation was diagnosed in 7 dogs (6 female and 1 male) by means of histopathologic examination of the liver. The mean (range) age of the dogs was 3.4 (0.5-6.5) years. The liver was small in all dogs with either normal (2/7 dogs) or slightly irregular echo-structure (5/7 dogs). Ascites was found at physical examination only in 1/7 dog; in 3 other dogs moderate amount of free abdominal fluid was detected ultrasonographically, and in the remaining 3 dogs no free abdominal fluid was seen.

*Chronic hepatitis* with or without cirrhosis was the histopathologic diagnosis of the liver biopsy specimen in 7 dogs (3 females and 4 males). The mean (range) age of the

dogs was 5.5 (2.9-9.5) years. Six of the 7 dogs had severe ascites at physical examination and irregular liver structure detected by ultrasound. One dog had only moderate amount of free abdominal fluid and ultrasonographically normal liver.

### Double caudal vena cava

Double CVC was found in 3 dogs in addition to an extrahepatic CPSS. In cases of double CVC the left and right common iliac veins fuse to form the CVC more cranial than normal, namely between the left and right renal veins, hence the left renal vein enters the left common iliac vein and the right renal vein enters the CVC. The left and right common iliac veins had the same diameters and ran symmetrically on the respective side of the aorta (Fig 10).



**Figure 10.**

Double caudal vena cava. (Full color illustration on page 179.)

**A.** Color Doppler image of the left renal vein (LRV) as it enters the left common iliac vein (LCIV) in a 3-month-old female cairn terrier. Compare to Figure 6! Dotted arrows indicate the direction of blood flow, LCIV left common iliac vein, RCIV right common iliac vein. **B.** Gray scale image of the aortic trifurcation. The left and right common iliac veins (LCIV, RCIV) run on the corresponding side of the aorta (AO) beyond the level of the aortic trifurcation. LEIA left external iliac artery

## Discussion

As a cause of hyperammonemia, the following diseases were found in our series of dogs: (1) CPSS, (2) APSCs due to PHPV, (3) APSCs due to arterioportal fistulae, (4) APSCs due to chronic hepatitis and (5) urea cycle enzyme deficiency.

The incidence of APSCs and CPSSs in the present study does not represent the incidence of these disorders in the clinic's population because the dogs with an ultrasonographic diagnosis of APSCs or with congenital extrahepatic spleno-azygos shunts were more often excluded from the study population than dogs with for example intrahepatic CPSSs. In cases of APSCs an exclusion criterion was an insufficient coagulation time, which did not allow liver biopsies to be taken, hence the ultrasonographic diagnosis remained unconfirmed. In cases of CPSSs, if the dog was older than 5 years, dietary and medical management was recommended instead of surgical shunt-ligation. Therefore, several dogs with an ultrasonographic diagnosis of congenital extrahepatic



spleno-azygos shunt were not included in the study population because the ultrasonographic diagnosis was not confirmed surgically.

Two basic types of intrahepatic CPSSs and four basic types of extrahepatic CPSSs were found in this study. The basic categories were established based on the origin and termination of the anomalous veins.<sup>10</sup>

Based on the origin and the course of the anomalous veins, the intrahepatic CPSSs were categorized into left-divisional shunts (originating from the left portal branch), right-divisional shunts (long shunts originating from the right portal branch) and central-divisional shunts (short shunts originating from the right portal branch). These categories are based and are in agreement with reported angiographic studies.<sup>12</sup>

Previous descriptions of extrahepatic CPSSs used the “porto”-caval term.<sup>18,19</sup> Indeed, on portographic and ultrasonographic images all extrahepatic CPSSs seem to arise from the PV itself and they divert the blood of the PV, however necropsy studies showed that they actually originate either from the splenic or from the right gastric veins.<sup>10,20</sup> Ultrasonographically we confirmed these findings and found that all extrahepatic CPSSs originated very close to the point where the splenic vein (in cases of spleno-caval or spleno-azygos shunts) or the right gastric vein (in cases of right gastric-caval shunts) entered the PV, and the short segment between the PV and the shunt-origin was always dilated, with hepatofugal flow. What actually happens in cases of extrahepatic CPSSs with splenic vein origin is that the shunt drains the blood of the PV and of the splenic vein via a short and dilated segment of the splenic vein to the CVC or to the azygos vein. In dogs, whose portal flow direction is hepatofugal in the PV-segment that is cranial to the shunt-origin, the blood of the gastroduodenal vein flows via the PV to the shunt as well. In cases of extrahepatic CPSSs with right gastric vein origin, there are two anatomic variations regarding the cranial loop of the shunt: (1) the right gastric vein is a tributary of the PV and is located between the portal bifurcation and the gastroduodenal vein, or (2) the right gastric vein is a tributary of the gastroduodenal vein.<sup>26</sup> When the right gastric vein is a direct tributary of the PV, the blood of the PV is drained via the right gastric vein to the CVC or to the azygos vein. When the right gastric vein is a tributary of the gastroduodenal vein, then the blood of the PV is drained via a short and dilated segment of the gastroduodenal vein through the right gastric vein into the CVC or into the azygos vein and the blood of the gastroduodenal vein flows through the shunt (ie, the right gastric vein) without reaching first the PV. The caudal shunt-loop of a right-gastric-caval shunt actually functions similarly to a spleno-caval shunt, except for the fact that the flow direction is always hepatopetal in the PV segment cranial to the origin of the caudal loop (ie, between the origins of the two shunt-loops). Since in cases of extrahepatic “porto”-azygos CPSSs the shunting vessel enters the azygos vein in the thorax,<sup>10</sup> we assumed that the CPSSs that entered the thorax terminated in the azygos vein,<sup>20</sup> however we could never visualize this segment by ultrasound because of the air-filled lungs.

Hepatofugal portal flow has been reported in association with extrahepatic CPSS in one dog, but no explanation was added.<sup>18</sup> Hepatofugal portal flow cranial to the shunt-origin was observed in our case series both with APSCs and congenital extrahepatic spleno-caval and spleno-azygos shunts (**Figs 3B, 8A**). The cause of hepatofugal portal flow however is probably different. In cases of CPSSs, the blood of the gastroduodenal vein was found to be responsible for the hepatofugal flow because the gastroduodenal blood finds lower resistance to flow towards the shunt than towards the hepatic sinusoids. This was confirmed by the presence of hepatopetal portal flow cranial to the entering point of the

gastroduodenal vein (**Fig 3**). Preoperative detection of the flow-direction in the PV-segment cranial to the origin of a CPSS may be important in determining the level of portal vein hypoplasia, hence to facilitate predicting the surgical outcome (**Chapter 7**). In cases of hepatopetal or “to-and-fro” flow excellent prognosis could be expected because the flow-direction is continuously or at least intermittently physiological, whereas in cases of continuous hepatofugal flow the surgical prognosis can range from poor to excellent. In human cirrhotic patients microscopic intrahepatic arteriportal communications were found to be responsible for the hepatofugal portal flow, and were thought to have been formed due to the disorganized hepatic architecture.<sup>27,28</sup> This might also be the case in dogs with chronic hepatitis,<sup>5,29</sup> however visualizing the portal branches in dogs with portal hypertension to detect whether the flow direction was indeed hepatofugal in them was impossible in any dogs of our study. Intraoperative Doppler ultrasonography of the portal branches<sup>30</sup> or angiography by superselective catheterization of a hepatic branch of the hepatic artery would be necessary to reveal whether intrahepatic arteriportal communications are indeed responsible for the hepatofugal portal flow in dogs with sustained portal hypertension.

Primary hypoplasia of the portal vein is a distinct congenital disorder characterized by hypoplasia of the portal branches and sometimes also of the PV.<sup>4</sup> In mild cases, portal hypertension and APSCs do not develop, hence blood ammonia level remains normal, however in severe cases APSCs develop as a consequence of sustained hepatic portal hypertension. The severe form of PHPV has also been described as non-cirrhotic portal hypertension.<sup>6,31-33</sup> “Hepatic microvascular dysplasia” was described as a condition that results in elevated serum bile acids levels without demonstrable macroscopic portosystemic shunting and was speculated to cause hepatic encephalopathy due to suspected microscopic intrahepatic portosystemic communications,<sup>34-37</sup> however blood ammonia levels of these dogs have never been determined. Since the histopathologic changes in the liver as well as the clinical and laboratory findings of these reported dogs were identical with the findings of dogs with the mild form of PHPV, the “WSAVA liver diseases and pathology standardization research group” agreed that the described condition is actually also PHPV.<sup>b,33</sup>

The etiology of secondary portal vein hypoplasia is different from that of the PHPV. Secondary hypoplasia of the portal branches can be found when the blood supply of the liver via the portal vein is reduced due to e.g. portal vein thrombosis or CPSS. Since a CPSS has equal or larger diameter compared to the PV-segment caudal to the shunt, it offers a lower resistance route towards the systemic veins than the route towards the hepatic sinusoids; therefore the PV cranial to the shunt-origin and the intrahepatic portal branches remain hypoperfused. Ultrasonographically this phenomenon is usually recognizable, namely in cases of intrahepatic CPSSs the non-affected portal branch is frequently unrecognizably thin, whereas in cases of extrahepatic CPSSs the portal vein segment that is cranial to the shunt-origin is much thinner than the segment that is caudal to it. In most cases of extrahepatic CPSSs the left and right portal branches are also very thin. The smallest portal branches, at microscopic level, are also thinner than normal, however this secondary portal vein hypoplasia is histologically indistinguishable from PHPV.<sup>4,5</sup> The situation can be more complicated because PHPV is either an independent disease, but can also be simultaneously present with arteriportal fistulae<sup>38</sup> and with CPSSs. When a CPSS and PHPV are simultaneously present in the same dog, PHPV cannot be diagnosed preoperatively. In these dogs portal hypertension and APSCs will not develop, because

there is already an existing connection between the portal and the systemic veins in the form of a CPSS. Currently, the earliest time point when PHPV can be suspected in a dog that has a simultaneous CPSS is during surgical attenuation of the CPSS, with the use of intraoperative Doppler ultrasonography (**Chapter 7**).

Congenital arteriportal fistula is a single or multiple connection of a portal branch and a hepatic arterial branch that results in development of portal hypertension and formation of APSCs. Ultrasonographically, the presence of an extremely dilated and tortuous portal branch in a liver lobe is a pathognomic finding.<sup>7</sup> The high arterial pressure causes dilation of the affected portal branch and hepatofugal flow in the affected portal branch and in the PV. Similarly to a reported case,<sup>38</sup> both dogs that underwent a liver biopsy in our case-series had coinciding PHPV. Surgical resection of the affected liver lobe(s) should only be considered when PHPV is excluded by histopathologic examination of liver biopsy specimens, because after having ceased the arteriportal communication surgically, the portal blood would continue to flow towards the lower resistance ie, via the APSCs, and not towards the hypoplastic portal branches.

The development of portal hypertension and APSCs in dogs with cirrhosis is well documented and is associated with the disorganized hepatic architecture due to the formation of connective tissue and regenerative nodules.<sup>2,8</sup> Portal hypertension due to chronic hepatitis develops as a result of intrahepatic inflammatory and fibrotic changes.<sup>2,39</sup> As a result of these pathological processes, the little portal branches and hepatic veins in the liver lobes are compressed and portal hypertension develops.

Since no previous studies aimed diagnosing APSCs ultrasonographically, the ultrasonographic features of APSCs have not been described in details yet.<sup>19</sup> Measuring portal flow velocity was suggested to differentiate APSCs from CPSSs<sup>18,40</sup> because B-mode ultrasonographic signs of APSCs were thought to be variable.<sup>40</sup> However, we showed that slow portal flow velocity is not necessarily present in all cases of portal hypertension (**Fig 8A**). Moreover, a dilated left gonadal vein was found to be a reliable indicator of APSCs. The dilated left gonadal vein is the result of the spleno-renal collateral circulation, which is the most consistently observed route of APSCs in dogs.<sup>3,4,29</sup> The left gonadal vein enters the left renal vein in normal dogs, but it is so thin that cannot be ultrasonographically visualized (**Fig 6, Chapter 5**). As a result of sustained hepatic or prehepatic portal hypertension, the virtual communications between the velar-omental radicles of the splenic vein and the mesocolic radicles of the left gonadal vein become functional and these rudimentary vessels dilate allowing the portal blood to shunt into the systemic veins, therefore the left gonadal vein gets dilated.<sup>3</sup> Non-invasive diagnosis of APSCs is essential because patients with portal hypertension and hyperammonemia are of a high anesthetic risk,<sup>41</sup> furthermore there is nothing in the abdominal cavity that could surgically be corrected in these dogs during a diagnostic laparotomy; except for some rare cases such as a circumscribed stenosis of the PV.<sup>42</sup> Banding the CVC was described as a surgical technique to reduce portosystemic shunting via APSCs by attenuating the CVC to increase its pressure above the portal pressure, however this method did not bring satisfactory results,<sup>43</sup> hence is not recommended.

In cases of spleno-renal collaterals, a relatively wide and straight collateral vein can regularly be seen. This vein should not be mistaken with a CPSS. We believe that the conditions that were described as spleno-mesenteric-renal shunt in 2 dogs<sup>44</sup> as well as the case report of a “suspected microscopic hepatic arteriovenous fistulae”<sup>16</sup> were both cases of PHPV with acquired spleno-renal collaterals. The fact that the histopathologic findings of

liver biopsy specimens are identical in cases of CPSS, PHPV and arterioportal fistula, these conditions should be differentiated by means of diagnostic imaging.

A double CVC is an innocent congenital vascular anomaly.<sup>45</sup> According to our knowledge ultrasonographic diagnosis of this condition has not been reported yet. The only significance of a double CVC is that the left common iliac vein may be mistaken with a dilated left gonadal vein. If a vein is found on the left side of the aorta caudal to the left kidney running parallel to the CVC, thorough evaluation of this vein and the abdomen is necessary to decide whether the dog has a double CVC or APSCs. The left and right common iliac veins in cases of a double CVC have the same diameter and they run symmetrically on the respective side of the aorta, whereas a dilated left gonadal vein may be tortuous and its diameter is usually different from that of the CVC. In addition, the common iliac veins can always be followed caudally until the point where they leave the abdomen, unlike a left gonadal vein.

Large amount of free abdominal fluid may hinder ultrasonographic visualization of the abdominal vessels, but hyperammonemia in dogs with severe peritoneal effusion cannot possibly be the result of CPSSs or an urea cycle enzyme deficiency,<sup>2,19</sup> since a dog with CPSS cannot have portal hypertension or so severe hypoalbuminemia that would result in a formation of a large amount of transudate in the abdominal cavity.<sup>5,19</sup> Naturally occurring simultaneous presence of APSCs and CPSSs is also very unlikely, if not impossible<sup>c</sup>. Small amount of free abdominal fluid is normal in healthy pups, hence may also be seen in puppies with CPSSs or with urea cycle enzyme deficiency.

Free abdominal fluid was absent in some dogs with sustained portal hypertension in our case-series. This is not surprising, since ascites-formation depends not only on the degree of portal pressure but also on the colloid osmotic pressure and albumin concentration of the blood as well as the effectiveness of the APSCs.<sup>2</sup> In the dog that had a combination of arterioportal fistulae and an intrahepatic porto-caval shunt, ascites and APSCs did not develop because the simultaneously present congenital porto-caval shunt did not allow portal hypertension to develop.

No splenomegaly was found in any of the dogs with portal hypertension, however it is a common finding in humans and was suggested to be present in dogs as well.<sup>46</sup> The reason why splenomegaly does not develop in dogs with APSCs could be that acquired spleno-renal collaterals are the most consistently developing APSCs in dogs in contrast to humans, and these collateral veins prevent the spleen from congestion.

Since in dogs with a urea cycle enzyme deficiency a functional disorder is responsible for the hyperammonemia, ultrasonographically the abdominal organs and vessels do not differ from normal.

The scanning time that was necessary to image the anomalous vein or to exclude portosystemic shunting was approximately 15-30 minutes. This was actually not or not much longer than a routine abdominal ultrasound examination. This was possible not only because of the experience and skill of the ultrasonographer and the use of a high quality ultrasound system, but also because of the use of our systematic scanning protocol (**Chapter 5**) and the knowledge of the ultrasound anatomy of the various types of vascular anomalies. Moreover, an important factor that made the examinations shorter was that the clinician's request was straightforward and based on the high blood ammonia level only three distinct conditions had to be distinguished with ultrasound: normal anatomy, CPSS and portal hypertension.

In sum, ultrasonography is a reliable diagnostic method to characterize the underlying disease of hyperammonemic dogs non-invasively. The cause of APSCs can be established ultrasonographically in cases of arterioportal fistulae, however in other cases taking an ultrasound-guided liver biopsy for histopathologic examination is necessary.

## Acknowledgements

Dr Szatmári was supported by the Hungarian State Eötvös Scholarship. Mr Aart van der Woude helped in preparing the illustrations. This paper was presented in part at the WSAVA-FECAVA-AVEPA veterinary congress in Granada, Spain, October, 2002.

## Footnote

- a. Gerritzen-Bruning MJ, Rothuizen J. Sensitivity and specificity of ammonia and bile acids in diagnosing portosystemic shunting. Abstract. p. 264. "Voorjaarsdagen" International Veterinary Congress, April 25-27, 2003, Amsterdam, The Netherlands
- b. Cullen JM. Histology of vascular disorders of the canine and feline liver. Abstract. 21<sup>st</sup> Annual ACVIM Forum Proceedings CD-ROM, June 4-8, 2003, Charlotte, North Carolina
- c. Szatmári V. Simultaneous congenital and acquired extrahepatic portosystemic shunts in two dogs — Letter to the Editor. *Vet Radiol Ultrasound* 2003;44:486-487.

## References

1. Strombeck DR, Meyer DJ, Freedlan RA. Hyperammonemia due to a urea cycle enzyme deficiency in two dogs. *J Am Vet Med Assoc* 1975;166:1109-1111.
2. Johnson SE. Portal hypertension. Part I. Pathophysiology and clinical consequences. *Comp Cont Educ Pract Vet* 1987;9:741-748.
3. Vitums A. Portosystemic communications in the dog. *Acta Anat (Basel)* 1959;39:271-299.
4. Van den Ingh TSGAM, Rothuizen J, Meyer HP. Portal hypertension associated with primary hypoplasia of the hepatic portal vein in dogs. *Vet Rec* 1995;137:424-427.
5. Van den Ingh TSGAM, Rothuizen J, Meyer HP. Circulatory disorders of the liver in dogs and cats. *Vet Q* 1995;17:70-76.
6. Bunch SE, Johnson SE, Cullen JM. Idiopathic noncirrhotic portal hypertension in dogs: 33 cases (1982-1998). *J Am Vet Med Assoc* 2001;218:392-399.
7. Szatmári V, Németh T, Kótai I, et al. Doppler ultrasonographic diagnosis and anatomy of congenital arterioportal fistula in a puppy. *Vet Radiol Ultrasound* 2000;41:284-286.
8. Twedt DC. Cirrhosis: a consequence of chronic liver disease. *Vet Clin North Am Small Anim Pract* 1985;15:151-176.
9. Komtebedde J, Forsyth SF, Breznock EM, Koblik PD. Intrahepatic portosystemic venous anomaly in the dog. Perioperative management and complications. *Vet Surg* 1991;20:37-42.
10. Rothuizen J, van den Ingh TSGAM, Voorhout G, et al. Congenital porto-systemic shunts in sixteen dogs and three cats. *J Small Anim Pract* 1982;23:67-81.
11. Payne JT, Martin RA, Constantinescu GM. The anatomy and embryology of portosystemic shunts in dogs and cats. *Sem Vet Med Surg (Small Anim)* 1990;5:76-82.

12. Lamb CR, White RN. Morphology of congenital intrahepatic portocaval shunts in dogs and cats. *Vet Rec* 1998;142:55-60.
13. Meyer HP, Rothuizen J, Tiemessen I, et al. Transient metabolic hyperammonaemia in young Irish Wolfhounds. *Vet Rec* 1996;138:105-107.
14. Hall JA, Allen TA, Fettman MJ. Hyperammonemia associated with urethral obstruction in a dog. *J Am Vet Med Assoc* 1987;191:1116-1118.
15. Stone EA, Withrow SJ, Page RL, et al. Ureterocolonic anastomosis in ten dogs with transitional cell carcinoma. *Vet Surg* 1988;17:147-153.
16. Schermerhorn T, Center SA, Dykes NL, et al. Suspected microscopic hepatic arteriovenous fistulae in a young dog. *J Am Vet Med Assoc* 1997;211:70-74.
17. Wrigley RH, Park RD, Konde LJ, Lebel JL. Subtraction portal venography. *Vet Radiol* 1987;28:208-212.
18. Lamb CR. Ultrasonographic diagnosis of congenital portosystemic shunts in dogs: results of a prospective study. *Vet Radiol Ultrasound* 1996;37:281-288.
19. Wrigley RH, Konde LJ, Park RD, Lebel JL. Ultrasonographic diagnosis of portacaval shunts in young dogs. *J Am Vet Med Assoc* 1987;191:421-424.
20. Holt DE, Schelling CG, Saunders HM, Orsher RJ. Correlation of ultrasonographic findings with surgical, portographic, and necropsy findings in dogs and cats with portosystemic shunts: 63 cases (1987-1993). *J Am Vet Med Assoc* 1995;207:1190-1193.
21. Tiemessen I, Rothuizen J, Voorhout G. Ultrasonography in the diagnosis of congenital portosystemic shunts in dogs. *Vet Q* 1995;17:50-53.
22. Nyland TG, Mattoon JS, Herrgesell EJ, Wisner ER. Liver. In *Small Animal Diagnostic Ultrasound*. 2nd ed. Eds T. G. Nyland, J. S. Mattoon. Philadelphia, W.B. Saunders Co. 2002;93-127.
23. Wolschrijn CF, Mahapokai W, Rothuizen J, et al. Gauged attenuation of congenital portosystemic shunts: results in 160 dogs and 15 cats. *Vet Q* 2000;22:94-98.
24. Rothuizen J, van den Ingh, TGSAM. Rectal ammonia tolerance test in the evaluation of portal circulation in dogs with liver disease. *Res Vet Sci* 1982;33:22-25.
25. Meyer HP, Rothuizen J, van den Brom WE, et al. Quantitation of portosystemic shunting in dogs by ultrasound-guided injection of 99mTc-macroaggregates into a splenic vein. *Res Vet Sci* 1994;57:58-62.
26. Vitums A. Portal vein in the dog. *Zbl Vet Med* 1959;7:723-741.
27. Foster DN, Herlinger H, Miloszewski KJ, Losowsky MS. Hepatofugal portal blood flow in hepatic cirrhosis. *Ann Surg* 1978;187:179-182.
28. Wachsberg RH, Bahramipour P, Sofocleous CT, Barone A. Hepatofugal flow in the portal venous system: pathophysiology, imaging findings, and diagnostic pitfalls. *Radiographics* 2002;22:123-140.
29. Suter PF. Portal vein anomalies in the dog: their angiographic diagnosis. *J Am Vet Radiol Soc* 1975;16:84-97.
30. Szatmári V, van Sluijs FJ, Rothuizen J, Voorhout G. Intraoperative ultrasonography of the portal vein during attenuation of intrahepatic portocaval shunts in dogs. *J Am Vet Med Assoc* 2003;222:1086-1092.
31. DeMarco JA, Center SA, Dykes N, et al. (1998) A syndrome resembling idiopathic noncirrhotic portal hypertension in 4 young Doberman Pinschers. *J Vet Intern Med* 1998;12:147-156.
32. McEntee MF, Wright KN, Wanless I, et al. Noncirrhotic portal hypertension and nodular regenerative hyperplasia of the liver in dogs with mucopolysaccharidosis type I. *Hepatology* 1998;28:385-390.
33. Rothuizen J. Liver research group considers vascular hepatic diseases. *J Small Anim Pract* 2002;43:100-101.



34. Schermerhorn T, Center SA, Dykes NL, et al. Characterization of hepatoportal microvascular dysplasia in a kindred of cairn terriers. *J Vet Intern Med* 1996;10:219-230.
35. Phillips L, Tappe J, Lyman R, et al. Hepatic microvascular dysplasia in dogs. *Prog Vet Neurol* 1996;7:88-96.
36. Allen L, Stobie D, Mauldin GN, Baer KE. Clinicopathologic features of dogs with hepatic microvascular dysplasia with and without portosystemic shunts: 42 cases (1991-1996). *J Am Vet Med Assoc* 1999;214:218-220.
37. Christiansen JS, Hottinger HA, Allen L, et al. Hepatic microvascular dysplasia in dogs: a retrospective study of 24 cases (1987-1995). *J Am Anim Hosp Assoc* 2000;36:385-389.
38. Schaeffer IG, Kirpensteijn J, Wolvekamp WT, et al. Hepatic arteriovenous fistulae and portal vein hypoplasia in a Labrador retriever. *J Small Anim Pract* 2001;42:146-150.
39. Sterczar A, Gaál T, Perge E, Rothuizen J. Chronic hepatitis in the dog — a review. *Vet Q* 2001;23:148-152.
40. Lamb CR. Ultrasonography of portosystemic shunts in dogs and cats. *Vet Clin North Am Small Anim Pract* 1998;28:725-753.
41. Thurmon JC, Tranquilli WJ, Benson GJ. Considerations for general anesthesia. In: Thurmon JC, Tranquilli WJ, Benson GJ, eds. *Lumb & Jones' veterinary anaesthesia*. Baltimore: Lea & Febiger, 1996;5-34.
42. Szatmári V, van den Ingh TSGAM, Fenyves B, et al. Portal hypertension in a dog due to circumscribed fibrosis of the wall of the extrahepatic portal vein. *Vet Rec* 2002;150:602-605.
43. Boothe HW, Howe LM, Edwards JF, Slater MR. Multiple extrahepatic portosystemic shunts in dogs: 30 cases (1981-1993). *J Am Vet Med Assoc* 1996;208:1849-1854.
44. Valentine RW, Carpenter JL. Spleno-mesenteric-renal venous shunt in two dogs. *Vet Pathol* 1990;27:58-60.
45. Laborda J, Gimeno M, Dominguez L, Gil J. Anomalous caudal vena cava in the dog. *Vet Rec* 1996;138:20-21.
46. Finn-Bodner ST, Hudson JA. Abdominal vascular sonography. *Vet Clin North Am Small Anim Pract* 1998;28:887-942.

