

Canine counterpart of senile dementia of the Alzheimer type

J.E. Rofina, S. Zander, I. van Driel, S. van Erp, M. Roerdink, D. Oorburg, M.C. Goedhard, M.A. Gonggrijp, M. Teuben-van der Leest, F.J.C.M. van Eerdenburg and E. Gruys

Review of Alzheimer's disease

Alzheimer's disease is named after Alois Alzheimer, a German neuropathologist and psychiatrist. He was born on June 14, 1864 in Marktbreit, Bavaria and died on December 19, 1915 in Breslau. In 1907 he published his first case as a short communication under the title "eine eigenartige Erkrankung der Hirnrinde" (a peculiar disease of the cerebral cortex) [1]. In this paper he described the clinical and neuropathological features of a woman aged 51 years who had been institutionalised at the Frankfurt Hospital. The woman had displayed symptoms as: increased memory impairment, disorientation, unpredictable behaviour, aphasia, paranoia, auditory hallucinations, and pronounced psychosocial impairment. The histopathological findings of this case were neurofibrillary tangles (NFT): "in the centre of a cell stand out several fibrils due to their characteristic thickness and peculiar impregnability" and senile plaques: "numerous miliary foci determined by storage of a peculiar material in the cortex".

Alzheimer published a longer article in 1911 [2] in which he focused on a second case, a demented 56-year-old man, who was admitted to the university psychiatric clinic in Munich. The histopathological lesions in the second case differed from those in the first case. The second case did not display NFT, only plaques. In this article Alzheimer discussed the relationship of the plaques and fibrillary degeneration (NFT) in senile and presenile dementia. Alzheimer concluded that in these cases and other cases described [3], the alterations were in the same manner and direction as in senile dementia but of greater severity and had not been found yet in any disease of younger people. These younger cases were senile psychoses, atypical forms of senile dementia. In 1910 the director of the Royal Psychiatric Clinic in Munich, where Alzheimer worked, named this presenile dementia Alzheimer's disease [4].

Alzheimer's disease or Senile Dementia of the Alzheimer Type (SDAT) is now well known [4] as a slowly-progressive form of dementia, characterized by acquired impairment of intellectual functions. Memory impairment is a necessary feature for the clinical diagnosis. Change in one of the following areas must also be present for any form of dementia to be diagnosed: language, decision-making ability, judgment, attention, and other related areas of cognitive function and personality [5]. The rate of progression is different for each person. If SDAT develops rapidly, it is likely to continue to progress rapidly. If it has been slow to develop, it will likely continue on a slow course.

Aging and SDAT

Associated with advances in technology, medicine and nutrition, humans and animals live substantially longer and are therefore increasingly subjected to various physical and mental consequences of old age. Human aging is generally associated with a decline in a range of cognitive functions. The rate of cognitive decline, however, occurs unevenly across the population. Based on cognitive decline, three categories can be identified [6].

1. People suffering from dementia
2. People suffering from mild cognitive impairment (MCI)
3. People without cognitive decline

Dementia is characterized by memory loss and decline in other cognitive functions, resulting in behavioural disturbances and interference with normal daily functioning. SDAT is the most common form of dementia. The criteria for the diagnosis of SDAT include loss of recent memory and at least one other cognitive or behavioural deficit. MCI is a condition that exceeds normal physiological aging processes but does not meet with the criteria of

dementia. There is growing evidence that MCI represents an early stage of dementia [7] [8] [9]. Successful aging people maintain a consistently high level of cognitive functioning [10]. Behavioural disturbances are characterized with a cognitive mental status examination in the form of questionnaires [11] [12] [13].

Histopathological features of SDAT

Two diagnostic histopathological features in SDAT brains are extracellular amyloid (A β) deposits and accumulation of intraneuronal neurofibrillary tangles (NFT) [14]. The MCI brains contain intermediate levels of SDAT pathology, while a healthy geriatric cognitive brain may contain some features of SDAT pathology [7]. Amyloid can be detected in the walls of cerebral arteries, the so-called cerebrovascular amyloidosis or cerebral amyloid angiopathy (CAA) [15] [16], around arterioles/capillaries in the brain parenchyma (dyschoric angiopathy) [17] [18] and in the neuropil of brain tissue as senile plaques [19] [20].

Amyloid plaques

The plaques have been classified morphologically into two major types: the mature or neuritic plaque and the diffuse or amorphous plaque (Figure 1) [21]. The neuritic plaque is characterized by a dense assembly of dystrophic neurites and Congophilic amyloid. Dystrophic neurites are damaged extensions of neurons which in the beginning contain accumulations of neurofilaments in their axons, leading to accumulation of tau and formation of NFT in the cell body. Neurofilaments do not stain with thioflavine S, thiazin red, or Gallya's method (silver impregnation), as do tau and NFT, but they can be detected by immunohistochemistry. The neuritic plaques contain amyloid in the form of a web of fibrils which stain positively with Congo red and show the characteristic green-red birefringence in polarized light and the orange fluorescence of amyloid [22]. This type is further subdivided into the "classical plaque" (Figure 1, panel A), which has a central amyloid core and the "primitive plaque", which has no core. The diffuse plaque (Figure 1, panel B) either does not contain amyloid fibrils or the number of fibrils is too small to be detected histologically and, as a result, diffuse plaques are characterized by the absence of Congophilic amyloid deposits.

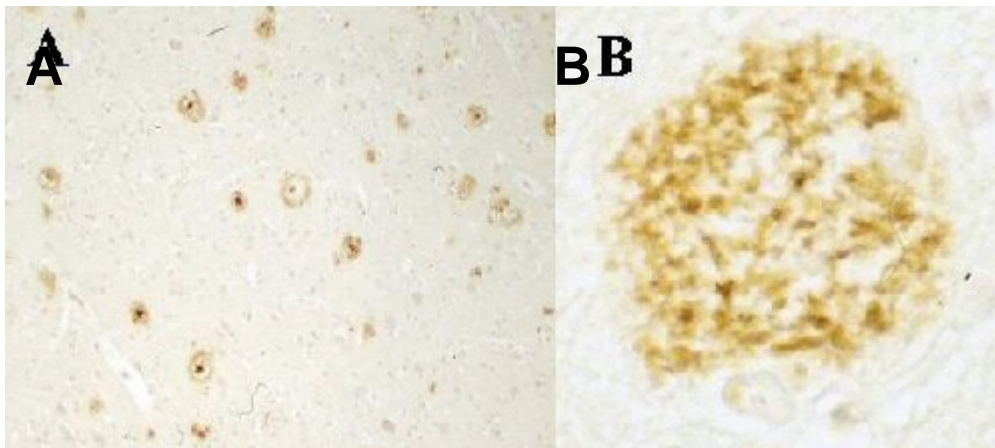


Figure 1. Panel A: diffuse and compact plaques. Panel B: detail of a diffuse plaque. Both pictures show a positive reaction with antibody A β 8-17. Patient with Alzheimer's disease.

Neurofibrillary tangles (NFT)

Neurofibrillary tangles (NFT) are formed by the intracellular accumulation of hyperphosphorylated tau protein (Figure 2) [23] [24]. Tau protein belongs to the family of microtubule-associated proteins which play an important role in the formation of the neuronal microskeletal network, maintaining the cell's shape and playing a role in the signal transduction pathway. In the neurons of Alzheimer patients, tau protein molecules may aggregate into intraneuronal filamentous inclusions: paired helical filaments (PHF, also called neurofibrillary tangles). The PHF-tau proteins are hyperphosphorylated and several studies support the concept that these proteins are pathological and differ from phosphorylated native tau. The hyperphosphorylation should occur after aggregation, which means that other factors such as ubiquitination may be involved in the process of the aggregation. Ubiquitin is a stress protein that is involved in the intracellular removal of abnormal or damaged proteins. Conjugated ubiquitin has been found in the PHF and the proteins targeted were tau proteins.

It is also possible that the abnormally phosphorylated tau which accumulated as PHF is proteolysed and subsequently ubiquitinated [25] [26].

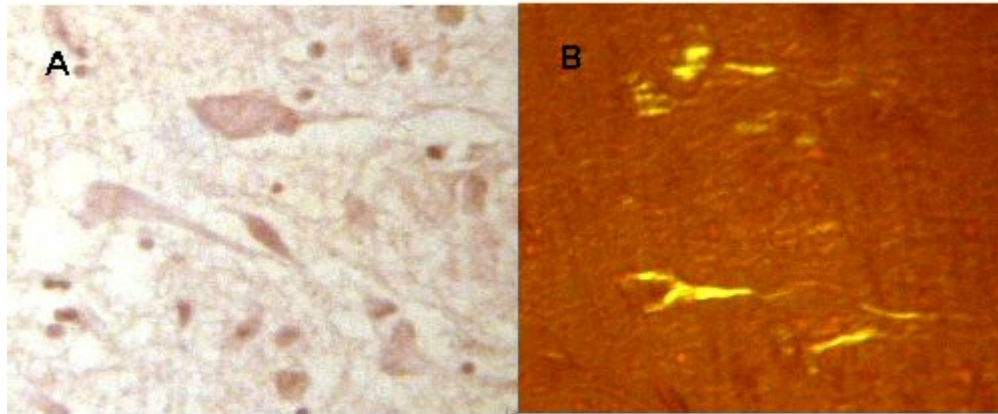


Figure 2. Neurofibrillary tangles. Panel A: Congo red stain viewed with normal light. Panel B: Congo red stain viewed in polarized light, green-red birefringence.

Pathogenesis of A β -amyloid

Amyloid protein (A β peptide)

A β peptide is a physiological, soluble, non-toxic cellular metabolite and comparable levels of the peptide have been detected in both cerebrospinal fluid and plasma in sporadic SDAT and in healthy subjects throughout life. A β peptide has predominantly an α -helical conformation but this structure may change to an enriched pleated β -sheet structure and then aggregate into insoluble amyloid fibrils with neurotoxic effects. The mechanism for this change might involve the binding of A β to clusters of GM1 gangliosides (Figure 3). GM1 gangliosides are located in the plasma membrane of cells but not in clusters. Studies *in vitro* have shown that cholesterol facilitates clustering of the GM1 gangliosides. The formation of GM1-A β forces the A β to adopt an altered conformation, after which an insoluble monomeric protein is formed that can polymerise into amyloid fibrils [27].

Amyloid precursor protein (A β PP)

The A β peptide results from proteolysis of a membrane protein, amyloid β -protein precursor (A β PP) [28] [29], which is a large ubiquitously expressed transmembrane spanning glycoprotein [30] and which may be involved in neuronal survival [31], axonal sprouting [31], and in axonal transport [32]. Expression of A β PP mRNA increases in neurons and glial cells after a brain lesion [33].

Proteolysis of A β PP

Proteolysis of A β PP involves three secretases (Figure 3). A β PP is first cleaved by either an α -secretase or a β -secretase and the fragments are then cleaved by a γ -secretase [27] [34]. Cleavage by β -secretase yields a large soluble N-terminal fragment (sAPP β), secreted into the extracellular space, and a smaller membrane-bound C-terminal fragment, C99, that remains in the plasma membrane. The C99 fragment can be cleaved further by a γ -secretase, resulting in generation of the A β peptide and a remaining fragment of C99 in the cell. Cleavage by an α -secretase yields a soluble N-terminal fragment (sAPP α) that slightly longer

than the sAPP β , secreted into the extracellular space, and a C-terminal fragment C83, slightly shorter than the C99. Further cleavage of the C83 fragment by γ -secretase yields a p3 peptide and the remainder of C83 in the cell. There is an important consequence of the difference in cleavage sites of the α - and β -secretases in the A β PP. Processing of these C-terminal fragments by γ -secretase, occurring for both at the same place, can only proceed in the case of the longer C99 fragment. Fortunately, a substantially larger portion of the β -amyloid precursor proteins is cleaved by the α -secretase and not the β -secretase. In recent years, there has been further characterization of the different secretases involved in this complex proteolytic process and the proteins have been identified [27] [34].

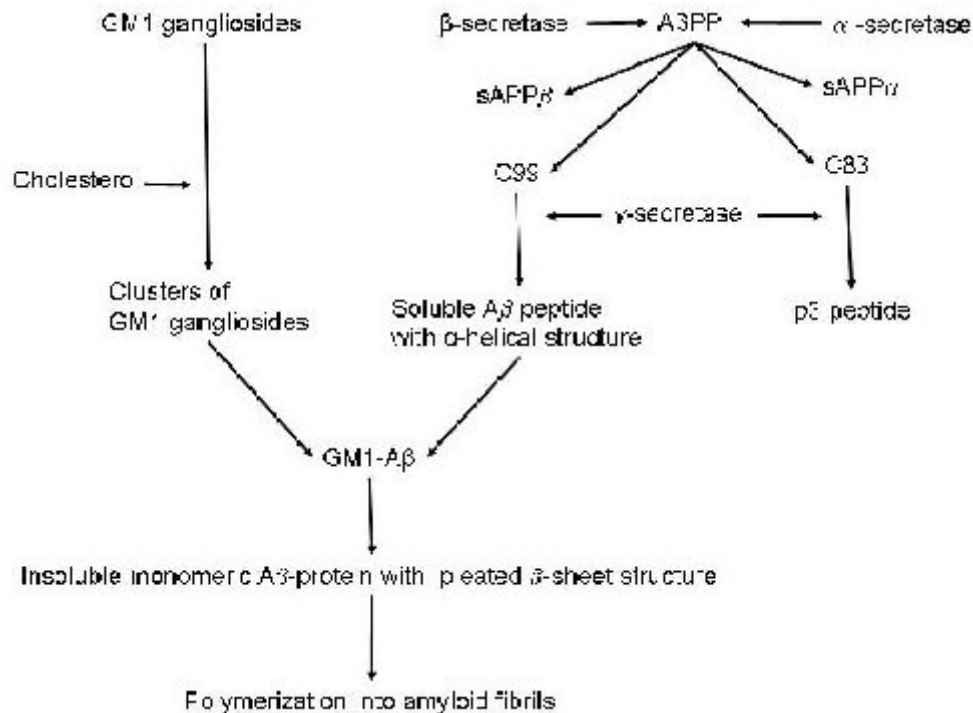


Figure 3. Possible major pathway of amyloidogenesis from A β PP [27] [34].

Oxidative stress

Although the principal cause of SDAT is unknown, studies have shown that oxidative damage due to oxidative stress might play an important role [35] [36]. The damage results from free radicals. Once formed, the free radicals attack cell constituents: lipids, proteins, sugars, and nucleic acids. Oxidative damage can, therefore, be determined by detecting accumulated end products of the oxidative processes and by studying secondary consequences of tissue damage due to the oxidative stress, such as demyelination [37]. In brain tissue, the occurrence of oxidative stress is well known during the penumbra phenomenon after an episode of blood vascular hypoperfusion. In geriatric humans, such hypoperfusion might occur due to atherosclerosis or the CAA.

Lipofuscin-like pigment, a result of oxidative stress

As a result of the oxidative stress, free radicals are formed and a complex process of lipid peroxidation at unsaturated bonds is initiated. A wide range of cross-linked lipid products may be formed which can be detected through relatively low-reactive end-products in fluorescent light. These products were originally called lipofuscin-like pigments (LFPs) on the basis of similarity of their fluorescence spectra to lipofuscin, the well-known 'wear and tear' or aging pigment. Due to their native (auto)fluorescence they can be detected and have been used as an indicator of free radical damage to lipids in various tissues [38] [39]. The LFPs formed in the brain are lipid soluble and can diffuse from the site of primary radical attack, to interact with membranes of other cells, such as erythrocytes in the blood stream [38] [39]. Consecutively elevated peripheral blood erythrocyte membrane LFP levels might be used to monitor oxidative damage in the brain. As mentioned above, the free radical damage may cause neurodegeneration [40], white matter changes (demyelination) [37], or both. It is still

not clear whether the neurodegeneration or the demyelination is more important for the deterioration of cognitive functions.

Inflammation

A β -peptide deposits, NFT, and oxidative stress provide stimuli for inflammation. The opposite might also be possible: microglia and macrophages might stimulate deposition of A β peptide or amyloid. It is known that A β and NFT play a role in the activation of macrophages and microglia by activating the complement pathway [41] [42]. Activated microglia have been found clustered around amyloid plaques, due to generated complement signals for chemotaxis. Activated microglia and macrophages in turn produce cytokines that modulate A β PP synthesis and convert nonfibrillar A β to fibrillar A β . It has been shown that microglia/macrophages play a role in plaque evolution by phagocytosis and/or degrading of deposited A β . As mentioned above, oxidative stress plays a role in inflammation in AD. End products of oxidative stress and advanced glycation end products (AGE) activate microglia and macrophages. These activated cells generate free radicals: reactive oxygen species (ROS) and nitric oxide (NO), enhancing oxidative damage in their environment [43] [44].

Diagnosis of SDAT

Cognitive disorders are diagnosed with the help of questionnaires [11] [13]. The diagnosis of SDAT is confirmed post mortem, when the brain has been examined macroscopically and microscopically [14]. Recently, advanced technical studies have shown the possibility of confirming the diagnosis while patients are still alive. Typical changes may be revealed by MRI [45] and cerebrospinal fluid (CSF) can be assayed for levels of biomarkers such as tau and A β [46].

Animal models to study SDAT

To study and understand the pathogenesis of SDAT various animal models have been used. An ideal animal model should show the same diversity in cognitive functioning as humans during aging, show different types of cognitive dysfunctions due to aging (e.g., learning impairments, memory deficits and visuospatial functioning), and especially histopathological lesions corresponding to SDAT pathology in human brains. Amyloid deposits and tau protein have been detected in several mammals [47] [48] [49] [50] [51]. Dogs are ideal models to study Alzheimer's disease. They display similar patterns of cognitive decline (deficit in learning ability and memory) due to aging [52] and age-related brain pathology similar to that in humans [53]. In most countries companion dogs share the same environment as humans. Dogs can be taught cognitive tasks without difficulty [52] [54]. Some authors have described the senile canine brain disorder as 'canine counterpart of the senile dementia of the Alzheimer type: ccSDAT' [55] [56].

Behavioural changes due to ccSDAT

Behavioural changes in geriatric dogs (Figure 4) due to cognitive decline have been observed frequently and have been classified using questionnaires by several authors [57] [58] [59]. These questionnaires contain a variety of items describing the behavioural symptoms. Correlating behavioural changes with Alzheimer-like brain pathology in dogs, such as brain atrophy, amyloid depositions, and accumulation of oxidative damage products might indicate the importance of items in the questionnaires with respect to the diagnosis of Alzheimer-like changes. In order to investigate the relevance of the items, two age-matched groups of old dogs, with and without behavioural changes, were compared [60]. The behavioural changes were analysed and scored with the questionnaires and necropsy was performed to rule out any other cause for changed behaviour. The behavioural changes were briefly described in the items of the questionnaires and evaluated by correlating them with the brain lesions found. The sum of the behavioural changes was expressed in a dementia score. The scores in old dogs appeared to be as variable as those in elderly humans. The dementia scores correlated significantly with all brain lesions studied except demyelination, in contrast to studies in human brains [60]. This might indicate that demyelination plays a less significant role than other changes found in the dog brains, or that demyelination had not progressed sufficiently to cause changes because dogs are euthanised in earlier stages of the dementia disorder.



Figure 4. Panel A. A 15-year-old female cross-breed wants to enter the house by passing through the wrong side of the door. The dog does not realize that it does not fit through that slit. Panel B. The dog is stuck between a garbage can and a kitchen cupboard door because it does not realize that it can get out by walking backwards.

Behavioural changes similar to ccSDAT due to other disorders

Before the diagnosis ccSDAT can be made, a thorough clinical examination and inventory of the behaviour of a geriatric dog is necessary. Dogs suffering from failure of an internal organ may also display behavioural changes, which the owners could interpret as dementia [61]. Comparison of healthy old dogs, dogs with renal or liver disease, and old dogs with ccSDAT (demented) but healthy renal and liver function revealed that dogs with renal or liver disease displayed several behavioural changes similar to those in demented dogs. Thus, short questionnaires provided by pet food companies which are used in many veterinary practices to diagnose cognitive impairment could lead to a misdiagnosis. A more elaborate questionnaire revealed that dogs suffering from renal or liver diseases do not reach the dementia score level of a demented dog. Thorough investigation of the behavioural changes in addition to a complete clinical examination may solve the diagnostic problem.

Canine brain pathology

Several papers have described brain lesions in dogs resembling those in humans with SDAT, such as brain atrophy, amyloid deposits in cerebral artery walls and cerebral grey matter, accumulation of oxidative damage products, and products related to NFT.

Neurofibrillary tangles, tau protein, and ubiquitin in aged dogs

An important lesion in SDAT patient brains is the formation of neurofibrillary tangles (NFT). Hyperphosphorylated tau, ubiquitin, and advanced glycation end products (AGE) antigens have been reported to be co-localized in NFT. During aging, AGE accumulate in the human brain and glycated tau induces lipid peroxidation *in vivo*. This indicates that AGE may play an important role in SDAT by oxidation of tau. There are reports that NFT and tau protein have been detected in dogs, e.g., in cerebral neurons and neurons in the brain stem. There are also reports that it has not been found. The finding of a weak indication of tau, ubiquitin, and advanced glycation end products (AGE) in some old dogs [55] might indicate that the spontaneous brain pathology of the aged dog is similar to the early stages of SDAT in humans, especially those with Down's syndrome [62] [63]. In Down's syndrome NFT formation follows plaque formation. Moreover, it has been suggested that dogs probably do not live long enough to develop NFT because they are euthanised in an early stage of ccSDAT.

Amyloid deposits in the canine brain

Investigation of canine brains has revealed amyloid deposits in cerebral artery walls and cerebral grey matter in the form of diffuse and dense plaques (Figure 5). Comparison of the morphology of the human plaques in Figure 1 with that of the canine plaques in Figure 5 reveals no difference. The amyloid deposits correlated with age and cognitive dysfunction [54] [64].

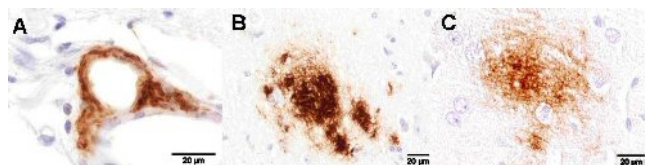


Figure 5. Immunohistochemical staining of A β -amyloid protein (mouse monoclonal antibodies against anti-human A β 8-17) in a blood vessel wall (panel A), in brain tissue as a dense plaque (panel B), and a diffuse plaque (panel C)

of a 14-year-old neutered female dog which displayed symptoms of cognitive deterioration.

Oxidative damage

Oxidative damage is considered to play an important role in SDAT. It has also been reported in dogs [53] [55] [56] [60] [65]. This is supported by the finding of a significant correlation of the oxidative damage products 4-hydroxy-2-nonenal (HNE), 8-hydroxy-2'-deoxyguanosine (OHdG), and lipofuscin with age and a high dementia score [60]. These results suggest that even lipofuscin may seriously impair the function of cellular systems in the aged brain, as has been suggested [66]. The role of free radicals in oxidative damage was studied in canine brain and blood samples. This revealed a significant increase in lipid oxidation products (lipofuscin-like pigments) in erythrocyte membranes and in brain tissue and protein oxidation products (carbonyl proteins) in brain tissue [67]. Furthermore, a significant decrease of the antioxidant vitamin E was found in brain samples of demented dogs [67]. This result appears to have implications for therapeutic possibilities and fits with other reports. The low vitamin E levels might indicate that there is a lower uptake by the body, or that there is increased vitamin E consumption due to increased free radical production in advanced age. Several pet food companies have increased the level of vitamin E in their diets for old dogs to prevent or stabilize cognitive deterioration. It would be interesting to study whether the vitamin E levels are improved in brains of dogs receiving those diets. Preliminary studies (data not shown) showed no decline in LFP levels in erythrocyte membrane fractions and brain extracts.

As mentioned above, dogs with renal or liver disease may have behavioural changes similar those in demented dogs as a result of oxidative damage [61]. Comparison of young dogs, old dogs, old demented dogs, and dogs with renal or liver disease revealed significant differences in LFP levels in the dogs with liver diseases compared with demented dogs and dogs with renal diseases. Results of the synchronous fluorescence spectra of pooled blood samples revealed that the composition of fluorophores of LFP was different for young dogs, old dogs, old demented dogs, and those with renal or liver disease, meaning that each category had its own specific LFP composition.

Cause of oxidative damage

The amount of oxidative damage products was found to be correlated with amyloid, which raises the question: what caused the oxidative damage, the amyloid deposits or decreased brain perfusion? Studies have shown that neurons produce the β -amyloid peptide [68] [69]. Although that A β peptide has an antioxidant function [35], it also has pro-oxidant abilities and it may produce free radicals causing oxidative damage [70].

According to several authors, geriatric humans may suffer from hypoperfusion of the brain and oxidative stress due to arteriosclerosis, amyloid angiopathy (CAA), or other vascular lesions, possibly leading to SDAT [51] [71] [72]. Atherosclerosis is not as common in dogs as in humans, but CAA has been described as a common disorder in ageing dogs [55] [56] [60]. Preliminary investigations in geriatric dogs revealed a decrease in arterial filling (Figure 6) and an increase in vascular wall tissue mass (collagen and amyloid) with age [73]. The decreased filling correlated with accumulation of amyloid deposits and oxidative damage products in brain tissue and in cerebral blood vessel walls.

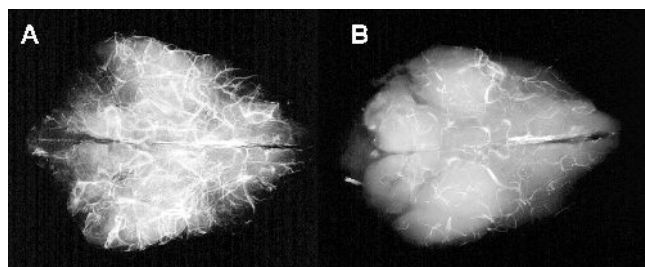


Figure 6. Radiograph of the brain of a young dog, 0.3 years (A) and of an old dog, 19 years (B). The larger arteries are filled with barium sulphate in saline (white lines). There is a significant decrease in arterial filling in the old dog (B) compared with the young dog (A).

Inflammation

Studying the role of inflammation revealed an accumulation of macrophages in the white matter. They were located perivascularly [56] and were positively correlated with age, oxidative damage, and behavioural changes (dementia score) [60]. The fact that there was very little increase in macrophages in the vicinity of vascular amyloid deposits and diffuse and

dense plaques in the grey matter [56] agrees with findings by others in dog brains [74]. In humans only neuritic plaques are surrounded by macrophages, indicating that the inflammation described in human brains depends on neuritic change. Insoluble A β peptide damages neurons and neurites, and NFT stimulate macrophages. In the dog neuritic degeneration and tangle formation are minimal and insoluble A β is mostly found in meningeal and cerebral arterial walls, which might explain the restriction of macrophages to the adventitia of blood vessels in the canine white matter.

Diagnosis of ccSDAT

There are many conditions that could cause behaviour changes in old dogs and there is need for objective diagnostics. MRI and examination of CSF are too elaborate and expensive for a veterinary clinic. A blood test would be more appropriate. As has been outlined above, oxidative damage plays an important role in SDAT and ccSDAT. Since LFP has been used as an indicator of free radical damage to lipids [38] [75] in various tissues, it might also be applicable to the brain [67]. In a preliminary study, significant differences in LFP levels were found between for young dogs, old dogs with normal behaviour, and dogs with ccSDAT. However, oxidative damage has also been described in patients with renal disease and liver disease, patients which often have behavioural changes as well [61]. This might interfere with diagnosing behavioural changes due to brain damage and also interfere with using LFP as a diagnostic indicator of SDAT.

Diagnostics for veterinary practice

In humans several diagnostic procedures are used for SDAT in living patients [76] [77], such as MRI and magnetization transfer imaging (MTI). MRI is used to detect cerebral lobe atrophy and white matter hyperintensities (WMH). MTI allows more accurate detection and quantification of histological changes during life. Data obtained by MTI provide a quantitative estimate of structural damage in large portions of the brain. Measurements of biomarkers (β -amyloid₁₋₄₂, tau) in CSF and neuroimaging to evaluate the onset and progression SDAT by detecting microglial activation [78], amyloid deposits, and enzymatic activity, are other options for the diagnosis of SDAT in humans. These technologies, as mentioned above, are not suitable as diagnostic tools in veterinary practice.

Data obtained from our investigations show that a questionnaire [60] adapted from a former study [57] is an adequate diagnostic tool in addition to clinical examination. Preliminary studies revealed that with this questionnaire, one can distinguish between behavioural changes due to ccSDAT and renal or liver disease. These results are promising. Although the differences in LFP levels were not significant in all cases, the composition of the LFP was (data not yet published).

Conclusion

Dogs form a good model for study of SDAT. They display behavioural changes and pathological lesions similar to those in geriatric humans with and without cognitive impairment. A questionnaire is available, suitable for use in veterinary practice, to help diagnose changed behaviour due to cognitive disturbances. Accumulation of amyloid and oxidative damage products appears to be age related and to correlate with the behavioural changes. It is interesting that amyloid deposits have a lower correlation with the dementia score than do oxidative damage products. This suggests that amyloid may be less important than the oxidative damage in the pathogenesis of Alzheimer's disease. A preliminary study of LFP fluorescence in pooled blood samples revealed a specific fluorophore in membranes of erythrocytes of demented dogs. A longitudinal follow-up study is suggested, combining a search for the specific "demented" LFP pattern in younger dogs and long-term follow-up to see whether they develop ccSDAT in the future.

References

1. Alzheimer, A., 1907. Über einen eigenartige Erkrankung der Hirnrinde. Allgemeine Zeitschrift für Psychiatrie und Psychisch-gerichtliche Medizin 64: 146-148.
2. Alzheimer, A., 1911. Über eigenartige Krankheitsfälle des späteren Alters. Zeitschrift für die Gesamte Neurologie und Psychiatrie 4: 356-385.
3. Perusini, G., 1909. Über klinisch und histologisch eigenartige psychische Erkrankungen des späteren

- Lebensalters. Histologische und Histopathologische Arbeiten. Jena: Verlag G Fischer, 297-351.
4. Kraepelin, E., 1910. *Psychiatrie: Ein Lehrbuch für Studierende und Ärzte*. 593-632.
 5. All Refer Health. <http://health.allrefer.com/health/alzheimers-disease-info.html>.
 6. Huppert, F., Wilcock, G., 1997. [Ageing, cognition and dementia](#). *Age Ageing* 26: Suppl 4, 20-3.
 7. Bennett, D.A., Schneider, J.A., Bienias, J.L., Evans, D.A. Wilson, R. S., 2005. [Mild cognitive impairment is related to Alzheimer disease pathology and cerebral infarctions](#). *Neurology* 64: 834-41.
 8. Rombouts, S.A., Barkhof, F., Goekoop, R., Stam, C.J., Scheltens, P., 2005. [Altered resting state networks in mild cognitive impairment and mild Alzheimer's disease: An fMRI study](#). *Hum Brain Mapp.*
 9. Rombouts, S.A., Goekoop, R., Stam, C.J., Barkhof, F., Scheltens, P., 2005. [Delayed rather than decreased BOLD response as a marker for early Alzheimer's disease](#). *Neuroimage* 26: 1078-85.
 10. Teri, L., McCurry, S.M., Logsdon, R.G., 1997. [Memory, thinking, and aging. What we know about what we know](#). *West J Med.* 167: 269-75.
 11. Roth, M. et al., 1986. [CAMDEX. A standardised instrument for the diagnosis of mental disorder in the elderly with special reference to the early detection of dementia](#). *Br J Psychiatry* 149: 698-709.
 12. Schmidt, K.S., Mattis, P.J., Adams, J., Nestor, P., 2005. [Alternate-form reliability of the Dementia Rating Scale-2](#). *Arch Clin Neuropsychol.* 20: 435-41.
 13. Folstein, M.F., Folstein, S.E., McHugh, P.R., 1975. ["Mini-mental state". A practical method for grading the cognitive state of patients for the clinician](#). *J Psychiatr Res.* 12: 189-98.
 14. Ingelsson, M. et al., 2004. [Early Abeta accumulation and progressive synaptic loss, gliosis, and tangle formation in AD brain](#). *Neurology* 62: 925-31.
 15. de Figueiredo, R.J., Oten, R., Su, J. Cotman, C.W., 1997. [Amyloid deposition in cerebrovascular angiopathy](#). *Ann N Y Acad Sci.* 826: 463-71.
 16. Yamaguchi, H., Yamazaki, T., Lemere, C.A., Frosch, M.P., Selkoe, D.J., 1992. [Beta amyloid is focally deposited within the outer basement membrane in the amyloid angiopathy of Alzheimer's disease](#). An immunoelectron microscopic study. *Am J Pathol.* 141: 249-59.
 17. de la Torre, J.C., 2000. [Impaired cerebrovascular perfusion. Summary of evidence in support of its causality in Alzheimer's disease](#). *Ann N Y Acad Sci.* 924: 136-52.
 18. de la Torre, J.C., 2000. [Cerebral hypoperfusion, capillary degeneration, and development of Alzheimer disease](#). *Alzheimer Dis Assoc Disord.* 14: Suppl 1, S72-81.
 19. Yamaguchi, H., Nakazato, Y., Hirai, S., Shoji, M., Harigaya, Y., 1989. [Electron micrograph of diffuse plaques. Initial stage of senile plaque formation in the Alzheimer brain](#). *Am J Pathol.* 135: 593-7.
 20. Yamaguchi, H., Nakazato, Y., Hirai, S., Shoji, M., 1990. [Immunoelectron microscopic localization of amyloid beta protein in the diffuse plaques of Alzheimer-type dementia](#). *Brain Res.* 508: 320-4.
 21. Yamaguchi, H., Hirai, S., Morimatsu, M., Shoji, M., Ihara, Y., 1988. [A variety of cerebral amyloid deposits in the brains of the Alzheimer-type dementia demonstrated by beta protein immunostaining](#). *Acta Neuropathol (Berl).* 76: 541-9.
 22. Linke, R.P., 2000. [Highly sensitive diagnosis of amyloid and various amyloid syndromes using Congo red fluorescence](#). *Virchows Arch.* 436: 439-48.
 23. Buee, L., Bussiere, T., Buee-Scherrer, V., Delacourte, A., Hof, P.R., 2000. [Tau protein isoforms, phosphorylation and role in neurodegenerative disorders](#). *Brain Res Brain Res Rev.* 33: 95-130.
 24. Sergeant, N., Bussiere, T., Vermersch, P., Lejeune, J.P., Delacourte, A., 1995. [Isoelectric point differentiates PHF-tau from biopsy-derived human brain tau proteins](#). *Neuroreport.* 6: 2217-20.
 25. Lee, G., 2005. [Tau and src family tyrosine kinases](#). *Biochim Biophys Acta.* 1739: 323-30.
 26. Morishima-Kawashima, M. et al., 1993. [Ubiquitin is conjugated with amino-terminally processed tau in paired helical filaments](#). *Neuron* 10: 1151-60.
 27. Zha, Q., Ruan, Y., Hartmann, T., Beyreuther, K., Zhang, D., 2004. [GM1 ganglioside regulates the proteolysis of amyloid precursor protein](#). *Mol Psychiatry* 9: 946-52.
 28. Selkoe, D. J., 1994. [Amyloid beta-protein precursor: new clues to the genesis of Alzheimer's disease](#). *Curr Opin Neurobiol.* 4: 708-16.
 29. Head, E., Torp, R., 2002. [Insights into Abeta and presenilin from a canine model of human brain aging](#). *Neurobiol Dis.* 9: 1-10.
 30. Selkoe, D.J., 1991. [The molecular pathology of Alzheimer's disease](#). *Neuron* 6: 487-98.
 31. Calingasan, N.Y. et al., 1995. [Accumulation of amyloid precursor protein-like immunoreactivity in rat brain in response to thiamine deficiency](#). *Brain Res.* 677: 50-60.
 32. Kamal, A., Almenar-Queralt, A., LeBlanc, J.F., Roberts, E.A., Goldstein, L.S., 2001. [Kinesin-mediated axonal transport of a membrane compartment containing beta-secretase and presenilin-1 requires APP](#). *Nature* 414: 643-8.
 33. Ramirez, M.J., Heslop, K.E., Francis, P.T., Rattray, M., 2001. [Expression of amyloid precursor](#)

- [protein, tau and presenilin RNAs in rat hippocampus following deafferentation lesions](#). Brain Res. 907: 222-32.
34. Ling, Y., Morgan, K., Kalsheker, N., 2003. [Amyloid precursor protein \(APP\) and the biology of proteolytic processing: relevance to Alzheimer's disease](#). Int J Biochem Cell Biol. 35: 1505-35.
35. Smith, M.A., Rottkamp, C.A., Nunomura, A., Raina, A.K., Perry, G., 2000. [Oxidative stress in Alzheimer's disease](#). Biochim Biophys Acta 1502: 139-44.
36. Rottkamp, C.A. et al., 2000. [Oxidative stress, antioxidants, and Alzheimer disease](#). Alzheimer Dis Assoc Disord. 14: Suppl 1, S62-6.
37. Englund, E., Brun, A., 1990. [White matter changes in dementia of Alzheimer's type: the difference in vulnerability between cell compartments](#). Histopathology 16: 433-9.
38. Wilhelm, J., Herget, J., 1990. [Hypoxia induces free radical damage to rat erythrocytes and spleen: analysis of the fluorescent end-products of lipid peroxidation](#). Int J Biochem Cell Biol. 31: 671-81.
39. Vesela, A., Wilhelm, J., Kawaciuk I., 2002. Investigation of the role of free radical damage in patients after transurethral prostatectomy. J Urol. 167: 221-222.
40. Sayre, L.M., Smith, M.A. Perry, G., 2001. Chemistry and biochemistry of oxidative stress in neurodegenerative disease. Curr Med Chem. 8: 721-38.
41. Loeffler, D.A., 2004. [Using animal models to determine the significance of complement activation in Alzheimer's disease](#). J Neuroinflammation 1: 18.
42. Tuppo, E.E., Arias, H.R., 2005. [The role of inflammation in Alzheimer's disease](#). Int J Biochem Cell Biol. 37: 289-305.
43. Akiyama, H. et al., 2000. [Inflammation and Alzheimer's disease](#). Neurobiol Aging 21: 383-421.
44. Munch, G. et al., 2003. [Microglial activation induces cell death, inhibits neurite outgrowth and causes neurite retraction of differentiated neuroblastoma cells](#). Exp Brain Res. 150: 1-8.
45. van der Flier, W.M. et al., 2005. [Neuropsychological correlates of MRI measures in the continuum of cognitive decline at old age](#). Dement Geriatr Cogn Disord. 20: 82-88.
46. Grossman, M. et al., 2005. [Cerebrospinal fluid profile in frontotemporal dementia and Alzheimer's disease](#). Ann Neurol. 57: 721-9.
47. Giannakopoulos, P. et al., 1997. [Quantitative analysis of tau protein-immunoreactive accumulations and beta amyloid protein deposits in the cerebral cortex of the mouse lemur, Microcebus murinus](#). Acta Neuropathol (Berl). 94: 131-9.
48. Braak, H., Braak, E., Strothjohann, M., 1994. [Abnormally phosphorylated tau protein related to the formation of neurofibrillary tangles and neuropil threads in the cerebral cortex of sheep and goat](#). Neurosci Lett. 171: 1-4.
49. Papaioannou, N. et al., 2001. [Immunohistochemical investigation of the brain of aged dogs. I. Detection of neurofibrillary tangles and of 4-hydroxynonenal protein, an oxidative damage product, in senile plaques](#). Amyloid 8: 11-21.
50. Head, E. et al., 2005. [Beta-amyloid deposition and tau phosphorylation in clinically characterized aged cats](#). Neurobiol Aging 26: 749-63.
51. Roertgen, K.E. et al., 1996. [A beta-associated cerebral angiopathy and senile plaques with neurofibrillary tangles and cerebral hemorrhage in an aged wolverine \(Gulo gulo\)](#). Neurobiol Aging 17: 243-7.
52. Adams, B., Chan, A., Callahan, H., Milgram, N.W., 2000. The canine as a model of human cognitive aging: recent developments. Prog Neuropsychopharmacol Biol Psychiatry 24: 675-92.
53. Borrás, D., Ferrer, I., Pumarola, M., 1999. [Age-related changes in the brain of the dog](#). Vet Pathol. 36: 202-11.
54. Cummings, B.J., Head, E., Afagh, A.J., Milgram, N. W., Cotman, C.W., 1996. [Beta-amyloid accumulation correlates with cognitive dysfunction in the aged canine](#). Neurobiol Learn Mem. 66: 11-23.
55. Rofina, J.E. et al., 2004. [Histochemical accumulation of oxidative damage products is associated with Alzheimer-like pathology in the canine](#). Amyloid 11: 90-100.
56. Rofina, J.E. et al., 2000. [Canine counterpart of senile dementia of the Alzheimer type: amyloid plaques near capillaries but lack of spatial relationship with activated microglia and macrophages](#). J Protein Folding Disorders 10: 86-96.
57. Rofina J.E., van der Meer I., Goossens M., Secrève M., van Ederen A.M., Schilder M., Gruys E., 2001. Preliminary inquiry to assess behavior changes in aging pet dogs. IXth international symposium on Amyloidosis, 464-466.
58. Kiatipattanasakul, W. et al., 1996. [Apoptosis in the aged dog brain](#). Acta Neuropathol (Berl). 92: 242-8.
59. Colle, M.A. et al., 2000. [Vascular and parenchymal Abeta deposition in the aging dog: correlation with behavior](#). Neurobiol Aging 21: 695-704.

60. Rofina J.E, van Ederen, A.M., Toussaint M.J.M., Secrève M., van der Spek, A., van der Meer I., van Eerdenburg, F.J., Gruys E., 2006. [Cognitive disturbances in old dogs suffering from the canine counterpart of Alzheimer's disease](#). Brain Res. 1069: 216-226.
61. Parker, A.L., 1995. Behavioral signs of organic disease. In: Ettinger S.J., Feldman E.C. Eds. Textbook of Veterinary Internal Medicine. Philadelphia: W.B. Saunders Company, 175-178.
62. Mann, D.M., 1988. [The pathological association between Down syndrome and Alzheimer disease](#). Mech Ageing Dev. 43: 99-136.
63. Coyle, J.T., Oster-Granite, M.L., Gearhart, J.D., 1986. [The neurobiologic consequences of Down syndrome](#). Brain Res Bull.16: 773-87.
64. Cummings, B.J., Head, E., Ruehl, W., Milgram, N.W., Cotman, C.W., 1995. [The canine as an animal model of human aging and dementia](#). Neurobiol Aging 17: 259-268.
65. Head, E. et al., 2002. [Oxidative damage increases with age in a canine model of human brain aging](#). J Neurochem. 82: 375-81.
66. Gray, D.A., Woulfe, J., 2005. [Lipofuscin and aging: a matter of toxic waste](#). Sci Aging Knowledge Environ. Re 1.
67. Skoumalova, A., Rofina, J., Schwippelova, Z., Gruys, E., Wilhelm, J., 2003. [The role of free radicals in canine counterpart of senile dementia of the Alzheimer type](#). Exp Gerontol 38, 711-9.
68. Pappolla, M.A., Omar, R.A., Sambamurti, K., Anderson, J.P., Robakis, N.K., 1992. [The genesis of the senile plaque. Further evidence in support of its neuronal origin](#). Am J Pathol 141, 1151-9.
69. Perry, G., Cras, P., Siedlak, S.L., Tabaton, M., Kawai, M., 1992. [Beta protein immunoreactivity is found in the majority of neurofibrillary tangles of Alzheimer's disease](#). Am J Pathol. 140: 283-90.
70. Butterfield, D.A., Hensley, K., Harris, M., Mattson, M., Carney, J., 1994. [Beta-Amyloid peptide free radical fragments initiate synaptosomal lipoperoxidation in a sequence-specific fashion: implications to Alzheimer's disease](#). Biochem Biophys Res Commun. 200: 710-5.
71. Riekse, R.G. et al., 2004. [Effect of vascular lesions on cognition in Alzheimer's disease: a community-based study](#). J Am Geriatr Soc. 52: 1442-8.
72. Thal, D.R., Ghebremedhin, E., Orantes, M., Wiestler, O.D., 2003. [Vascular pathology in Alzheimer disease: correlation of cerebral amyloid angiopathy and arteriosclerosis/lipohyalinosis with cognitive decline](#). J Neuropathol Exp Neurol. 62: 1287-301.
73. Rofina, J.E., 2005. Canine counterpart of senile dementia of the Alzheimer type. Thesis Utrecht University.
74. Wegiel, J., Wisniewski H.M., Dziewiatkowski J., Tarnawski M., Dziewiatkowska A., Soltysiak Z., Kim K-S., 1995. Fibrillar and non-fibrillar amyloid in the brain of aged dogs. Research of advanced Alzheimer's disease and related diseases 76: 703-707.
75. Wilhelm, J., Brzak, P., Rejholcova, M., 1989. [Changes of lipofuscin-like pigments in erythrocytes and spleen after whole-body gamma irradiation of rats](#). Radiat Res. 120: 227-33.
76. Su, M.Y. et al., 1998. [Magnetic resonance imaging of anatomic and vascular characteristics in a canine model of human aging](#). Neurobiol Aging 19: 479-85.
77. Su, M.Y. et al., 2005. [A longitudinal study of brain morphometrics using serial magnetic resonance imaging analysis in a canine model of aging](#). Prog Neuropsychopharmacol Biol Psychiatry 29: 389-97.
78. Arends, Y.M., Duyckaerts, C., Rozemuller, J.M., Eikelenboom, P., Hauw, J.J., 2000. [Microglia, amyloid and dementia in Alzheimer disease. A correlative study](#). Neurobiol Aging 21: 39-47.