Artery ligation in the treatment of hemorrhoidal disease

Jaap-Peter Schuurman

Artery ligation in the treatment of hemorrhoidal disease

Thesis, Utrecht University, the Netherlands

ISBN	978-90-393-5820-7
Lay-out	Bram Zondag
Illustrations	Rogier Trompert
Printed by	OCC De Hoog B.V., Oosterhout

Artery ligation in the treatment of hemorrhoidal disease

Arterie ligatie procedure voor de behandeling van hemorroïden

(met een samenvatting in het Nederlands)

Proefschrift

ter verkrijging van de graad van doctor aan de
Universiteit Utrecht op gezag van de rector magnificus,
prof. dr. G.J. van der Zwaan, ingevolge het besluit van het
college voor promoties in het openbaar te verdedigen op
dinsdag 25 september 2012 des middags te 4.15 uur

door

Jacob Peter Schuurman

geboren op 18 augustus 1983 te Utrecht

Promotor: Prof. dr. I.H.M. Borel Rinkes

Co-promotor: Dr. P.M.N.Y.H. Go

The printing of this thesis was financially supported by:

Contents

1

General introduction and outline of the thesis

1

General introduction and outline of the thesis

Hemorrhoidal disease

Complaints in the anal area are a frequently occurring disorder. A major cause of anal complaints involve hemorrhoidal disease which has a roughly estimated prevalence of 7.3 to 10.1 per 1000 in the Netherlands with a male to female ratio of 1:4.[1-3] Hemorrhoidal disease is often referred to as hemorrhoids or piles. Typically, patients complain of painless blood loss during defecation possibly accompanied by prolapsing tissue which may or may not retract spontaneously.

Hemorrhoidal tissue is physiological and represents a part of the anal continence mechanism that is located in the anal canal and distal rectum. In a non-pathological case the hemorrhoidal tissue is described as vascular cushions embedded in a stroma of connective tissue and smooth muscle fibers situated within the anal canal. This complex fulfills four main functions: the three cushions in the anal canal provide maintenance of anal continence, provide 15%–20% of resting anal pressure, protect the sphincter mechanism during evacuation and form a compressible lining, facilitating closure of the anal canal.[4] The smooth muscle acts as a supportive structure, forming a fibro-elastic network within the plexuses.[5] This structure was named by Stelzner *et al.* as the corpus cavernosum recti, also known as plexus hemorrhoidalis, and is supplied by a complex structure of blood vessels.[6]

The exact location of this tissue is in the distal rectum over a trajectory of 2 to 3 centimeters and ends at the dentate line (Figure 1). The dentate line is both an anatomical and histological border marking the transition from mucosa to squamous epithelium. This line is also used to differentiate between internal and external hemorrhoids. Although this classification is still used frequently, it is confusing since internal hemorrhoids have a completely different etiology than external ones. Instead, it is advisable to differentiate internal hemorrhoids from a thrombosed anal peripheral vein.

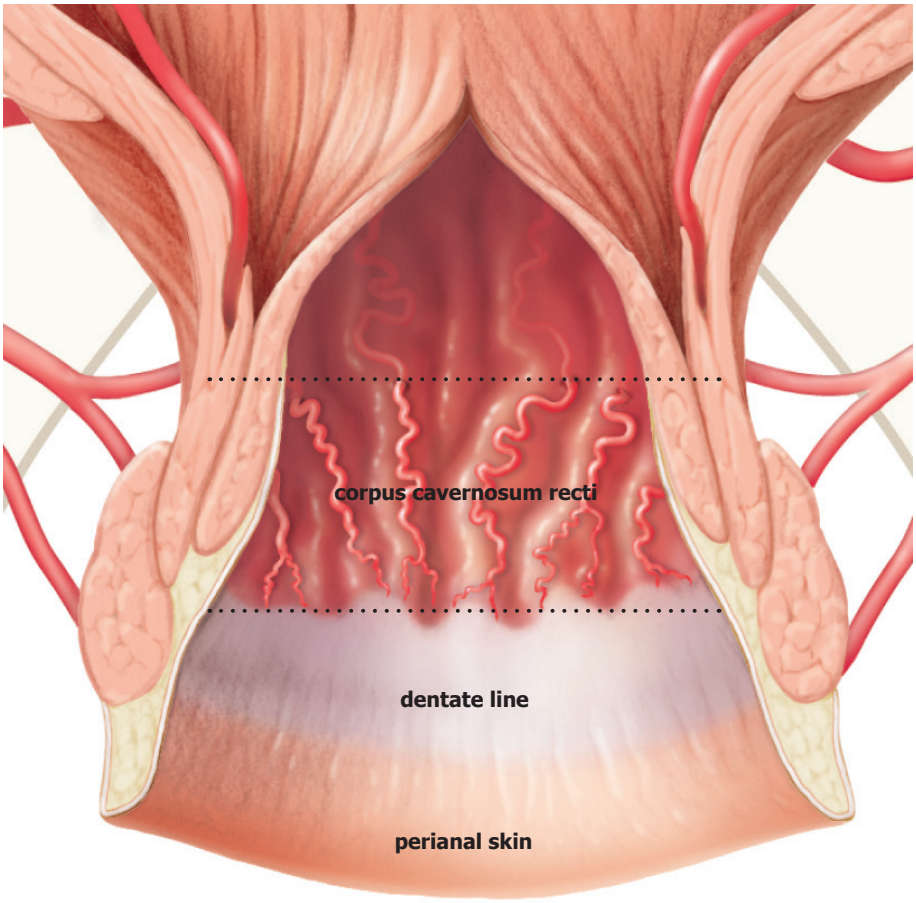

Figure 1. Overview of the distal anal canal with the corpus cavernosum recti indicated.

The internal hemorrhoids find their origin in the intra-luminally located plexus hemorrhoidalis superior, the corpus cavernosum of the rectum (Figure 2a). One refers to an internal hemorrhoid when this physiological corpus cavernosum recti swells, loses its function as well as its relation to the surrounding tissue and eventually prolapses outside to some degree. This may or may not be accompanied by blood loss. Internal hemorrhoids can be divided into four types according to the classification of Goligher.[7] First-degree hemorrhoids bleed but do not prolapse (i.e. normal-looking anal cushions causing symptoms). Second-degree hemorrhoids bleed and prolapse, but

reduce spontaneously after defecation. Third-degree hemorrhoids need to be reduced manually, and fourth-degree hemorrhoids are permanently prolapsed at the anal verge and cannot be reduced.

Thrombosis in an anal peripheral vein (previously external hemorrhoid) on the other hand stems from the inferior hemorrhoidal plexus and is located distally of the

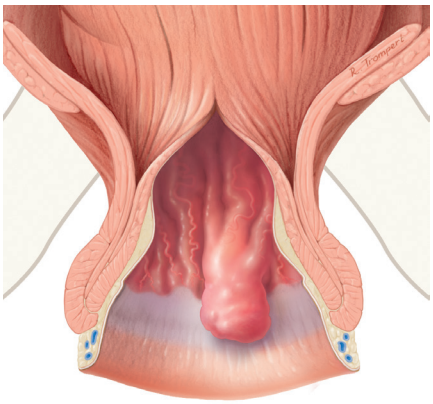

Figure 2a. Internal hemorrhoid

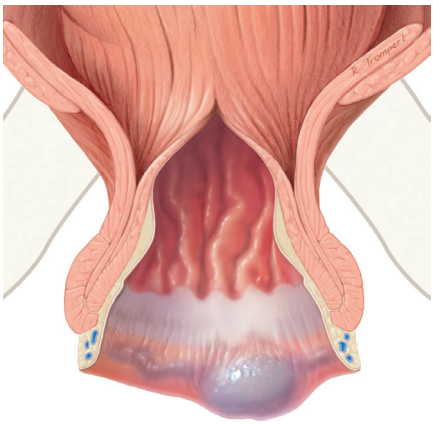

Figure 2b. Thrombosed anal peripheral vein

dentate line (Figure 2b). Contrary to the mucosa over the internal hemorrhoid in the distal rectum this squamous epithelium is innervated with somatic pain fibers causing this type of hemorrhoids to be extremely painful and distinguishable from internal hemorrhoids which are nearly always painless. There are also mixed lesions that involve both the superior and inferior hemorrhoidal plexus.

The etiology and pathophysiology of hemorrhoids is unclear. Several authors have tried to formulate a solid theory that would explain the forming mechanism, the complaints and the effects of various treatments. Mechanical wear in combination with stretching of the supporting tissue by age would be an explanation for the mucosal prolapse.[8, 9] Others have suggested that the problem arises from dysfunction of the blood flow in the arteriovenous shunts with dilatation, bleeding and eventually resulting in a prolapse. This theory has its own variations with bends in the arteries by shifts from the mucosa,

inadequately opening shunts as a result of irritation, disbalance in blood pressure due to diets that are low on fibers and varying anal rest pressures.[10, 11] Besides this, consensus exists that frequent straining while defecating, constipation and pregnancy are associated with heightened intra-abdominal pressure and therefore contribute to the formation of hemorrhoids. In short, the etiology of the disease appears to be multifactorial.[10]

Assessment

In determining the anal complaint the anamnesis and physical examination are of paramount importance. Asking detailed questions related to the complaints in daily life and the defecation provides a specific direction for a diagnosis. The physical examination should focus on a thorough inspection of the perineum and anus accompanied by a digital rectal examination.[12] Since hemorrhoids are not palpable the presence of hemorrhoids should be proven with proctoscopy. In the case of elderly patients with rectal blood loss it is recommended to perform a sigmoidoscopy to exclude the possibility of a rectal carcinoma. Vening *et al.* concluded that the age threshold for performing a colonoscopy, should be lowered from the frequently used age limit of 50-60 years to 40 years.[13]

Treatment

The majority of patients can be treated conservatively, including measures such as laxatives, ointments and lifestyle/dietary modifications. For more severe or persisting hemorrhoids several treatment modalities have become available, including Ferguson's (closed) hemorrhoidectomy, procedure for prolapse and hemorrhoids (PPH), Milligan-Morgan (open) hemorrhoidectomy, rubber band ligation and sclerotherapy. In selected cases a treatment with cryo- and laser application can be performed.[14,15] With this broad spectrum of possibilities a tailored surgery according to the grade of hemorrhoids has been made possible, clear cut guidelines however are not yet available in the Netherlands.

Since the arterial blood supply of the internal hemorrhoidal plexus is now commonly believed to be associated with the pathogenesis of hemorrhoids, newer techniques aim to reduce the vascularity of hemorrhoidal tissue. It was Morinaga *et al.* who, 15 years ago, first described the results of selective ligation of the supplying arteries of the corpus cavernosum recti in patients with hemorrhoidal disease.[16] This technique is based

on Doppler identification and suture ligation of the submucosally coursing terminal branches of the superior rectal artery in the corpus cavernosum recti. This procedure of artery ligation aims to block the arterial blood flow to the pathologic hemorrhoidal tissue in order to induce shrinkage of the corpus cavernosum recti with subsequent relief of symptoms. During the procedure the hemorrhoidal arteries are localized with a specially designed proctoscope involving a Doppler device and distally, an operating window allowing ligation of the rectal mucosa (figure 3). After insertion into the rectum, the supplying arteries are located and identified by an audible Doppler sound signal. At these positions the sutures are placed in the appropriate position, which is normally approximately 1-3 cm above the dentate line. Reduction or disappearance of the Doppler signal provides confirmation of vessel occlusion.

For the past 10 years this hemorrhoidal artery ligation procedure has increasingly found its basis in the treatment of mainly grade II and III hemorrhoidal disease. This

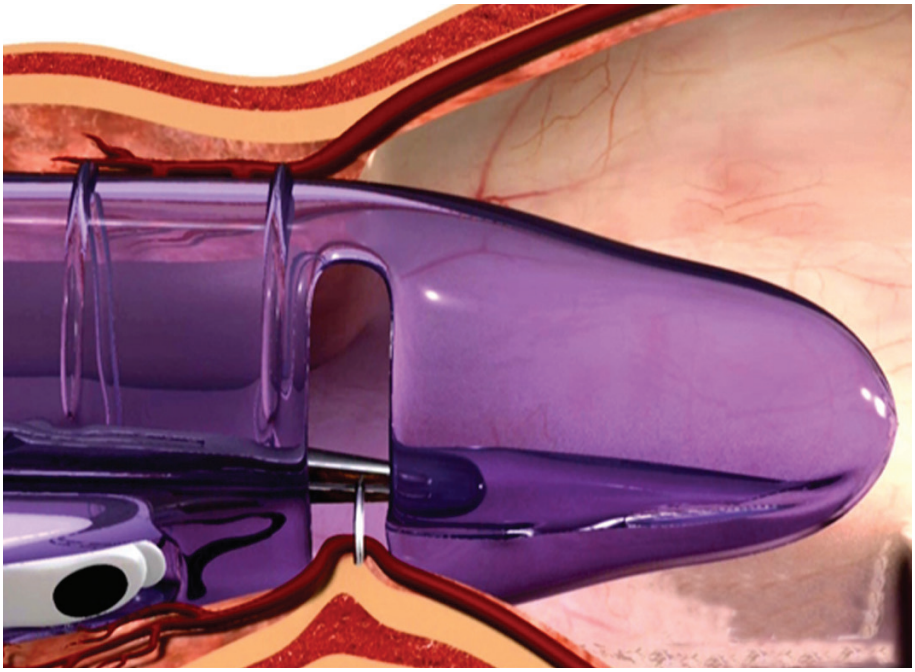

Figure 3. Proctoscope with Doppler transducer in the anal canal. A ligation is placed around a supplying artery. (Figure used from THD america database)

technique is also referred to as Doppler-guided hemorrhoid artery ligation (DG-HAL or HAL) or transanal hemorrhoidal dearterialization (THD) and is the subject of this thesis. Despite the fact that HAL is frequently used worldwide because of its high success rates and few postoperative discomforts, the underlying mechanism has not been fully elucidated. This thesis, therefore, focuses on the relation between the placement of Doppler guided ligations in the plexus hemorrhoidalis and the effects at an anatomical and clinical level.

Aims and outlines of this thesis

The aim of this thesis is to study the working principle of HAL in relation to the outcome in the treatment of patients suffering from grade II and III hemorrhoidal disease.

In **chapter 2,** the clinical status of patients, who had undergone HAL for the treatment of grade II and III hemorrhoidal disease, is investigated in a retrospective study.

In **chapter 3**, the vascular anatomical configuration of the corpus cavernosum recti in the distal rectum as the origin of hemorrhoidal tissue is investigated by means of a unique casting method.

In **chapter 4**, the results of the HEMARTY study (**hem**orrhoidal **art**er**y** ligation) is described. This randomized controlled trial was initiated for the determination of the added value of the use of Doppler during HAL. In this study patients suffering from hemorrhoidal disease grade II and III were either treated by means of the conventional HAL with or without the use of Doppler.

In **chapter 5**, the vascular anatomy of the corpus cavernosum recti in patients suffering from hemorrhoidal disease is investigated in the preoperative and postoperative (HAL) situation. The vascular anatomy as a consequence of treatment with or without the use of Doppler is discussed.

In **chapter 6**, the anamnestic complaint profile of patients with anal complaints referred by the general practitioner for hemorrhoidal disease is correlated with the definite diagnosis.

In **chapter 7**, a clinical case report is presented in which the difference between internal hemorrhoidal disease and thrombosed anal peripheral vein is explained, exemplified and discussed.

References

1. Centraal Begeleidingsorgaan voor de Intercollegiale Toetsing, *Consensus hemorroïden*, 1993, ISBN 90-6910-160-2. Available at http://www.huidziekten.nl/richtlijnen/richtlijn-hemorroiden-1994.pdf. Accessed at 01-07-2012.
2. Felice G, Privitera A, Ellul E, Klaumann M. Doppler-guided hemorrhoidal artery ligation: an alternative to hemorrhoidectomy. *Dis Colon Rectum* 2005; **48:** 2090-2093.
3. Wallis de Vries BM, van der Beek ES, de Wijkerslooth LR, van der Zwet WC, van der Hoeven JA, Eeftinck Schattenkerk M, *et al.* Treatment of Grade 2 and 3 Hemorrhoids with Doppler-Guided Hemorrhoidal Artery Ligation. *Dig Surg* 2007; **24:** 436-440.
4. Wexner SD, Baig K. The evaluation and physiologic assessment of hemorrhoidal disease: a review. *Tech Coloproctol* 2001; **5:** 165-168.
5. Dal Monte PP, Tagariello C, Sarago M, Giordano P, Shafi A, Cudazzo E, Franzini M. Transanal haemorrhoidal dearterialisation: Nonexcisional surgery for the treatment of haemorrhoidal disease. *Tech Coloproctol* 2007; **11:** 333-338.
6. Stelzner F, Staubesand J, Machleidt H. Das corpus carvernosum recti - die grundlage der inneren hämmorrhoiden. *Langenbecks Arch klein Chir* 1962; **299:** 302-312.
7. Goligher JC (1980 4th edition). Haemorrhoids or piles. In *Surgery of the Anus Rectum and Colon*, pp 93–135. Baillere Tindall, London.
8. Scheyer M, Antonietti E, Rollinger G, Mall H, Arnold S. Doppler-guided hemorrhoidal artery ligation. *Am J Surg* 2006; **191:** 89-93.
9. Arnold S, Antonietti E, Rollinger G, Scheyer M. Doppler ultrasound assisted hemorrhoid artery ligation. A new therapy in symptomatic hemorrhoids. *Chirurg*. 2002; **73:** 269-73.
10. Kaidar-Person O, Person B, Wexner SD. Hemorrhoidal disease: A comprehensive review. *J Am Coll Surg* 2007; **204:** 102-17.
11. Aigner F, Bodner G, Gruber H, Conrad F, Fritsch H, Margreiter R, *et al.* The vascular nature of hemorrhoids. *J Gastrointest Surg* 2006; **10:** 1044-50.
12. van Driel MF, van Andel MV, ten Cate Hoedemaker HO, Wolf RF, Mensink HJ. Physical diagnosis--digital rectal examination. *Ned Tijdschr Geneeskd* 2002; **16;** 146:508-12.
13. Vening W, Willigendael EM, Tjeertes EK, Hulsewe KW, Hoofwijk AG. Timing and necessity of a flexible sigmoidoscopy in patients with symptoms suggestive of haemorrhoids. *Colorectal Dis* 2010; **12:** 109-13.
14. Arezzo A, Podzemny V, Pescatori M. Surgical management of hemorrhoids. state of the art. *Ann Ital Chir* 2011; **82:** 163-72.
15. Sneider EB, Maykel JA. Diagnosis and management of symptomatic hemorrhoids. *Surg Clin North Am* 2010; **90:** 17-32.
16. Morinaga K, Hasuda K, Ikeda T. A novel therapy for internal hemorrhoids: Ligation of the hemorrhoidal artery with a newly devised instrument (moricorn) in conjunction with a doppler flowmeter. *Am J Gastroenterol* 1995; **90:** 610-3.

2

Inventory of hemorrhoidal status in patients previously treated with the hemorrhoidal artery ligation therapy

J.P. Schuurman, C. Salzbach, A. Pronk, P.M.N.Y.H. Go

Submitted

ABSTRACT

Purpose

The aim of this study was to prospectively inventory the status of the patients who had previously undergone a hemorrhoidal artery ligation procedure for the treatment of grades II and III hemorrhoidal disease.

Methods

In this prospective cohort study we included 103 patients with grade II and grade III hemorrhoidal disease who were treated with the ligation procedure. Two identical questionnaires, Q1 and Q2, concerning previous treatments, actual complaints, *i.e.* blood loss, prolapse, pain, defecation difficulties, discomfort in daily life and actual patients' satisfaction were sent to the patients after a mean of 12.4 months and 29.2 months after the procedure.

Results

The ligation procedure was the first treatment for hemorrhoids for 32% of the patients; for 68% of the patients the procedure was used as an adjunct to previous treatment or as primary treatment followed later on by subsequent treatment during the follow-up of 29.2 months. At the end of the follow-up 42% of the patients were completely or highly satisfied with the results, blood loss was still present in 32.3% of the patients and prolapse complaints in 73.8% of the patients.

Conclusions

The ligation procedure could be a useful method to attain symptom relief of hemorrhoidal disease. Only a minority of the patients benefit from this procedure as being a curing intervention.

2

Inventory of hemorrhoidal status in patients previously treated with the hemorrhoidal artery ligation therapy

Introduction

For the past 15 years the hemorrhoidal artery ligation has found its basis in the treatment of hemorrhoidal disease. This technique is also referred to as Doppler-guided hemorrhoidal artery ligation (DG-HAL or HAL) or trans-anal hemorrhoidal dearterialisation (THD). This treatment modality aims to reduce the blood flow to the plexus hemorrhoidalis located in the distal rectum in order to establish a shrinkage of the corpus cavernosum recti with subsequent relief of the symptoms of hemorrhoidal disease. Reduction of the blood flow is established by ligation of the supplying arteries that are located by a Doppler-echo transducer built into the proctoscope.

In recent literature the outcome of this technique appears to be satisfactory, with reported success rates ranging from 49% up to 96%.[1-4] However, it is not very clear how the effect of the HAL will evolve in time and whether the measured success parameters could be sustained in time. Therefore, we inventoried the hemorrhoidal status over a short term and long term of patients who had previously undergone HAL for the treatment of grades II and III hemorrhoidal disease.

Material and methods

Patients

A prospective cross-sectional study was conducted in two large teaching hospitals in the Netherlands: Diakonessen Hospital [DH] in Utrecht and the St. Antonius Hospital [SAH] in Nieuwegein, with a capacity of 584 and 627 beds, respectively. Patients with symptomatic hemorrhoidal disease grade II and grade III according to the Goligher classification and who were treated by HAL in the period 2005 – 2008 were enrolled in the study, resulting in a total of 103 patients.[5] Written informed consent was obtained from all patients. The protocol was reviewed and approved by the medical

Table 1. Baseline characteristics of the enrolled patients

Number of patients		103
Male		56
Female		47
Age, mean (range)		51.1 (23 - 84)
Timing of questionnaire;	*Q1*	12.4 (2 - 22; sd 5.7)
months after surgery (range)	*Q2*	29.2 (16 - 39; sd 6.9)
Hemorrhoidal grade (%)	*II*	33 (32%)
	III	70 (68%)

ethics committee of the SAH. The baseline characteristics of the patient groups of both hospitals did not differ significantly. The group consisted of 47 female and 56 male patients (age 23 to 84 years; mean age 51.1 years) (Table 1).

Surgery

In both hospitals the ligation procedure was performed in an operating room under general or spinal anesthesia in lithotomy position (as with the conventional hemorrhoidectomy). In both hospitals the procedure was performed by or under supervision of surgeons who had attended ligation procedure training during a congress in the SAH. The specially designed proctoscope was inserted in the rectum in a way that allowed the Doppler device to be situated 2 to 3 cm above the dentate line. During rotation of the scope the pulsations of the efferent arteries could be located by an audible signal of the Doppler transducer. After completion of the proximal examination a more distal examination followed, *i.e.* 1.0 to 2.0 cm above the dentate line. When an artery was located, a figure-of-eight ligation was placed. The ligations were performed with an absorbable, synthetic braided suture (Darvin, Ergomed Sutramed, 2/0 vicryl, 5/8 circumference).

Follow-up

All patients treated by HAL were asked to fill in a standardized postal questionnaire (Q1) 12.4 months (mean) after the procedure. Approximately one year after Q1 the same questionnaire (Q2) was sent to the patients (29.2 months (mean) after the initial HAL). The questionnaires contained questions about blood loss, pain, prolapse, discomfort in daily life and difficulties with defecation. Every item could be scored on a 5-point Likert

scale: 1; very severe complaints, 2; severe complaints, 3; moderate complaints, 4; mild complaints (almost entirely complaint free), 5; no complaints. The Likert scale is a psychometric scale and can be used to provide an ordinal measure for difficult quantifiable data such as subjective complaint experience.[6] Six patients were also asked whether they were satisfied with the results of the procedure, whether they would have the procedure again if their symptoms returned and if they wished to receive subsequent treatment at the time of the questionnaires. Non-responders were contacted by telephone.

At the moment of the second questionnaire (Q2) we also evaluated at what moment in time HAL was used to manage the complaints of the hemorrhoidal disease. As a result the patients could be divided into four groups. In the first group patients had only undergone HAL as treatment of their hemorrhoidal disease. The second group consisted of patients that had undergone previous surgical treatment before HAL. In the third group patients had received additional surgical treatment after the HAL procedure. The fourth group consisted of patients that had received previous surgical treatment before and were in need of subsequent surgical treatment after HAL.

Statistical analysis

Response to the treatment per group was analyzed by means of the independent samples Kruskal-Wallis test. P values < 0.05 were considered statistically significant. Statistical analysis was performed using SPSS 18.0 for Windows (SPSS, Inc., Chicago, IL).

Results

For all patients the procedure was performed in same day surgery except for three patients (3%) who stayed one night for post-operative pain management.

Table 2. Inventory of the success of HAL at Q1 and Q2

	Q1	Q2
Completely satisfied with the results (5 points on Likert scale); (%)	13%	18%
Highly satisfied with the results (4 points on Likert scale); (%)	29%	24%
Completely complaint free; (%)	8%	22%
Nearly complaint free; (%)	36%	35%
Would undergo same operation in case of recurrent disease; (%)	58%	65%
In need of subsequent treatment; (%)	n.a.	50%

n.a. = not available

Table 3. Patients' self reported clinical parameters at Q1 and Q2

Symptoms		none	mild	severe
blood loss	Q1	69.2%	27.6%	3.3%
	Q2	67.7%	26.8%	5.5%
prolapse	Q1	19.2%	65.0%	15.9%
	Q2	26.3%	55.6%	18.2%
pain	Q1	64.9%	30.4%	4.7%
	Q2	58.4%	35.2%	6.5%
discomfort in daily life	Q1	65.1%	32.2%	2.8%
	Q2	71.4%	23.2%	5.5%
defecation problems	Q1	30.3%	57.0%	12.7%
	Q2	35.5%	48.6%	16.0%

Table 4. Previous and subsequent treatment of the patients in relation to HAL

Overall	
group 1: only HAL	29 (32%)
group 2: previous treatment and HAL	35 (38%)
group 3: HAL and subsequent treatment	11 (12%)
group 4: previous treatment followed by HAL followed by subsequent treatment	16 (18%)
pre-operative period	
without pre-operative intervention; n (%) (group 1 and 3)	40 (44%)
previous rubber band ligation; n (%) (group 2 and 4)	37 (41%)
mean time between RBL and HAL; years (sd)	4.4 (2.3)
previous hemorrhoidectomy; n (%) (group 2 and 4)	14 (15%)
mean time between hemorrhoidectomy and HAL; years (sd)	20.0 (7.8)
post-operative period	
without subsequent intervention after HAL; n (%) (group 1 and 2)	64 (70%)
subsequent rubber band ligation; n (%) (group 3 and 4)	14 (15%)
subsequent hemorrhoidectomy; n (%) (group 3 and 4)	11 (12%)
subsequent re-HAL; n (%) (group 3 and 4)	2 (2%)
mean time after HAL; years (sd)	1.6 (0.7)

Table 5. Complaint profile per group scored in Q2

	Group 1	**Group 2**	**Group 3**	**Group 4**	
	Only HAL	*Previous treatment and subsequent HAL*	*HAL and subsequent treatment*	*previous treatment, HAL and subsequent treatment*	*p-value* †
satisfaction rate* (sd)	3.14 (1.09)	3.47 (1.38)	2.83 (1.64)	2.53 (1.28)	0.093
blood loss* (sd)	4.69 (0.58)	4.55 (0.50)	4.85 (0.51)	4.37 (1.12)	0.938
pain* (sd)	4.57 (0.70)	4.39 (0.95)	4.62 (0.65)	3.89 (1.15)	0.240
prolapse* (sd)	3.92 (0.63)	3.64 (0.79)	3.85 (0.38)	3.50 (1.07)	0.713
defecation problems* (sd)	4.03 (0.94)	4.00 (1.13)	4.15 (0.99)	3.79 (1.34)	0.916
discomfort in daily life* (sd)	4.69 (0.94)	4.73 (1.06)	4.62 (0.90)	4.16 (1.22)	0.095
Completely satisfied; (%)	16%	22%	30%	7%	-
Completely complaint free; (%)	32%	31%	10%	21%	-
Nearly complaint free; (%)	31%	27%	60%	15%	-

** - 5-point Likert scale: 5 points resemble highest score, i.e. completely satisfied or no complaints*
† - Independent Samples Kruskal-Wallis test

Complications such as urinary retention, re-bleeding or anal stenosis did not occur. One patient developed a perianal abscess. In this cohort six patients (6%) were completely lost for follow-up; two patients to non-hemorrhoidal disease related death and four as the result of a move, resulting in 91 patients.

The first questionnaire (Q1) was sent to the patients after a mean period of 12.4 months (range 2 – 22; sd 5.7), the second questionnaire (Q2) after a mean period of 29.2 months (range 16 – 39; sd 6.9) after surgery. The results of Q1 and Q2 showed that 13% and 18% of the patients were completely satisfied with the results of HAL (score of 5 points on the Likert scale) (Table 2). 36 percent of the patients reported to be almost entirely complaint free (score of 4 points on the Likert scale) in Q1 which had not changed in Q2. Only 8% of the patients reported to be completely complaint free in Q1. This figure had increased to 22% in Q2. At the time of Q2, 50% of the patients thought that a new procedure for the anal complaints was indicated. At the time of Q1, 58% and at the time of Q2, 65% of the patients would choose HAL again if a subsequent procedure should prove to be necessary.

In Table 3, the occurrence of the various clinical complaints at the time of Q1 and Q2 is summarized. There was no significant improvement of the complaints between Q1 and Q2. It shows that anal prolapse is a persisting complaint which was still present in

73.8% of the patients at the end of the follow-up.

51 patients (56%) of all the patients included in the study had previously been treated for hemorrhoidal disease either by rubber band ligation or hemorrhoidectomy (group 2 and 4) (Table 4). For 40 patients (44%) HAL was the initial treatment for their hemorrhoidal disease (group 1 and 3). During the follow-up of 29.2 months 29% of the patients underwent additional treatment, on average 1.6 years (sd 0.7) after HAL, in order to relieve the complaints of the hemorrhoidal disease.

Table 5 provides an overview of the degree of complaints and satisfaction rates in each group at the moment of Q2 which did not differ significantly between the four groups. It shows that patients who had undergone subsequent treatment after HAL suffered least from remaining symptoms with a 70% 'completely' and 'nearly complaint free' rate. In this group also the highest 'completely satisfaction' rate was measured (30%). Patients who were more frequently treated for hemorrhoidal disease (group 4) were least satisfied and suffered most from remaining symptoms.

Discussion

We performed a prospective study in a group of patients previously treated for hemorrhoidal disease by HAL with the aim to inventory the hemorrhoidal complaint profile of the patients at the mid long and long term. We evaluated the outcome at approximately 12 and 29 months (mean) after the procedure.

In analyzing data, the way in which success is measured or defined is important. The reported wide range of success rates could be due to various causes.[1-4] First, the reported outcome of the procedure could be based on different points of view, i.e. either from the doctor's (anatomical evaluation) or the patient's perspective (satisfaction rates or remaining complaints). Secondly, results of the procedure are reported from different points in time after the treatment, varying from 6 weeks, 6 months and ranging up to 5 years.[7] Thirdly, different definitions of success result in a wide range of success rates. Success is often defined as 'a reduction of the hemorrhoidal gradation', 'therapeutic successes', 'improvement of the complaints' or as 'recurrence rates'. These definitions often fail to take into account the patient's perspective of the actual status of the disease. Even when symptoms remain a patient can be satisfied with the outcome of the procedure. On the other hand, a patient can still be unsatisfied after significant

reduction of hemorrhoidal gradation after the procedure. One observation which was also made by Pol *et al.* and Wilkerson *et al.* We feel that the patient's satisfaction or complaint experience after treatment should be the reference for success of the procedure, independent of post-operative gradation of the hemorrhoidal disease.

In our study, we did not find significant differences in the measured satisfaction rates for the whole group in Q1 and Q2 (satisfaction rate of 42%) (Table 2). Pol *et al.* found a decrease of the satisfaction rates; he observed a decrease from 85% after 9 months to 69% after 18.4 months of follow-up.[8] Wilkerson *et al.* also found a decline in satisfaction rates from 74% to 40% after 30 months of follow-up.[1] Combining these data we postulate that the initial success rates (satisfaction rates and/or symptom reduction) of HAL could be high, but in the long term a decrease of success rate or recurrent disease is to be expected.

In line with other reports we also found that the effects of HAL on prolapse complaints seem to be less favorable than for the other scored complaints.[1, 9] Symptoms of prolapse was the most frequently reported symptom during the follow-up, 55.6% of the patients still experienced mild symptoms and 18.2% experienced severe prolapse complaints.

Our study provided insight into how HAL is used in the management of hemorrhoidal disease. It revealed that 70% of the patients were not in need of additional treatment after the ligation procedure. On the other hand, despite HAL, and in some cases additional treatments, only a very small portion of the patients could report to be completely free of complaints (22%) at the end of the follow-up. Nevertheless, after a follow-up of 29 months 42% of the patients revealed to be highly or completely satisfied with the outcome. Wilkerson *et al.* who also evaluated satisfaction rates on a 5-point scale in patients treated with HAL for grade II and III hemorrhoidal disease, reported that 57% of the participating patients were completely satisfied after a follow-up of 30 months.[1] Changing the definition from 'completely satisfied' to the less stringent 'almost satisfied', Wilkerson *et al.* report a satisfaction rate of 90%. With this less stringent definition Narro *et al.* also reported a high satisfaction rate of 84.3%.[7] Considering these numbers we concluded that they are in contrast with our findings, something for which we were not able to find a clear explanation.

Despite the fact that we used a non-validated scoring system to assess patients'

satisfaction, we feel that we have been able to inventory the patients' perception of the outcome of HAL treatment as well as its acceptability. A weakness of this study is that there is no pre-test data on primary symptoms available, which would have provided a more detailed scheme of the development of the complaints after HAL.

We conclude that HAL is a safe procedure with a low complication rate as was also concluded by Bursics *et al.*[10] Considering the small portion of patients whose symptoms of hemorrhoidal disease were completely resolved it is questionable whether this procedure fulfills the requirements of a curing intervention; however, based on the satisfaction rates this procedure could (partially) reduce signs and symptoms of hemorrhoidal disease from a patient's perspective.

Acknowledgement

The authors thank Hugo Rijken for help in collecting the data and Bert Bos for help in the preparation of the manuscript.

References

1. Wilkerson PM, Strbac M, Reece-Smith H, Middleton SB. Doppler-guided haemorrhoidal artery ligation: Long-term outcome and patient satisfaction. *Colorectal Dis* 2009; **11:** 394-400.
2. Felice G, Privitera A, Ellul E, Klaumann M. Doppler-guided hemorrhoidal artery ligation: An alternative to hemorrhoidectomy. *Dis Colon Rectum* 2005; **48:** 2090-2093.
3. Scheyer M, Antonietti E, Rollinger G, Mall H, Arnold S. Doppler-guided hemorrhoidal artery ligation. *Am J Surg* 2006; **19:** 89-93.
4. Arnold S, Antonietti E, Rollinger G, Scheyer M. Doppler ultrasound assisted hemorrhoid artery ligation. A new therapy in symptomatic hemorrhoids. *Chirurg* 2002; **73:** 269-273.
5. Goligher JC (1980 4th edition). Haemorrhoids or piles. In *Surgery of the Anus Rectum and Colon*, pp 93–135. Baillere Tindall, London.
6. R. Likert (1932) A technique for the measurement of attitudes. In: *Archives of psychology*, **no. 140** 1932:1-55.
7. Narro JL. Hemorrhoid therapy with doppler guided hemorrhoidal artery ligation via proctoscope KM-25. A new alternative to hemorrhoidectomy and rubber band ligation? *Zentralbl Chir* 2004; **129:** 208-210.
8. Pol RA, van der Zwet WC, Hoornenborg D, Makkinga B, Kaijser M, Eeftinck Schattenkerk M, *et al.* Results of 244 consecutive patients with hemorrhoids treated with doppler-guided hemorrhoidal artery ligation. *Dig Surg* 2010; **27:** 279-84.
9. Morinaga K, Hasuda K, Ikeda T. A novel therapy for internal hemorrhoids: Ligation of the hemorrhoidal artery with a newly devised instrument (moricorn) in conjunction with a doppler flowmeter. *Am J Gastroenterol* 1995; **90:** 610-3.
10. Bursics A, Morvay K, Kupcsulik P, Flautner L. Comparison of early and 1-year follow-up results of conventional hemorrhoidectomy and hemorrhoid artery ligation: A randomized study. *Int J Colorectal Dis* 2004; **19:** 176-180.

3

Anatomical branches of the superior rectal artery in the distal rectum

J. P. Schuurman, P. M. N. Y. H. Go and R. L. A. W. Bleys

Colorectal Dis 2009; **11:** 967-71

The definitive version is available at www3.interscience.wiley.com

ABSTRACT

Objective

The aim of this experimental study was to study the arterial supply of the corpus cavernosum recti in the inner wall of the distal rectum in relation to hemorrhoidal ligation therapy.

Method

In 10 non-fixed human cadavers, the arterial vasculature of the rectum was studied using the Araldite casting method. Subsequently, the specimens were treated with methylbenzoate in order to obtain semitransparent specimens in which the corpus cavernosum recti could be studied.

Results

Specimens were obtained permitting study of the arterial vasculature of the rectum and corpus cavernosum recti at all levels. The superior rectal artery was found to supply the corpus cavernosum recti which consisted of a variable number of equally spaced twisting arteries.

Conclusion

The distal rectum is supplied by the superior rectal artery. The supplying arteries of the corpus cavernosum recti are not confined to the strict locations described in the literature. This finding is of importance in surgical treatment of hemorrhoidal disease.

3

Anatomical branches of the superior rectal artery in the distal rectum

Introduction

The prevalence of hemorrhoidal disease ranges from 4% to 86% of the population, with a male : female ratio of 1:4.[1-3] Hemorrhoidal tissue forms part of the anal continence mechanism in the anal canal and distal rectum. When non-symptomatic it is referred to by the term 'anal cushions' which consist of vascular tissue in a stroma of connective tissue and smooth muscle fibers within the anal canal. The anal cushions fulfill four main functions.[4] By their approximation they contribute to anal canal closure and thus continence; they provide 15–20% of resting anal pressure; they protect the sphincter mechanism during evacuation and they form a compressible lining, facilitating closure of the anal canal. The smooth muscle acts as a supportive structure forming a fibro-elastic network within the cushion plexus.[2] This structure was named by Stelzner *et al.* as the corpus cavernosum recti also known as plexus hemorrhoidalis and is supplied by a complex structure of blood vessels.[5]

As the arterial blood flow in the internal hemorrhoidal plexus is thought to be associated with the pathogenesis of hemorrhoids, newer techniques have aimed to reduce the vascularity of the hemorrhoidal tissue. One such technique is hemorrhoidal artery ligation (HAL) or transanal hemorrhoidal dearterialization (THD). The technique is based on Doppler identification and suture ligation of the submucosal terminal branches of the superior rectal artery in the corpus cavernosum recti. A special designed proctoscope with a fixed ligation window prevents sutures to be placed deeper than in the submucosal layer.

Several anatomical studies have concluded that the corpus cavernosum recti is exclusively fed by the superior rectal artery. A detailed account of the vasculature in the external rectal muscular wall layers was recently described by Aigner *et al.*, but the vascular anatomy of the internal lining of the distal rectum has not been studied.[6] We investigated the anatomy in cadavers of the corpus cavernosum recti in the inner wall of the distal rectum and its relationship to the superior rectal artery.

Method

Specimens

Ten non-fixed human cadavers (seven male, three female; age range 60–87 years, mean age 75) were studied. The arteries of the rectum and the vascular territory of the superior rectal artery were injected with Araldite introduced into the superior rectal and the internal iliac arteries. The abdomen was opened and the inferior mesenteric artery was carefully dissected along its course to its division into the superior rectal arteries. A superior rectal artery was then cannulated and connected to a pump to inject the Araldite after clamping the external iliac arteries and the aorta to prevent leakage of Araldite into nonrelevant areas.

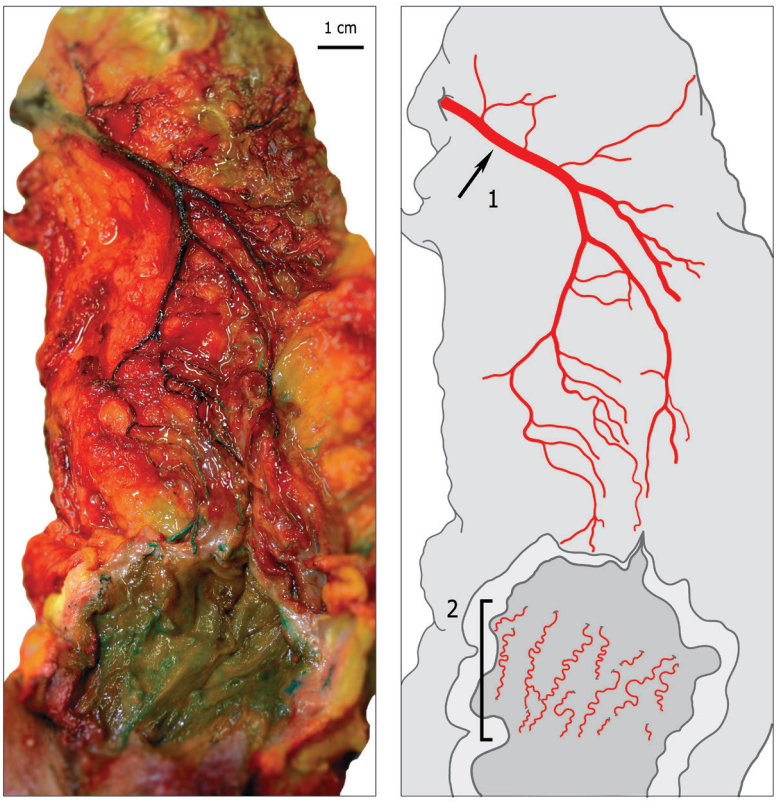

Figure 1. Posterior view of a non-fixed specimen in which the connective tissue and fat have been removed for better visualization of the vessel casts. (1; superior rectal artery) (2; opened anal canal providing a view on the corpus cavernosum recti).

Araldite casting

After preparation the vessels were filled with Araldite delivered by a pump, after connecting the Araldite reservoir with an electrical membrane valve pump with a needle valve for pressure control. The Araldite mixture consisted of Araldite DY G26SP, dilutant DY 026SP, hardener HY 2967 (Ciba Geigy, Basel, Switzerland) and differently colored Mircolith-T pigments. Its temperature was maintained at approximately 10°C to avoid premature hardening. Each artery was filled with a different colored mixture as follows: superior rectal artery: green, left internal iliac artery: blue, right internal iliac artery: red. These arteries were simultaneously filled at a pressure of 160 mmHg, with each artery filled with a maximum of 40 cc Araldite. This volume was sufficient to fill the vessels adequately. After casting, the Araldite was allowed to set for at least 20 h.

Dissection

In eight specimens, the anorectum was carefully dissected for macroscopic examination. The specimen was removed from the pelvis and the connective tissue and fat were carefully removed for better visualization of the vessels (Figure 1). The

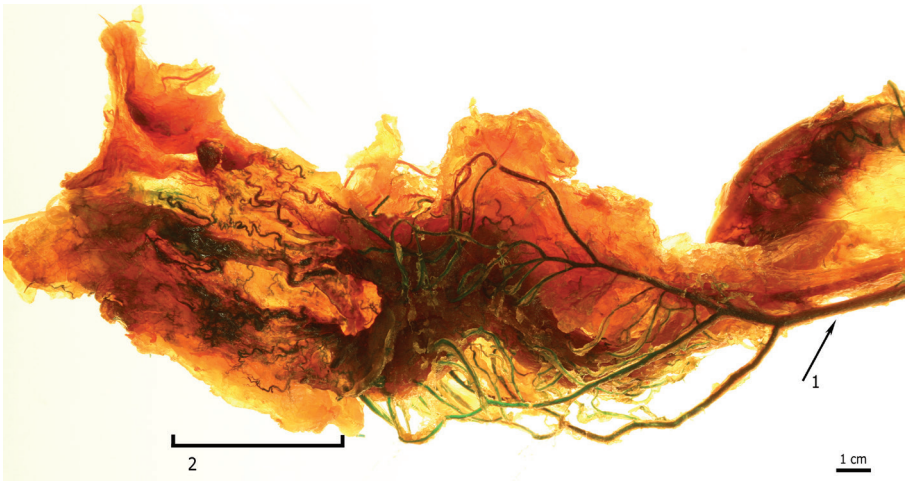

Figure 2. Araldite cast in a semitransparent specimen of the distal rectum showing the superior rectal artery (1) and opened anal canal providing a view on the corpus cavernosum recti (2).

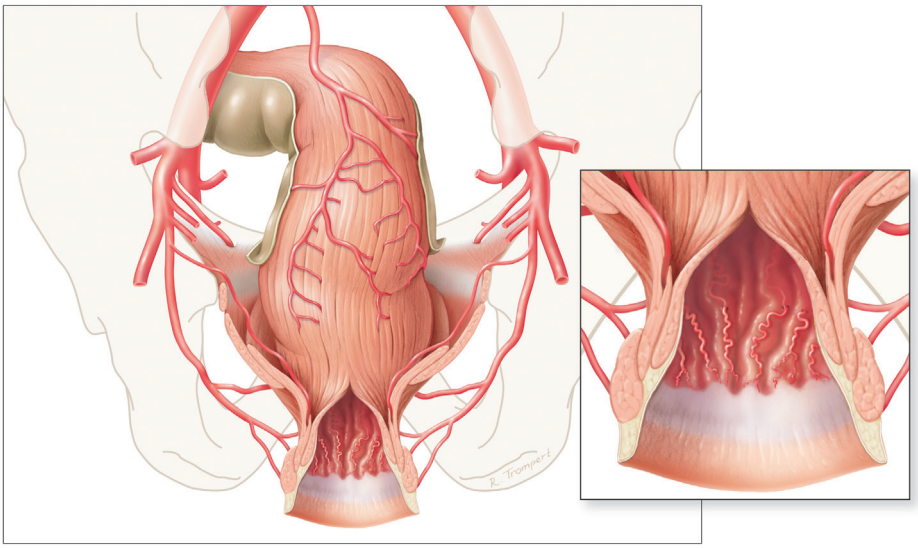

Figure 3. Posterior view on the rectum showing the course of the superior rectal artery with a detailed picture of the corpus cavernosum recti.

casted perirectal vessels were carefully dissected and the rectum was then opened longitudinally to study its internal lining.

Serial sectioning

The two remaining specimens were cut in serial sections to a thickness of 25 and 50 µm in a cryomicrotome (Model 450 MP, PMV, Stockholm, Sweden) after embedding in carboxymethylcellulose (CMC). After each section the surface of the tissue block was digitally imaged and processed for computerized reconstruction.

Tissue clearing

The eight specimens were subsequently placed in a series of alcohol solutions of increasing concentration (70%, 80%, 96% and 100%) to dehydrate the surrounding tissue and were then finally placed in methylbenzoate 98% to obtain semitransparent specimens to allow study of the casted vessels.

Results

Araldite casting

Araldite casting in combination with tissue clearing provided three-dimensional preparations that were semitransparent as methylbenzoate has a refractory index which approximates to that of the tissue. In the cleared specimens, the vascular system could be studied in detail throughout all levels of the bowel wall. Figure 2 shows an Araldite cast in a semitransparent specimen of the distal rectum. For optimal visualization, specimens were transluminated. The green-coloured Araldite in the SRA contrasted clearly with the surrounding tissue.

Spatial relations

Vessels were identified down to a diameter of 0.2 mm. The superior rectal artery followed the posterior aspect of the sigmoid colon and bifurcated about 12 cm (range 10–14 cm) above the dentate (pectinate) line (Figure 3). The artery divided in three to five large branches. Each branch partially spiralled around the central axis of the rectum and subsequently separated into five to seven branches penetrating the bowel

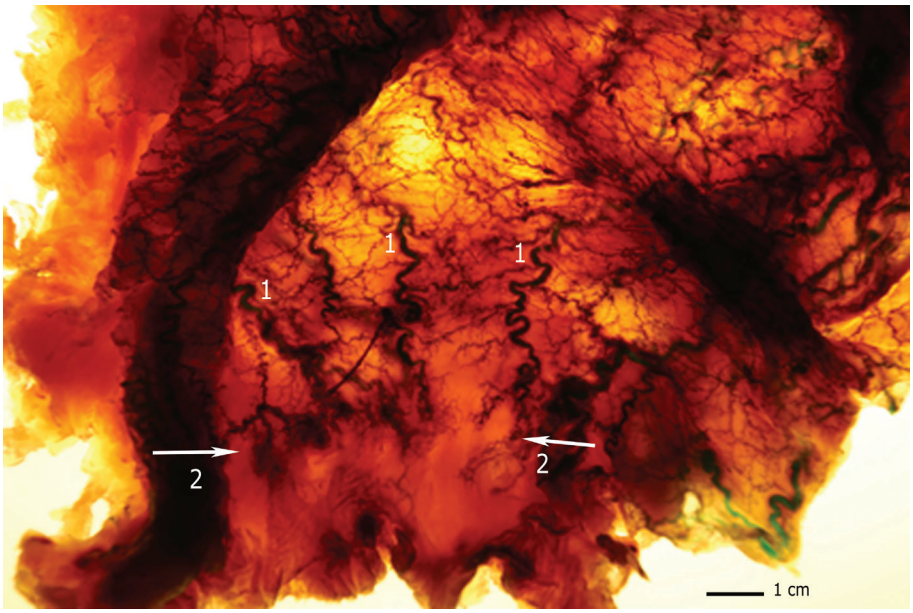

Figure 4. Green casted vessels (1) emerging at the surface of the internal lining of the rectum continuing to the dentate line (2, between arrows).

wall. No anastomosis greater than 0.2 mm between the branches was seen. The most distal branch of the superior rectal artery entered the bowel wall approximately 4 cm above the dentate line. This pattern showed little variation and most differences were observed in the branching pattern of the main stem of the superior rectal artery.

Internal lining of the rectum

About 2–3 cm above the dentate line, twisting arteries containing green Araldite with a maximum diameter of 2 mm were seen to emerge towards the mucosal surface (Figure 4). These continued in the submucosa down to the dentate line where they diverged into

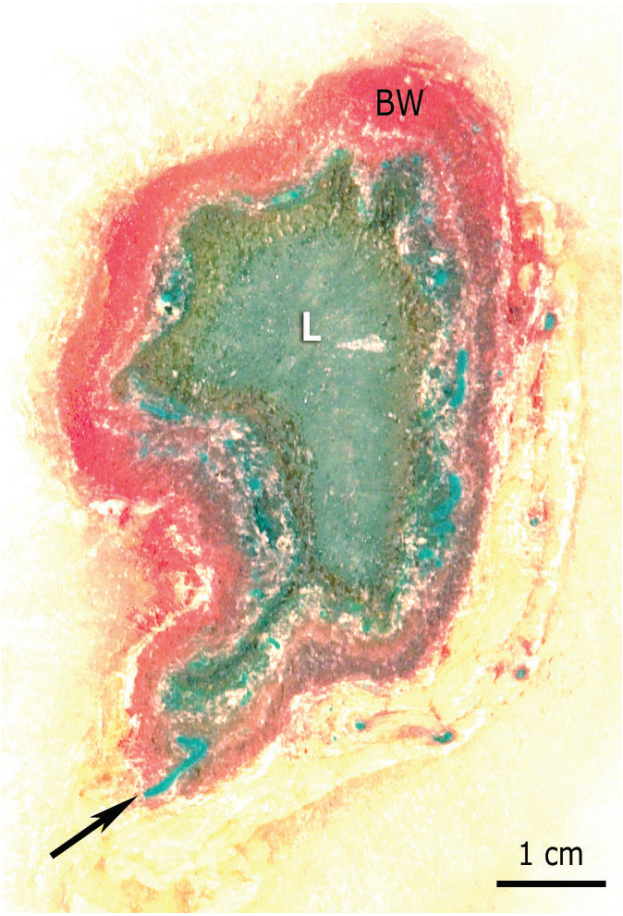

Figure 5. Still frame of the reconstruction video showing a cross sectional cut with a vessel (arrow) penetrating through the bowel wall (BW). Lumen (L).

smaller branches to form, to some degree, a plexus in the corpus cavernosum recti area. On average about eight arteries were seen in the distal rectum, all originating in the superior rectal artery (Figures 3 and 4). These vessels were circumferentially arranged with more or less equal distances between them. Only green Araldite was seen in the corpus cavernosum recti. A small area at the level of the corpus cavernosum recti in the outer lining of the rectum showed vessels colored with Araldite other than green. The area distal to the dentate line (pecten and skin) showed small branches colored blue or red originating from the internal iliac arteries. These had their origin in the internal pudendal arteries which branch from the internal iliac arteries and were considered to be the inferior rectal arteries. In six specimens, this inferior rectal artery was found either bilaterally or unilaterally. In none of the specimens could the middle rectal artery be identified.

Serial sectioning

The slice thickness of 25–50 μm enabled a high-resolution reconstruction. This showed a plexiform network (green) of supplying arteries in the rectum wall. Figure 5 is a still frame of the reconstruction video and shows a cross section with a vessel penetrating through the bowel wall.

Discussion

Our findings showed a detailed picture of the course of the superior rectal artery in the distal rectum to the anal verge. The alcohol tissue clearing technique proved to be suitable for producing transparent tissue specimens allowing a new and detailed picture of the vessel structure at the inner lining of the distal rectum to be constructed. Although the study was performed with hemorrhoid ligation therapy in mind, it should be emphasized that none of the specimens were obtained from individuals known to have hemorrhoids. The anatomical changes in hemorrhoids were therefore beyond the scope of the study.

In our specimens, we only found green colored Araldite from the superior rectal artery in the corpus cavernosum recti region, indicating that the corpus cavernosum recti is solely supplied from the superior rectal artery as was found by Aigner *et al.*[6] These vessels are of great importance especially in terms of oncological rectal

resections, where those collateral arterial vessels originating from the inferior rectal artery are crucial for sufficient blood supply of the rectal stump.[7] The suggestion by Bursics *et al.* that other vessels could penetrate the wall of the distal rectum and supply the corpus cavernosum recti can not be confirmed in our study.[8]

There is no consensus regarding the presence of the middle rectal arteries with varying conclusions from different studies. Jones *et al.* found a huge variation in the published data on the incidence of the middle rectal artery.[9] This may have been due to differences in the definition of the middle rectal artery and the anatomical methods used to trace them. In all these dissection studies the possibility that the middle rectal artery accidentally removed cannot be ruled out. In our noninvasive study in which the casted vessels were all easily seen, we found few red and blue colored branches in the outer layers of the rectum, below the level of the levator ani muscle. We assumed this to be the inferior rectal artery supplying the outer layers of the muscular wall in the area up to about 3 cm above the dentate line. We did not consider that these vessels were branches of the middle rectal artery as this artery is reported to supply the rectum above the levator ani muscle. We were unable to find any casted vessel that might be part of the middle rectal artery in any of the cadavers, although this possibility cannot be completely excluded. As Araldite is generally considered to be a suitable agent for visualization of the small-sized vessels, we would have expected it to show the middle rectal artery if that were present.[10, 11]

It has been suggested in the past that the arteries in the distal rectal submucosa are arranged in the classic 3, 7 and 11 o'clock positions. Others have indicated a more complicated picture of 1, 3, 5, 7, 8 and 11 o'clock.1,[12–14] In this study, distribution patterns appeared to differ from these configurations since the course of the submucosa vessels and their length, diameter and number indicated that the arrangement is not constant. It is therefore questionable whether these typically positions are useful in clinical practice.

Hemorrhoid artery ligation therapy (HAL) is minimally invasive and produces little pain.[7, 12, 14] Its aim is to reduce the blood flow to the hemorrhoid plexus by identifying the arterial branches by ultrasound Doppler probe and ligating them individually. In the light of this study, it is likely that not all arteries are found and ligated despite good results being reported. This calls into question the precision of ultrasound Doppler

identification. Besides artery ligation it may be that HAL also produces an anopexy effect caused by the placement of the sutures.

Conclusion

The distal rectum is supplied by the superior rectal artery. The arteries supplying the corpus cavernosum recti are not necessarily found in the locations stated in the literature.

Acknowledgements

We wish to acknowledge Willem van Wolferen (prosector) and Simon Plomp (prosector) both of the University Medical Centre, Utrecht, The Netherlands for their expert technical assistance. We also wish to acknowledge Rogier Trompert of Medical Art, Maastricht, The Netherlands for providing the anatomical illustrations.

References

1. Felice G, Privitera A, Ellul E, Klaumann M. Doppler-guided hemorrhoidal artery ligation: an alternative to hemorrhoidectomy. *Dis Colon Rectum* 2005; **48:** 2090–3.
2. Dal Monte PP, Tagariello C, Sarago M, Giordano P, Shafi A, Cudazzo E, Franzini M. Transanal haemorrhoidal dearterialisation: nonexcisional surgery for the treatment of haemorrhoidal disease. *Tech Coloproctol* 2007; **11:** 333–8.
3. Wallis de Vries BM, van der Beek ES, de Wijkerslooth LR, van der Zwet WC, van der Hoeven JA, Eeftinck Schattenkerk M, Eddes EH. Treatment of grade 2 and 3 hemorrhoids with Doppler-guided hemorrhoidal artery ligation. *Dig Surg* 2007; **24:** 436–40.
4. Wexner SD, Baig K. The evaluation and physiologic assessment of hemorrhoidal disease: a review. *Tech Coloproctol* 2001; **5:** 165–8.
5. Stelzner F, Staubesand J, Machleidt H. Das corpus carvernosum recti - die Grundlage der inneren Hämmorrhoiden. *Langenbecks Arch klein Chir* 1962; **299:** 302–12.
6. Aigner F, Bodner G, Conrad F, Mbaka G, Kreczy A, Fritsch H. The superior rectal artery and its branching pattern with regard to its clinical influence on ligation techniques for internal hemorrhoids. *Am J Surg* 2004; **187:** 102–8.
7. Nano M, Marchisio F, Ferronato M, Breatta AD, Solej M, Barbero S, Dei Poli M, Gandini G. Vascular anatomy of the rectal stump after total mesorectal excision. *Dis Colon Rectum* 2006; **49:** 1897–904.
8. Bursics A, Morvay K, Kupcsulik P, Flautner L. Comparison of early and 1-year follow-up results of conventional hemorrhoidectomy and hemorrhoid artery ligation: a randomized study. *Int J Colorectal Dis* 2004; **19:** 176–80.
9. Jones OM, Smeulders N, Wiseman O, Miller R. Lateral ligaments of the rectum: an anatomical study. *Br J Surg* 1999; **86:** 487–9.
10. Van der Zwan A, Hillen B. Araldite F as injection material for quantitative morphology of cerebral vascularization. *Anat Rec* 1990; **288:** 230–6. (Chapter III)
11. Funk R. Studies on the functional morphology of rat ocular vessels with scanning electron microscopy. *Acta Anat* 1986; **125:** 252–7.
12. Scheyer M, Antonietti E, Rollinger G, Mall H, Arnold S. Doppler-guided hemorrhoidal artery ligation. *Am J Surg* 2006; **191:** 89–93.
13. Greenberg R, Karin E, Avital S, Skornick Y, Werbin N. First 100 cases with Doppler-guided hemorrhoidal artery ligation. *Dis Colon Rectum* 2006; **49:** 485–9.
14 . Sohn N, Aronoff JS, Cohen FS, Weinstein MA. Transanal hemorrhoidal dearterialization is an alternative to operative hemorrhoidectomy. *Am J Surg* 2001; **182:** 515–9.

4

Hemorrhoidal artery ligation with or without Doppler transducer in grade II and III hemorrhoidal disease. A blinded randomized clinical trial.

J.P. Schuurman, I. H. M. Borel Rinkes, P. M. N. Y. H. Go

Ann Surg 2012; **255:** 840-5

ABSTRACT

Objective

The aim of this study was to compare the outcome of the hemorrhoidal artery ligation procedure for hemorrhoidal disease with and without use of the provided Doppler transducer.

Background

Hemorrhoidal artery ligation, known as HAL (hemorrhoidal artery ligation) or THD (transanal hemorrhoidal dearterialization) procedure, is a common treatment modality for hemorrhoidal disease in which a Doppler transducer is used to locate the supplying arteries that are subsequently ligated. It has been suggested that the use of the Doppler transducer does not contribute to the beneficial effect of these ligation procedures.

Methods

The authors conducted a single-blinded randomized clinical trial and assigned a total of 82 patients with grade II and III hemorrhoidal disease to undergo either HAL without use of the Doppler transducer (non-Doppler group, 40 patients) or a conventional HAL (Doppler group, 42 patients). Primary endpoint was improvement of self-reported clinical parameters after both 6 weeks and 6 months. This study is registered at trialregister.nl and carries the ID number: NTR2139.

Results

After 6 weeks and 6 months in both the non-Doppler and the Doppler group, significant improvement was observed with regard to blood loss, pain, prolapse, and problems with defecation ($P < 0.05$). The improvement of symptoms between both groups did not differ significantly ($P > 0.05$), except for prolapse, which improved more in the non-Doppler group ($P = 0.047$). There were more complications and unscheduled postoperative events in the Doppler group ($P < 0.0005$). After 6 months, 31% of the patients in the non-Doppler group and 21% in the Doppler group reported completely complaint free ($P = 0.313$).

Conclusions

The authors' findings confirm that the hemorrhoidal artery ligation procedure significantly reduces signs and symptoms of hemorrhoidal disease. The authors' data also show that the Doppler transducer does not contribute to this beneficial effect.

4

Hemorrhoidal artery ligation with or without Doppler transducer in grade II and III hemorrhoidal disease. A blinded randomized clinical trial.

Introduction

Hemorrhoidal disease is one of the most frequently occurring diseases of the distal rectum. Fifteen years ago, Morinaga *et al.* published the first results on the hemorrhoidal artery ligation procedure known as the HAL (hemorrhoidal artery ligation) or THD procedure (transanal hemorrhoidal dearterialization), which has become one of the standard surgical procedures in the treatment of grade II and III hemorrhoidal disease.[1] The procedure aims to localize the supplying arteries of the corpus cavernosum recti in the distal rectum using a Doppler transducer and subsequently ligate these arteries through a specially designed proctoscope resulting in shrinkage of the pathological tissue and subsequent symptom relief.

Clinical experience has revealed that it can be difficult to silence all Doppler signals during the procedure, even after application of multiple ligations.[2] Postoperative patients may nevertheless experience relief of their complaints. In the literature, it is assumed that on average 6 to 8 ligations would suffice to achieve complaint reduction, while in a recent anatomical study it was shown that the distal rectum is provided by more than 6 twisting arteries.[2–5] This discrepancy between peroperative experiences and clinical outcome and the insight into the anatomical configuration of the distal rectum raises the question in what way the proctoscope and Doppler transducer is intervening in the anatomical configuration and whether there might be another mechanism that could explain the beneficial effect of HAL. For these reasons, it is questionable whether the use of the Doppler transducer in HAL is essential for the beneficial clinical outcome of the treatment.

The aim of this single-blinded randomized clinical trial was to evaluate the contributory value of the Doppler transducer in HAL by comparing treatment outcome in 2 groups treated either with or without the use of Doppler transducer.

Methods

Patients

We conducted a single-center single-blinded randomized controlled trial (HEMARTY study) in which we compared the outcome of HAL performed with and without the provided Doppler transducer. All consecutive patients who aged 18 years or older and were referred to our surgical outpatient clinic by primary health care providers with suspected grade II or grade III hemorrhoidal disease were eligible for inclusion in the study. Patients were included after confirmation of the diagnosis grade II or III hemorrhoidal disease according to the Goligher classification by physical examination and/or proctoscopy followed by digital exploration, and after giving written informed consent. Six weeks after treatment, the patients underwent the same routine of clinical examination.

Exclusion criteria included pregnancy, Crohn's disease, previous major surgery to the rectum, and simultaneously presence of other anal disorders including abscesses and colorectal or anal carcinoma. Patients who already unsuccessfully had been treated by rubber band ligation were also included if the previous treatment was rendered at least 6 months prior.

Symptom Evaluation

A written questionnaire was completed before treatment, at 6 weeks and at 6 months after treatment. The questionnaire contained questions about the actual complaints of the hemorrhoidal disease, including blood loss, prolapse, pain, discomfort in daily life, and difficulties with defecation. Every item was scored on a 5-point Likert scale, which is a psychometric scale that can be used to provide an ordinal measure to difficult quantifiable data such as subjective complaint experience.[6] The 5 points involves the following: (1) heavy complaints, (2) severe complaints, (3) moderate complaints, (4) mild complaints, and (5) no complaints. The used questionnaire aims to assess the patients' views on the success of the treatment relative to the baseline condition, independent of the success from a medical point of view. At both 6 weeks and 6 months posttreatment, the patients were subsequently asked whether they were satisfied with the result of the procedure and if they would undergo the same procedure in case of recurrent disease. Pain, related to the procedure, was prospectively scored for 7 consecutive days after the procedure on a visual analogue scale (VAS score) ranging from 0 to 10.

Surgery

The HAL procedure was performed in the operating room under general anesthesia in lithotomy position. All patients were treated with use of the THD proctoscope (THD America, Inc, Tampa, FL). The ligations were performed with an absorbable, synthetic braided suture (Darvin, Ergomed Sutramed, 2/0 vicryl, 5/8 circumference). Patients in the non-Doppler group received the artery ligation procedure without the supplied Doppler transducer. For these patients, the ligations were placed in the area of visible pathologic hemorrhoidal tissue. Patients in the Doppler group received the standard artery ligation procedure with use of the Doppler transducer. Significant reduction or disappearance of the Doppler signal was considered confirmative of vessel occlusion. In both groups, a figure-of-eight ligation was applied with a maximum of 6 ligations. In both groups, no additional pexy procedures were performed. All procedures were performed by surgeons and residents under supervision of the same surgeon (P.G.).

Randomization and Allocation of Patients

The patients were assigned randomly to 1 of the 2 treatment groups. Randomization was done by an outpatient clinic employee using a closed-envelope method. The patient was blinded to the treatment rendered until fulfillment of the written questionnaire at 6 months follow-up. All medical documents and operative notes referred to the procedure as “HAL/THD-procedure” with the prefix “group 0” or “group 1” without specifying the actual surgical approach. The randomization code was known only by the surgeon (P.G.). The protocol was reviewed and approved by the medical ethics committee of the St. Antonius hospital. This study is registered at trialregister.nl and carries the following ID number: NTR2139.

Endpoints

The primary endpoint of the study was improvement of self-reported clinical parameters scored preoperatively and at both 6 weeks and 6 months after the procedure. Secondary endpoints included procedure-related pain, recovery time for regaining daily activities, treatment-induced complications, need for subsequent treatment, and patient’s satisfaction rates.

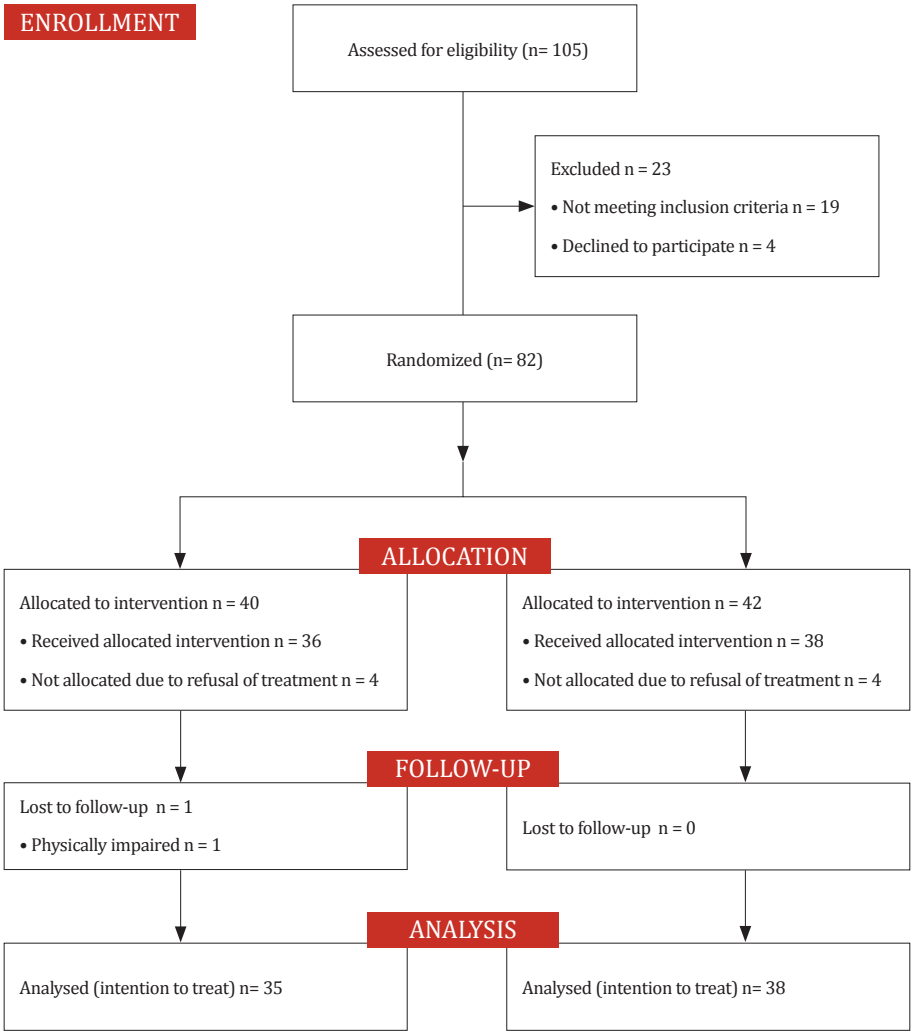

Figure 1. CONSORT flow diagram of the HEMARTY study.

Follow-Up

The follow-up was performed by the treating surgeon (P.G.). Persisting complaints were allowed to be treated according to the surgeon's discretion.

Sample Size and Statistical Analysis

A power calculation was made assuming a power of 80%, a type 1 error probability of 5%, and an allocation ratio of 1. On the basis of published data, we estimated conventional HAL to attain a 95% success rate. Subsequently, we assumed the healing rate of the procedure without Doppler transducer as effective as a rubber band ligation procedure (70%), because in this procedure there is also placement of ligatures in the surgeons' best opinion without Doppler control.[7] In an a priori Fisher exact sample size calculation, we determined that 39 patients in each arm would provide the necessary power to calculate this difference.

Patients were analyzed according to the intention-to-treat principle. Baseline characteristics were compared by means of the t-test and $\chi 2$ test. The data of the questionnaires were analyzed by means of 1-way repeated measures ANOVA (analysis of variance) and paired t-test. Comparison of the VAS scores obtained on each postoperative day was performed by means of the 1-way repeated-measures ANOVA. $P < 0.05$ was considered statistically significant. Statistical analysis was performed using SPSS 18.0 for Windows (SPSS, Inc, Chicago, IL).

Results

Between January 2008 and March 2010, 105 consecutive patients were candidates for the study: 23 patients were ineligible before randomization—4 declined to take part, 19 were not randomized for other reasons. Patients were randomly assigned to the non-Doppler group or to the Doppler group (Figure 1). In the non-Doppler group, 4 patients did not receive allocated treatment because of refusal of treatment and 1 patient was lost to follow-up. In the Doppler group, 4 patients did not receive allocated treatment because of refusal of treatment. Eventually, 35 patients in the non-Doppler group and 38 patients in the Doppler group could be analyzed. The characteristics of the 73 patients included in the analysis were similar in the 2 groups before treatment; except for the complaint of blood loss that was more severe in the Doppler group (Table 1).

Table 1. Baseline characteristics

	non-Doppler n = 35	Doppler n = 38	p value
Age, years (sd)	51 (13.7)	50 (13.0)	0.988
Sex ratio (M:F)	24 : 10	22 : 14	0.560
Grade II; n (%)	12 (34%)	7 (18%)	0.122
Grade II/III; n (%)	14 (40%)	19 (50%)	0.391
Grade III; n (%)	9 (26%)	12 (32%)	0.583
Duration symptoms, years (sd)	13.3 (13.6)	11.3 (11.0)	0.126
Complaints before treatment	**mean value Likert scale***	**mean value Likert scale***	
blood loss (sd)	3.37 (1.14)	2.77 (1.43)	0.004
pain (sd)	3.32 (1.17)	3.32 (1.21)	0.942
prolapse (sd)	2.82 (1.07)	2.64 (1.02)	0.320
defecation problems (sd)	2.96 (1.10)	2.73 (1.19)	0.403
discomfort in daily life (sd)	4.00 (1.20)	4.18 (1.05)	0.493

** 5-point Likert scale: 5 points resemble no complaints*

The number of ligations in both groups did not differ significantly. In the non-Doppler group a mean of 5.1 ligations (sd = 0.75) were placed and in the Doppler group a mean of 5.2 ligations (sd = 0.71) were placed (P = 0.75).

Self-Reported Clinical Parameters

Pain experienced over the first week after surgery scored a mean (sd) of 4.5 (1.0) on a VAS scale of 0 to 10 for the non-Doppler group and a mean (sd) of 3.9 (1.0) for the Doppler group. The course of postprocedural pain experience did not differ significantly in both groups (P = 0.682) (Figure 2). In the non-Doppler group it took 9.8 days before patients returned to work or their daily activities and 7.7 days in the Doppler group (P = 0.194).

In both the non-Doppler and the Doppler group, a significant improvement in symptoms was observed with regard to blood loss, pain, prolapse, and problems with defecation. The amount of discomfort in daily life was significantly reduced in both groups too (Table 2). Repeated measures test between groups showed that the improvement of self-reported clinical parameters between both groups did not differ significantly, except for the prolapse complaints, which improved more in the non-Doppler group (P = 0.047, Table 2).

Table 2. Mean Likert scale values in both groups

	non-Doppler group				Doppler group				
	Likert score (mean) *	none	mild	severe	Likert score (mean) *	none	mild	severe	**p-value ‡**
blood loss									
before treatment	3.37	23.5%	61.8%	14.7%	2.77	8.3%	58.4%	33.4%	
6 weeks post treatment	4.50	43.8%	50%	6.3%	4.05	36.8%	63.2%	0%	
6 months post treatment	4.86	87.0%	13.0%	0%	4.45	62.5%	33.3%	4.2%	0.221 §
p-value †	< 0.0005				< 0.0005				
pain									
before treatment	3.32	14.7%	61.8%	23.5%	3.32	13.9%	61.1%	25%	
6 weeks post treatment	3.95	31.3%	50%	18.8%	3.73	31.6%	52.6%	15.8%	
6 months post treatment	4.64	73.9%	26.1%	0%	4.63	66.7%	33.3%	0%	0.702
p-value †	< 0.0005				< 0.0005				
prolapse									
before treatment	2.82	8.8%	55.9%	33.3%	2.64	2.8%	44.5%	52.8%	
6 weeks post treatment	4.05	25%	68.8%	6.3%	3.68	21.1%	63.2	15.8%	
6 months post treatment	4.59	65.2%	34.8%	0%	3.91	41.7%	45.9%	12.4%	0.047
p-value †	< 0.0005				< 0.0005				
defecation problems									
before treatment	2.96	6.1%	65.7%	33.4%	2.73	5.6%	41.7%	52.8%	
6 weeks post treatment	4.04	43.8%	37.5%	18.8%	3.45	10.5%	78.9%	10.6%	
6 months post treatment	4.52	70.8%	29.1%	0%	4.27	54.3%	37.5%	8.4%	0.167
p-value †	< 0.0005				< 0.0005				
discomfort in daily life									
before treatment	4.00	29.4%	50%	20.6%	4.18	36.1%	55.6%	8.4%	
6 weeks post treatment	4.45	68.8%	25.0%	6.3%	4.14	47.4%	36.9%	15.8%	
6 months post treatment	4.81	82.6%	17.4%	0%	4.72	79.2%	20.9%	0%	0.637
p-value †	< 0.002				< 0.003				

** 5-point Likert scale: 5 points resemble no complaints*
† paired t-test between preoperative and 6 months postoperative values within group
‡ repeated measurements analysis; tests of between-groups effects
§ corrected for initial difference at preoperative measurement

Complications

Table 3 summarizes the postoperative events during 6 months of follow-up. A significant difference in the number of reported complications, additional visits, and procedures between both groups was noted (P<0.0005). In the non-Doppler group, no complications were reported, while in the Doppler group 3 cases with complications were reported. The patients in the Doppler group visited the outpatient clinic and

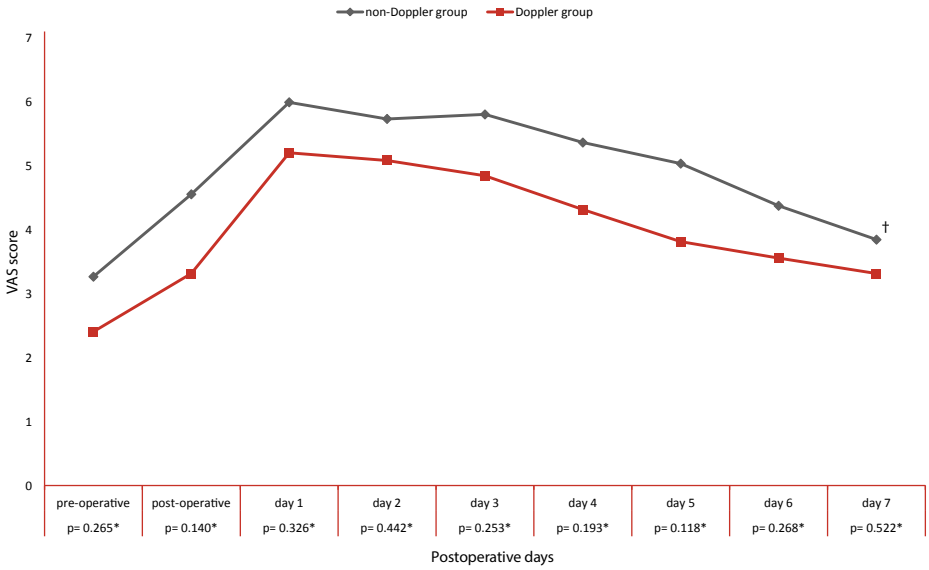

Figure 2. Course of postoperative pain (VAS-score). ∗ Independent samples t-test for comparison of mean VAS scores in both groups. † Repeated measures analysis; tests of between-groups effects. Corrected for the preoperative values (P = 0.682). Mean difference of 0.6 points on the 1 to 10 visual analog scale between both groups, not in figure.

Table 3. Not scheduled postprocedural events and complications

	non-Doppler group	Doppler group	p-value*
			< 0.0005
Complications	**0**	**3**	
		1 patient with postoperative external thrombosed peripheral vein 1 patient with postoperative retention bladder 1 patient with severe hemorrhage requiring blood transfusion	
Additional visits to hospital next to regular control visit	**2**	**7**	
	2 patients to the outpatient clinic 0 patients to the ER	4 patients to the outpatient clinic 3 patients to the ER	
Additional procedures in order to manage the complaints	**0**	**5**	
		2 hemorrhoidectomies 3 rubber banding procedures	

**Fishers exact test*

emergency department more frequently than the patients in the non-Doppler group. Visits to the emergency department concerned persisting bleeding or pain shortly after surgery. The visits to the outpatient clinic concerned persisting complaints of hemorrhoidal disease several weeks after surgery. During the follow-up of 6 months, in the non-Doppler group no additional procedures were performed to manage remaining complaints. In the Doppler group, 2 additional hemorrhoidectomies and 3 additional rubber-banding procedures were performed.

Patient Satisfaction

Table 4 provides an overview of the satisfaction rates of the patients in both groups. Although not statistically significant, differences in satisfaction rates between both groups were considerable. The patients in the non-Doppler group were more satisfied at both 6 weeks and 6 months in comparison to the Doppler group. Furthermore, 31% of the patients in the non-Doppler group reported complaint free after 6 months in contrast to 21% in the Doppler group. At both 6 weeks and 6 months postsurgery, respectively 5% and 8% of the patients in the non-Doppler group considered themselves to be in need of subsequent treatment, in contrast to respectively 21% and 17% of the patients in the Doppler group.

Table 4. Experiences with HAL from a patient's perspective

	non-Doppler group	Doppler group	p-value
Satisfied with the result of the procedure			
6 weeks postprocedural	81%	66%	0.172
6 months postprocedural	87%	75%	0.298
Complaint free			
6 weeks postprocedural	25%	9%	0.133
6 months postprocedural	31%	21%	0.313
Would undergo same procedure in case of recurrent disease			
6 weeks postprocedural	61%	64%	0.823
6 months postprocedural	87%	78%	0.437
In need of subsequent treatment			
6 weeks postprocedural	5%	21%	0.114
6 months postprocedural	8%	17%	0.383

Discussion

In this study, we evaluated the results of HAL performed with and without the supplied Doppler transducer. Both procedures resulted in significant reduction of the evaluated complaints. In analogy with previous published results, this beneficial effect of HAL procedure was to be expected.[8] However, the aim of this study was to evaluate whether there is a difference in outcome for both procedures. In a comparison between both procedures, we found a statistical significant difference in outcome for prolapse complaints. In the non-Doppler group, there were 23.5% less patients who suffered from mild or severe prolapse complaints 6 months after the procedure when compared with the Doppler group. Because prolapse is an important part of the complaint profile of hemorrhoidal disease and a focus of current treatment modalities, this result is not only statistically significant but also clinically relevant.

Considering clinical relevant parameters such as complications and additional treatments as summarized in Table 3, the non-Doppler group scored better. The Doppler group encountered more complications and were in need of more additional support in terms of repeated outpatient clinic and emergency department visits and additional procedures to manage the persisting complaints. In addition, although not statistically significant, we found considerable differences in favor of the non-Doppler group in patient's satisfaction rates, complaint-free percentages, and the number of patients who think they are in need of subsequent treatment.

On the contrary, patients in the non-Doppler group experienced slightly more pain (a mean difference of 0.6 points on a 0–10 visual analogue scale) and were unable to perform their daily activities a few more days than the patients in the Doppler group. Although this is not a statistically significant difference, we find a difference of 2.1 days of clinical relevance.

The main weakness of our study is related to the sample size. However, we believe that this relatively small single-center study could provide clinicians with convincingly conclusive data. Another weakness is related to the included patients; we only included patients with grade II and grade III hemorrhoidal disease and did not include patients with hemorrhoidal disease grade I or IV. In literature, it is suggested that the results of the ligation procedure is depended on the initial grading.[9] Subsequent analysis of our data by means of the Kruskal-Wallis test suggests that there is no significant difference in outcome for the procedure dependent on the initial grading. Finally, after

randomization, 9 patients left the study for various reasons. This limits the strength of our study, although a post hoc analysis with the actual sample sizes determined a remaining power of 81%.

The fact that the treatment outcome of the patients in the non-Doppler group was similar, and at some parameters better than in the Doppler group, supports the hypothesis that the beneficial effect of HAL may not be caused by the Doppler localization of the supplying arteries and subsequent ligation. Our observations suggest that there may be another or complimentary underlying working mechanism that accounts for the beneficial effect of HAL. We hypothesize that due to the various ligations, a restrictive pressure is applied at the arterial microcirculation in the corpus cavernosum recti, which results in shrinkage of the pathological tissue and reduction of the complaints. To achieve a beneficial effect it seems therefore unnecessary to ligate the main artery itself, but compromising the blood flow in the microcirculation of the pathological tissue may suffice.

Furthermore, we hypothesize that due to a visual approach (non-Doppler group) the surgeon is triggered to ligate the prolapsed tissue rather than to focus on the tissue where audible signals are present (Doppler group). It seems that this visual approach results in a way of operating that causes the patients to suffer a little more pain and a longer recovery time, but to benefit as a result of less complications, less re-treatments, more prolapse reduction, and higher satisfaction rates. One might conclude that ligation of the prolapsed tissue is more effective than ligating the supplying arteries which may or may not be present in the prolapsed tissue.

It appears that the visual approach is better from a patient perspective but is also interesting from the economic point of view. The visual approach necessitates less expensive supplies such as Doppler probes, disposable proctoscopes, and Doppler equipment and involves less re-treatments and complication management resulting in a considerable cost reduction.

In conclusion, our findings confirm that the hemorrhoidal artery ligation procedure reduces signs and symptoms of hemorrhoidal disease. Our data also show that the Doppler transducer does not contribute to this beneficial effect and could be omitted during the ligation procedure in the treatment of hemorrhoidal disease.

Acknowledgments

The authors thank Ellen Tromp for help with the statistical analysis and Arie Jan van Winkelhoff and Bert Bos for help in the preparation of the manuscript.

References

1. Morinaga K, Hasuda K, Ikeda T. A novel therapy for internal hemorrhoids: ligation of the hemorrhoidal artery with a newly devised instrument (Moricorn) in conjunction with a Doppler flowmeter. *Am J Gastroenterol* 1995; **90:** 610–613.
2. Scheyer M, Antonietti E, Rollinger G, *et al.* Doppler-guided hemorrhoidal artery ligation. *Am J Surg* 2006; **191:** 89–93.
3. Wallis de Vries BM, van der Beek ES, de Wijkerslooth LR, *et al.* Treatment of grade 2 and 3 hemorrhoids with Doppler-guided hemorrhoidal artery ligation. *Dig Surg* 2007; **24:** 436–440.
4. Faucheron JL, Gangner Y. Doppler-guided hemorrhoidal artery ligation for the treatment of symptomatic hemorrhoids: early and three-year follow-up results in 100 consecutive patients. *Dis Colon Rectum* 2008; **51:** 945–949.
5. Schuurman JP, Go PM, Bleys RL. Anatomical branches of the superior rectal artery in the distal rectum. *Colorectal Dis* 2009; **11:** 967–971.
6. Likert R. A technique for the measurement of attitudes. In: *Archives of Psychology*. Vol. 22. **No. 140**. 1932:1–55.
7. Hardy A, Chan CL, Cohen CR. The surgical management of haemorrhoids: a review. *Dig Surg* 2005; **22:** 26–33.
8. Giordano P, Overton J, Madeddu F, et al. Transanal hemorrhoidal dearterialization: a systematic review. *Dis Colon Rectum* 2009; **52:** 1665–1671.
9. Dorn HU, Mory M. 5 Jahre HAL: Erfahrungen und langzeitenergebnisse. *Coloproctology* 2007; **29:** 205–210.

5

Anal duplex fails to show changes in vascular anatomy after the hemorrhoidal artery ligation procedure

J. P. Schuurman, P. M. N. Y. H. Go

Colorectal Dis 2012; **14;** e330–e334

The definitive version is available at www3.interscience.wiley.com

ABSTRACT

Aim

The aim of this prospective study was to evaluate whether the beneficial effect of hemorrhoidal artery ligation (HAL) is attributable to a change in the macroscopic vascular anatomy at the level of the corpus cavernosum recti.

Method

Patients treated with HAL for grade II or grade III hemorrhoids were scanned by anal color Doppler endosonography before treatment and 6 weeks postoperatively. As part of a randomized controlled trial, patients were treated either with or without the Doppler transducer. The number and diameter of vascular structures were measured at the distal, mid and proximal levels in the anal canal.

Results

There were 30 patients in the non-Doppler group and 34 in the Doppler group. The postoperative measurements of the anal color Doppler endosonography did not show any significant differences in macroscopic vascular anatomy compared with the preoperative measurements, regardless of whether the Doppler transducer was used ($P > 0.05$).

Conclusion

This study failed to show that the effect of HAL is caused by alteration of the macroscopic vascular anatomy in the corpus cavernosum recti.

5

Anal duplex fails to show changes in vascular anatomy after the hemorrhoidal artery ligation procedure

Introduction

Hemorrhoidal artery ligation has become popular for the treatment of hemorrhoids. Its rationale is occlusion of the arteries supplying the corpus cavernosum recti. During the procedure the arteries are located by a Doppler transducer incorporated into a specially designed proctoscope. It is believed that the Doppler transducer is able to indicate the exact location of the supplying arteries, thus facilitating targeted placement of the ligations. It is postulated that because of the ligation of the artery a reduction in blood flow is established, resulting in a diminution of symptoms.

The procedure relieves hemorrhoidal symptoms to some extent but the mode of action is debated.[1] One of the suggestions is that it has an effect on the vascular anatomy of the distal rectum, but this has not been formally studied. The aim of this study was to determine prospectively whether the effect of the hemorrhoidal artery ligation (HAL) procedure is attributable to a change in the macroscopic vascular anatomy in the corpus cavernosum recti.

Method

The study was carried out as an adjunct to the HEMARTY study, a single-centre, single-blinded randomized controlled trial in which the outcome of HAL without (non-Doppler group) and with (Doppler group) the Doppler transducer was compared in patients with grade II, grade II/III and grade III hemorrhoids.[2] Grade II hemorrhoidal disease was defined as bleeding without prolapse and grade III hemorrhoidal disease was defined as prolapse that could be reduced digitally.

The study was approved by the hospital Ethics Committee and written informed consent was obtained from each patient. Data were obtained from 35 patients in the non-Doppler group and from 38 patients in the Doppler group (Table 1). Patients were

Table 1. Baseline characteristics

	non-Doppler n = 35	Doppler n = 38	p value
Age, years	51 (13.7)	50 (13.0)	0.988
Sex ratio (M:F)	24 : 10	22 : 14	0.560
Grade of hemorrhoid			
Grade II	12 (34%)	7 (18%)	0.122
Grade II/III	14 (40%)	19 (50%)	0.391
Grade III	9 (26%)	12 (32%)	0.583
Duration symptoms (years)	13.3 (13.6)	11.3 (11.0)	0.126

** Data are given as mean ± sd or as n (%).*

scanned by anal color Doppler endosonography (ACDE) in addition to receiving the standard physical examination and preoperative work-up. The ACDE was performed preoperatively and 6 weeks after the procedure.

Anal color Doppler endosonography

Patients were placed in the left lateral position. They were studied by one examiner (JPS), trained in ACDE, using an EUB 6500 scanner with an EUP-R54AW 5.0–10.0 MHz transducer (diameter 6 mm) (Hitachi Medical Systems Europe, Reeuwijk, The Netherlands) covered with a soft sonolucent protective cover (Safe Scan 84;Amedic, Stockholm, Sweden). The scanner had sufficient resolution to depict all relevant topographic landmarks, including vessels that could be detected down to a diameter of 0.1 mm. The anal canal was assessed at the following levels: distal (0–1 cm above the dentate line), mid (2–3 cm above the dentate line) and proximal (4–5 cm above the dentate line). The mid level was considered to be the level at which the corpus cavernosum recti would be found. The Doppler transducer allowed for 360° vision, facilitating a transectional view on the anal canal and accompanying vessels at the various anal canal levels. All vessels draining into the corpus cavernosum recti, including submucosal branches, were imaged. All other vascular structures not related to the rectal wall were not taken into account. Low-flow (venous) and high-flow (arterial) vascular structures were captured, but were not scored separately. The number and diameter of visible vascular structures draining into the corpus cavernosum were

measured. The blood supply of the variable middle and the inferior rectal arteries were not studied because neither contributes significantly to the corpus cavernosum recti.[3,4]

Surgical technique

The HAL procedure was performed in the operating theater with the patient under general anesthesia in the lithotomy position. The THD proctoscope (THD America, Inc., Tampa, FL, USA) was used in all cases. The ligations were performed with an absorbable, synthetic braided suture (Darvin, 2/0 vicryl, 5/8 circumference; Ergomed Sutramed, San Antonio, Texas, USA). Patients in the non-Doppler group underwent arterial ligation without the Doppler transducer, placed in the area of visible hemorrhoidal tissue. Patients in the Doppler group underwent standard arterial ligation directed by the Doppler transducer. Significant reduction or disappearance of the Doppler signal was considered to be confirmation of vessel occlusion. In both groups a figure-of-eight ligation was applied with a maximum of six ligations to correspond to the anatomy of the intramural branches of the supplying arteries. Six ligations have been previously reported to produce a satisfactory result.[5-7] In both groups no additional pexy procedures were performed because the aim of the study was to determine the effect of the ligation per se. All procedures were performed by surgeons and residents under supervision of the same surgeon (PG).

Statistical analysis

Statistical analysis was performed using the statistical package SPSS, version 18.0 (SPSS Inc., Chicago, IL, USA). Statistical differences in pre- and postoperative number of vessels and vessel diameter were determined using the paired Student's t-test. Comparison between groups was performed using the independent samples t-test. Statistical significance was defined as a P-value of <0.05.

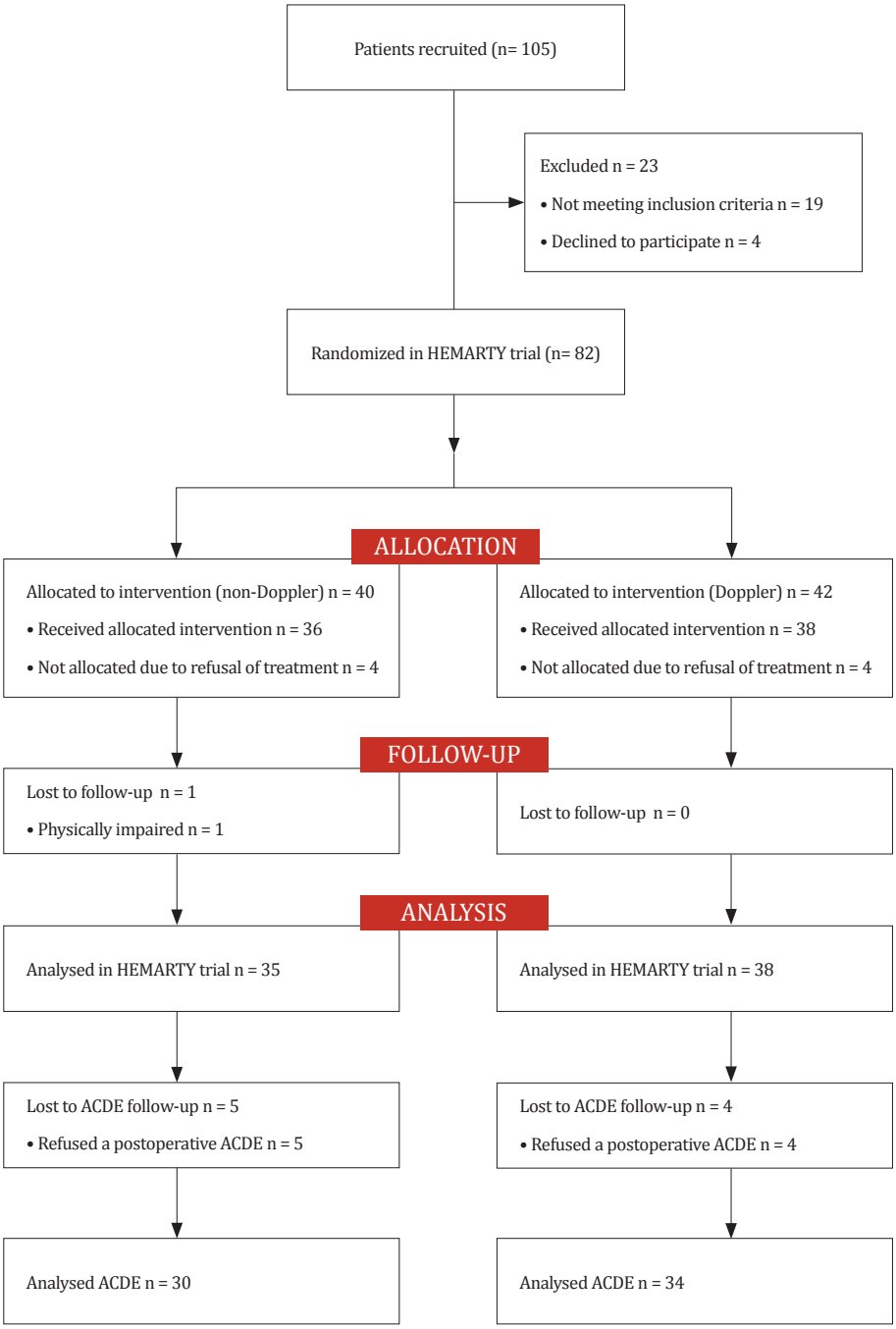

Figure 1. Flow chart. ACDE, anal colour Doppler endosonography; HEMARTY.

Results

Sixty-three patients underwent ACDE (Figure 1). Eleven (17%) had previously undergone rubber band ligation, all at least 6 months previously. None of the patients had undergone a procedure for prolapse and hemorrhoids (PPH) or a hemorrhoidectomy. The number of ligations placed during surgery did not differ significantly between groups. In the non-Doppler group, a median (sd) of five (0.75; range 3–6) ligations were placed and in the Doppler group this was also five (0.71; range 4–6) (P = 0.75).

The ACDE provided a detailed overview of vascular structures at different levels of the anal canal. Both arterial and venous blood flow areas were visible but were not differentiated. Frequently, larger vessels not related to the rectal wall were seen but were considered to be not relevant because an intraluminal ligation would not reach beyond the rectal wall. Few vascular structures (median = 0) were seen at the level of the dentate line. The mid level showed the most variation, thought to be caused by the known variations in the corpus cavernosum recti. At the level of the proximal anal canal larger vascular structures could be identified.

Figure 2a shows an ACDE frame of the preoperative measurement taken at the level of the corpus cavernosum recti in a patient undergoing HAL directed by the Doppler transducer. Five ligations were placed before the Doppler signals become silent. Six weeks postoperatively (Figure 2b) the same distinct vascular structure could be seen penetrating through the rectal circular muscular and muscularis mucosae. Despite improvement of symptoms, there was no significant difference in the vascular anatomy.

At the level of the corpus cavernosum recti (mid anal canal) in the non-Doppler group preoperatively, a median of three vessels was found, of mean ± sd diameter 1.1 ± 0.4 mm, compared with a median of three vessels of mean ± sd diameter 1.1 ± 0.3 mm in the Doppler group (Table 2). Postoperatively there were, respectively, two vs three vessels of (mean ± sd) 1.0 ± 0.3 and 1.1 ± 0.3 mm in diameter. These preoperative and postoperative measurements were not statistically different in the two groups at any level in the anal canal. The only statistically significant difference was between the postoperative vessel diameter at the proximal anal canal level, which was larger in the Doppler group (1.4 ± 0.6 vs 1.2 ± 0.4 mm; P = 0.030) (Table 2).

2a.

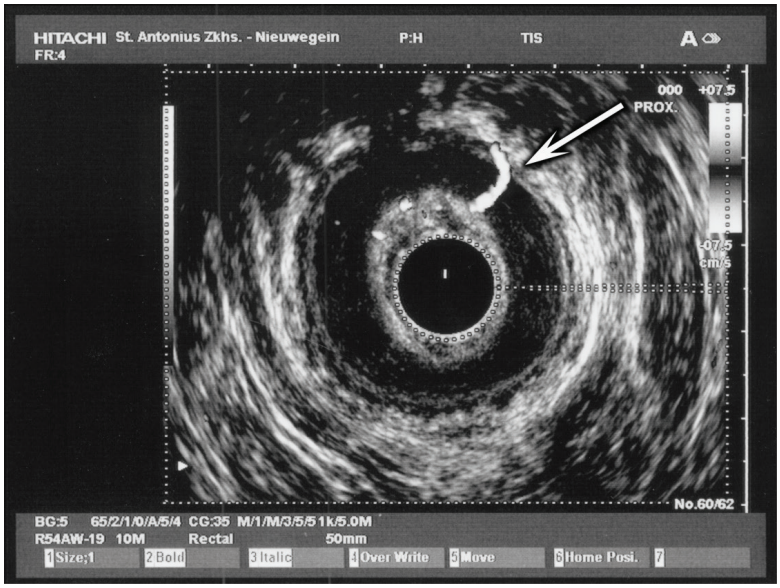

2b.

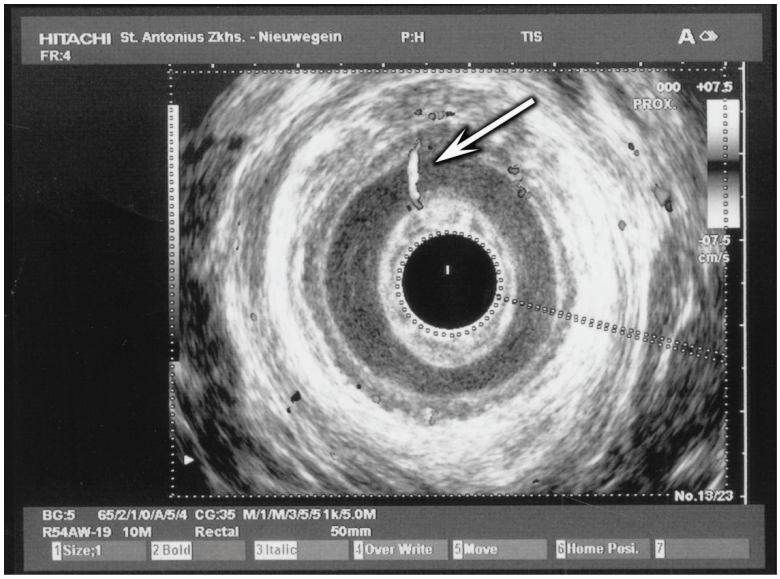

Figure 2. Anal color Doppler endosonography (ACDE). (a) Captured ACDE frame of the preoperative measurement at the level of the corpus cavernosum recti, showing a penetrating vascular structure towards the corpus cavernosum recti (arrow). (b) Postoperative ACDE frame of the same patient 6 weeks after the procedure. Despite the Doppler-guided placement of the ligation, no significant difference in vascular anatomy was observed.

Table 2. Results of anal colored Doppler endosonography

		preprocedural	postprocedural	p-value ¶
Number of arteries distal level; median (range) *				
	non-Doppler	0 (1.2)	0 (0.7)	0.104
	Doppler	0 (0.7)	0 (1.0)	0.311
	p-value †	0.140	0.403	
Number of arteries mid level; median (range) ‡				
	non-Doppler	3 (1.2)	2 (1.1)	0.345
	Doppler	3 (2.1)	3 (0.8)	0.839
	p-value †	0.448	0.231	
Number of arteries proximal level; median (range) §				
	non-Doppler	2 (1.2)	2 (0.9)	0.534
	Doppler	3 (1.0)	2 (1.2)	0.203
	p-value †	0.083	0.066	
Vessel diameter (mm) distal level (range) *				
	non-Doppler	0.7 (0.2)	0.7 (0.2)	1.00
	Doppler	1.0 (0.2)	1.2 (0.6)	0.595
	p-value †	0.173	0.090	
Vessel diameter (mm) mid level (range) ‡				
	non-Doppler	1.1 (0.4)	1.0 (0.3)	0.194
	Doppler	1.1 (0.3)	1.1 (0.3)	0.728
	p-value †	0.283	0.095	
Vessel diameter (mm) proximal level (range) §				
	non-Doppler	1.4 (0.5)	1.2 (0.4)	0.326
	Doppler	1.3 (0.4)	1.4 (0.6)	0.238
	p-value †	0.648	0.030	

** Distal level is at the level of the dentate line*
† Independent sample t-test between non-Doppler and Doppler group
‡ Mid level is at 2-3 cm proximal to the dentate line
§ Proximal level is 5 cm proximal to the dentate line
¶ Paired t-test between pre- and postoperative measurement

Discussion

The study showed no significant difference in the vascular anatomy of the corpus cavernosum recti 6 weeks after HAL in patients entered in the HEMARTY trial, despite a significant reduction in symptoms.[2] The finding is striking because the aim of the treatment is to ligate the supplying arteries. While an effect on the vessels might be expected in both the non-Doppler and Doppler groups there was no difference in vascular anatomy postoperatively.

It must therefore be concluded that the exact mechanism of HAL is not yet clear. Walega *et al.* postulated that the ligation could interfere with the anorectal physiology. They found however, no difference between preoperative and postoperative values.[8] We postulate that the beneficial effect of ligation is not based on alteration of anorectal physiology or vascular anatomy but is mainly achieved by the application of pressure to the microcirculation within the hemorrhoidal tissue. This would be sufficient to reduce flow and cause fibrosis with a resulting improvement of symptoms.

In its early days, HAL was performed with a figure-of-eight ligation. However, in patients with more severe hemorrhoids, redundant hemorrhoidal tissue persisted following the ligation. As a result the technique was modified to include recto anal repair (RAR) or mucopexy in addition. This resulted in an elevation of the hemorrhoidal plexus and its fixation to a more anatomically correct position.[9] The mucopexy appeared to improve the clinical results.[10-12] As the primary goal of our study was to evaluate the influence of the figure-of-eight ligation on the vascular anatomy of the corpus cavernosum recti, a mucopexy or RAR was not performed. For the same reason grade IV hemorrhoids were excluded because the vascular anatomy of the corpus cavernosum recti would have been too distorted to assess.

The ACDE probe is a good instrument for visualizing the vascular anatomy of the distal rectum. It is noteworthy, however, that it demonstrated on average only two to three vessels at the level of the corpus cavernosum recti. This is small compared with the six to eight ligations placed during the procedure and raises the question of the origin of the signals heard during the procedure. Based on the ACDE frames, we postulate that some of the signals heard during HAL may originate from vascular structures located beyond the rectal wall. These do not drain into the corpus cavernosum recti and are out of range of the ligation, but they might nevertheless be able to cause an audible Doppler

signal during surgery.

The number of arteries in this in vivo study was different from the eight found in our anatomical study.[4] With ACDE, only a few patients showed the typical configuration seen in the anatomical models. This might be due to the Doppler equipment used. However, when the ACDE pictures were compared with the locations of the audible signals of the Doppler probe used during surgery it showed similar results. Further work is needed to determine the cause of the difference between the anatomical model and the in vivo situation.

In conclusion, despite the proven beneficial clinical effect of HAL there is no sonographic evidence that this is caused by an alteration of the macroscopic vascular anatomy of the corpus cavernosum recti.

Acknowledgements

The authors thank Bert Bos and Arie Jan van Winkelhoff for their help in the preparation of the manuscript.

References

1. Giordano P, Overton J, Madeddu F *et al.* Transanal hemorrhoidal dearterialization: a systematic review. *Dis Colon Rectum* 2009; **52:** 1665–71.
2. Schuurman JP, Borel Rinkes IHM, Go PMNYH. Hemorrhoidal artery ligation procedure with or without Doppler transducer in grade II and III hemorrhoidal disease: A blinded randomized clinical trial. *Ann Surg* 2012; **255:** 840–5.
3. Aigner F, Bodner G, Conrad F, Mbaka G, Kreczy A, Fritsch H. The superior rectal artery and its branching pattern with regard to its clinical influence on ligation techniques for internal hemorrhoids. *Am J Surg* 2004; **187:** 102–8.
4. Schuurman JP, Go PM, Bleys RL. Anatomical branches of the superior rectal artery in the distal rectum. *Colorectal Dis* 2009; **11:** 967–71.
5. Sohn N, Aronoff JS, Cohen FS, Weinstein MA. Transanal hemorrhoidal dearterialization is an alternative to operative hemorrhoidectomy. *Am J Surg* 2001; **182:** 515–9.
6. Lienert M, Ulrich B. Doppler-guided ligation of the hemorrhoidal arteries. report of experiences with 248 patients. *Dtsch Med Wochenschr* 2004; **23;129:** 947–50.
7. Scheyer M, Antonietti E, Rollinger G, Mall H, Arnold S. Doppler-guided hemorrhoidal artery ligation. *Am J Surg* 2006; **191:** 89–93.
8. Walega P, Scheyer M, Kenig J *et al.* Two-center experience in the treatment of hemorrhoidal disease using dopplerguided hemorrhoidal artery ligation: functional results after 1-year follow-up. *Surg Endosc* 2008; **22:** 2379–83.
9. Scheyer M. Doppler-guided recto-anal repair: a new minimally invasive treatment of hemorrhoidal disease of all grades according to scheyer and arnold. *Gastroenterol Clin Biol* 2008; **32:** 664.
10. Testa A, Torino G, Gioia A. DG-RAR (doppler-guided recto-anal repair): a new mini invasive technique in the treatment of prolapsed hemorrhoids (grade III-IV): preliminary report. *Int Surg* 2010; **95:** 265–9.
11. Forrest NP, Mullerat J, Evans C, Middleton SB. Dopplerguided haemorrhoidal artery ligation with recto anal repair: a new technique for the treatment of symptomatic haemorrhoids. *Int J Colorectal Dis* 2010; **25:** 1251–6.
12. Walega P, Krokowicz P, Romaniszyn M *et al.* Doppler guided haemorrhoidal arterial ligation with recto-anal-repair (RAR) for the treatment of advanced haemorrhoidal disease. *Colorectal Dis* 2010; **12:** e326–9.

6

Predictive value of self-reported clinical parameters in assessment of the anal complaint

J.P. Schuurman, P.M.N.Y.H. Go

Submitted

6

Predictive value of self-reported clinical parameters in assessment of the anal complaint

Introduction

Complaints in the anal area are frequently occurring events in general health care. Often the patient and the physician assume that these complaints are related to hemorrhoidal disease.[1] As the anatomy in the anal region can be difficult to assess it can be difficult to determine the exact cause of the anal complaints. Therefore, we investigated how the by patients self-reported clinical parameters relate to the final diagnosis and whether these parameters could facilitate the determination of the nature of the complaints in the anal area.

Methods

Patients that were electively referred by their general practitioner for hemorrhoidal disease were seen in our surgical outpatient clinic and were included in this study. Patients referred for anal fissures and skintags did not belong to population and were treated separately. Patients' self-reported clinical parameters were prospectively collected by means of a written questionnaire that contained questions about complaints in the anal area including blood loss, pain, prolapse, itching, problems with defecation and discomfort in daily life. Each item could be answered as either 'yes, present' or 'no, not present'. The questionnaire aimed to assess patients' views on the actual complaints caused by the anal disorder, whether this was due to hemorrhoidal disease or something else.

The questionnaires were independently collected by an employee of the outpatient clinic. The surgeon was not informed about the answers until his diagnosis was established. After the anamnesis, physical examination and subsequent proctoscopy the diagnosis made by the referring general practitioner was either confirmed or adjusted. Subsequently the patients were set for therapy. All patients were seen by the same surgeon.

The positive predictive value (PPV) was calculated as the proportion of patients who

suffered from the self-reported clinical parameters and were positive for the diagnosis. Similarly, the negative predictive value (NPV) gives the proportion of patients who did not suffer from the items mentioned in the group negative for the diagnosis. PPV and NPV and their 95% confidence intervals (CI) were calculated using SPSS 18.0 statistical package (SPSS®, Inc., Chicago, IL, USA).

Results

Between June 2008 and June 2010, 170 consecutive patients with a diagnosis of hemorrhoidal disease were seen in the outpatient clinic. The mean age of the patients was 47 years (sd 13.4 years). In 52.4% of the patients the diagnosis of hemorrhoidal disease diagnosed by the general practitioner could be confirmed. For 47.6% of patients it appeared that the symptoms were due to other causes as they had been wrongly diagnosed with hemorrhoids in the first instance. The second most common diagnosis was skintags (18.2%), followed by anal fissures (14.1%). Table 1 summarizes the variety

Table 1. Characteristics of the 170 patients included in the analysis

Age (sd)		47 (13.4)
Sex ratio (M:F)		84 : 86
Elapsed time since start complaints; months (sd)		113 (131)
Patients undergone previous treatment		51 (35.4 %)
Diagnosis	**n**	**%**
Grade I	5	2,9 %
Grade II	28	16,5 %
Grade III	55	32,4 %
Grade IV	1	0,6 %
Skintag	31	18,2 %
Anal fissure	24	14,1 %
Thrombosed peripheral vein (external hemorrhoid)	9	5,3 %
Anal polyp	6	3,5 %
Dermatitis	5	2,9 %
Rectum carcinoma	3	1,8 %
Fistula	1	0,6 %
Proctalgia fugax	1	0,6 %
Pruritis ani	1	0,6 %

of diagnosis of the remaining patients included in the present analysis.

Table 2 provides an overview of the PPV and NPV of the six self-reported clinical parameters in relation to the three most common diagnoses including hemorrhoidal disease, anal fissure and skintags. The most important predictor for hemorrhoidal disease is the presence of blood loss: 50/74 patients (67.6%) with this condition had indeed a confirmed diagnosis of hemorrhoidal disease. The other self-reported clinical parameters are less contributory in determining the presence of hemorrhoidal disease. Combining blood loss and prolapse resulted in a probability of 75.5% for a positive diagnosis of hemorrhoidal disease.

The PPV for the diagnosis anal fissure in respect to the self-reported clinical parameters is particularly low. However, the NPV for pain in relation to the diagnosis fissure is particularly high; 97% with a likelihood ratio of 8.56 (95% CI 6.75 – 10.86), *i.e.* in the absence of pain there is a probability of 3% that the complaint is caused by a fissure. The same is true for the relation of an anal fissure and difficulties during defecation with a NPV of 98% and a likelihood ratio of 9.21 (95% CI 7.52 – 11.28).

For the diagnosis skintag a NPV of 82.8% was found for the symptom of itching. For all other symptoms the PPV and NPV are particularly low and the diagnosis of skintags is therefore even more difficult to identify by means of anamnestic characteristics.

Discussion

Summary of main findings

For 47.6% of the patients it appeared that the symptoms were in the first instance wrongly assessed as hemorrhoidal disease. Our analysis revealed that if a patient presents with complaints of anal blood loss there is a probability of 67.6% that the complaint is caused by hemorrhoidal disease. A combination of both anal blood loss and prolapse result in a probability of 75.5% for the presence of hemorrhoidal disease. We conclude that the anamnesis could provide an important clue about the nature of the anal complaint but is not specific enough to set the diagnosis on the anamnesis alone.

Strengths and limitations of the study

We analyzed a population referred by general practitioners, which provided a good insight in the assessment of anal complaints by general practitioners. A limitation of the

Table 2. Self-reported clinical parameters related to diagnosis

	hemorrhoidal disease					**anal fissure**				**skintags**			
	prevalence	*PPV*	*95% CI*	*NPV*	*95% CI*	*PPV*	*95% CI*	*NPV*	*95% CI*	*PPV*	*95% CI*	*NPV*	*95% CI*
Blood loss	44.0	67.6	56.3 - 77.1	68.1	58.1 - 76.6	13.5	7.5 - 23.1	86.2	77.8 - 91.7	6.8	2.9 - 14.9	72.3	62.6 - 80.4
Pain	55.1	45.7	35.9 - 55.8	41.5	30.4 - 53.7	22.8	15.4 - 32.4	97.3	90.8 - 99.3	13.0	7.6 - 21.4	76.0	65.2 - 84.2
Prolapse	66.5	57.8	48.4 - 66.5	70.9	57.9 - 81.2	11.0	6.4 - 18.3	81.8	69.7 - 89.8	16.5	10.7 - 24.6	76.4	63.7 - 85.6
Itching	35.4	27.5	17.1 - 40.9	52.7	42.6 - 62.5	17.6	9.6 - 30.3	84.9	76.3 - 90.8	29.4	18.7 - 43.0	82.8	73.9 - 89.1
Problems with defecation	70.5	53.0	44.0 - 61.8	71.2	58.6 - 81.2	18.8	12.8 - 26.8	98.0	89.3 - 99.6	15.4	10.0 - 23.0	73.5	59.7 - 83.8
Discomfort in daily life	30.5	50.0	36.6 - 63.4	52.6	43.5 - 61.6	26.0	15.9 - 39.6	91.2	84.6 - 95.2	10.0	4.3 - 21.4	77.2	68.7 - 83.9
Blood loss and prolapse	31.5	75.5	62.4 - 85.1	64.3	55.3 - 72.5	n.a.				n.a.			

NPV = negative predictive value.
PPV = positive predictive value.
n.a. = not applicable

analysis could be the relatively small sample size.

Comparison with existing literature

To the authors' best knowledge there is no published data showing the accuracy of the diagnosis hemorrhoids by general practitioners in patients with an anal complaint. A correct diagnosis of the anal complaint set by the general practitioner was observed in 52.4% of the referred patients. This percentage is close to the percentages published by Grucela *et al.* with an overall diagnostic accuracy for physicians of 53.5%.[2]

Implications for future research or clinical practice

These results provide insight for the general practitioners that the frequent occurring anal complaint is often wrongly assessed as being hemorrhoids. Our results show that an inventory of self-reported clinical parameters alone is not very reliable in assessing the nature of the anal complaint. Therefore, to diagnose anal disease correctly an anamnesis of patients' complaints should be followed by specific physical examination of the anal region. In this way a more specific referral to a surgeon, dermatologist or gastroenterologist could be realized.

References

1. Kuehn HG, Gebbensleben O, Hilger Y, Rohde H. Relationship between anal symptoms and anal findings. *Int J Med Sci* 2009; **6:** 77-84.
2. Grucela A, Salinas H, Khaitov S, *et al.* Prospective analysis of clinician accuracy in the diagnosis of benign anal pathology: Comparison across specialties and years of experience. *Dis Colon Rectum* 2010; **53:** 47-52.

7

Internal and external hemorrhoids

J.P. Schuurman, P.M.N.Y.H. Go

Ned Tijdschr Geneeskd 2011; **155:** A3113

www.ntvg.nl

7

Internal and external hemorrhoids

Ladies and gentlemen,

In 1963 Lockhart-Mummery wrote: *'...nearly every lesion around the anus is liable to be called 'piles' by the patient and not infrequently by the referring doctor also.'* [1] Lockhart-Mummery described here that in his time the internal and external hemorrhoids were seen as one diagnosis or easily confused. In 2012 this still appears to be the case. It can be hard to judge the source of the complaint because the anatomy of the anal area is sometimes hard to define. Because internal and external hemorrhoids are often regarded as one group, these conditions are often wrongfully treated the same, for example using lidocaine ointment and zinc oxide suppositories. Difficulties making the correct diagnosis can lead to a delay in effective treatment.

In this clinical lesson we demonstrate three cases which show that anal complaints can be caused by hemorrhoids that are manifested in various ways.

Patient A, a 27 year-old female, was referred by her GP to the surgical outpatient's clinic with a diagnosis for 'hemorrhoids'. The patient had had incidental bright red rectal blood loss when defecating for three months without a change in her defecation pattern. She experienced no pain; she did suffer from some prolapsing tissue while defecating; the tissue retracted spontaneously.

At the physical examination we met a healthy looking woman without co-morbidity. External inspection of the anal area showed no abnormalities. The rectal examination was not experienced as painful; no abnormalities were felt and there was no blood on the glove. A proctoscopy showed grade II internal hemorrhoids. The patient was successfully treated with rubber band ligation in which three bands were placed in one session. Eight months after the treatment the patient told us that she had been complaint free since the treatment.

Patient B, a 67 year-old female, was referred by her GP to the surgical outpatient's clinic with a diagnosis for 'hemorrhoids'. The patient told us that she had been suffering from a painful swelling near the anus for a year. The complaints increased every day during the day. In the past year there had been no occasion of rectal blood loss. Neither were there changes in the defecation pattern. The GP had already prescribed lidocaine ointment 30mg/g, but without any lasting effect. Former treatments using rubber band ligations had also failed to relieve any of the complaints.

At the physical examination we met a healthy looking woman without co-morbidity. An inspection of the anal area showed a blue discolored swelling at the left lateral side of the anus which was very painful during palpation (Figure 1). The swelling was soft in consistency and located outside of the lumen of the intestine. The rectal examination was painful, but without and further abnormalities.

The proctoscopy showed no prolapsing or easily bleeding hemorrhoidal tissue.

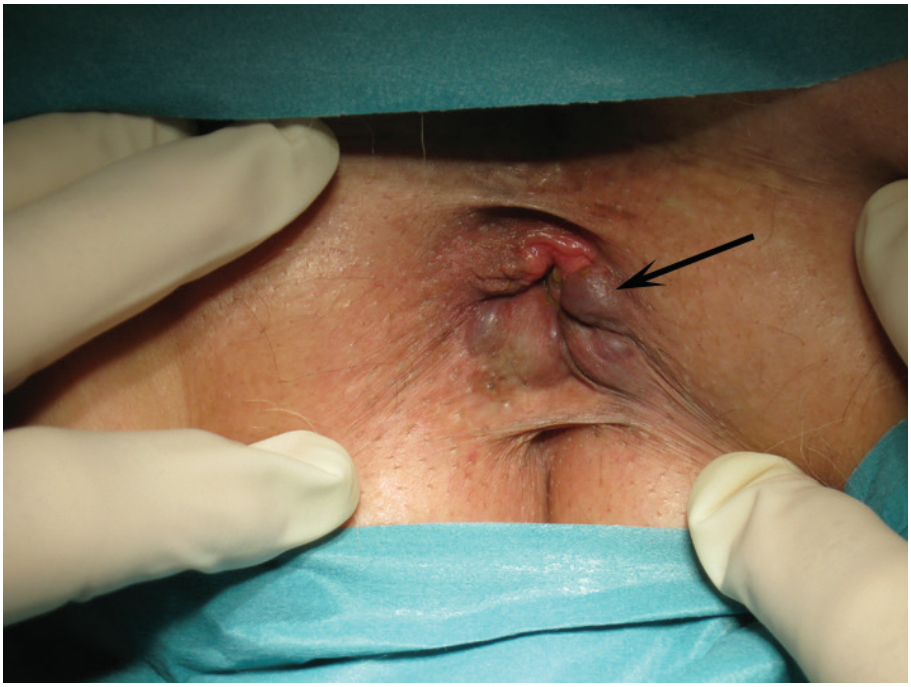

Figure 1. Anal area of patient B with non-thrombosed, engorged, perianal peripheral vein, usually called an external hemorrhoid.

We diagnosed non-thrombosed external hemorrhoid. We treated the patient using an excision of the swelling and a ligation of the underlying venous structure. During a control visit the complaints appeared to have disappeared completely. One year after the procedure the patient told us that she was still complaint free.

Patient C, a 31 year-old male, reported to the emergency room with severe continuous pain complaints around the anus that had come about in a short time and had been hurting for three days. One day prior to this the GP had diagnosed a painful swelling near the anus and incised it, causing the pain to subside somewhat. This relief was short-lived and the pain returned to the same level as before.

At the physical examination we saw a healthy looking man. Inspection of the anus revealed a painful, solid, blue discolored swelling at the right ventrolateral side with the traces of the GP's incision in it. The rectal examination was very painful, but showed no further abnormalities. We diagnosed an 'acute thrombosed external hemorrhoid'. We treated the patient using isosorbidedinitrate cream 10mg/g and explained to him about the recovery he was to expect in the next 14 days. When checked after both 2 weeks and 6 months the patient was pain free and functioned normally, except for a small extra skin tag.

Discussion

In the previous three cases patients reported complaints that might fit the diagnosis 'hemorrhoids' at first sight. Physical examination and further investigation showed that indeed these were hemorrhoids, but with different etiologies, each requiring a different treatment.

Anatomy

The anatomy of the anal area is further explained in figure 2. Every healthy rectum has hemorrhoidal tissue. This tissue is located in the distal rectum at the same height as the anal canal over a length of 2-3 cm until it reaches the dentate line, where it stops (Figure 2). The dentate line is the anatomical and histological line that marks the transition from the mucosa located inside the intestine to the squamous epithelium of the skin around the anus. This line is used to distinguish between internal hemorrhoids

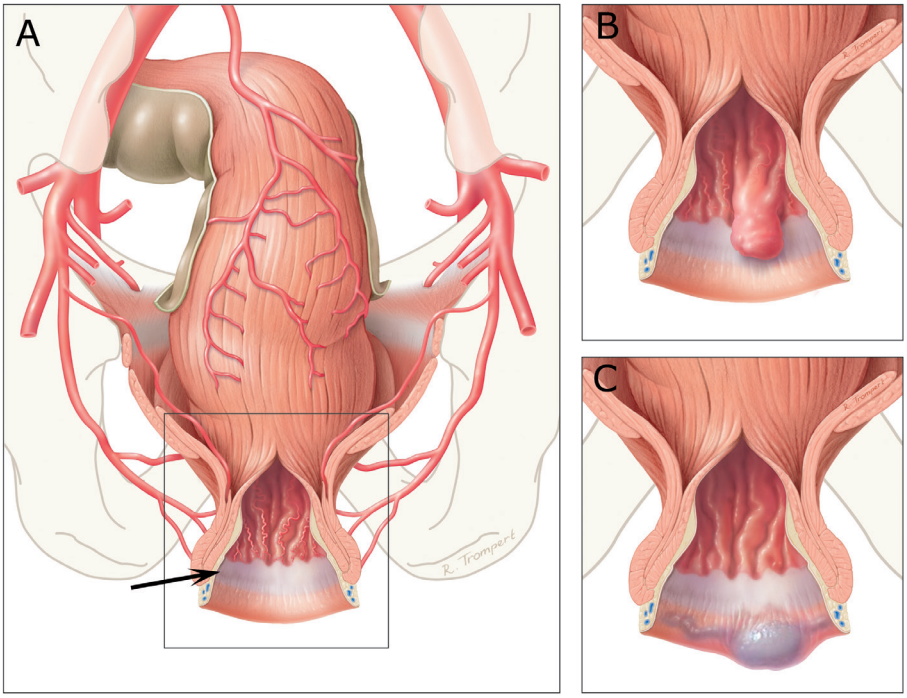

Figure 2. (a) Dorsal view of the rectum with dentate line at the level of the arrow. (b) Internal hemorrhoid with its origin located above the dentate line. (c) Thrombosed perianal peripheral vein, also called thrombosed external hemorrhoid, originating below the dentate line.

and anomalies with perianal peripheral veins, frequently addressed as internal and external hemorrhoids. Since the external hemorrhoid has a different etiology from the internal hemorrhoid it can be preferable to use the name describing the origin of the disease, i.e. internal hemorrhoid and thrombosed or engorged non-thrombosed perianal peripheral vein.

Internal hemorrhoids

The internal hemorrhoids find their origin in the intra-luminal located plexus hemorrhoidalis superior, also known as the corpus cavernosum recti, the swelling bodies of the rectum.[2,3] These vascular cushions are embedded in the connective tissue and smooth muscle cells. The smooth muscle cells create a fibro-elastic network as a supporting structure.[4] This anatomic configuration fulfills three important functions:

it helps to maintain the anal continence; contributes to the anal rest-pressure by 15-20% in addition to the sphincter pressure and protects the sphincter complex during defecation.[5] One talks of internal hemorrhoids when the vascular cushions along with the connective tissue and the smooth muscle cells swell, loose connection to the surrounding tissue and prolapse, which may or may not be accompanied by blood loss (Figure 2).

External hemorrhoids

The external hemorrhoids have two varieties: the acute thrombosed perianal peripheral vein, as was the case with patient C, and the engorged non-thrombosed perianal peripheral vein, as was the case with patient B. These peripheral veins find their origin in the plexus hemorroidalis inferior (Figure 2) and are located right below the perianal skin. Contrary to the mucosa that covers the internal hemorrhoid, the squamous epithelium surrounding the anus is highly innervated with somatic pain fibers. As a result, these so frequently called external hemorrhoids are often experienced as severely painful.

Diagnosis

To determine the cause of anal complaints a good anamnesis and physical examination are indispensable. Patients suffering from internal hemorrhoids typically complain of blood loss and a sensation of prolapsing tissue from the anus without any pain. In patients suffering from an external hemorrhoid pain is a more prominent feature. It is recommended to try and be aware of the structure causing the complaints: a vascular origin from the lumen or from the perianal skin. Proctoscopy can provide an additional value in this case. Proctoscopy can be done fast and simply during consultation hours without any necessary preparation by the patient and without anesthesia. In the presence of a fissure a proctoscopy can be painful and is therefore not recommended.

Table 1. Classification of hemorrhoids according to Golingher[6]

Grade I	painless blood loss, hemorrhoids visible on proctoscopy,
Grade II	prolapse of hemorrhoids when defecating, spontaneous reduction, blood loss
Grade III	prolapse, spontaneous or when defecating, manual reduction necessary, blood loss
Grade IV	permanent prolapse, not reducible, blood loss

The internal hemorrhoid is classified using the Goligher classification of 4 types (Table 1).[6] The most serious form (grade IV: prolapsed hemorrhoids) can be accompanied by thrombosing: this type of hemorrhoids should not be confused with a thrombosed perianal peripheral vein. In some cases a mixture of both occurs in which both the plexus hemorrhoidalis superior and inferior are involved.

It is advisable to perform an endoscopic examination on patients of 40 years and older to rule out polyps and colon carcinoma; from this age on there is an increased chance that blood loss has another cause besides hemorrhoids.[7]

Treatment Options

Internal hemorrhoids

Over the last years many treatments have been developed varying from lifestyle advice in the case of grade I hemorrhoids to surgical interventions in the case of grades II, III or IV hemorrhoids. The tendency in the treatment of internal hemorrhoids is: the lower the diagnosed grade, the less invasive the treatment needs to be. Thus grades I and II hemorrhoids with few symptoms can be treated from the GP's practice using advice on exercise, diet and toilet-hygiene. In more severe forms of internal hemorrhoids the choice is often made for the less invasive rubber band ligation. Other options to treat internal hemorrhoids are the hemorrhoid artery ligation (HAL) or trans-anal hemorrhoidal dearterialization (THD), and open or closed hemorrhoidectomy or a procedure for prolapse and hemorrhoids using a stapler-device (PPH).

External hemorrhoids

The thrombosed or engorged perianal peripheral vein complex (external hemorrhoid) can be treated conservatively or surgically. Literature shows that a surgical intervention using an excision can bring a more speedy relief of the complaints than conservative therapy (3,9 days versus 24 days).[8] In addition to this an excision provides significantly better relief of pain complaints and a significantly smaller chance of a recurrence than incision (thrombectomy) or conservative treatment.[9] The excision needs to be applied by experienced hands considering the risk of a sphincter trauma. Primarily, a conservative treatment would be recommended.

The literature reports good results with conservative treatment when it comes to

vascular resistance reducing medication that optimize the blood flow, such as nifedipine salve 0,3%, diltiazem cream 2% and isosorbidedinitrate cream 10 mg/g.[10] Good results for pain relief are reported on the use of a single shot of 30 units of botulinetoxine.[11] The use of lidocaine ointment 30 mg/g appears to be insufficiently effective. Conservative treatment will cause the body to reabsorb the thrombus. The stretched skin, however, will not always return to its original state, which can result in a skin tag which in general does not cause any complaints.

Ladies and Gentlemen, the medical histories described above show that complaints in the anal region often find their origin in the different anatomic structures. Even though the often used term 'hemorrhoids' creates the suspicion that these are the same disorder, they could in fact be disorders that differ greatly in both location and pathophysiology. A decent anamnestic survey of the complaints and physical exam are important to make the correct diagnosis. In the case of internal hemorrhoids conservative therapy is an option; in the more severe cases, a range of surgical treatment methods is available. In the case of thrombosed or engorged peripheral veins (or frequently called external hemorrhoids) the preferable treatment is primarily conservative, to be followed by a surgical intervention if necessary.

References

1. Lockhart-Mummery HE. Non-venereal lesions of the anal region. *Br J Vener Dis* 1963; **39:** 15-7.
2. Stelzner F, Staubesand J, Machleidt H. The corpus cavernosum recti; basis of internal hemorrhoids. *Langenbecks Arch Klin Chir Ver Dtsch Z Chir* 1962; **299:** 302-12.
3. Schuurman JP, Go PM, Bleys RL. Anatomical branches of the superior rectal artery in the distal rectum. *Colorectal Dis* **2009;** 11: 967-71.
4. Dal Dal Monte PP, Tagariello C, Sarago M, Giordano P, Shafi A, Cudazzo E, Franzini M. Transanal haemorrhoidal dearterialisation: Nonexcisional surgery for the treatment of haemorrhoidal disease. *Tech Coloproctol* **2007;** 11: 333,8.
5. Kaidar-Person O, Person B, Wexner SD. Hemorrhoidal disease: A comprehensive review. *J Am Coll Surg* 2007; **204:** 102-17.
6. Goligher JC (1980 4th edition). Haemorrhoids or piles. In *Surgery of the Anus Rectum and Colon,* pp 93–135. Baillere Tindall, London.
7. Vening W, Willigendael EM, Tjeertes EK, Hulsewe KW, Hoofwijk AG. Timing and necessity of a flexible sigmoidoscopy in patients with symptoms suggestive of haemorrhoids. *Colorectal Dis* 2010; **12:** 109-13.
8. Greenspon J, Williams SB, Young HA, Orkin BA. Thrombosed external hemorrhoids: outcome after conservative or surgical management. *Dis Colon Rectum* 2004; **47:** 1493-8.
9. Cavcic J, Turcic J, Martinac P, Mestrovic T, Mladina R, Pezerovic-Panijan R. Comparison of topically applied 0.2% glyceryl trinitrate ointment, incision and excision in the treatment of perianal thrombosis. *Dig Liver Dis* 2001; **33:** 335-40.
10. Perrotti P, Antropoli C, Molino D, De Stefano G, Antropoli M. Conservative treatment of acute thrombosed external hemorrhoids with topical nifedipine. *Dis Colon Rectum* 2001; **44:** 405-9.
11. Patti R, Arcara M, Bonventre S, Sammartano S, Sparacello M, Vitello G, *et al.* Randomized clinical trial of botulinum toxin injection for pain relief in patients with thrombosed external haemorrhoids. *Br J Surg* 2008; **95:** 1339-43.

8

Summary and general discussion

8

Summary and general discussion

Summary

Hemorrhoidal disease is an illness of all times and has gathered many treatment modalities in the past decades. At the end of the 20th century a new approach was introduced. In 1995 Morinaga *et al.* published the first results of a hemorrhoidal ligation procedure now known as the HAL procedure (hemorrhoidal artery ligation) or THD procedure (transanal hemorrhoidal dearterialisation).[1] Following this landmark publication, many reports have been published on the outcome of this ligation procedure. It was not until 2001 that the first evaluation was published.[2] Since then, many abstracts, reports and studies on this subject have seen the light, illustrating the increasing popularity of HAL based on the fact that it is less invasive than other surgical treatments. Despite the large number of clinical reports, the exact role of artery ligation in the management of hemorrhoidal disease has not been established due to lack of comprehensive clinical trials. Also, the underlying mechanism has not been fully elucidated.

The aim of this thesis was to study the working principle in relation to the outcome of the artery ligation procedure. To achieve this goal, we aimed to:

1. Evaluate the artery ligation procedure from a patient perspective.
2. Elucidate the vascular anatomy of the anal canal in the distal rectum and its role in the artery ligation procedure.
3. Asses the contributory value of the Doppler transducer in the artery ligation procedure.

In **chapter 2** we evaluated the short- and long term outcome of HAL from a patient's perspective regarding residual complaints including blood loss, prolapse, pain, defecation difficulties, and discomfort. In addition, patient satisfaction was evaluated.

In this study cohort the HAL procedure was the first treatment for hemorrhoidal disease for 32% of the patients; for 68% of the patients the procedure was used as an

adjunct to a previous treatment or as primary treatment followed later on by subsequent treatment during the follow-up of 29.2 months. At the end of the follow-up, 42% of the patients were completely or highly satisfied with the results, blood loss still being present in 32.3% of the patients and prolapse complaints in 73.8% of the patients. We concluded that HAL is a useful method to achieve symptom relief. However, it does not seem to be able to provide a definite cure for hemorrhoidal disease in the long term.

In **chapter 3**, we studied the arterial supply of the corpus cavernosum recti in the inner wall of the distal rectum. In ten non-fixed human cadavers the arterial vasculature of the rectum was studied by means of Araldite casting method. We obtained specimens in which the arterial vasculature of the rectum and corpus cavernosum recti could be studied in detail at all levels. The superior rectal artery was found to be the supplier of the corpus cavernosum recti, which consisted of a variable number of equally spaced twisting arteries. Our conclusion focused on the fact that the distal rectum is supplied by the superior rectal artery and that the supplying arteries of the corpus cavernosum recti are not as strictly bound to specific anatomical locations as has been suggested in the literature.[2-9] This finding may bear relevance for the surgical treatment of hemorrhoidal disease. Furthermore, the results of this anatomical study also raise the question of whether the arteries are within range of the ligation depth of the ligation procedure.

Chapter 4 deals with the question of whether the use of Doppler during HAL is beneficial. We conducted a single-blinded randomized clinical trial and assigned a total of 82 patients with grade II and III hemorrhoidal disease to undergo HAL with or without the use of Doppler. After six weeks and six months significant improvement was observed with regard to blood loss, pain, prolapse and problems with defecation in both the non-Doppler and the Doppler group ($p < 0.05$). This improvement did not differ significantly between groups except for prolapse, which improved more in the non-Doppler group ($p=0.047$). There were more complications and unscheduled post-operative events in the Doppler group ($p<0.0005$). After six months, 31% of the patients in the non-Doppler group and 21% in the Doppler group reported to be completely complaint free ($p=0.313$).

In **chapter 5**, HAL was evaluated at the vascular level. This prospective study evaluated whether the beneficial effect of HAL can be attributed to a change in the macroscopic vascular anatomy at the level of the corpus cavernosum recti. Patients treated with HAL for grade II or III hemorrhoidal disease were scanned with anal colored Doppler endosonography before treatment and 6 weeks postoperatively. As part of a randomized, controlled trial (HEMARTY (**hem**orrhoidal **art**er**y** ligation) patients were either treated with or without the use of the Doppler transducer. Postoperative measurements by anal colored Doppler endosonography revealed no significant changes in the vascular anatomy compared to the preoperative measurement, independent of the use of the Doppler probe ($p>0.05$). This study showed that the beneficial effect of HAL is most likely not based on the alteration of the macroscopic vascular anatomy in the corpus cavernosum recti. Taken together, the results of chapter 4 and 5 do not support the use of Doppler during HAL.

During the HEMARTY trial we found that patients were frequently referred with an incorrect diagnosis of hemorrhoidal disease. In **chapter 6** we investigated how self-reported clinical complaints relate to the final diagnosis and whether these anamnestic parameters could facilitate a correct diagnosis. We found that 47.6% of the referred patients were incorrectly diagnosed with hemorrhoidal disease by the general physician. Our analysis revealed that if a patient complains of anal blood loss there is a probability of 67.6% that these complaints are caused by hemorrhoids. A combination of anal blood loss and prolapse resulted in a probability of 75.5% for the presence of hemorrhoidal disease. We conclude that the anamnesis provides an important clue about the nature of the anal complaint but lacks sufficient specificity to set the definite diagnosis. We therefore recommend combining the anamnesis with a physical examination of the anal area for diagnosis of putative hemorrhoidal disease.

Often, no distinction is made between internal and thrombosed anal peripheral veins (external hemorrhoids). As a consequence, these conditions are treated in the same way, which is often incorrect. Delay in setting the correct diagnosis can lead to a delay in effective treatment. In **chapter 7** we present three patients with anal complaints. In this clinical lesson we show different manifestations of hemorrhoidal disease.

General discussion

Pathophysiology and etiology

The exact cause of the development of hemorrhoidal disease is unknown. Various theories for the pathogenesis of hemorrhoidal disease have been postulated. Although increased resting anorectal pressure is deemed to be a major initiating factor, a thorough understanding of the pathogenesis is still lacking. Klink *et al.* studied hemorrhoidal tissue at the immunohistochemical level.[10] They found that patients with hemorrhoidal disease have an elevated expression of epidermal growth factor receptor (EGFR) in hemorrhoidal tissue. EGFR is involved in wound repair and is required for keratinocyte migration in wound healing. Next, higher levels of cyclo-oxygenase (COX-2) expression were found in hemorrhoidal tissue indicative of a chronic inflammatory process in the submucosal layer of hemorrhoids. Also indications of an elevated level of cell migration and proliferation were found by a significantly elevated expression of notch-3. The authors concluded that hemorrhoidal disease may be regarded a manifestation of a soft tissue disease.

Willis *et al.* reported on the alterations in the extracellular matrix in patients with hemorrhoidal disease.[11] They found reduced amounts of collagen and a decreased ratio of type I to type III collagen in these patients. This altered ratio of type I to type III collagen is known to change the geometrical arrangement and diameter of collagen fibrils, with reduced mechanical stability of connective tissue as a consequence.[12,13] This results in a reduced mechanical stability of the perivascular tissue and the anchoring connective tissue system. Willis *et al.* concluded that due to this loss of elasticity a relative outflow obstruction could occur with an increase of pressure in the arteriovenous glomerula with concomitant vascular dilatation as is seen in hemorrhoidal disease. It remains however unclear whether these biophysical changes are the cause or the result of hemorrhoids and could be the subject of further research.

The quest for the origin of hemorrhoidal disease and possible treatment options has also been the motive for detailed research to the distal anal canal at an anatomical level. The first anatomical investigations were based on dissection specimens. In the early 20th century it became clear that hemorrhoidal tissue originates from a vascular plexus that was named the corpus cavernosum recti (CCR) or plexus hemorrhoidalis.[14] This structure is situated just above the dentate line, at the segregation of intra luminal

mucosa to perianal epithelium.

Aigner *et al.* performed outstanding work in the study of the vascular anatomy of the CCR and the distal rectum.[15] They paid specific attention to the course of the supplying arteries in outer rectal wall layers and their relationship to the superior rectal artery and the corpus cavernosum recti. They carefully documented that the CCR is solely supplied by the terminal branches of the superior rectal artery. The distribution pattern of the supplying vascular structures of the CCR by the superior rectal artery was found to vary considerably. Also, the entering points of its branches into the rectal muscle layers varied considerably.

The intraluminal vascularization pattern after the entering point into the muscular layers was not studied by Aigner *et al.* due to technical difficulties and the assumption that this was of little clinical interest. For us, however, the actual intraluminal vascularisation at the level of the CCR seemed of great clinical relevance since this is the area where the problems of hemorrhoidal disease arise. Our study on the anatomy of the CCR described in chapter 3 has provided a better insight into the number, pattern and course of the intraluminal submucosal branches at the level of the CCR.[16] It revealed that the submucosal arteries only have a superficial course in the mucosa over a short length where they are in range of the ligation depth. Furthermore, we found more than 6 supplying arteries which are not necessarily bound to strict locations. This insight contributes to the understanding of why not all Doppler signals can be silenced while the procedure could be effective.

HAL

The present anatomical vascular model of the CCR has been the basis for the development of HAL. In 1995, Morinaga *et al.* postulated that ligation of the supplying arteries of the CCR would result in reduction of hemorrhoidal complaints.[1] A special ligation proctoscope with a mini-Doppler instrument was developed for HAL. This mini-Doppler transducer can locate the submucosal arteries by an audible signal and makes precise ligation possible. It was thought that, with the aid of Doppler localized ligation of the terminal branches of the superior rectal artery at the level of the CCR, blood flow would diminish and complaints subside.

Clinically the procedure is reported to be effective and is currently used as a treatment

modality for hemorrhoidal disease in many hospitals worldwide. Observations in our operating room however revealed that silencing of the Doppler signals frequently could not be established. We therefore wondered whether the arteries are actually ligated or not. In order to further elucidate the working mechanism of the HAL procedure we studied the role of the Doppler transducer in relation to the effect of the procedure. We found that ligations placed in the CCR, resulted in improvement of the hemorrhoidal condition but results were independent of the use of the Doppler guided technique. On the basis of these observations we conclude that there is no additional benefit of the use of Doppler during HAL and that Doppler may be omitted from the device. We also found that the placement of ligations in the distal rectum has no influence on the macroscopic vascular anatomy independent of the use of the Doppler transducer. We postulate that compression of the microcirculation in combination with the pexy effect of the ligation is the effective component in this treatment modality. This suggestion is supported by the results of Pakravan et al. who found that the placement of stitches in the anal canal during a transanal open hemorrhoidopexy has positive effects on the complaints of hemorrhoidal disease.[17] Further research is necessary to strengthen this theory.

HAL for various grades of hemorrhoidal disease

Is has been suggested that the ligation procedure is useful in grade I to grade IV hemorrhoidal disease.[2, 5-9, 18-29, 30-46] This seems superfluous since grade I hemorrhoidal disease can effectively be treated with conservative measures by altered diet including fiber supplement and/or a topical hemorrhoidal ointment.[47] However, Dorn *et al.* have reported excellent results using HAL for patients with grade I hemorrhoidal disease, with success rates of 92.8% after 6 months, 90% after 2 years and 84,5% after 5 years.[48] Pol *et al.* also applied the ligation procedure for grade I hemorrhoidal disease.[31] They treated patients with grade I hemorrhoids in cases of unsuccessful conservative treatment. In his cohort 61% of the patients benefited from the procedure, whereas the intervention resulted in symptom aggravation in 14% of patients. These data suggest that there may be a place for HAL in the primary treatment of grade I hemorrhoids as well as in the treatment of grade I hemorrhoids refractory to conservative measures.

The majority of the reports on HAL have involved patients with grade II and III hemorrhoidal disease. The inclusion of grade II hemorrhoids vary greatly in the studies.

For example Ratto *et al.* suggested using HAL in patients with grade II hemorrhoids when unresponsive to prior rubber band ligation or sclerotherapy.[4] As a consequence, only 7.7% of their study population involves grade II hemorrhoids, whereas the study population of Pol *et al.* consisted of 48% grade II hemorrhoid patients. Interestingly, in both studies good results for grade II hemorrhoidal disease were reported; Pol *et al.* found that 70% of the grade II patients profited from the ligation procedure and that 47% of the patients became complaint free. Ratto *et al.* found beneficial effects of HAL in 77% of the patients. Hence, it seems that the ligation procedure may also play a role in grade II patients.

All authors included grade III hemorrhoids for HAL and this therefore seems to be the core population for this procedure. Wallis de Vries *et al.* reported that 85% of the patients improved with respect to their initial grading and that disappearance of complaints was achieved in 35% of the study population.[45] Regarding long term results, Dorn *et al.* reported success rates of 53% after 6 months and 2 years, and 40% after 5 years.[48]

Initially, HAL was considered unsuitable for grade IV hemorrhoids since this condition is characterized by substantial volumes of prolapsing tissue. Results from various studies indeed revealed that residual or recurrent protrusion of hemorrhoidal tissue is the main complication after HAL in grade IV disease.[8, 23, 35, 45] However, Dal Monte *et al.* reported on the application of a modified figure-eight technique to improve results in prolapsed hemorrhoids.[8] After arterial localization, they placed a running suture with 3–5 stitches tied cranially in order to lift the prolapse and to occlude the perforating arterial branches. They postulated that the ligation with a supplemental segmental mucopexy of prolapses may be more effective in advanced hemorrhoidal disease. Since 2008 studies have been published for this variation of the standard ligation technique, which is also known as recto-anal repair (RAR).[23, 43, 49, 50] Forrest *et al.* found that 14.3% of the patients had recurrent symptoms after 6 months of follow-up with the application of the RAR technique.[50] Walega *et al.* concluded that 10% of the patients had residual symptoms at three months after RAR.[43] Although follow-up time was short, the reported results seem promising. It would appear that HAL with recto-anal repair is safe, easy to perform, and can be considered an effective treatment option for severe hemorrhoids. A more extensive study on the long-term effects of the altered procedure is however mandatory before firmer conclusions might be drawn.

Results of HAL

Various prospective and retrospective studies have shown HAL to be a safe and easy method for the treatment of hemorrhoids. With early success rates of up to 97% and reported low complication rates, it seems to be ideal.[2] These results differ from our observations as displayed in this thesis. In our retrospective study not more than 50% of the patients reported to be satisfied, whereas 32% still suffered from blood loss and 74% from prolapse complaints after a median follow up of 29 months (**chapter 2**). Furthermore, in our prospective randomized controlled trial we did not find a success rate higher than 70% during the follow-up of 6 months (**chapter 4**).[51] We postulate these differences in reported success rates to be related to a different appreciation of the objective data. Success is often defined as 'a reduction of the complaints', 'therapeutic successes', 'improvement of the complaints' or 'recurrence rates'. These definitions are vague and often not/semi- quantitative and do not always take into account the patient's perspective. The lack of one single defined outcome according to which success is measured makes it difficult to compare the results from the various studies. We feel that the patient's satisfaction after treatment should be the reference for success of the procedure, independent of the opinion of a doctor since there is no objective examination method available. Success is then determined from a patient's perspective and study results can be compared.

There is only limited information available on the long-term effects of HAL; only 5 studies have shown results after long-term (>1 year) follow-up.[3,8,46,48,52] Although these studies report success rates of 84–93%, which is significantly higher than our results, a decline in the success rate and an increase in recurrences over time is also noticed. This observation has been reported by Wilkerson *et al.*, who observed a drop in the patients' asymptomatic rate from 74 to 40% after 30 months of follow-up.[46] They concluded that the 'success rate' of the procedure decreases over time with respect to prolapse and blood loss. Unfortunately, this was not correlated with initial grading. Dorn *et al.* also tried to provide insight into the evolution of the complaint profile.[48] They concluded that the beneficial effects last longer for low grade hemorrhoidal disease. Their initial mean success rates were 80.5% after 6 months (stage I: 92.8%; stage II: 81.6%; stage III: 52.5%), 79% after 2 years (stage I: 90%; stage II: 81.6%; stage III: 52.5%), and 73.5% after 5 years (stage I: 84.5%; stage II: 80.3%; stage III: 40%). Regrettably, the

results were not related to specific symptoms. These long-term results suggest that the ligation procedure can be curative in a subset of patients but provides only partial reduction of symptoms for the majority of patients with hemorrhoidal disease.

HAL in relation to other treatment modalities

Only a few reports exist that have compared HAL with other treatment modalities for hemorrhoidal disease. In a randomized trial Bursics *et al.* compared conventional hemorrhoidectomy with HAL and found that the ligation procedure produced less postoperative pain.[5] Also, the patients could return to daily activities faster after HAL than after hemorroidectomy. One year after treatment, the results of the two procedures did not differ significantly between groups.

Giordano *et al.* randomly allocated patients with second- or third-degree hemorrhoids who failed to respond to conservative treatment to HAL versus stapled hemorrhoidectomy (SH).[53] Patients treated with HAL recovered faster and could return to daily activities sooner after treatment. Patient satisfaction ("excellent/good outcome") and recurrence rates were found to be similar in the two groups. Short-term results were also similar, although the SH procedure resulted in increased post-operative morbidity. Medium-term results demonstrated that HAL and SH have similar effectiveness.

The ligation procedure was also compared with the PPH procedure (procedure for prolapse and hemorrhoids). Festen *et al.* concluded that both PPH and HAL are safe treatments for grade III and IV hemorrhoids with acceptable complication rates and satisfactory short-term results.[24] In this study HAL was the preferred treatment because it carried similar complication rates and short-term results, but resulted in less postoperative pain when compared with PPH.

It may be concluded that HAL is equally effective in comparison to other more conventional treatment modalities. Unfortunately, a comparative study between HAL and rubber band ligation is not available; such a comparison would be of great value in decision making for treatment of the lower grades of hemorrhoidal disease, as rubber band ligation is considered the method of choice in many centers, particularly in the Netherlands.

Variations in HAL protocols

Studies on HAL have revealed quite some variation in the pre-surgery and postoperative protocols. In the preoperative phase many authors report on the administration of a rectal enema in order to clean the distal rectum.[8, 31, 33, 36, 44] Since there is no conclusive data that a rectal enema will positively affect the outcome of the procedure, the value of this preparatory action is unclear. Also, no data are available to show that the omission of an enema results in adverse effects on the procedure or outcome. The contributive value seems, therefore, debatable.

Several authors have reported the routine use of perioperative antibiotic prophylaxis (generally consisting of metronidazole with or without ceftriaxone).[23, 36, 54] In contrast, Ratto *et al.* reported not to administer antibiotics before, during or after surgery.[4] None of these reports provides any indication of aberrant incidences of infectious complications. Nonetheless, this issue requires more attention before any firm conclusions may be drawn.

Anesthesia for HAL may involve general, local or regional anesthesia, either with or without sedatives. In their randomized clinical trial, Bursics *et al.* described the progression from general anesthesia to local to even surface anesthesia.[5] They experienced that surface anesthesia is sufficiently effective for HAL. Dal Monte *et al.* reported comparably on a successful shift from general to regional anesthesia.[8] Interestingly, Ratto *et al.* used anesthesia in the opposite direction: they used regional anesthesia in the first 11 patients but used sedation with propofol supported by analgesia with remifentanil in the remaining 159 patients.[4] Unfortunately, they do not provide a rationale for this shift in protocol. At present it seems that most procedures are performed under regional or general anesthesia.

In conclusion, quite some variety still exists in the perioperative procedures involved in HAL, some of which may or may not contribute to its success or failure.

Advantages and disadvantages

Besides the reported effectiveness, attention has been paid to possible downsides of this procedure. There is a theoretical possibility that HAL might affect anorectal function

(sensoric or functional), for example by causing sphincter stretching or an alteration of the rectal wall due to the suture placement. Ratto *et al.* investigated the influence of HAL by performing a clinical assessment, anorectal manometry, rectal volumetry and endo-anal ultrasound preoperatively and 6 months postoperatively.[55] They found no significant changes of the mean values of anal manometric and rectal volumetric parameters relative to preoperative values. In addition, at 6 months both internal and external sphincters were endosonographically intact. Moreover, all patients remained able to distinguish whether anal urge was caused by gas or feces. They concluded that HAL does not adversely affect the function of the anal canal and the rectum. Walega *et al.* evaluated the effect of HAL on the rectal system by means of anal manometry. They found no significant differences in basal anal pressure, squeeze pressure, and vector volume before versus after HAL.[43, 54] However, during follow-up a decrease of anal function was recorded. Analysis of recto-anal reflex components one month after HAL showed that the procedure had decreased the speed and the amplitude of contraction. Likely this is caused by an impairment of sensory receptors of the pre-sphincteric part of the rectum in response to the stretching of the rectal wall during the procedure, possibly due to the proctoscope insertion. Fortunately, the changes in recto-anal inhibitory reflex and recto-anal reflex morphology returned to normal during follow-up, indicating that the negative influence of the ligation procedure on the ano-rectal reflectory function is transitory.

Complications of HAL are rarely reported and it appears that major complications have yet to occur. Most studies conclude that HAL is safe, easy to perform, and can be considered an attractive alternative for the treatment of symptomatic hemorrhoids. It is stated that early complications of HAL are rare and minor, and include post-operative bleeding (2.4%), urinary retention (< 1.0%), thrombosis (1.2%), fistula (<1.0%) and infection (0.5%).[49]

Conclusion

HAL may be regarded as an attractive, easy to learn and perform procedure for the treatment of hemorrhoidal disease. Studies by us and others show that patients may benefit from the procedure, although most patients develop some degree of recurrence of complaints in the long term.

The studies in this thesis reveal that in HAL, the contributory value of the Doppler transducer is highly overrated, to the extent that, in our opinion, it can safely be omitted. The existing literature reveals only limited attempts to define the role of HAL between all other available treatment entities. We therefore strongly support the execution of a broad and multi-center randomized trial on the effectiveness of HAL in relation to other standard procedures, particularly rubber band ligation.

References

1. Morinaga K, Hasuda K, Ikeda T. A novel therapy for internal hemorrhoids: Ligation of the hemorrhoidal artery with a newly devised instrument (moricorn) in conjunction with a doppler flowmeter. *Am J Gastroenterol* 1995; **90:** 610-3.
2. Sohn N, Aronoff JS, Cohen FS, Weinstein MA. Transanal hemorrhoidal dearterialization is an alternative to operative hemorrhoidectomy. *Am J Surg* 2001; **182:** 515-9.
3. Scheyer M, Antonietti E, Rollinger G, Mall H, Arnold S. Doppler-guided hemorrhoidal artery ligation. *Am J Surg* 2006; **191:** 89-93.
4. Ratto C, Donisi L, Parello A, Litta F, Doglietto GB. Evaluation of transanal hemorrhoidal dearterialization as a minimally invasive therapeutic approach to hemorrhoids. *Dis Colon Rectum* 2010; **53:** 803-11.
5. Bursics A, Morvay K, Kupcsulik P, Flautner L. Comparison of early and 1-year follow-up results of conventional hemorrhoidectomy and hemorrhoid artery ligation: A randomized study. *Int J Colorectal Dis* 2004; **19:** 176-80.
6. Greenberg R, Karin E, Avital S, Skornick Y, Werbin N. First 100 cases with doppler-guided hemorrhoidal artery ligation. *Dis Colon Rectum* 2006; **49:** 485-9.
7. Felice G, Privitera A, Ellul E, Klaumann M. Doppler-guided hemorrhoidal artery ligation: An alternative to hemorrhoidectomy. *Dis Colon Rectum* 2005 **48:** 2090-3.
8. Dal Monte PP, Tagariello C, Sarago M, Giordano P, Shafi A, Cudazzo E, *et al.* Transanal haemorrhoidal dearterialisation: Nonexcisional surgery for the treatment of haemorrhoidal disease. *Tech Coloproctol* 2007; **11:** 333,8.
9. Arnold S, Antonietti E, Rollinger G, Scheyer M. Doppler ultrasound assisted hemorrhoid artery ligation. A new therapy in symptomatic hemorrhoids. *Chirurg* 2002; **73:** 269-73.
10. Klink C, Binnebosel M, Kammer D, Willis S, Prescher A, Klinge U, *et al.* Haemorrhoids are related to changes of cell function in mucosa and submucosa. *Int J Colorectal Dis* 2009; **24:** 1389-94.
11. Willis S, Junge K, Ebrahimi R, Prescher A, Schumpelick V. Haemorrhoids - a collagen disease? *Colorectal Dis* 2010; **12:** 1249-53.
12. Fleischmajer R, Perlish JS, Burgeson RE, Shaikh-Bahai F, Timpl R. Type I and type III collagen interactions during fibrillogenesis. *Ann N Y Acad Sci* 1990; **580:** 161-75.
13. Wiedemann H, Chung E, Fujii T, Miller EJ, Kuhn K. Comparative electron-microscope studies on type-III and type-I collagens. *Eur J Biochem* 1975; **51:** 363-8.
14. Stelzner F, Staubesand J, Machleidt H. Das corpus carvernosum recti - die grundlage der inneren hämmorrhoiden. *Langenbecks Arch klein Chir* 1962; **299:** 302-312.
15. Aigner F, Bodner G, Conrad F, Mbaka G, Kreczy A, Fritsch H. The superior rectal artery and its branching pattern with regard to its clinical influence on ligation techniques for internal hemorrhoids. *Am J Surg* 2004; **187:** 102-8.
16. Schuurman JP, Go PM, Bleys RL. Anatomical branches of the superior rectal artery in the distal rectum. *Colorectal Dis* 2009; **11:** 967-71.
17. Pakravan F, Helmes C, Baeten C. Transanal open hemorrhoidopexy. *Dis Colon Rectum* 2009; **52:** 503-6.

18. Avital S, Itah R, Skornick Y, Greenberg R. Outcome of stapled hemorrhoidopexy versus doppler-guided hemorrhoidal artery ligation for grade III hemorrhoids. *Tech Coloproctol* 2011; **15:** 267-71.
19. Cantero R, Balibrea JM, Ferrigni C, Sanz M, Garcia Perez JC, Perez R, *et al.* Doppler-guided transanal haemorrhoidal dearterialisation. an alternative treatment for haemorrhoids. *Cir Esp* 2008; **83:** 252-5.
20. Charua Guindic L, Fonseca Munoz E, Garcia Perez NJ, Osorio Hernandez RM, Navarrete Cruces T, Avendano Espinosa O, *et al.* Hemorrhoidal desarterialization guided by doppler. A surgical alternative in hemorrhoidal disease management. *Rev Gastroenterol Mex* 2004; **69:** 83-7.
21. Conaghan P, Farouk R. Doppler-guided hemorrhoid artery ligation reduces the need for conventional hemorrhoid surgery in patients who fail rubber band ligation treatment. *Dis Colon Rectum* 2009; **52:** 127-30.
22. de Parades V, Faucheron JL. Doppler-guided hemorrhoidal artery ligation: The new deal of surgical treatment of hemorrhoids. *Gastroenterol Clin Biol* 2008; **32:** 660-3.
23. Faucheron JL, Poncet G, Voirin D, Badic B, Gangner Y. Doppler-guided hemorrhoidal artery ligation and rectoanal repair (HAL-RAR) for the treatment of grade IV hemorrhoids: Long-term results in 100 consecutive patients. *Dis Colon Rectum* 2011; **54:** 226-31.
24. Festen S, van Hoogstraten MJ, van Geloven AA, Gerhards MF. Treatment of grade III and IV haemorrhoidal disease with PPH or THD. A randomized trial on postoperative complications and short-term results. *Int J Colorectal Dis* 2009; **24:** 1401-5.
25. Greenspon J, Williams SB, Young HA, Orkin BA. Thrombosed external hemorrhoids: Outcome after conservative or surgical management. *Dis Colon Rectum* 2004; **47:** 1493-8.
26. Gupta PJ. Transanal haemorrhoidal dearterialization. *Tech Coloproctol* 2008; **12:** 138-340.
27. Infantino A. Transanal haemorrhoidal artery echodoppler ligation and anopexy (THD) is effective for II and III degree haemorrhoids. A prospective multicentre study. *Colorectal Dis* 2010; **12:** 1274,1318.2010.02418.x.
28. Jongen J, Peleikis HG. Doppler-guided hemorrhoidal artery ligation: An alternative to hemorrhoidectomy. *Dis Colon Rectum* 2006; **49:** 1082-3.
29. Karin E, Avital S, Dotan I, Skornick Y, Greenberg R. Doppler guided haemorrhoidal artery ligation in patients with crohn's disease. *Colorectal Dis* 2012; **14:** 111-4.
30. Narro JL. Hemorrhoid therapy with doppler guided hemorrhoidal artery ligation via proctoscope KM-25. A new alternative to hemorrhoidectomy and rubber band ligation? *Zentralbl Chir* 2004; **129:** 208-10.
31. Pol RA, van der Zwet WC, Hoornenborg D, Makkinga B, Kaijser M, Eeftinck Schattenkerk M, *et al.* Results of 244 consecutive patients with hemorrhoids treated with doppler-guided hemorrhoidal artery ligation. *Dig Surg* 2010; **27:** 279-84.
32. Qin PP, Huang B, Cai HJ, Ge Q, Wang ZL. A prospective controlled comparative study of doppler-guided hemorrhoidal artery ligation versus operative procedures for prolapse and hemorrhoids. *Zhonghua Yi Xue Za Zhi* 2010; **90:** 3131-4.
33. Ramirez JM, Aguilella V, Elia M, Gracia JA, Martinez M. Doppler-guided hemorrhoidal artery ligation in the management of symptomatic hemorrhoids. *Rev Esp Enferm Dig* 2005; **97:** 97-

103.

34. Ratto C, Donisi L, Parello A, Litta F, Doglietto GB. Evaluation of transanal hemorrhoidal dearterialization as a minimally invasive therapeutic approach to hemorrhoids. *Dis Colon Rectum* 2010; **53:** 803-11.

35. Scheyer M. Doppler-guided recto-anal repair: A new minimally invasive treatment of hemorrhoidal disease of all grades according to scheyer and arnold. *Gastroenterol Clin Biol* 2008; **32:** 664.

36. Spyridakis M, Christodoulidis G, Symeonidis D, Dimas D, Diamantis A, Polychronopoulou E, *et al.* Outcomes of doppler-guided hemorrhoid artery ligation: Analysis of 90 consecutive patients. *Tech Coloproctol* 2011; **15:** S21-4.

37. Tagariello C, Dal Monte PP, Sarago M. Doppler-guided transanal haemorrhoidal dearterialisation. *Chir Ital* 2004; ***56:*** 693-7.

38. Szmulowicz UM, Gurland B, Garofalo T, Zutshi M. Doppler-guided hemorrhoidal artery ligation: The experience of a single institution. *J Gastrointest Surg* 2011; **15:** 803-8.

39. Teo JY, Kam MH, Eu KW. Letter to the editor on the article "treatment of grade III and IV haemorrhoidal disease with PPH or THD. A randomized trial on postoperative complications and short-term results". *Int J Colorectal Dis* 2010; **25:** 1385.

40. Testa A, Torino G. Doppler-guided hemorrhoidal artery ligation (DG-HAL): A safe treatment of II-III degree hemorrhoids for all patients. could it be potentially also good prophylaxis? *Minerva Chir* 2010; **65:** 259-65.

41. Tirone A, Vuolo G, Gaggelli I, Francioli N, D'Onofrio P, Quarta S, *et al.* Transanal haemorridal dearterialisation: Personal experience. *Ann Ital Chir* 2010; **81:** 311-3.

42. Underwood TJ, Brent A, Nash GF. Haemorrhoidal artery ligation operation for the treatment of symptomatic anorectal varices. *Colorectal Dis* 2010; **12:** 148-9.

43. Walega P, Krokowicz P, Romaniszyn M, Kenig J, Salowka J, Nowakowski M, *et al.* Doppler guided haemorrhoidal arterial ligation with recto-anal-repair (RAR) for the treatment of advanced haemorrhoidal disease. *Colorectal Dis* 2010; **12:** e326-9.

44. Walega P, Scheyer M, Arnold S, Kenig J, Nowakowski M, Sobocki J, *et al.* Selective doppler-guided hemorrhoidal artery ligation as a minimaly invasive method of treatment of hemorrhoidal disease. *Przegl Lek* 2009; **66:** 122-5.

45. Wallis de Vries BM, van der Beek ES, de Wijkerslooth LR, van der Zwet WC, van der Hoeven JA, Eeftinck Schattenkerk M, *et al.* Treatment of grade 2 and 3 hemorrhoids with doppler-guided hemorrhoidal artery ligation. *Dig Surg* 2007; **24:** 436-40.

46. Wilkerson PM, Strbac M, Reece-Smith H, Middleton SB. Doppler-guided haemorrhoidal artery ligation: Long-term outcome and patient satisfaction. *Colorectal Dis* 2009; **11:** 394-400.

47. Kaidar-Person O, Person B, Wexner SD. Hemorrhoidal disease: A comprehensive review. *J Am Coll Surg* 2007; **204:** 102-17.

48. Dorn HU, Mory M. 5 Jahre HAL: Erfahrungen und langzeitenergebnisse. *Coloproctology* 2007; **29:** 205–210.

49. Theodoropoulos GE, Sevrisarianos N, Papaconstantinou J, Panoussopoulos SG, Dardamanis D, Stamopoulos P, *et al.* Doppler-guided haemorrhoidal artery ligation, rectoanal repair, sutured

haemorrhoidopexy and minimal mucocutaneous excision for grades III-IV haemorrhoids: A multicenter prospective study of safety and efficacy. *Colorectal Dis* 2010; **12:** 125-34.

50. Forrest NP, Mullerat J, Evans C, Middleton SB. Doppler-guided haemorrhoidal artery ligation with recto anal repair: A new technique for the treatment of symptomatic haemorrhoids. *Int J Colorectal Dis* 2010; **25:** 1251-6.
51. Schuurman JP, Rinkes IH, Go PM. Hemorrhoidal artery ligation procedure with or without doppler transducer in grade II and III hemorrhoidal disease: A blinded randomized clinical trial. *Ann Surg* 2012; **255:** 840-5.
52. Faucheron JL, Gangner Y. Doppler-guided hemorrhoidal artery ligation for the treatment of symptomatic hemorrhoids: Early and three-year follow-up results in 100 consecutive patients. *Dis Colon Rectum* 2008; **51:** 945-9.
53. Giordano P, Nastro P, Davies A, Gravante G. Prospective evaluation of stapled haemorrhoidopexy versus transanal haemorrhoidal dearterialisation for stage II and III haemorrhoids: Three-year outcomes. *Tech Coloproctol* 2011; **15:** 67-73.
54. Walega P, Scheyer M, Kenig J, Herman RM, Arnold S, Nowak M, *et al.* Two-center experience in the treatment of hemorrhoidal disease using doppler-guided hemorrhoidal artery ligation: Functional results after 1-year follow-up. *Surg Endosc* 2008; **22:** 2379-83.
55. Ratto C, Parello A, Donisi L, Litta F, Doglietto GB. Anorectal physiology is not changed following transanal haemorrhoidal dearterialization for haemorrhoidal disease: Clinical, manometric and endosonographic features. *Colorectal Dis* 2011; **13:** e243-5.

9

Summary in Dutch
Samenvatting in het Nederlands

9

Summary in Dutch
Samenvatting in het Nederlands

Hemorroïden, oftewel aambeien in het Nederlands, is een veel voorkomende aandoening die veroorzaakt wordt door het niet goed functioneren van vaat- en bindweefselstructuren in het laatste deel van de endeldarm. Hierdoor kunnen klachten van bloedverlies en het gevoel van uitstulpen van weefsel uit de anus ontstaan. Dit gebeurt voornamelijk na of tijdens de ontlasting.

In de afgelopen decennia zijn er diverse behandelmogelijkheden voor aambeien ontwikkeld. Omdat het niet helemaal duidelijk is waardoor aambeien ontstaan, blijft het moeilijk om de aandoening te voorkomen en goed te behandelen. Als gevolg van de doorgaande zoektocht naar nieuwe behandelingen wordt er eens in de zoveel tijd een nieuwe behandeling ontwikkeld. Een voorbeeld hiervan is de hemorroïd arterie ligatie procedure die in 1995 voor het eerst werd beschreven door Dr. Morinaga uit Japan. In de medische literatuur is de behandeling vooral bekend onder de naam HAL (hemorroïd arterie ligatie) of THD (transanale hemorroïd dearterialisatie). Vanaf het jaar 2000 genoot deze behandeling wereldwijd steeds meer bekendheid en verschenen de eerste publicaties over de resultaten van deze behandeling. In de jaren die daarop volgden verschenen nog vele publicaties. Het bleef echter onduidelijk wat het precieze effect van deze vorm van behandeling is en wat het werkzame principe van HAL is.

Het achterliggende idee van HAL is om de toevoerende slagadertjes naar het aambeiweefsel af te binden met hechtingen. Hierdoor wordt het aambeiweefsel kleiner waardoor de klachten van bloedverlies en uitstulpingen kunnen afnemen. Om de hechtingen op de goede plek te kunnen zetten is een speciale proctoscoop (anuskijker) ontwikkeld waar een kleine Doppler-transducer (echoapparaatje) is ingebouwd. Met de Doppler-transducer is de chirurg in staat om de bloedstroom van slagadertjes hoorbaar te maken en daarmee de locatie van de slagadertjes te bepalen. Met deze proctoscoop kan de chirurg dus in de endeldarm van een patiënt kijken en tegelijkertijd, door het echoapparaatje langs de rand van de endeldarm te laten gaan, horen waar de bloedvaten

zich bevinden. Door een speciaal daarvoor gemaakte opening in de proctoscoop kan de chirurg dan een hechting in de wand van de endeldarm plaatsen om het slagadertje te onderbinden. Na het controleren van de hele rand van de endeldarm op Doppler signalen en het plaatsten van ongeveer zes hechtingen is de procedure klaar en kan de patiënt wakker worden en vaak snel weer naar huis.

In dit proefschrift hebben we onderzocht of het gebruik van de Doppler-transducer bijdraagt aan het verminderen van klachten, die door aambeien veroorzaakt worden.

In **hoofdstuk 2** wordt beschreven hoe het met de patiënten gaat die eerder werden behandeld voor hun aambeien door middel van HAL. In de follow-up periode van 30 maanden heeft 32% van de patiënten die voor het eerst voor aambeien werden behandeld middels HAL geen verdere behandeling meer ondergaan om klachten te verlichten. De rest van de patiënten (68%) ondergingen HAL als aanvulling op een eerdere aambei-behandeling of ondergingen na HAL nog aanvullende behandelingen. Aan het einde van de follow-up van 30 maanden rapporteerde 32% van alle patiënten nog klachten van bloedverlies te hebben en 74% van alle patiënten rapporteerde nog last van uitstulpingen uit de anus te hebben. Wel kon worden geconcludeerd dat 42% van alle patiënten volledig of bijna volledig tevreden waren met de resultaten. Op basis van deze resultaten concludeerden we dat HAL effectief kan zijn maar dat HAL waarschijnlijk niet effectief genoeg is om voor altijd van de klachten af te komen.

In **hoofdstuk 3** van dit proefschrift is de vaatanatomie (vasculaire anatomie) van het anale kanaal onderzocht en dan voornamelijk van het gebied waar de aambeien uit ontstaan. Er zijn al verschillende studies geweest waarin de bloedtoevoer naar het aambei weefsel onderzocht werd, maar er waren nog geen studies die op een goede manier de bloedvaten aan de binnenkant van de endeldarm hebben laten zien. In deze anatomische studie is door middel van een speciale methode met vloeibaar plastic getoond hoe de bloedvaten in het laatste stukje van de dikke darm verlopen. We concludeerden dat er tal van kleine slagadertjes vlak onder het slijmvlies lopen zonder dat deze strict gebonden zijn aan een vast verloop. Ook zagen we dat de bloedvaatjes waarschijnlijk niet goed bereikbaar zijn voor de hechtingen die geplaatst kunnen

worden met de proctoscoop. Deze bevindingen hebben een nieuw licht geworpen op de vaatanatomie van het rectum welke van belang is voor chirurgische behandeling in dat gebied.

In **hoofdstuk 4** worden de resultaten beschreven van een studie waarin werd onderzocht of de Doppler-transducer een toegevoegde waarde heeft voor het resultaat van HAL of dat HAL ook uitgevoerd kan worden zonder Doppler-transducer. We vergeleken de resultaten van patiënten die werden behandeld door middel van Doppler-geleide geplaatste hechtingen (Doppler groep) met de resultaten van patiënten bij wie er op willekeurige plaatsen hechtingen in het aambeiweefsel werden gezet zonder het gebruik van de Doppler-transducer (non-Doppler groep). De resultaten van dit onderzoek laten zien dat in beide groepen een vermindering van klachten (bloedverlies, pijn, uitstulpingen, ontlastingsproblemen en ongemak in het dagelijkse leven) werd bereikt. In de non-Doppler groep was er echter een significant betere vermindering van de uitstulpingsklachten dan in de Doppler groep. Ook bleek dat de patiënten in de non-Doppler groep minder postoperatieve complicaties hadden. Daarnaast bleken de patiënten uit de non-Doppler groep (hoewel niet statistisch significant) meer tevreden met de resultaten dan de patiënten die met een Doppler-transducer waren behandeld. We concludeerden dan ook dat het plaatsen van hechtingen effectief is, maar dat het gebruik van de Doppler-transducer bij het plaatsen van de hechtingen de resultaten niet verbetert. Zonder hier verder onderzoek naar te hebben gedaan denken we dat het positieve effect van het plaatsen van hechtingen wordt veroorzaakt door de druk die wordt uitgeoefend op mini-bloedvaatjes in het aambeigebied. De plaats waar deze druk wordt uitgeoefend lijkt dan niet zoveel uit te maken.

In **hoofdstuk 5** worden de resultaten beschreven van een studie waarin de vaatanatomie van patiënten uit de Doppler en de non-Doppler groep worden vergeleken. In dit onderzoek is in het aambeiweefsel zowel voor als na de operatie het aantal en de diameter van bloedvaatjes op 3 niveaus in de endeldarm gemeten. De waarden die in beide groepen na de operatie gemeten zijn blijken niet te verschillen van de waarden die gemeten zijn voor de operatie. We concludeerden hieruit dat het plaatsen van hechtingen met of zonder Doppler-transducer geen verandering in de vaatanatomie

veroorzaakt. Eerder concludeerden we al dat HAL effectief kan zijn. De effectiviteit lijkt echter niet gebaseerd te zijn op een verandering van de vaatvoorziening van het laatste stukje van de endeldarm.

Bij het verzamelen van de patiënten voor de studie beschreven in hoofdstuk 4 werd duidelijk dat veel patiënten worden verwezen naar het ziekenhuis met vermeende aambeien terwijl de anale klacht in veel gevallen door iets anders wordt veroorzaakt. In **hoofdstuk 6** wordt beschreven dat de diagnose 'aambeien' in ongeveer de helft van de patiënten die door de huisarts verwezen wordt niet juist is. Bij veel van de patiënten ging het om huiduitstulpinkjes en/of scheurtjes bij de anus in plaats van dat er sprake was van aambeien. Het werd duidelijk dat veel patiënten werden verwezen zonder dat de huisarts daadwerkelijk had gekeken naar het anale gebied. Daarom evalueerden we de positief voorspellende waarde van de informatie die een patiënt aan een huisarts vertelt voor het vaststellen van de diagnose 'aambeien'. Het blijkt dat het goed inschatten van de daadwerkelijke oorzaak van de anale klachten moeilijk is op basis van een anamnese. We concludeerden dan ook dat de anamnese een belangrijk middel is maar dat een goed lichamelijk onderzoek van de anale regio onontbeerlijk is voor het goed kunnen vaststellen van de onderliggende aandoening van een anale klacht.

In **hoofdstuk 7** worden drie patiëntcasus beschreven die zich met verschillende vormen van aambeien presenteerden in het ziekenhuis. In deze klinische les wordt de achtergrond en het verschil tussen interne en getromboseerde peri-anale randvene (vaak externe aambeien genoemd) verduidelijkt en worden er aanwijzingen gegeven om de oorzaak van de anale klacht beter te kunnen interpreteren.

10

Review committee
Publications
Dankwoord
Curriculum vitae

Review committee

Prof. dr. L.M.A. Akkermans
Department of Gastrointestinal Surgery
University Medical Center Utrecht
Utrecht, the Netherlands

Prof. dr. C.G.M.I. Baeten
Department of Colorectal Surgery
University Medical Center Maastricht
Maastricht, the Netherlands

Prof. dr. R.L.A.W. Bleys
Department of Anatomy
University Medical Center Utrecht
Utrecht, the Netherlands

Prof. dr. R. van Hillegersberg
Department of Surgical oncology and endocrine Surgery
University Medical Center Utrecht
Utrecht, the Netherlands

Prof. dr. P.D. Siersema
Department of Gastroenterology
University Medical Center Utrecht
Utrecht, the Netherlands