Clinical communications

Anomalous pulmonary venous drainage associated with mitral valve disease

*Albert V. G. Bruschke, M.D.**
*Antoine Bloch, M.D.***
Utrecht, The Netherlands

The association of anomalous pulmonary venous drainage with mitral valve disease has rarely been reported. In the literature only 14 publications[1-14] dealing with 19 cases could be found. In 17 of these cases the anomalous pulmonary venous return was associated with stenosis of the mitral valve. In only 2 cases[13,14] was slight or mild mitral regurgitation noted; cases with severe mitral insufficiency were not published. (A case published by Töply[15] has been cited,[1] but this case actually represents mitral valve disease with an anomalous superior caval vein.)

From a review of 943 cases of mitral valve disease and 70 cases of anomalous pulmonary venous return studied in our department, a combination of both conditions was found in a total of 4 cases. This might lead one to suggest that this syndrome is less rare than would be expected from the literature. In 2 of our cases a mitral stenosis was found, and in the other 2 cases severe mitral insufficiency as well was found.

It is the purpose of this paper to describe the diagnostic features that led up to the recognition of this syndrome, discussing the hemodynamic consequences with particular respect to the so-called "safety valve" mechanism of the anomalous pulmonary venous connection.

Case reports

Case 1. A 34-year-old fireman was admitted to the hospital in June, 1964. He complained of slight dyspnea on exertion of several years duration. For the last 2 years he noticed that the dyspneic symptoms had got worse with the onset of some episodes of vertigo, palpitations, and hemoptysis. He had no history of rheumatic fever.

The physical examination showed no signs of congestive heart failure. Auscultation revealed a loud first mitral sound, a mitral opening snap, and an apical diastolic rumble with presystolic accentuation. The second sound was split normally, the pulmonary component being accentuated. Along the left sternal border a faint systolic murmur was detected.

The electrocardiogram and vectorcardiogram showed a pattern of marked right ventricular and left atrial hypertrophy.

The chest roentgenogram (Fig. 1) showed a slightly enlarged cardiac silhouette with a prominent main pulmonary artery and an increased central pulmonary vasculature, confined mainly to the right side.

On right heart catheterization (Table I) anomalous pulmonary veins of the right middle and right upper lobes were entered from the superior caval vein. The pulmonary capillary pressure in the right upper lobe equalled the right atrial pressure, whereas the wedge pressure in the right lower lobe

From the Department of Cardiology of the St. Antonius Hospital, Utrecht, The Netherlands.
Received for publication August 27, 1968.
*Reprint requests to: Dr. Bruschke, Department of Cardiology, St. Antonius Ziekenhuis, Jan Van Scorelstraat 2, Utrecht, The Netherlands.
**Present address: Hôpital Cantonal, Clinique médicale universitaire, Genève, Switzerland.

Table I. *Catheterization data*

Location	Case 1		Case 2 (Nov., 1956)		Case 2 (Dec., 1959)		Case 3		Case 4	
	Pressures (mm. Hg)	O_2 sat. (%)	Pressures (mm. Hg)	O_2 sat. (%)	Pressures (mm. Hg)	O_2 sat. (%)	Pressures (mm. Hg)	O_2 sat. (%)	Pressures (mm. Hg)	O_2 sat. (%)
Pulmonary capillary										
Right upper lobe	(6)		(5)				(9)			
Right middle lobe	(7)		(12)							
Right lower lobe	(20)				(8)		(24)		53/20(37)	
Left lung					(8)					
Pulmonary artery	67/22(42)	79.3	36/10(18)	67.5	33/6(15)	81.2	45/18(30)	78.1	87/28(51)	71.2
Right ventricle	67/6	79.1	38/3	65.5	33/0	82.0	50/5	78.5	91/4	
Right atrium	(5)	80.5	(4)	66.7	(0)	81.4	(10)		(6)	
Superior caval vein (low)						82.5		81.0		
Superior caval vein (high)				61.0				69.6		
Innominate vein		67.0				73.8				
Inferior caval vein		68.2		83.8		78.0		74.6		
Anomalous pulmonary vein		94.1				100		98.0	72	72.9
Brachial artery		95.8		96.2						
Aorta							150/90	98.8	120/74	96.0
Left ventricle							150/6		118/2	
O_2 capacity (vol. %)	19.7		18.1		17.6		19.2		18.4	
O_2 consumption (ml./min.)	250		210		230		190		260	
Pulmonary flow (L./min.)	7.6				7.0		4.8			
Systemic flow (L./min.)	4.5				5.5		3.7			
Left-to-right shunt (L./min.)	3.1				1.5		1.1			
Vascular resistence, normally draining lung tissue (dynes sec. cm.$^{-5}$)	392				102		129			
Vascular resistence, anomalously draining lung tissue (dynes sec. cm.$^{-5}$)	950				800		1456			
Mitral valve area (cm.^{2})	1.2				2.2					

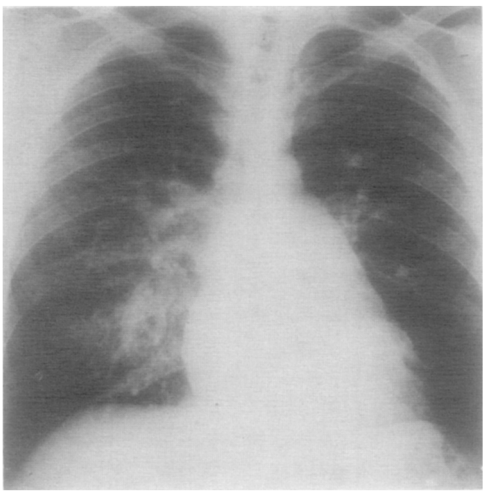

Fig. *1*. Case 1. Chest roentgenogram. Increased pulmonary vasculature mainly confined to right side.

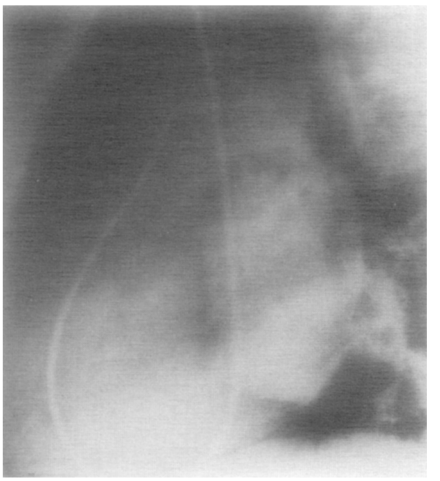

Fig. *2*. Case 2. Pulmonary angiogram. Left atrial and left ventricular filling; diastolic phase. The mitral valve appears to be severely stenotic.

was elevated. A left-to-right shunt was demonstrated by oxymetry. On the basis of the catheterization data, a diagnosis was made of mitral stenosis associated with anomalous drainage of the right upper and middle lobes.

The patient refused surgical intervention and his condition is reported to be essentially unchanged at the present time.

Case 2. A 43-year-old laborer with a clinical picture of mitral stenosis was admitted in November, 1956. He had no history of rheumatic fever. The catheterization data (Table I) indicated a mitral stenosis of such a mild degree that it did not warrant surgical intervention at this time. In November, 1959, he was readmitted, complaining of a marked increase in the dyspneic symptoms and syncopal attacks.

The physical examination showed no signs of congestive heart failure. The cardiac rhythm was irregular, ± 86 per minute. The first mitral sound was moderately accentuated and at the apex a mitral opening snap and a diastolic rumble were heard. There was no systolic murmur and the second sound was split normally.

The electrocardiogram demonstrated atrial fibrillation, but apart from that it was within the normal limits.

The chest roentgenogram showed a typical mitral configuration of the heart and a moderately increased pulmonary vasculature on both sides.

In December, 1959, a second right-heart catheterization was performed (Table I). On this occasion an anomalous pulmonary vein of the right upper lobe was entered from the superior caval vein. Oxymetry demonstrated a left-to-right shunt at this level. A diagnosis was made of mild mitral stenosis associated with anomalous pulmonary venous return.

Subsequently, the patient sustained an arterial embolism in one lower extremity, for which an embolectomy was performed.

In January, 1960, a third right-heart catheterization was performed which yielded practically identical results as the previous one of December, 1959.

A pulmonary angiogram (Fig. 2) suggested a tight mitral stenosis contradicting the catheterization data. It was noted that only a very faint reopacification of the pulmonary artery could be seen, indicating a small shunt volume.

At operation in March, 1960, a large anomalous pulmonary vein draining a portion of the right upper lobe and entering the superior caval vein was noted. The other pulmonary veins drained normally. The mitral valve orifice at the time of surgery was estimated to be less than 0.8 cm.^{2}. A closed commissurotomy and resection of the anomalously draining lung segment were performed.

The postoperative course was complicated by the development of hemorrhagic infarction of the right upper lobe. In a suicide attempt in April, 1960, the patient sustained a chest trauma resulting in a hematoma which ruptured into a bronchus and the pleural cavity, causing empyema. A lobectomy was performed but this could not prevent the onset of septicemia with highly resistent staphylococci, as a result of which the patient died in August, 1960.

On autopsy a well-opened mitral valve was found. It could not be determined with certainty whether the mitral stenosis had been of rheumatic or of congenital origin.

COMMENT. In this case of mitral stenosis associated with partial anomalous venous return of the right upper lobe, a striking discrepancy between the calculated mitral valve orifice and the findings at operation was noted. A careful review of the catheterization data of December, 1959, and January, 1960, offered no definite solution to the problem. As the calculation of the shunt volume may be considered to be most liable to error, it could be expected that in reality the shunt volume was larger and consequently the systemic flow lower than was

calculated, which would result in a narrower mitral valve. However, the angiogram and thorax roentgenogram both corroborated the calculation of a low shunt volume.

The only reasonable explanation seems to be, therefore, that the systemic flow, as well as the pulmonary flow, were lower than had been calculated, which could have been due to incorrect measurement of the oxygen consumption. (The oxygen consumption was accurately measured in December, 1959, but merely estimated in January, 1960).

Case 3. In September, 1965, a 33-year-old housewife was admitted with a history of rheumatic fever in 1944. For the last 5 years she had progressive symptoms of dyspnea and easy fatigability.

On physical examination a moderately elevated jugular venous pressure was found, the liver was not enlarged, and there was no edema. Auscultation revealed an apical holosystolic murmur Grade 3/6 and a third heart sound, with a middiastolic murmur. The splitting of the second sound was wide and fixed, with accentuation of the pulmonary component. A Grade 1/6 pulmonary systolic murmur was also noted.

The chest roentgenogram demonstrated left-sided cardiac enlargement and marked dilatation of the left atrium. The central pulmonary vasculature was increased.

The electrocardiogram and vectorcardiogram showed a pattern of right ventricular hypertrophy, left atrial hypertrophy, and left ventricular strain.

At cardiac catheterization (Table I) an anomalous pulmonary vein of the right upper lobe was entered from the superior caval vein. A left-to-right shunt was demonstrated by hydrogen curves and oxymetry. The pulmonary capillary pressure was markedly elevated in the right lower lobe and equalled the right atrial pressure in the right upper lobe.

A left ventricular angiogram revealed a severe mitral regurgitation. A preoperative diagnosis was made of severe mitral stenosis and insufficiency with abnormal venous return of the right upper lobe.

At operation in May, 1966, a fibrosed mitral valve was replaced with a Starr-Edwards prosthesis. A large pulmonary vein which extended from the right upper lobe and drained into the superior caval vein was detected. Attempts to anastomose this vein to the left atrium were unsuccessful. The artery to the apical segment was ligated, after which the shunt was practically completely abolished. (This was demonstrated by oxygen samples taken on the operation table.)

The postoperative course was characterized by abnormal bleeding and renal shutdown. As a result of this, the patient died 15 days after operation.

Case 4. A 30-year-old secretary was known to have mitral valve disease since an episode of rheumatic fever in 1958. After a full-term spontaneous delivery of a normal infant in November, 1965, she had become markedly dyspneic. This improved significantly after diuretics and digoxin administration. At the time of her admission in January, 1966, she was virtually symptom free.

On physical examination an accentuation of the first mitral sound and a mitral opening snap was noted. An apical diastolic rumble with presystolic accentuation and a holosystolic murmur Grade 3/6 was heard. The second pulmonic sound was loud and not split. The liver extended two fingerbreadths below the right costal margin but was not tender on palpation. The jugular venous pressure was not elevated and there was no edema.

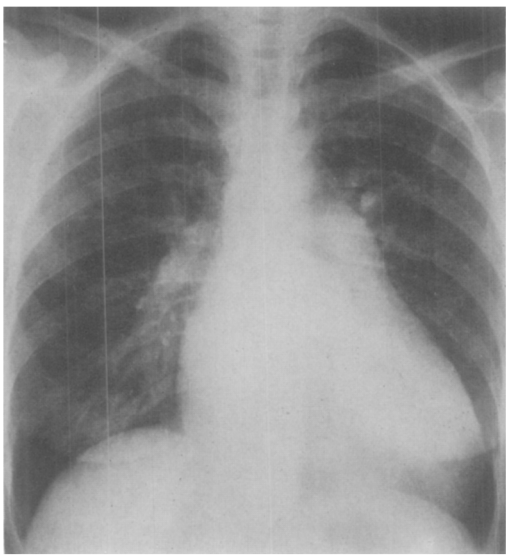

Fig. 3. Case 4. Chest roentgenogram. No evidence of abnormal vasculature of left upper lung field.

The chest roentgenogram (Fig. 3) demonstrated left ventricular and left atrial enlargement. The main pulmonary artery was prominent and the central pulmonary vasculature was increased equally on both sides.

The electrocardiogram and vectorcardiogram showed a pattern of biventricular and biatrial hypertrophy.

At cardiac catheterization (Table I) a left-to-right shunt at the level of the left innominate vein was demonstrated by hydrogen curves. An anomalous pulmonary vein, with an oxygen saturation only slightly higher than the pulmonary artery, was entered easily from the left innominate vein. The relatively low oxygen saturation was rather surprising but was attributed to coexisting pulmonary arteriovenous shunts. Confirmation of this rare coincidence was obtained by a pulmonary angiogram (Fig. 4). Because of the minimal difference in oxygen saturation between the pulmonary artery and the anomalous pulmonary vein, the calculation of the shunt and subsequent calculation of pulmonary vascular resistances could not be performed with satisfactory accuracy.

A left ventricular angiogram demonstrated a stenotic calcified mitral valve and severe mitral regurgitation.

A diagnosis was made of severe calcific mitral stenosis and insufficiency associated with anomalous drainage and arteriovenous shunts of the left upper lung field.

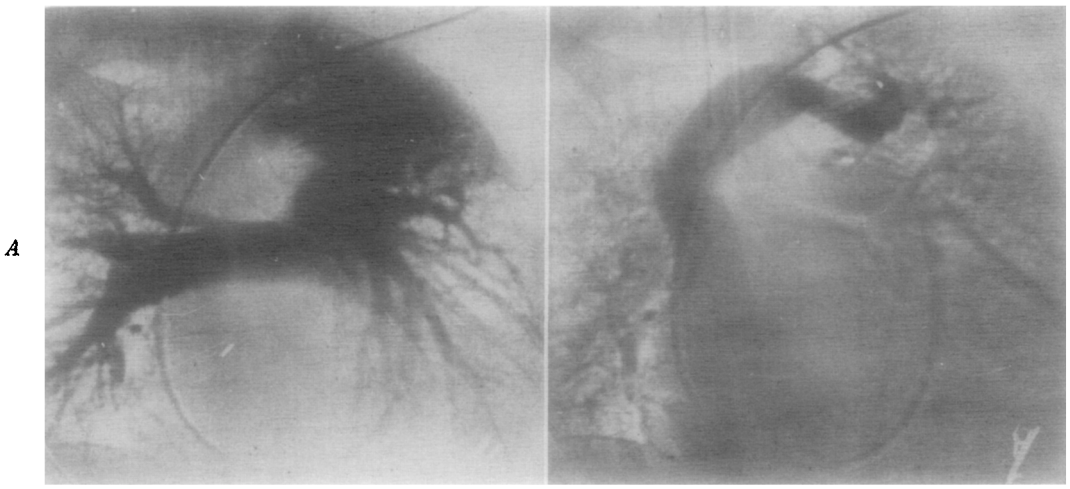

Fig. 4, *A* and *B*. Case 4. Pulmonary angiogram (subtraction technique). *A*, Abnormal vasculature of left upper lung field with early drainage into left innominate vein and *B*, subsequent opacification of superior caval vein and right atrium.

In 1966 and 1967, the patient went through several periods of decompensation and supraventricular tachycardia. In November, 1967, she had become severely decompensated and was admitted to a hospital elsewhere. Two weeks after admission her condition was complicated by a cerebrovascular accident and she died suddenly in November, 1967. An autopsy was not performed.

Discussion

In Cases 1 and 2, partial anomalous pulmonary venous return was associated with tight mitral stenosis. In Cases 3 and 4, severe mitral insufficiency was also found. Case 4 represents the first reported case in which a combination with pulmonary arteriovenous shunts were demonstrated as well.

The material of this study has been taken from the records of patients with mitral valve disease and those with anomalous pulmonary venous return who have been admitted to our department for cardiac catheterization from January, 1956, to December, 1967. This material comprises 943 cases of mitral valve disease and 70 cases of anomalous pulmonary venous return; as a combination of both conditions was found in 4 cases, the association was present in 0.42 per cent of the cases of mitral valve disease and 5.7 per cent of the patients with anomalous pulmonary venous return.

It is remarkable that, although anomalous pulmonary venous return is associated in the majority of cases with atrial septal defect, in all our cases and in the cases reported in the literature,[1-14] the atrial septum was found intact.

Diagnostic features. Physical examination usually reveals signs of mitral valve disease only. It is true that a pulmonary systolic murmur may often be heard, but this cannot be considered to be typical for a combination with anomalous pulmonary venous return. The electrocardiographical findings did not substantially contribute to the diagnosis.

Specific changes of the chest roentgenogram have been reported in only a few cases. In a case described by Warembourg and associates,[8] the anomalous pulmonary vein could be seen on the plain chest roentgenogram. Aldridge and Wigle[12] noted in one case an increased pulmonary vasculature which was confined to the anomalously draining part, the same being discovered in Case 1 (Fig. 1) of our series. In Cases 2, 3, and 4, no characteristic changes of the chest roentgenogram were observed, which is worth particular note in the case with pulmonary arterial venous shunts (Case 4, Fig. 3). The diagnosis was established in all the cases at cardiac catheterization by the following findings: (1) a left-to-right shunt at the superior caval level;

(2) pulmonary capillary pressures equalling right atrial pressure in the anomalously draining segments, in combination with higher capillary pressures (equalling left atrial pressure) in the normally draining segments; and (3) probing of the anomalous pulmonary vein of veins.

The hydrogen electrode system proved to be a very sensitive and simple means of detecting and localizing the left-to-right shunt,* which actually led to a correct diagnosis in Cases 3 and 4. The disadvangage of this method of not yielding quantitative data can be overcome by performing oxymetry or dye dilution studies[17] in "positive" cases. The finding of different pulmonary capillary pressures is highly suggestive of the syndrome but cannot be considered as conclusive since the same finding may occur in cases of triatrial heart or stenosis of a pulmonary vein.

Hemodynamic features. The anomalous pulmonary venous connection has been assumed by various sources to function as a safety valve, thus allowing the pulmonary blood to drain via a low-resistance by-pass into the right atrium. In this respect the pathophysiology has been regarded to be essentially the same as in the Lutembacher syndrome.[13] A number of arguments have been put forward to substantiate this concept. Varnauskas and associates[10] demonstrated in a case a rise of the pulmonary arterial pressure after occlusion of the pulmonary artery on the anomalously draining side at cardiac catheterization. However, only a small pressure increase was observed, which indicates limited hemodynamic importance.

The observation of Bland and Sweet[18] in 1949, that in cases of mitral stenosis the clinical condition could be improved when a pulmonary vein was anastomosed with the azygos vein, has also been regarded as proof of the safety valve mechanism.[13] It may be noted that the longest follow-up in the paper from which this conclusion was drawn was only one year and therefore this statement is open to criticism. The large flow through the anomalously draining lung tissue could well lead to a rise of the vascular resistance and as a result of this a limitation of the shunt.

High vascular resistances of the anomalously draining lung tissue and consequently unimportant safety valve function was observed by Lendrum and Lichtman[6] and Adler and associates.[11] Calculations* revealed the same findings in Cases 1 and 3 of our series. In Case 4 no calculations could be made but in this case an extremely high pulmonary capillary pressure excluded the decompressive effect of the anomalous pulmonary venous connection.

In conclusion, from our own series and from a review of the literature, we find that the safety valve mechanism is not a proved fact and that indeed, in a large proportion of cases the high vascular resistance of the anomalously draining lung tissue prevents a significant decompressive effect.

Summary

Four cases of mitral stenosis associated with anomalous pulmonary venous return are described. In two of these cases there was severe mitral regurgitation as well. A pulmonary arteriovenous shunt was also found in one of these.

A review of the records of patients admitted for cardiac catheterization revealed that in 0.42 per cent of the cases of mitral valve disease and 5.7 per cent of the cases of anomalous pulmonary venous drainage, both conditions were associated.

The clinical, roentgenologic, electrocardiographic, and vectorcardiographic findings were predominantly characterized by the mitral valve disease.

In every case, the diagnosis was established at cardiac catheterization.

Hemodynamic studies were performed. These indicated that the circulatory consequences of the mitral valve disease were only little influenced by the anomalous pulmonary venous return.

*The platinum electrode catheters were routinely anodized, which has been shown to improve the method.[16]

*Calculations of vascular resistances were made according to the formula:

$$R(\text{esistance}) = \frac{P(\text{ressure})}{F(\text{low})}.$$

For the normally draining lung tissue P is represented by pulmonary arterial pressure minus the left atrial pressure, and F is given by the systemic flow. For the anomalously draining lung tissue P = pulmonary arterial pressure minus the right atrial pressure, and F = shunt volume.

REFERENCES

1. Hughes, C. W., and Rumore, P. C.: Anomalous pulmonary veins, Arch. Path. **37**:364, 1944.
2. Dimond, E. G., and Gonlubol, F.: Death following angiocardiography. Report of two cases after administration of Diodrast and Neo-iopax, respectively, New England J. Med. **249**:1029, 1953.
3. Sepulveda, G., Lukas, D. S., and Steinberg, I.: Anomalous drainage of pulmonary veins. Clinical, physiologic and angiocardiographic features, Am. J. Med. **18**:883, 1955.
4. Nichols, H. T., Woldow, A., and Goldberg, H.: Partial anomalous pulmonary venous drainage associated with mitral stenosis: Report of a case with surgical correction of both lesions, AM. HEART J. **51**:475, 1956.
5. Zion, M. M.: Mitral stenosis associated with anomalous pulmonary venous drainage into a left superior vena cava, Brit. M. J. **1**:1020, 1956.
6. Lendrum, B. L., and Lichtman, A. M.: Pulmonary vascular resistance in man at different intravascular distending pressure measured in a case of mitral stenosis complicated by anomalous pulmonary venous connection, Circulation **16**:1090, 1957.
7. Reale, A., Gioffre, P. A., and Collela, C.: Due casi di stenosi mitralica associata a subocco venoso pulmonare in atrio destro simulanti la malatia de Lutembacher, Atti Soc. Ital. cardiol. **21**:236, 1959.
8. Warembourg, H., Bonte, G., Pauchant, M., Caron, J., Merovitch, R., and Vayron de la Moureyre, D.: Retour veineux pulmonaire anormal associé à une sténose mitrale, Lille méd. **6**:26, 1961.
9. Wassermil, M., and Hoffman, M. S.: Partial anomalous pulmonary venous drainage associated with mitral stenosis with an intact atrial septum. A distinctive haemodynamic syndrome, Am. J. Cardiol. **10**:894, 1962.
10. Varnauskas, E., Forsberg, S. A., Paulin, S., and Bjure, J.: The syndrome of anomalous pulmonary venous drainage with enlarged left atrium reflecting mitral stenosis, Am. J. Med. **35**:577, 1963.
11. Adler, L. N., Berger, R. L., Starkey, G. W. B., and Abelmann, W. H.: Anomalous pulmonary venous drainage associated with mitral stenosis. Report of a case successfully repaired, New England J. Med. **270**:166, 1964.
12. Aldridge, H. E., and Wigle, E. D.: Partial anomalous pulmonary venous drainage with intact interatrial septum associated with congenital mitral stenosis, Circulation **31**:579, 1965.
13. Goldfarb, B., and Wang, Y.: Mitral stenosis and left to right shunt at the atrial level. A broadened concept of the Lutembacher syndrome, Am. J. Cardiol. **17**:319, 1966.
14. Kalke, B. R., Carlson, R. G., Ferlic, R. M., Sellers, R. D., and Lillehei, C. W.: Partial anomalous pulmonary venous connections, Am. J. Cardiol. **20**:91, 1967.
15. Töply, R.: Eine neue Varietät der oberen Hohlvene, Prager med. Wchnschr. **7**:233, 1882.
16. Bruschke, A. V. G.: Het Waterstof-elektrodesysteem voor de herkenning en lokalisatie van intracardiale links-rechts shunts, Ned. T. Geneesk. **110**:1857, 1966.
17. Swan, H. J. C., and Wood, E. H.: Localization of cardiac defects by dyedilution curves recorded after injection of T-1824 at multiple sites in the heart and great vessels during cardiac catheterization, Proc. Mayo Clin. **28**:95, 1953.
18. Bland, E. F., and Sweet, R. H. A.: Venous shunt for advanced mitral stenosis, J.A.M.A. **140**: 1259, 1949.