

## Fibro-osseous pseudotumor of digits - Expanding the spectrum of clonal transient neoplasms harboring *USP6* rearrangement<sup>☆</sup>

Uta Flucke<sup>a,\*</sup>, Sarah J. Shepard<sup>b</sup>, Elise M. Bekers<sup>a,c</sup>, Roberto Tirabosco<sup>b</sup>, Paul J. van Diest<sup>d</sup>, David Creytens<sup>e</sup>, Joost M. van Gorp<sup>f</sup>

<sup>a</sup> Department of Pathology, Radboud University Medical Center, Nijmegen, The Netherlands

<sup>b</sup> Royal National Orthopedic Hospital NHS Trust, Stanmore, Middlesex, United Kingdom

<sup>c</sup> Department of Pathologie (Pathologie-DNA), Jeroen Bosch Hospital, Den Bosch, The Netherlands

<sup>d</sup> Department of Pathology, Utrecht University Hospital, Utrecht, The Netherlands

<sup>e</sup> Department of Pathology, Ghent University Hospital, Ghent, Belgium

<sup>f</sup> Department of Pathology (Pathologie-DNA), Diaconessenhuis Utrecht, Utrecht, The Netherlands

### ARTICLE INFO

#### Keywords:

*USP6* rearrangement

Fibro-osseous pseudotumor of digits

Soft tissue tumors

### ABSTRACT

Fibro-osseous pseudotumors of the digits (FOPD) is a rare self-limiting lesion composed of bland looking hypercellular fibrous tissue and bone.

*USP6* rearrangement is a consistent genetic finding in aneurysmal bone cyst, nodular fasciitis, myositis ossificans and giant cell lesions of small bones.

We report herein the occurrence of *USP6* rearrangement in fibro-osseous pseudotumors of the digits using fluorescence in situ hybridization analysis (FISH).

Of the five patients included, three were female and two were male. The age ranged from 33 to 72 years (mean 48 years). Lesions arose in the palm (n = 2), thenar (n = 1), middle finger (n = 1) and great toe (n = 1). All patients underwent resection.

Four cases (80%) harbored *USP6* rearrangements showing that fibro-osseous pseudotumors of digits belongs to the spectrum of clonal transient neoplasms including aneurysmal bone cyst, nodular fasciitis, myositis ossificans and giant cell lesion of small bones.

### 1. Introduction

Fibro-osseous pseudotumor of digits (FOPD) is a very rare bone producing condition showing otherwise nodular fasciitis-like features. It originates in the soft tissue predominantly of the hands and more rarely of the wrist and feet. Fingers, especially the index finger are reported as preference sites. In comparison to other digital fibroosseous lesions there is no primary relationship with the periosteum [1-6]. Although, the age range is broad the mean age is in the 4th decade. Precedent traumata were reported in only a subset of cases making a relationship uncertain [1-3]. Pain and swelling of short duration are the usual clinical symptoms [1-3,6]. Radiologically, a soft tissue mass with variable mineralization is seen, often with development of a peripheral bone rim depending on duration [2,3]. Attachment to the periosteum or osseous surface has been rarely observed most probably being a secondary phenomenon due to the close relationship of tissues at these

sites [3].

Because of the clinicopathological features lesions were linked to myositis ossificans and interpreted as being reactive [1-5].

Recently, we identified *USP6* rearrangements in myositis ossificans [7]. This arose the question whether FOPD has corresponding genetic characteristics. We therefore analyzed FOPD cases using *USP6* fluorescence in situ hybridization analysis (FISH).

### 2. Material and methods

The cases were retrieved from the authors' (referral) files. Clinical details were obtained from the referring physicians. The study was conducted in accordance with the Code of Conduct of the Federation of Medical Scientific Societies of the Netherlands, Great Britain and Belgium.

In all cases the tissue was fixed in 4% buffered formalin, routinely

<sup>☆</sup> There are no conflicts of interest.

This research did not receive any specific grant from funding agencies in the public, commercial, or not-for-profit sectors.

\* Corresponding author at: Radboud University Medical Center, Department of Pathology, P.O. Box 9101, 6500 HB Nijmegen, The Netherlands.

E-mail address: [uta.flucke@radboudumc.nl](mailto:uta.flucke@radboudumc.nl) (U. Flucke).

processed including decalcification, if needed, and embedded in paraffin; 2–4 µm thick sections were stained with hematoxylin and eosin.

USP6 FISH detection was performed on paraffin sections of 4 µm. Slides were mounted and dried for 45 min at 55 °C. They were deparaffinized in xylene for 5 min, rehydrated in ethanol (99,5%) and demineralized water. Pretreatment with 10 mM Sodiumcitrate (pH = 6.0) at 96 °C for 10 min followed and after cooling down, rinsing in demineralized water. Slides were rinsed with 0,01 M HCL for 5 min and cells were digested by 200 U/ml pepsin (0,01 M HCL) for 15 min at 37 °C. To remove pepsin, slides were rinsed 3 × shortly with 0,01 M HCl and subsequently with PBS. Slides were fixated in 1% formaldehyde/PBS for 5 min. After that, they were rinsed shortly with PBS and demineralized water and finally dehydrated in increasing ethanol series and are dried.

For the ISH staining, 10 µl USP6 (Kreatech, KBI-00094 split probe, Leica, Rijswijk, The Netherlands) was applied per pre-treated slide. The probe incubated area were covered with a cover glass and sealed with photo glue. The slides were denaturated at 80 °C for 10 min and hybridized overnight at 37 °C. After hybridization the slides were washed in 2xSSC at 42 °C for 5 min to remove the cover glass, then washed for 1 × 1 min and 1 × 2 min in 2xSSC-NP40 3% washbuffer at 73 °C and rinsed with 2xSSC for 5 min (covered). Slides were dehydrated again in increasing ethanol series to demineralized water and were dried. Slides were covered with Vectashield mounting medium with DAPI (Vector, Brunswick, Amsterdam, The Netherlands) and stored at 4 °C.

USP6 signals were scored by two independent experienced technicians and considered positive if at least 20% of the 50 counted cells showed split signals. Slides were scored using a Leica DM4000 (Leitz) fluorescence microscope with a Leica DFC310 FX camera and LAS AF software.

Positive controls were used throughout.

### 3. Results

Clinical and FISH results are summarized in Table 1.

Of the five patients included, three were female and two were male. The age ranged from 33 to 72 years (mean 48 years). Lesions arose in the palm (n = 2), thenar (n = 1), middle finger (n = 1) and great toe (n = 1). All patients underwent resection.

Grossly, the resection specimens showed ill-defined (multi)nodular lesions with a firm grey-white appearance with gritty areas.

Microscopically, in all cases a (multi)nodular infiltrative proliferation of plump, tissue culture-like bland looking myofibroblasts was seen merging with osteoid and woven bone sometimes with maturing areas peripherally. There was osteoblast rimming without atypia. Mitotic activity was readily identified. Osteoclast-like giant cells were variably present in all cases (Fig. 1).

Using FISH, USP6 rearrangements were observed in four out of the five cases (Table 1, Fig. 2).

### 4. Discussion

Fibro-osseous pseudotumor of digits is defined as a classic pseudosarcomatous lesion usually occurring in the superficial soft tissue of the fingers, especially on the proximal phalanx region, and less frequently

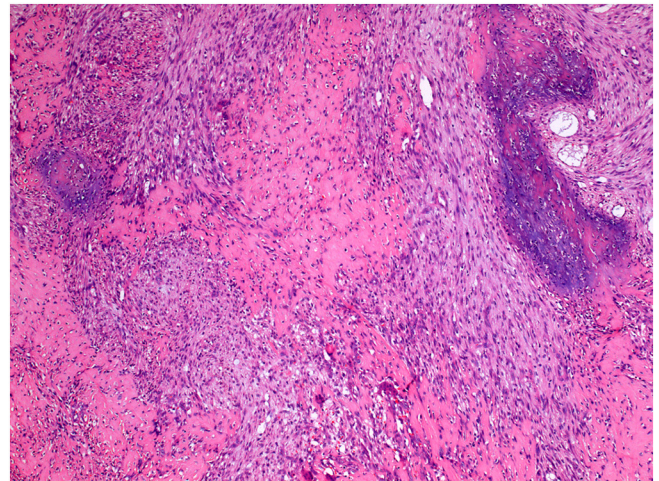


Fig. 1. Classical features of FOPD showing tissue culture-like myofibroblasts merged with osteoid and woven bone were seen in all cases (Case 3).

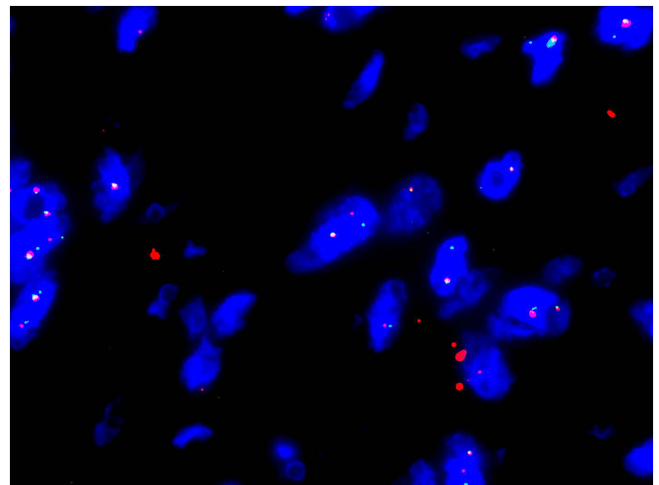


Fig. 2. Using FISH break apart signals of USP6 were observed in 4/5 cases demonstrating rearrangement (Case 3).

on the toes [1-6]. It shares clinicopathological and especially genetic characteristics with nodular fasciitis, myositis ossificans, aneurysmal bone cyst and giant cell lesion of small bones [5,7-12]. These myofibroblastic tissue culture-like and variable bone-producing lesions are transient neoplasms with short duration, rapid growth and secondary involution [7,12]. Pseudocystic changes are most often present in aneurysmal bone cysts and more rarely in myositis ossificans, which is sometimes referred by some authors as aneurysmal bone cyst of soft tissue [7,13,14].

Osteoid and woven bone formations in FOPD are haphazardly distributed with sporadic occurrence of a zonation pattern as seen in myositis ossificans [1,2,6].

In contrast to the initial large FOPD series by Dupree and Enzinger in 1986, Chaudhry et al. [6] discussed a more variable anatomic distribution emphasizing the morphological overlap within the above mentioned soft tissue lesions.

The presence of USP6 rearrangements, the genetic hallmark of all of these neoplasms underpins that they are biologically related [7-12], although the fusion partner of USP6 in the mentioned lesions is usually different with CDH11 and MYH 9 being the most common in aneurysmal bone cysts and nodular fasciitis, respectively [12]. What genetic partners are present in FOPD and whether there is overlap with the other related conditions need to be investigated.

Table 1  
Clinical data and USP6 FISH results.

Case #	Sex/age	Site	USP6 FISH (% of nuclei)
1	f/45	Palm	23
2	m/50	Palm	21
3	m/42	Great toe	22
4	f/33	Middle finger	30
5	f/72	Thenar	< 10

f, female; m, male.

The detection of *USP6* rearrangement can be useful for diagnostic purposes when interpretation of immature bone is challenging because of lack of the bone architecture with peripheral maturation and osteoblast rimming especially in small biopsies [4,7].

Other acral fibro-osseous soft tissue lesions as florid reactive periostitis, subungual exostosis and bizarre parosteal osteochondromatous proliferation (Nora's lesion) are differential diagnoses. These lesions in contrast develop on the surfaces of small bones and share with FODP rapid growth and the nodular fasciitis-like appearance with mineralization and haphazardly arranged woven bone. The fibrous component is usually most prominent at the periphery and overlies cellular hyaline cartilage that undergoes enchondral ossification at its base which is different from FODP [4].

The known genetic changes in Nora's lesion are a t(1;17) translocation [15] and in subungual exostosis a t(X;6) leading to rearrangements of *COL12A1* and *COL4A5* [16-18].

The diagnosis of extrasosseous or surface osteosarcoma is of paramount importance because of the clinical consequences demanding neoadjuvant chemo- and/or radiotherapy and extended surgery. However, these tumor types are extremely rare at acral sites and severe cytological atypia along with more aggressive features on imaging, would lead to the correct diagnoses in most cases [1,4,6].

Synovial sarcoma may also originate at acral sites and may produce bone, however these tumors consist of cellular fascicles of monomorphic spindle cells with elongated nuclei in its monophasic fibrous form. Furthermore, the immunoprofile with positivity for EMA and keratins and the X;18 translocation with SS18-SSX1/2 is specific for this malignant tumor [19].

Prognosis of FODP is excellent with recurrence in exceptional cases. Complete excision is the treatment of choice [1-3].

In conclusion, we have identified *USP6* rearrangements in a series of fibro-osseous pseudotumors of the digits. We therefore argue that this entity belongs to the group of clonal transient neoplasms also including nodular fasciitis, myositis ossificans, aneurysmal bone cyst and giant cell lesion of small bones. *USP6* FISH can be helpful when considering malignancy on clinicopathological grounds.

## References

- [1] Dupree WB, Enzinger FM. Fibro-osseous pseudotumor of the digits. *Cancer* 1986;58:2103–9.
- [2] De Silva MV, Reid R. Myositis ossificans and fibroosseous pseudotumor of digits: a clinicopathological review of 64 cases with emphasis on diagnostic pitfalls. *Int J Surg Pathol* 2003;11:187–95.
- [3] Moosavi CA, Al-Nahar LA, Murphey MD, Fanburg-Smith JC. Fibroosseous pseudotumor of the digit: a clinicopathologic study of 43 new cases. *Ann Diagn Pathol* 2008;12:21–8.
- [4] Rosenberg AE. Pseudosarcomas of soft tissue. *Arch Pathol Lab Med* 2008;132:579–86.
- [5] Rosenberg AE, Oliveira AM. Myositis ossificans and fibro-osseous pseudotumour of digits. In: Fletcher CDM, Bridge JA, Hogendoorn PCW, Mertens F, editors. WHO classification of tumours of soft tissue and bone. Lyon: IARC; 2013. p. 50–1.
- [6] Chaudhry IH, Kazakov DV, Michal M, Mentzel T, Luzar B, Calonje E. Fibro-osseous pseudotumor of the digit: a clinicopathological study of 17 cases. *J Cutan Pathol* 2010;37:323–9.
- [7] Bekers EM, Eijkelenboom A, Grünberg K, Roverts RC, de Rooy JW, van der Geest IC, et al. Myositis ossificans – another condition with *USP6* rearrangement, providing evidence of a relationship with nodular fasciitis and aneurysmal bone cyst. *Ann Diagn Pathol* 2018;34:56–9.
- [8] Oliveira AM, Hsi BL, Weremowicz S, Rosenberg AE, Dal Cin P, Joseph N, et al. *USP6* (*Tre2*) fusion oncogenes in aneurysmal bone cyst. *Cancer Res* 2004;64:1920–3.
- [9] Erickson-Johnson MR, Chou MM, Evers BR, Roth CW, Seys AR, Jin L, et al. Nodular fasciitis: a novel model of transient neoplasia induced by *MYH9-USP6* gene fusion. *Lab Invest* 2011;91:1427–33.
- [10] Amary MF, Hongtao Ye, Berisha F, Tirabosco R, Presneau N, Flanagan AM. Detection of *USP6* gene rearrangement in nodular fasciitis: an important diagnostic tool. *Virchows Arch* 2013;463:97–8.
- [11] Agaram NP, LeLoarer FV, Zhang L, Hwang S, Athanasian EA, Hameed M, et al. *USP6* gene rearrangements occur preferentially in giant cell reparative granulomas of the hands and feet but not in gnathic location. *Hum Pathol* 2014;45:1147–52.
- [12] Oliveira AM, Chou MM. *USP6*-induced neoplasms: the biologic spectrum of aneurysmal bone cyst and nodular fasciitis. *Hum Pathol* 2014;45:1–11.
- [13] Nielsen GP, Fletcher CD, Smith MA, Rybak L, Rosenberg AE. Soft tissue aneurysmal bone cyst: a clinicopathological study of five cases. *Am J Surg Pathol* 2002;26:64–9.
- [14] Sukov WR, Franco MF, Erickson-Johnson M, Chou MM, Unni KK, Wenger DE, et al. Frequency of *USP6* rearrangements in myositis ossificans, brown tumor, and cherubism: molecular cytogenetic evidence that a subset of “myositis ossificans-like lesions” are the early phases in the formation of soft-tissue aneurysmal bone cyst. *Skelet Radiol* 2008;37:321–7.
- [15] Endo M, Hasegawa T, Tashiro T, Yamaguchi U, Morimoto Y, Nakatani F, et al. Bizarre parosteal osteochondromatous proliferation with a t(1;17) translocation. *Virchows Arch* 2005;447:99–102.
- [16] Zambrano E, Nose V, Perez-Atayde AR, Gebhardt M, Hresko MT, Kleinman P, et al. Distinct chromosomal rearrangement in subungual (Duuytren) exostosis and bizarre parosteal osteochondromatous proliferation (Nora lesion). *Am J Surg Pathol* 2004;28:1033–9.
- [17] Nilsson M, Domanski HA, Mertens F, Mandahl N. Molecular cytogenetic characterization of recurrent breakpoints in bizarre parosteal osteochondromatous proliferation (Nora's lesion). *Hum Pathol* 2004;35:1063–9.
- [18] Storlazzi CT, Wozniak A, Panagopoulos I, Sciot R, Mandahl N, Mertens F, et al. Rearrangement of the *COL12A1* and *COL4A5* genes in subungual exostosis: molecular cytogenetic delineation of the tumor-specific translocation t(X;6) (q13–14;q22). *Int J Cancer* 2006;118:1972–6.
- [19] Suurmeijer AJH, de Bruijn D, Geurts van Kessel A, Miettinen MM. Synovial sarcoma. In: Fletcher CDM, Bridge JA, Hogendoorn PCW, Mertens F, editors. WHO classification of tumours of soft tissue and bone. Lyon: IARC; 2013. p. 213–5.